

Received: 2017.08.04
Accepted: 2017.10.23
Published: 2018.02.16

Raised Serum Levels of Syndecan-1 (CD138), in a Case of Acute Idiopathic Systemic Capillary Leak Syndrome (SCLS) (Clarkson's Disease)

Authors' Contribution:
Study Design A
Data Collection B
Statistical Analysis C
Data Interpretation D
Manuscript Preparation E
Literature Search F
Funds Collection G

ABCDEF 1 **Ole Wilhelm Bøe**
ABCDEF 1 **Kjell Sveen**
BDE 2,3 **Magne Børset**
CDEF 4 **Kirk M. Druey**

1 Department of Medical Biochemistry, Innlandet Hospital Trust, Lillehammer, Norway
2 Department of Cancer Research and Molecular Medicine, Norwegian University of Science and Technology, Trondheim, Norway
3 Department of Immunology and Transfusion Medicine, St. Olav's University Hospital, Trondheim, Norway
4 Molecular Signal Transduction Section, Laboratory of Allergic Diseases, National Institute of Allergy and Infectious Diseases/National Institutes of Health (NIAID/NIH), Bethesda, MD, U.S.A.





Corresponding Author: Kirk M. Druey, e-mail: kdruey@niaid.nih.gov
Conflict of interest: None declared
Source of support: This study was supported in part by the Intramural Research Program of the National Institute of Allergy and Infectious Diseases/ National Institutes of Health (NIAID/NIH) (Grant AI0001083 to K.M.D)

Patient: Female, 49
Final Diagnosis: Systemic capillary leak syndrome (SCLS)
Symptoms: Hypotension
Medication: —
Clinical Procedure: None
Specialty: Allergology

Objective: Rare disease
Background: Systemic capillary leak syndrome (SCLS) (Clarkson's disease) is a rare disorder of unknown etiology, characterized by transient episodes of hypotension, and the microvascular leak of fluids into the peripheral tissues, resulting in edema. Between 80–90% of patients with SCLS have a concomitant monoclonal gammopathy. Although translational *in vitro* studies have implicated vascular endothelial barrier dysfunction in the etiology of SCLS, the etiology and disease associations in clinical cases remain unknown.
Case Report: We report a case of SCLS in a 49-year-old woman who initially presented with an upper respiratory tract infection, which was complicated by edema and compartment syndromes in the extremities that required fasciotomies. Serum levels of the cell surface heparan sulfate proteoglycan, syndecan-1 (CD138), a measure of endothelial surface glycocalyx (ESG) damage, were measured by enzyme-linked immunoassay (ELISA), peaked at up to 500 ng/mL (reference range, 50–100 ng/mL) and normalized on disease remission.
Conclusions: This case report supports the view that damage to the microvascular endothelium, has a role in the pathogenesis of acute SCLS. This case also indicated that monitoring serum levels of syndecan-1 (CD138) might be used to monitor the progression and resolution of episodes of SCLS.

MeSH Keywords: Capillary Leak Syndrome • Cardiovascular Abnormalities • Endothelium, Vascular

Full-text PDF: <https://www.amjcaserep.com/abstract/index/idArt/906514>

 2839  2  1  24



Background

Systemic capillary leak syndrome (SCLS) (Clarkson's disease) presents clinically with transient hemoconcentration, hypoalbuminemia, hypotension, and generalized edema, without known cause [1]. In 1960, Clarkson et al. first described an idiopathic form of this disorder characterized by repeated episodes of edema and hypotension associated with increased capillary permeability that resolved spontaneously [2]. Although triggers for acute episodes of SCLS have not yet been identified, they are frequently preceded by viral infections or intense physical exertion, suggesting a role for inflammatory mediators in acute SCLS [1].

Common complications of SCLS include hypotensive shock, acute kidney injury resulting from hypovolemia, and muscle compartment syndromes due to massive soft tissue edema, which can lead to mortality in untreated cases. Treatment for acute episodes of SCLS is supportive, including an intravenous infusion of crystalloids, colloids, and vasopressors to maintain adequate blood pressure, but with avoidance of excessive intravenous fluids that can exacerbate edema. Clinical observation and monitoring for the early signs and symptoms of an acute attack of SCLS, and treatment in a highly equipped intensive care unit (ICU) are all important measures to improve the chances of patient survival. A monoclonal gammopathy, typically IgG kappa, has been described in up to 90% of patients with acute SCLS [3,4]. From the published literature, most cases of SCLS present in middle-aged adults, and SCLS is equally reported in both sexes [5,6]. Although at least 300 cases of SCLS have been reported in the literature at this time, because the condition is rare and the diagnosis may be missed, it is likely that cases of SCLS are under-reported.

Findings from *in vitro* studies suggest that vascular endothelial hyperpermeability contributes to the clinical presentation of SCLS [7,8]. Also, serum samples from patients in the acute phase of SCLS, when added to normal microvascular endothelial cells in culture disrupted cell-cell contacts and induced morphological changes consistent with vascular barrier dysfunction [7,8]. Microvascular endothelial cells provide the foundation for the vasculature, and on their luminal side, the microvascular endothelial cells secrete endothelial surface glycoalyx (ESG), which is of critical importance for the stabilization of hemodynamic equilibrium [9]. The basal side of the endothelium, lined by a basement membrane, forms important contacts with the extracellular matrix. These microvasculature structures function as a barrier between the blood and the interstitial fluid. During acute episodes of SCLS, the microvascular endothelial barrier is highly permeable for fluid, plasma, and protein molecules of up to 900 kDa, which can enter into the interstitial space, causing edema [10]. The specific molecules that mediate endothelial hyperpermeability in SCLS are unknown.

Although a flu-like prodrome has been reported in up to 88% of cases of SCLS, specific infectious or other triggers for attacks can only be identified in approximately 60% of cases [3,5]. Common complications of acute attacks of SCLS include acute kidney failure (89%), muscle compartmental syndromes with rhabdomyolysis (43%), thromboses, pulmonary edema, and painful peripheral neuropathies. The five-year survival rate for SCLS has been reported to be between 73–78% [3,5].

This report is the second known case of SCLS in Norway [9]. In addition to reporting a rare condition, this report includes details of the medical history of the family members, in an attempt to identify predisposing factors for SCLS. In this case, a family history of lymphoproliferative disorders, cardiovascular disease, cancer, and diabetes was identified. A transient increase in the cell surface heparan sulfate proteoglycan, syndecan-1 (CD138) was identified during the acute presentation, which normalized during the recovery phase. These findings suggest that reduced ESG function could contribute to vascular endothelial hyperpermeability in SCLS.

Case Report

In 2009, a 49-year-old woman reported an upper respiratory tract infection with rhinorrhea, cough, and fever of between 38–39°C, for two days. The patient had experienced increasing lethargy, fatigue, and loss of appetite for several days and was confined to bed. She became dehydrated and noted reduced urine output. On the fifth day of her symptoms, she experienced a brief syncopal attack with subsequent nausea and vomiting, but she was awake with normal mentation, but this episode resulted in emergency admission to hospital by ambulance and given intravenous Ringer's solution.

On hospital admission, the patient had no detectable pulse or measurable blood pressure in her extremities. She experienced brief, intermittent episodes of syncope but was fully awake and mentally coherent between these episodes. She initially presented with blueish extremities but had no peripheral edema or skin rashes. Her blood pressure was 60/40 mm Hg, her pulse was regular at between 85–105 beats per min, her temperature was 35.9°C, her respiration rate was 42 breaths per min, and her weight to height ratio was 50 kg to 1.65 m. Serum glucose was 9.8 mmol/L, with dipstick urinalysis showing urine protein of 3+, and erythrocytes of 2+. Electrocardiogram (ECG) and echocardiography were normal. Analytical blood results before, during, and after the initial presentation are summarized in Table 1.

On admission, on the fifth day of her illness, high values were measured for hemoglobin (Hb) (24.6 g/dL), hematocrit (Hct) (73%), and erythrocytes ($7.6 \times 10^{12}/L$). White blood cells were increased ($17 \times 10^9/L$) and were mainly comprised of neutrophils

Table 1. Laboratory results and treatments before, during and after the capillary leak attack.

| Day of illness | Time of day | Hgb 11.2–15.3 | Hct 35–46 | WBC 3.5–10 | Neutrophils 2.0–7.5 | Plt 145–390 | T.P./albumin 62–78/ 36–45 | Creatinine 45–90 | AST 5–15 | ALT 7–56 | CK 35–210 | Treatment |
|----------------|-------------|------------------|--------------|---------------|------------------------|----------------|---------------------------------|---------------------|-------------|-------------|--------------|---|
| –4 months | | 14.4 | | 5.1 | | | | 76 | | 23 | | |
| Day 5 | 20: 00 | 24.6 | 73 | 17 | 15 | 298 | 69/37 | 142 | 35 | 43 | 137 | Hospital admission IV fluids, antibiotics, corticosteroids, anticoagulation |
| Day 6 | 4: 00 | | | | | | | | | | | Fasciotomy #1 |
| | 8: 00 | 18.7 | 54 | 27.7 | | 277 | 34/19 | 86 | | | | |
| | 11: 00 | 17.4 | 54 | 29.1 | 25.1 | | 29/18 | 88 | 18 | 16 | 198 | |
| | 20: 00 | 16.9 | 51 | 26.2 | | 291 | | | | | | Furosemide |
| | 22: 00 | | | | | | | | | | | Fasciotomy #2 |
| | 24: 00 | 15.8 | 48 | 23.5 | 20 | 309 | 40/28 | | 204 | 41 | 8193 | |
| Day 7 | 06: 00 | 12.2 | 36 | 13.4 | 12.4 | | 31/20 | 112 | | 68 | 12410 | |
| | 14: 00 | | | | | | | | | | | IVIg |
| Day 9 | | 9.5 | 28 | | | 160 | 52/24 | 82 | 655 | 128 | 13980 | |
| Day 10 | | 7.2 | 21 | 5.0 | 4.0 | 141 | 64/24 | 63 | 593 | 172 | 8237 | |
| Day 11 | 07: 00 | 8.5 | 25 | 5.6 | 4.7 | 153 | 67/27 | 51 | | 256 | 5099 | SAG |
| Day 12 | | 7.8 | 23 | 7.5 | | 201 | 61/27 | 52 | 363 | 255 | 2404 | |
| Day 13 | | 8.3 | 24 | 10.7 | | 303 | 65 | 50 | 266 | 255 | 1303 | |
| Day 14 | | 8.7 | | 10.8 | | | | 55 | 218 | 281 | 447 | |
| 6 months | | 13.4 | | 5.5 | | 330 | 68/48 | 70 | | 33 | 240 | None (asymptomatic) |
| 5 years | | 15.0 | 048 | 5.4 | | 267 | 68/50 | 73 | 26 | 22 | 373 | None (asymptomatic) |

Results marked in **red** are above the upper reference limit, **black** within reference ranges, **blue** are below the reference range.

Treatments are marked in **green**. Normal reference values are indicated in the top row.

Hgb – hemoglobin (g/dL); Hct – hematocrit (%); WBC – white blood count ($\times 10^9/L$); Neutrophils – neutrophil count ($\times 10^9/L$); Plt – platelets ($\times 10^9/L$); T.P./Alb – total protein (g/L)/albumin (g/L); Creatinine – (micromol/L); AST – aspartate aminotransferase (U/L); ALT – alanine aminotransferase (U/L); CK – creatinine phosphokinase (U/L); IVIG – intravenous immunoglobulin; SAG – saline-adenine-glucose-mannitol (SAGMAN) red cell concentrate.

($15 \times 10^9/L$). Platelet levels were $298 \times 10^9/L$, and total protein was 69 g/L, which were all within normal reference values. Albumin (37 g/L) was decreased compared to a previous baseline value of 50 g/L. Creatinine (142 mmol/L), serum glutamic oxaloacetic transaminase (SGOT), and creatinine kinase (CK) all were increased. C-reactive protein (CRP) was 8 mg/L, which was 3 mg/L above normal limits. On hospital admission, only small amounts of urinary protein (0.2–0.5 g/L) were detected.

Because of her hypotension and elevated white blood cell count, a diagnosis of afebrile sepsis was first suspected, and she was treated empirically with antibiotics; she was also anticoagulated with enoxaparin 40 mg because she was considered to be at increased risk for thrombosis; intravenous hydrocortisone 250 mg was given for presumed adrenal insufficiency. She received 20 liters of intravenous crystalloid to achieve hemodynamic stability, which resulted in rapid development of generalized peripheral edema.

Five hours after her hospital admission, she required fasciotomy in both lower extremities to treat acute compartment syndrome. The muscles of the legs appeared to be clinically normal, and a pressure gauge was inserted into the muscle to enable incision closure and wound monitoring. Although the diuretic furosemide was given, urine output remained minimal during the first 24–48 hours following hospital admission.

On the sixth day of her illness, pleural effusions and retropharyngeal edema were diagnosed radiologically. However, her leg pain and interstitial muscle pressure increased progressively, and a bilateral fasciotomy was again performed. Necrotic areas were now seen in the leg muscles.

Creatine kinase (CK) levels increased over the next two days, peaking on the ninth day of her illness (13,980 U/L). Sporadic increases in liver and muscle enzymes were detected. Following resuscitation with large amounts of intravenous fluids and plasma extravasation from the surgical fasciotomy sites, the patient developed anemia requiring transfusion on the tenth day of disease. A slight increase in fibrinogen was noted on admission while D-dimer was normal. Erythrocyte sedimentation rate (ESR), prothrombin time (PT), INR, and platelet counts were all within normal limits during her hospital course. On the ninth day of her disease, complement levels, C3 (0.46 g/L) and C4 (0.05 g/L) were decreased. More extensive complement analysis performed one year later revealed lack of mannose-binding lectin (MBL), as shown in Table 2.

Based on clinical signs, symptoms, and laboratory tests, the differential diagnosis included sepsis, idiopathic anaphylaxis, hereditary angioedema, polycythemia vera, and cardiac insufficiency. However, these diagnoses were excluded because the combination of signs and symptoms of severe hemoconcentration, hypoalbuminemia, protracted hypotension, and generalized edema with accompanying compartment syndromes were pathognomonic of systemic capillary leak syndrome (SCLS).

In support of the diagnosis of SCLS, C1 esterase inhibitor levels and function were normal, and blood cultures were negative. There were no triggers found for an anaphylaxis reaction, and there were no typical allergic signs and symptoms of anaphylaxis, such as urticaria, stridor, or wheezing. Although small amounts of proteinuria were detected, urinary protein loss was unlikely to account for the acute drop in serum albumin. The urinary protein before the episode was equivalent to that obtained at the time of hospital admission, whereas serum albumin was initially normal on admission, and urine output was minimal during this time. Also, the urinary protein to creatinine ratio was only 0.4, which was well below levels required for the diagnosis of nephrotic syndrome. Serum immunoelectrophoresis showed a monoclonal IgG-kappa paraprotein (1–2 g/L); IgG paraprotein is frequently (80–90%) found

Table 2. Complement analyses one year after SCLS episode.

| | |
|-----------------------------------|------------|
| Normal classic activation pathway | 75 (>40%) |
| Lectin activation pathway | 0 (>10%) |
| Alternative activation pathway | 92 (>10%) |
| Mannose-binding lectin pathway | <50 (>500) |

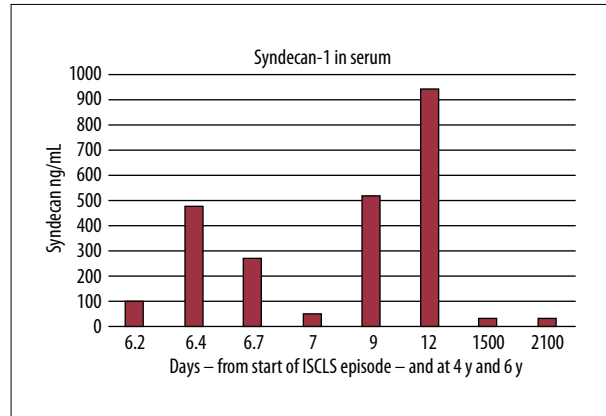


Figure 1. Serum levels of syndecan-1 (CD138) reflect the clinical course in a patient with systemic capillary leak syndrome (SCLS) (Clarkson's disease). Concentrations of soluble syndecan-1 (CD138) in serum samples taken in hospital during the episode of systemic capillary leak syndrome (SCLS) (Clarkson's disease), and in controls, four years and six years later. The syndecan-1 (CD138) reference range is 50–100 ng/mL. Intravenous immunoglobulin IgG (IVIG) was administered after the sample (marked 7) was taken. Day of disease (DOD) values are represented on the x-axis.

in the serum of patients with SCLS (1). Free kappa or lambda light chains were within normal reference ranges, and the kappa to lambda ratio was normal. While IgG and IgA were in the lower reference range, IgM was in the high normal range. Serum levels of the cell surface heparan sulfate proteoglycan, syndecan-1 (CD138), a measure of endothelial surface glyco-calyx (ESG) damage, were analyzed by enzyme-linked immunoassay (ELISA) (Dialclone, Besancon, France) and peaked at up to 500 ng/mL (reference range, 50–100 ng/mL), and normalized on disease remission (Figure 1).

Treatment with intravenous immunoglobulin IgG (IVIG) commenced on the seventh and eighth day of illness, based on previous reports of its efficacy in acute SCLS [12]. Clinical improvement was found within the first two hours of IVIG treatment, with resorption of generalized edema and an increase in urine output, and no signs of pulmonary edema developed on the following days. Antibiotics were withdrawn.

Five weeks following hospital admission, the patient left the hospital and underwent a slow process of rehabilitation. However, at present, due to leg pains and muscular weakness, she currently requires orthopedic support for walking, remains weak, and her quality of life is reduced. The patient also suffers from frequent upper respiratory tract infections but has had no further episodes of SCLS in the past eight years. The M-component of her monoclonal gammopathy has progressively declined to almost undetectable levels, and Hb, Hct, creatinine, and CK have remained within normal limits (Table 1). She has received prophylaxis with terbutaline and theophylline, as recommended in the literature for the treatment of SCLS. The patient has been informed of her medical condition and has been made aware of the early symptoms of SCLS with information regarding this condition, should she require further hospital admissions.

Relevant past medical history and family history

Examination of the patient's prior medical history showed that she was born nine weeks before term, weighing 1,070 g. Pregnancy and delivery were complicated by toxemia, Rhesus incompatibility, and exchange transfusion. She had appendicitis at two-years-of-age, which was complicated by sepsis. From early childhood, she had repeated urinary tract infections with cystitis, and at least four episodes of cysto-pyelonephritis, but she had no permanent kidney damage. During her pregnancies an increased blood glucose was noted.

In her paternal family, there were several cases of premature death due to heart disease, cancer, and diabetes. Her mother had toxemia associated with all three pregnancies, and died at 76 years-of-age and had a weak serum IgM-lambda monoclonal gammopathy of undetermined significance (MGUS). Six of mother's brothers and sisters died of cardiovascular disease, and one of the mother's sisters died at 72-years-of-age of multiple myeloma after 12 years with a known IgA-kappa monoclonal gammopathy of undetermined significance (MGUS).

Discussion

The pathogenesis of systemic capillary leak syndrome (SCLS) (Clarkson's disease) is not understood, and the site of the vascular endothelial hyperpermeability in SCLS remains unknown. Although transient increases in circulating vascular endothelial growth factor (VEGF), angiotensin-2 (Angpt-2), and monocyte/macrophage-associated inflammatory mediators including C-X-C chemokine motif 10 (CXCL10), tumor necrosis factor (TNF)- α , and interleukin (IL)-6 during acute episodes of SCLS suggest a role for these cytokines in the mechanism of vascular leak, the specific pathways resulting in vascular endothelial hyperpermeability in SCLS remain unknown. Preliminary study

findings from our laboratory (*unpublished data*) suggest that individuals affected by SCLS have cutaneous hyper-responsiveness to inflammatory mediators that affect the microvasculature and that endothelial cells derived from patients with SCLS exhibit this behavior persistently *in vitro*.

The barrier function of the microvasculature is a complex physiological process in which adhesive cell-cell junction contacts prevent plasma and cell extravasation. Under normal homeostatic conditions, microvascular endothelial cells secrete endothelial surface glyocalyx (ESG), which fortifies the endothelial barrier via several mechanisms. ESG is a fibrous matrix rich in negatively-charged proteoglycans containing sialic and neuraminic acids, which prevent binding of circulating leukocytes and platelets. Vascular endothelial cells actively build and replenish the structural components of ESG, as well as blood group antigens and endothelial superoxide dismutase (eSOD). Components from plasma, including albumin, antithrombin, and calcium ions, are interspersed throughout the ESG meshwork, which helps to maintain intravascular osmotic pressure, coagulation, and platelet adhesion [13,14]. ESG also protects endothelial cells from shear stress induced by circulating blood, and ESG degradation due to endothelial cell damage may contribute to the severity of plasma leak in diverse clinical conditions including, dengue virus infection and heart failure [15–17].

Syndecan-1 (CD138) is a transmembrane proteoglycan component of ESG that binds to hyaluronan on the luminal side of the endothelial cell membrane and cytoskeletal components on the cytosolic side. In conditions associated with ESG disruption, for example, sepsis, trauma, and ischemia, syndecan-1 (CD138) is shed and circulates in the serum, reflecting both damage to the ESG and weakening of the endothelial barrier [18]. Damage to ESG promotes white blood cell and platelet adherence to the endothelial wall, initiating thrombosis. Plasma fluid leaks into the interstitial space through trans-endothelial cell pores and through widened intercellular gaps, which partially depend on the availability of syndecan-1 (CD138) [9].

In the case of the patient in this report, fluctuating levels of syndecan-1 (CD138) were found during the presentation of SCLS. Serum syndecan-1 (CD138) levels were within the normal range for the first several days of the acute presentation, peaked at five times the upper limit of normal on the sixth day, and then returned to baseline after that. An upper respiratory infection preceded the attack of SCLS in this patient, and it has previously been reported that viral membrane components, including neuraminidase, may lead to ESG disruption through digestion of neuraminic acids [19]. Therefore, viremia may have resulted in disruption of ESG in this patient. Serum syndecan-1 (CD138) levels increased to nearly ten times the upper limit of normal on days 9–12, which could reflect

reperfusion injury resulting from mobilization of extravasated fluid during the recovery phase and restoration of intravascular volume, a phenomenon that has been described by previous clinical studies [20]. Syndecan-1 (CD138) levels returned to baseline during the convalescent phase, indicating the resolution of the acute endothelial dysfunction.

In this patient, several additional laboratory abnormalities were found during the acute phase in our patient that have not been previously reported in association with SCLS. Low levels of C3 and C4 were detected on the ninth day of the disease, which could reflect extravasation due to increased microvascular permeability, rather than complement consumption. Mannose-binding lectin (MBL) was low or undetectable in our patient. MBL adheres to mannose on the surface of many pathogens forming the complex, MBL-associated serine protease (MASP). MASP leads to the cleavage of C4 into C4a and C4b; C4b fragments then bind to microbes, initiating formation of C3-convertase. The subsequent complement cascade catalyzed by C3-convertase creates a membrane attack complex, which causes lysis of the pathogen as well as apoptosis and cell necrosis. MBL binds to glycoprotein in viruses and is instrumental in the first-line defense against infection [21]. MBL deficiency has been reported to be associated with recurrent infections in humans but has not previously been reported in SCLS. In the case of the patient in this report, MBL deficiency may have accounted for her history of frequent infections, including cystitis and pyelonephritis, as well as the frequent upper respiratory tract viral infections, such as the episode that triggered her attack of SCLS. Low levels of IgG and IgA, with normal levels of IgM, are findings that have previously been reported in cases of SCLS [22,23].

References:

1. Druey KM, Parikh SM: Idiopathic systemic capillary leak syndrome (Clarkson disease). *J Allergy Clin Immunol*, 2017; 140(3): 663–70
2. Clarkson B, Thompson D, Horwith M, Luckey EH: Cyclical edema and shock due to increased capillary permeability. *Trans Assoc Am Physicians*, 1960; 73: 272–82
3. de Chambrun MP, Gousseff M, Mauhin W et al: Intravenous immunoglobulins improve survival in monoclonal gammopathy-associated systemic capillary-leak syndrome. *Am J Med*, 2017; 130(10): 1219.e19–e27
4. Kapoor P, Greipp PT, Schaefer EW et al: Idiopathic systemic capillary leak syndrome (Clarkson's disease): The Mayo clinic experience. *Mayo Clin Proc*, 2010; 85(10): 905–12
5. Gousseff M, Arnaud L, Lambert M et al: The systemic capillary leak syndrome: A case series of 28 patients from a European registry. *Ann Intern Med*, 2011; 154(7): 464–71
6. Dhir V, Arya V, Malav IC et al: Idiopathic systemic capillary leak syndrome (SCLS): case report and systematic review of cases reported in the last 16 years. *Intern Med*, 2007; 46(12): 899–904
7. Xie Z, Ghosh CC, Patel R et al: Vascular endothelial hyperpermeability induces the clinical symptoms of Clarkson disease (the systemic capillary leak syndrome). *Blood*, 2012; 119(18): 4321–32
8. Xie Z, Ghosh CC, Parikh SM, Druey KM: Mechanistic classification of the systemic capillary leak syndrome: Clarkson disease. *Am J Respir Crit Care Med*, 2014; 189(9): 1145–47
9. Radeva MY, Waschke J: Mind the gap: Mechanisms regulating the endothelial barrier. *Acta Physiol (Oxf)*, 2017 [Epub ahead of print]
10. Atkinson JP, Waldmann TA, Stein SF et al: Systemic capillary leak syndrome and monoclonal IgG gammopathy; Studies in a sixth patient and a review of the literature. *Medicine (Baltimore)*, 1977; 56(3): 225–39
11. de Chambrun MP, Luyt CE, Beloncle F et al: The clinical picture of severe systemic capillary-leak syndrome episodes requiring ICU admission. *Crit Care Med*, 2017; 45(7): 1216–23
12. Lambert M, Launay D, Hachulla E et al: High-dose intravenous immunoglobulins dramatically reverse systemic capillary leak syndrome. *Crit Care Med*, 2008; 36(7): 2184–87
13. Chappell D, Westphal M, Jacob M: The impact of the glycocalyx on microcirculatory oxygen distribution in critical illness. *Curr Opin Anaesthesiol*, 2009; 22(2): 155–62
14. Nieuwdorp M, van Haefen TW, Gouverneur MC et al: Loss of endothelial glycocalyx during acute hyperglycemia coincides with endothelial dysfunction and coagulation activation *in vivo*. *Diabetes*, 2006; 55(2): 480–86
15. Suwanto S, Sasmono RT, Sinto R et al: Association of endothelial glycocalyx and tight and adherens junctions with severity of plasma leakage in Dengue infection. *J Infect Dis*, 2017; 215(6): 992–99
16. Nguyen TH, Liu S, Ong GJ et al: Glycocalyx shedding is markedly increased during the acute phase of Takotsubo cardiomyopathy. *Int J Cardiol*, 2017; 243: 296–99

Conclusions

This case report supports the view that damage to the microvascular endothelium and its ESG have a role in the pathogenesis of acute systemic capillary leak syndrome (SCLS) (Clarkson's disease). This case also indicated that monitoring serum levels of syndecan-1 (CD138) might be used to monitor progression and resolution of episodes of SCLS. Further studies are needed to determine the mechanisms underlying the degradation of endothelial surface glycocalyx (ESG) and vascular damage in SCLS.

Statement

The patient was enrolled in a National Institutes of Health (NIH) institutional review board (IRB)-approved study protocol (I-09-0184) after written informed consent was obtained. The patient also consented to the publication of this case report.

17. Kim YH, Nijst P, Kiefer K, Tang WH: Endothelial glycocalyx as biomarker for cardiovascular diseases: Mechanistic and clinical implications. *Curr Heart Fail Rep*, 2017; 14(2): 117–26
18. Rahbar E, Cardenas JC, Baimukanova G et al: Endothelial glycocalyx shedding and vascular permeability in severely injured trauma patients. *J Transl Med*, 2015; 13: 117
19. Puerta-Guardo H, Glasner DR, Harris E: Dengue virus NS1 disrupts the endothelial glycocalyx, leading to hyperpermeability. *PLoS Pathog*, 2016; 12(7): e1005738
20. Rehm M, Bruegger D, Christ F et al: Shedding of the endothelial glycocalyx in patients undergoing major vascular surgery with global and regional ischemia. *Circulation*, 2007; 116(17): 1896–906
21. Ji X, Olinger GG, Aris S et al: Mannose-binding lectin binds to Ebola and Marburg envelope glycoproteins, resulting in blocking of virus interaction with DC-SIGN and complement-mediated virus neutralization. *J Gen Virol*, 2005; 86(Pt 9): 2535–42
22. Kang PM, Lawrence C, Khan GA, Hays RM: Fulminating systemic capillary leak syndrome with lymphocytosis and hypogammaglobulinemia. *Ren Fail*, 1995; 17(5): 615–17
23. Lassoued K, Clauvel JP, Similowski T et al: Pulmonary infections associated with systemic capillary leak syndrome attacks in a patient with hypogammaglobulinemia. *Intensive Care Med*, 1998; 24(9): 981–83
24. Zhang W, Ewan PW, Lachmann PJ: The paraproteins in systemic capillary leak syndrome. *Clin Exp Immunol*, 1993; 93(3): 424–29