

ORIGINAL ARTICLE

STATE OF MICROCIRCULATION AND FREE-RADICAL PROCESSES OF PERIODONTAL TISSUES IN SMOKING DEPENDENT PATIENTS WITH CHRONIC GENERALIZED PERIODONTITIS ASSOCIATED WITH CHRONIC HYPERACID GASTRITIS

DOI: 10.36740/WLek202201202

Iuliia G. Romanova¹, Olena L. Zolotukhina², Georgy O. Romanov³, Stanislav A. Shnaider², Iryna M. Tkachenko⁴¹“ODESSA INTERNATIONAL MEDICAL UNIVERSITY” MES OF UKRAINE, ODESA, UKRAINE²THE ODESSA NATIONAL MEDICAL UNIVERSITY, ODESA, UKRAINE³UZHGOROD NATIONAL UNIVERSITY, UZHGOROD, UKRAINE⁴POLTAVA STATE MEDICAL UNIVERSITY, POLTAVA, UKRAINE

ABSTRACT

The aim: The aim of the work was to determine the state of microcirculation and free radical processes of periodontal tissues in smoking dependent patients with chronic generalized periodontitis associated with chronic hyperacid gastritis.

Materials and methods: We examined 90 patients (men and women) aged 25 to 44 years, who were divided into 3 groups: the first group - 48 smoking patients with chronic generalized periodontitis and chronic hyperacid gastritis associated with *Helicobacter pylori*; the second group - 22 patients with chronic generalized periodontitis and chronic hyperacid gastritis associated with *Helicobacter pylori*, without the bad habit; the third group - control, consisted of 20 healthy individuals. The smoking patients were randomly divided into two subgroups: patients of the first subgroup (G1.1) received the basic therapy of chronic generalized periodontitis and the proposed treatment and prevention complex; the patients in the second subgroup (G1.2) received basic therapy for chronic generalized periodontitis and ultraphonophoresis with placebo.

Results: The use of treatment and prevention complex in smoking dependent patients and patients without the bad habit with chronic generalized periodontitis and chronic hyperacid gastritis associated with *Helicobacter pylori* demonstrated a positive dynamics of the functional characteristics of microcirculation and the balance in the lipid peroxidation – antioxidant system.

Conclusions: So, the use of the proposed treatment and prevention complex had a positive effect on the state of microcirculation and free radical processes of periodontal tissues both at the near and long-term follow up, even under conditions of chronic hyperacid gastritis and the risk factor – smoking.

KEY WORDS: periodontitis, microcirculation, gastritis, smoking

Wiad Lek. 2022;75(1 p.2):156-163

INTRODUCTION

Periodontal diseases today remain an urgent problem of modern dentistry. The attention of dentists is focused on chronic generalized periodontitis (ChGP), which is associated with bad habits and comorbidities [1]. It is known that periodontal pathology is of polyetiologic nature, which is characterized by the development of the pathological process under the influence of risk factors and concomitant somatic pathology [2; 3]. Chronic generalized periodontitis is closely related on the one hand with the damaging effect of local microbial expansion and on the other hand — with the state of the host, namely with the immune, neurohumoral systems and disorders of internal organs [4].

One of the important risk factors for the development of periodontal disease is smoking [5; 6]. Smoking has wide systemic effects, many of which may provide mechanisms of increased susceptibility to periodontitis and poorer

susceptibility to treatment [7]. That is, smoking can affect both the tissues of the oral cavity and indirectly being a systemic factor [8].

Among the comorbid somatic diseases, the pathology of the gastrointestinal tract (GIT) is often accompanied by inflammatory-dystrophic periodontal disease [9]. The most common pathology of GIT in middle-aged people is chronic hyperacid gastritis (ChHG), which is accompanied by increased secretion of gastric juice [10]. It is known that pathology of the stomach and duodenum develops more often in smokers than in non-smokers. This can be explained by the fact that smoking causes gastric secretion imbalance, disrupts pyloric activity, reduces the secretion of bicarbonate by the pancreas and prevents ulcers healing. With combination of risk factors and concomitant pathology, periodontal tissues are more negatively affected, which can manifest itself in a prolonged recurrent inflammatory process, aggravation of the disease course, resistance to

treatment [11].

Many scientific studies have shown that the leading role in the pathogenesis of inflammatory-dystrophic periodontal diseases is played by the hemomicrocirculation disorders, which leads to tissue hypoxia, edema, dystrophy, necrosis and tissue sclerosis. Expansion of capillaries, increasing of their permeability, dilation of the venous vessels of the microcirculatory tract occurs with ChGP [12]. Free radical oxidation plays a leading role in the pathogenesis of microcirculation disorders, which causes periodontal tissue cell membranes destabilization, disturbing their functional activity [13]. So, in order to correct microcirculatory disorders and improve tissue trophicity, venotonic and angioprotective herbal drugs are used. The active substances of such drugs are most often plant flavonoid compounds — diosmin and hesperidin, which have venotonic, phleboprotective action [14].

THE AIM

The aim of the work is to determine the state of microcirculation and free radical processes of periodontal tissues in smoking dependent patients with ChGP associated with ChHG.

MATERIALS AND METHODS

We examined 90 patients (men and women) aged 25 to 44 years, who were divided into 3 groups. The first (main) group consisted of 48 patients with ChGP of initial, first degree associated with ChHG associated with *Helicobacter pylori*, with a smoking history 5–7 years and cigarettes smoked from 15 to 20 per day. The second group (comparison group) included 22 patients with initial, first-degree ChGP and a history of concomitant ChHG associated with *Helicobacter pylori*, but without the bad habit of smoking. The third (control) group consisted of 20 healthy individuals who had no history of oral pathology, comorbid somatic diseases and bad habits. All patients had a diagnosis of concomitant pathology from a gastroenterologist using video fibrogastroscopy (Olympus GIF-160). The diagnosis of ChGP was made on the basis of clinical studies, in accordance with classification of periodontal disease according to N.F. Danylevskiy (1994) [15].

At the next stage, the patients of the main group were randomly divided into two subgroups depending on the proposed treatment regimen. The patients of the first subgroup (G1.1) used the following treatment regimen, which included basic therapy of ChGP and the proposed treatment and prevention complex (TPC): 10 procedures of ultraphonophoresis (an ultrasound therapy device “UZT-1.02 C” with a set of emitters of ultrasound apparatuses “VUT 0.88–1.03 F” (for dentistry), VAT “EMA”, Moscow, Russia) alternate days with the developed gel based on bee products and other biologically active substances [16], gel application in the amount of 0.05–0.2 g on the affected areas of the gums at home (2 times a day after meals and oral hygiene, an exposure term 15 min), topical probiotic

preparation containing *Lactobacillus reuteri Prodentis* [17] (by 1 pastille 2 times a day: 1st pastille after breakfast and hygiene measures, the 2nd pastille before bedtime), and the herbal angioprotective drug based on diosmin and hesperidin [18] (by 1 tablet (1000 mg) once a day, during breakfast for 6 months). This treatment regimen was also used in patients of the comparison group to determine the effectiveness of the proposed TPC of patients with ChCG associated with ChHG without the presence of the risk factor — smoking. The preventive course for this category of patients consisted in taking drugs in the treatment regimen. The patients of the 2nd subgroup (G1.2) received basic therapy of periodontal disease and ultraphonophoresis with placebo. The patients with ChHG received general antihelicobacter therapy prescribed by a gastroenterologist.

To evaluate the state of hemodynamics in the microcirculation system, ultrasound of periodontal circulation was conducted using a portable ultrasound scanner “Sonoscape E3” (Guangdong, China) using an electronic linear multifrequency sensor with a signal frequency of 4–16 MHz, located on the transitory fold of the upper and lower jaw. To obtain a good signal a contact medium — acoustic gel was used. Doppler processing was performed automatically, using a specially built-in program. The Gosling index (Pi) was calculated, which reflects the elastic properties of blood vessels and the index of peripheral circulation resistance distal to the measurement site — the (Pourelot) resistance index (Ri) [19]. For biochemical studies, oral fluid was taken from all patients in the same way: on an empty stomach, after rinsing the mouth with distilled water according to the method of A.P. Levytskyi [20]. The intensity of lipid peroxidation processes was evaluated by the level of malonic dialdehyde (MDA) by Stalna, Garishvili method (1977), using 2-thiobarbituric acid, the principle of the method is based on the stained trimethyl complex formation [21]; diene conjugates (DC) by Stalna method (1977), modified method taking into account the molar extinction coefficient [22]. The state of antioxidant protection was studied by the levels of catalase enzymes activity according to M.A. Korolyuk et al. method (1988), which is based on the ability of hydrogen peroxide to form a stable stained complex with molybdate salts [23] and superoxide dismutase (SOD) by V.A. Kostiuk et al. (1990) method, the principle of the method is based on the quercetin oxidation reaction [24]. Antioxidant-prooxidant index (API) was calculated by the ratio of catalase activity and MDA concentration [25].

Registration of periodontal circulation ultrasound was performed before treatment, in 1, 6 and 18 months after the beginning of treatment. Biochemical markers were evaluated before treatment and during routine examinations of periodontal patients.

The research was conducted in compliance with the basic provisions of the “Rules of ethical principles of scientific medical research with human participation”, approved by the Declaration of Helsinki (1964–2013), ICH GCP (1996) and orders of the Ministry of Health of Ukraine No 690 dated 23.09.2009, No 944 dated 14.12.2009, No 616 dated

03.08.2012, with the voluntary informed consent of the patient both in the near and long-term follow-up.

Statistical processing of research data was performed using software packages Microsoft Excel XP, Statistica 6.0. In the tables, the data are presented as arithmetic mean values (M) and a mean error ($\pm m$). Differences in the data were considered statistically significant by $p < 0.05$.

RESULTS

The study revealed that the indicators of the control group of patients met the standards of previous scientific studies [26; 27]. Indicators of Doppler studies of the main and the comparison group showed changes to the direction of deterioration compared with the control group (Table I, Fig. 1). In smoking patients, the Pi index increases 3.6 times compared with the control group (Fig. 3), and on the other hand, the Ri index decreases 1.7 times, which reflects the low tonus of the vessel walls (see Table I, Fig. 1). In patients of the comparison group who did not have a bad habit — smoking, Pi index and Ri index were higher than normal, which reflects the active course of periodontitis associated with ChHG (see Table I, Fig. 2).

In patients of the comparison group, the levels of MDA by 30.4% and DC by 45.3% significantly increased, which indicates lipid peroxidation processes activation in the oral cavity caused by ChGP compared with the control group. The SOD level increases by 54.6%, which indicates the activation of compensatory mechanisms in response to the lipid peroxidation processes hyperactivation. The level of the antioxidant defense system falls as a result of decrease in enzyme catalase level by 23.7%, which is reflected in a decrease in the AP index level (by 43.2%). One should note that the values of biochemical markers of the oral fluid in the main group were significantly different from those in the comparison group: catalase activity, AP-index values were significantly lower (by 32.6% and 50.9% correspondently), MDA, DC, SOD (38%, 46.2% and 36.7% correspondently) — much higher, which indicates a more pronounced violation of

oral homeostasis associated with effects of damaging factors combination (Table II).

Evaluation of the effect of the proposed TPC immediately after treatment and at the long term revealed a slow but pronounced positive dynamics of the functional characteristics of microcirculation and the condition of the periodontium vascular wall in patients of the comparison group. Pi index and Ri index had almost reached normal levels at the end of treatment, and at the long term had better values than before treatment, which is probably due to the long-term therapeutic effect of the drug based on diosmin and hesperidin during 6 months and TPC course (Table III, Fig. 4).

Ultrasound examination of periodontal microhemocirculation in subgroups G1.1 and G1.2 of the main group in a month after the beginning of treatment revealed a rather slow change to improvement. Changes of values in the subgroup G1.1 immediately after treatment improved insignificantly, however, taking into account a long-lasting irritant — smoking, even such a positive trend supports the proposed TPC (see Table III). In subgroup G1.2, the Pi index remained unchanged immediately after treatment. The resistance Ri index, in its turn, had a rather sluggish improvement compared to the pre-treatment rate (0.466 ± 0.023), which is probably explained by the influence of general treatment prescribed by a gastroenterologist and the absence of venotonic and angioprotective drugs in the treatment regimen (see Table III). Long-term follow-ups in 6 and 18 months in the subgroups of the main group showed clear positive changes (Fig. 5, 6). Pi index in patients of subgroup G1.1 decreased 1.8 and 3.0 times in 6 and 18 months correspondently, compared with pre-treatment data (5.433 ± 0.318). Indicators of Ri index in 6 months increased 1.6 times compared with the values before treatment (0.524 ± 0.019), in 18 months increased up to normal values (see Table III). Positive changes also took place in subgroup G1.2, but very slowly. Stagnation of periodontal vessels took place in 6 months. And only in 18 months in this group Pi index reached the upper and middle values of the norm and Ri index normalized (see Table III).

Table I. The results of ultrasound examination of periodontal tissues microhemocirculation in the study groups before treatment (M \pm m)

Indicators	Control group, n=20	Comparison group, n=22	Main group, n=48
Ri	0.860 \pm 0.021	1.339 \pm 0.092*	0.495 \pm 0.015* \diamond
Pi	1.710 \pm 0.027	3.131 \pm 0.051*	6.097 \pm 0.253* \diamond

Note: * — significantly compared with the control group ($p < 0.05$);

\diamond — significantly compared with the comparison group ($p < 0.05$).

Table II. Biochemical markers of prooxidant-antioxidant system of oral fluid in the study groups before treatment (M \pm m)

Indicators	Control group, n=20	Comparison group, n=22	Main group, n=48
Catalase, μ kat/l	0.173 \pm 0.004	0.132 \pm 0.002*	0.089 \pm 0.001* \diamond
SOD, relative units	0.374 \pm 0.011	0.578 \pm 0.018*	0.790 \pm 0.006* \diamond
MDA, μ mol/l	0.125 \pm 0.004	0.163 \pm 0.002*	0.225 \pm 0.002* \diamond
DC, μ mol/l	6.154 \pm 0.063	8.939 \pm 0.115*	13.069 \pm 0.127* \diamond
AP-index	1.423 \pm 0.073	0.809 \pm 0.006*	0.397 \pm 0.002* \diamond

Note: * — significantly compared with the control group ($p < 0.05$);

\diamond — significantly compared with the comparison group ($p < 0.05$).

Table III. The results of ultrasound examination of the periodontal tissues microhemocirculation in the study groups after treatment and at the long-term follow-up (M±m)

Study groups	Before treatment		In 1 month		In 6 months		In 18 months	
	Ri	Pi	Ri	Pi	Ri	Pi	Ri	Pi
Control group, n=20	0.860±0.021	1.710±0.027						
Comparison group, n=22	1.339±0.092*	3.131±0.051*	0.927±0.027◇	2.233±0.028*◇	0.823±0.021◇	2.046±0.022*◇	0.819±0.010◇	1.670±0.022◇
Subgroup G1.1, n=24	0.524±0.019*	5.433±0.318*	0.745±0.012*◇	4.334±0.279*◇	0.815±0.010◇	3.096±0.166*◇	0.931±0.007*◇	1.821±0.028*◇
Subgroup G1.2, n=24	0.466±0.023*	6.761±0.350*	0.627±0.011*◇	6.314±0.347*	0.668±0.007*◇	5.401±0.299*◇	0.745±0.006*◇	2.662±0.130*◇

Note: * — significantly compared with the control group (p<0.05);

◇ — significantly compared with the indicators before treatment (p<0.05).

Table IV. Dynamics of biochemical markers of prooxidate-antioxidant system of oral fluid in the studied groups during treatment (M±m)

Group of patients	Indicators				
	Catalase, µkat/L	SOD, relative units	MDA, µmol/l	DC, µmol/l	AP-index
Control group, n=20	0.173±0.004	0.374±0.011	0.125±0.004	6.154±0.063	1.423±0.073
Comparison group, n=22					
Before treatment	0.132±0.002*	0.578±0.018*	0.163±0.002*	8.939±0.115*	0.809±0.006*
After the treatment					
In 1 month	0.174±0.002◇	0.412±0.005*◇	0.116±0.002◇	6.325±0.080*◇	1.498±0.022*◇
In 6 months	0.174±0.001◇	0.375±0.007◇	0.122±0.001◇	6.340±0.134◇	1.428±0.014◇
In 12 months	0.173±0.002◇	0.365±0.005◇	0.124±0.001◇	6.600±0.115*◇	1.404±0.022◇
In 18 months	0.170±0.001◇	0.397±0.016◇	0.125±0.002◇	6.455±0.111*◇	1.368±0.019◇
Subgroup G1.1, n=24					
Before treatment	0.088±0.001*	0.782±0.002*	0.223±0.002*	12.848±0.166*	0.395±0.004*
After the treatment					
In 1 month	0.177±0.002◇	0.392±0.005◇	0.128±0.001◇	7.812±0.101*◇	1.396±0.024◇
In 6 months	0.133±0.001*◇	0.554±0.007*◇	0.157±0.002*◇	8.248±0.107*◇	0.851±0.015*◇
In 12 months	0.139±0.001*◇	0.504±0.008*◇	0.161±0.002*◇	8.078±0.105*◇	0.867±0.015*◇
In 18 months	0.143±0.002*◇	0.530±0.007*◇	0.168±0.002*◇	7.906±0.103*◇	0.855±0.015*◇
Subgroup G1.2, n=24					
Before treatment	0.091±0.001*	0.798±0.008*	0.227±0.003*	13.289±0.185*	0.400±0.003*
After the treatment					
In 1 month	0.147±0.002*◇	0.474±0.005*◇	0.149±0.002*◇	9.701±0.135*◇	0.981±0.009*◇
In 6 months	0.120±0.002*◇	0.415±0.004◇	0.183±0.002*◇	10.207±0.142*◇	0.658±0.006*◇
In 12 month	0.124±0.002*◇	0.396±0.004◇	0.177±0.002*◇	9.924±0.138*◇	0.704±0.007*◇
In 18 months	0.128±0.002*◇	0.414±0.004◇	0.170±0.002*◇	10.079±0.140*◇	0.757±0.007*◇

Note: * — significantly compared with the control group (p<0.05);

◇ — significantly compared with the indicators before treatment (p<0.05).

Evaluation of the prooxidate-antioxidant system markers level in patients who received the proposed TPC during treatment, revealed positive dynamics. The best results were revealed in the patients of the comparison group, in which all the indicators of lipid peroxidation - antioxidant system were practically at the level of the indicators of the control group during the whole course of observations except for the SOD enzyme activity, which at the end of treatment had a slight increase (0.412±0.005 relative units) compared with the control group (0.374±0.011 relative units). This significant positive dynamics of lipid peroxidation - antioxidant system can be explained by the lack of

negative effects of smoking in these patients during treatment and the effectiveness of the therapy (Table IV).

As for dynamics of the prooxidate-antioxidant system in patients-smokers of subgroup G1.1, who also received the proposed TPC during treatment, there was a slightly worse positive dynamics compared with patients in the comparison group. In these patients, the lipid peroxidation - antioxidant system values reached the level of the control group only immediately after treatment, except for DC (7.812±0.101 µmol/l), which remained elevated compared to the corresponding value of the control group (6.154±0.063 µmol/l).

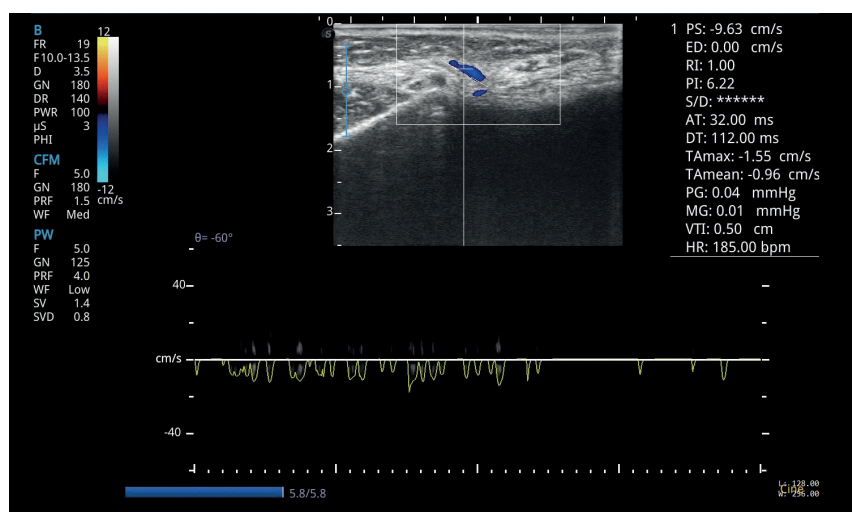


Fig. 1. Periodontal tissues Doppler of patient B. of the main group, before treatment

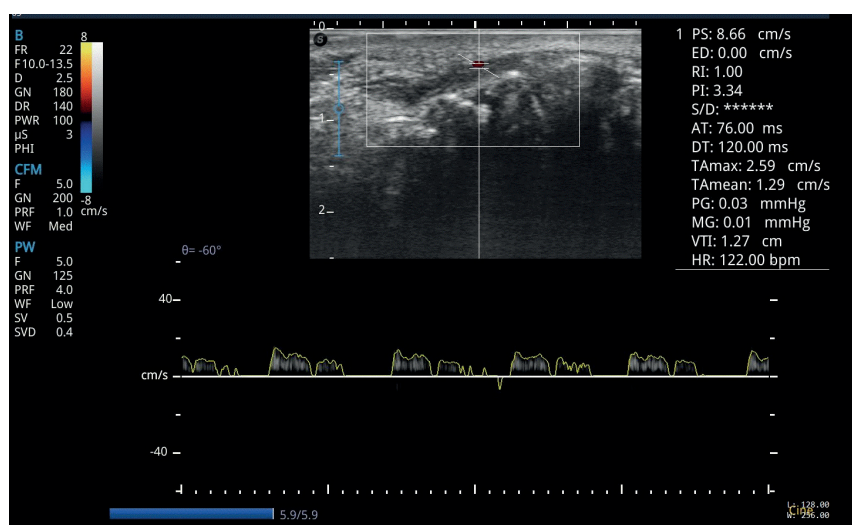


Fig. 2. Periodontal tissues Doppler of patient S. of the comparison group, before treatment

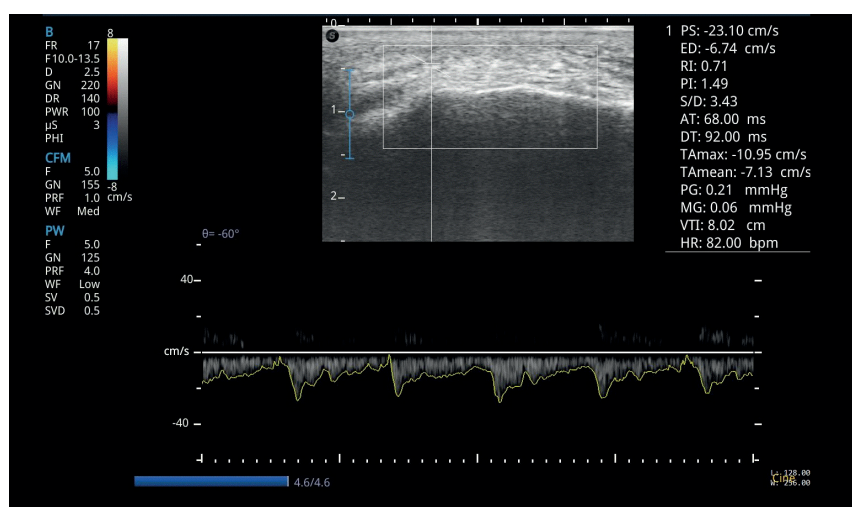


Fig. 3. Periodontal tissues Doppler of patient P. of the control group

During 6 and 18 months, the values gradually deteriorated, but insignificantly compared with those of this group before treatment (see Table IV). The data obtained prove that the use of the proposed TPC had a positive effect on the state of free radical processes of periodontal tissues at different follow up terms, even in the presence of risk factors — smoking and somatic pathology.

Indicators of the state of free radical processes of periodontal tissues in patients of subgroup G1.2, who were treated with ChGP basic therapy and ultraphonophoresis with placebo, had a slight positive effect throughout the observation period, but none of the indicators reached the control group, except for SOD activity, beginning from the 6th month of follow up (see Table IV). So, the selected treatment regimen was insufficient

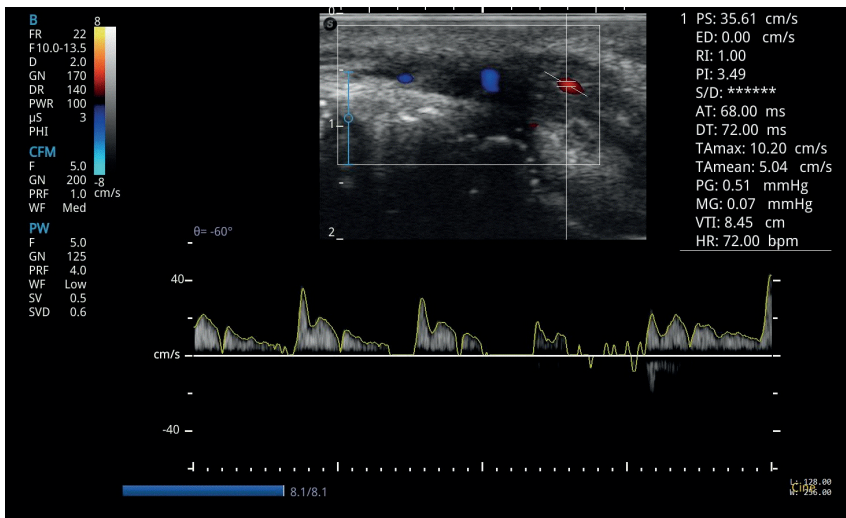


Fig. 4. Doppler of the patient S. of the comparison group, in 6 months from the beginning of treatment

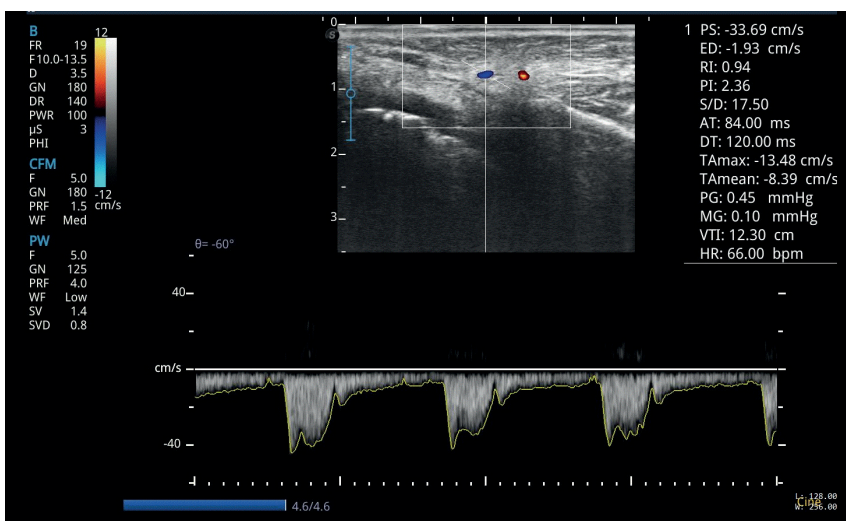


Fig. 5. Doppler of patient B. the subgroup G. 1.1 of the main group, 6 months after the beginning of treatment

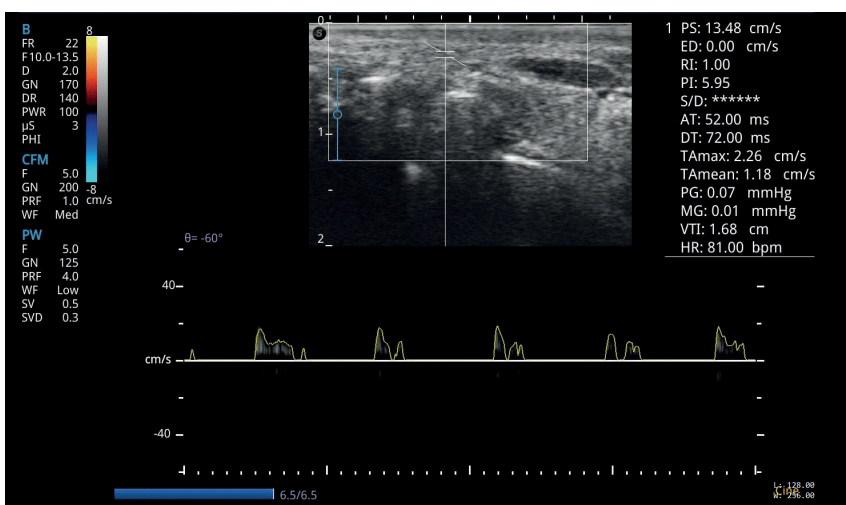


Fig. 6. Doppler of the patient O. subgroup G. 1.2 of the main group, in 6 months after the beginning of treatment

for the treatment and prevention of periodontal disease in this category of patients.

DISCUSSION

Based on the data of our study, we can say that more severe changes in the state of microcirculation and free radical pro-

cesses of periodontal tissues are observed in patients of the main group caused by the comorbid pathology course (chronic generalized periodontitis, chronic hyperacid gastritis associated with *Helicobacter pylori* and smoking addiction during 5–7 years), which worsened the pathological process in the periodontium, which was reflected in the violation of the elastic properties of blood vessels, peripheral circulation resistance and balance of

lipid peroxidation — antioxidant system: decreased catalase activity, increased concentrations of malonic dialdehyde, diene conjugates, superoxide dismutase [11-13]. So, the presence of comorbidity of pathological conditions of periodontal and gastrointestinal tissues associated with the risk factor — smoking creates conditions for the deterioration of tissues trophy and, as a result, the growth of free radical oxidation [11].

The obtained results of our study proved effectiveness of the proposed TPC (ultraphonophoresis procedure with the developed gel based on bee products and other biologically active substances [16], topical probiotic drug containing *Lactobacillus reuteri Prodentis* [17], and angioprotective drug based on diosmin and hesperidin [18]) in smoking patients with ChGP of the initial, I degree associated with acid-dependent diseases of the stomach — ChHG associated with *Helicobacter pylori*. The proposed TPC showed pronounced venotonic, angioprotective effects, microcirculatory activity, which increases venous tone, improves tissue trophy, as well as antioxidant properties due to its components and provided a stable long term remission.

The dynamics of microcirculation and free radical processes of periodontal tissues in smoking dependent patients with ChGP of the initial-I, I stage associated with ChHG associated with *Helicobacter pylori*, who underwent therapeutic measures using the proposed TPC, indicates a higher efficiency of this complex compared with those who received ultraphonophoresis with placebo, both at the near and long-term follow-up. On the other hand, the use of the proposed TPC in patients with relevant comorbid pathology, but without the bad habit, showed better results compared with smoking patients, due to the lack of harmful effects of smoking.

The results of the study allow the introduction of the proposed TPC into the dental practice as an effective method of treatment and prevention of periodontal disease in ChGP associated with chronic gastrointestinal diseases and risk factors — smoking, aimed at improving homeostasis, antioxidant protection and microcirculation of the oral tissues.

CONCLUSIONS

So, the study proves that the use of the proposed TPC had a positive effect on the state of microcirculation and free radical processes of periodontal tissues both at the short and long term follow up, even under conditions of chronic gastritis associated with *Helicobacter pylori*, with increased secretory function and with the factor risk — smoking.

REFERENCES

1. Dzampaieva Zh.V. Osobnosti etiologii i patogenezna vospalitel'nykh zabolovaniy parodonta [Features of the etiology and pathogenesis of inflammatory periodontal diseases]. Kubanskiy nauchnyy meditsinskiy vestnik. 2017; 5: 103-110. (In Russian).
2. Tsepov L.M., Nikolaev A.I., Nesterova M.M. et al. Patogeneticheskie osobnosti formirovaniya khronicheskoy vospalitel'noy patologii parodonta (obzor) [Pathogenetic features of the formation of chronic inflammatory periodontal pathology (review)]. Vestnik Smolenskoys gosudarstvennoy meditsinskoy akademii. 2018;17(3):206-214. (In Russian).

3. Duryagina L.Kh., Kolesnik V.M., Degtyareva L.A. et al. Nekotory`e aspekty` techeniya zabolovaniy parodonta i slizistoy obolochki polosti rta pri sochetanii s somaticheskoy patologiej: obzor literatury` [Some aspects of the course of periodontal and oral mucosa diseases in combination with somatic pathology: a literature review]. Kry`mskij terapevricheskij zhurnal. 2020;(1):43-48. (In Russian).
4. Savielieva N.M., Sokolova I.I., Herman S.I., Tomilina T.V. Deiaki aspekty etiologii zakhvoriuvan parodonta (ohliad literatury) [Some aspects of the etiology of periodontal disease (literature review)]. Ukrainskiy stomatolohichniy almanakh. 2018;(2):54-59. (In Ukrainian).
5. Ilchshyn M.P., Furdychko A.I., Barylyak A.Ya. Poshyrenist zakhvoriuvan parodontu sered tyutyunozaleznykh osib [Prevalence of periodontal diseases among tobacco addicts]. Novyny stomatolohiyi. 2018; 4 (97): 86-88. (In Ukrainian).
6. Shcherba V.V., Lavrin O.Ia. Tiutunokurinnia: rozpovsiudzenist ta vplyv na orhany i tkanyny porozhnyy rota (ohliad literatury) [Smoking: prevalence and effects on oral organs and tissues (literature review)]. Klinichna stomatolohiia. 2016;(2):27-33. (In Ukrainian).
7. Mishra R. Smoking and Periodontal Disease. Review. Acta Scientific Dental Sciences. 2019; 3(11): 114-116.
8. Kaur M., Kumar K. Effect of cigarette smoking on periodontal health. International J of Dentistry Research. 2017; 2(3): 86-88.
9. Bohatu S.Y. Kliniko-laboratorne obgruntuvannia likuvannia khronichnoho kataralnoho hinhivitu u patsientiv na tli antykhelikobakternoi terapii [Clinical and laboratory substantiation of treatment of chronic catarrhal gingivitis in patients on the background of antihelicobacter therapy] [dysertatsiia]. Odesa. 2019, 261 p. (In Ukrainian).
10. Yee J.K.C. Helicobacter pylori colonization of the oral cavity: A milestone discovery. World J Gastroenterol. 2016;22(2): 641-648.
11. Golub`A.A., Chemikosova T.S., Gulyaeva O.A. Vliyanie kureniya i nalichiya somaticheskoy patologii na sostoyanie slizistoy obolochki polosti rta [The effect of smoking and the presence of somatic pathology on the condition of the oral mucosa]. Parodontologiya. 2011; 16 (3): 66-69. (In Russian).
12. Kochieva I.V., Mkrtychyan S.N., Khetagurov S.K. Vliyanie tabakokurennya na mikrotsirkulyatsiyu v tkanyakh paradonta [The effect of tobacco smoking on microcirculation in periodontal tissues]. Mediko-farmatsevticheskiy zhurnal "Puls". 2015; 17 (1): 57-58. (In Russian).
13. Gard N., Singh R., Dixit J. Levels of lipid peroxides and antioxidants in smokers and nonsmokers. J. Periodont. Research. 2006; 41(5): 405-410.
14. Bogachev V.Yu., Golovanova O.V., Kuznecov A.N., Shekoyan A.O. Bioflavonoidy` i ikh znachenie v angiologii. Fokus na diosmin [Bioflavonoids and their importance in angiology. Focus on diosmin]. Angiologiya i sosudistaya khirurgiya. 2013;19(1):73-81. (In Russian).
15. Danilevskiy N.F., Borisenko A.V. Zabolovaniya parodonta [Periodontal Disease]. Kyiv: Zdorov`ya. 2000, 462 p. (In Russian).
16. Kravchenko L.S. Vynakhidnyk; Odeskiy natsionalnyy medychnyy universytet, patentovlasnyk. Gel "Apisan" dlya mistsevoho likuvannya ta profilaktyky travmatychnykh urazhen slyzovoi obolonky porozhnyy rota. Patent Ukrainy No 119715. 2017 zhovt. 10 (In Ukrainian).
17. Trubka I.O., Savychuk N.O., Tsyhanko I.R. Obgruntuvannia vykorystannia probiotyka, yakyy mistyt shtamy Lactobacillus reuteri DSM 17938 ta ATCC PTA 5289, u ditei iz khronichnym heneralizovannym kataralnym hinhivitom [Rationale for the use of a probiotic containing Lactobacillus reuteri strains DSM 17938 and ATCC PTA 5289 in children with chronic generalized catarrhal gingivitis]. Sovremennaia pedyatrya. 2018;(3):119-125. (In Ukrainian).
18. Mikhailov A.E. Kompleksnoe lechenie khronicheskogo generalizovannogo parodontita s ispol'zovaniem periarterial'noy kriosimpatodestruktsii luchevoyy arterii [Complex treatment of chronic generalized periodontitis using periarterial cryosympathodestruction of the radial artery]: avtoref. diss. k. med. nauk. Perm'. 2008, 12 p. (In Russian).

19. Krechina E.K., Rakhimova E.N., Girina M.B. Primenenie metoda ul'trazvukovoy dopplerografii dlya otsenki tkanevogo krovotoka pri vospalitel'nykh zabolevaniyakh parodonta [Application of the Doppler ultrasound method to assess tissue blood flow in inflammatory periodontal diseases]. Posobie dlya vrachey. Moskva. 2005, 14p. (In Russian).
20. Kosenko K.N., Romanova Iu.G., Dvulit I.P. Lechebno-profilakticheskie zubnye eliksiry. Ucheb. posobie Odessa: KP OGT. 2010, 246p. (In Russian).
21. Stalnaya I.D., Garishvili T.G. Metod opredeleniya malonovogo dialdegida s pomoshchyu tiobarbiturovoy kisloty [The method of detection of malonic dialdehyde with thiobarbituric acid]. Moscow, Meditsina. 1977, 68p. (In Russian).
22. Stalnaya I.D. Metod opredeleniya dienovoy konyugatsii nenasyshchennykh zhyrnykh kislot [Method for determination of diene conjugation of unsaturated fatty acids]. Sovremennyye metody v biokhimi. Moscow, Meditsina. 1977, 64p. (In Russian).
23. Korolyuk M.A., Ivanova D.I., Mayorova I.G. Metod opredeleniya aktivnosti katalazy [Method of determination of catalase activity]. Laboratornoe delo. 1988; 1: 16-18. (In Russian).
24. Kostyuk V.A., Popovich A.I. Prostoy i chuvstvitel'nyy metod opredeleniya aktivnosti superoksiddismutazy, osnovannyi na reaktsii okisleniya kvartsetina [A simple and sensitive method for determining the activity of superoxide dismutase based on the oxidation reaction of quercetin]. Voprosy meditsinskoy khimii. 1990; 2: 88-91. (In Russian).
25. Levitskiy A.P., Denga O.V., Makarenko O.A. et al. Biokhimicheskie markery vospaleniya tkaney rotovoy polosti: metodicheskie rekomendatsii [Biochemical markers of inflammation of oral cavity tissue: method guidelines]. Odessa, KP OGT. 2010, 16 p. (In Russian).
26. Kovach I.V., Makarenko M.V. Dinamika pokaznykiv krovotoku v tkanynakh parodontu pislya zastosuvannya ozonoterapiyi u osib molodogo viku [Dynamics of blood flow parameters in periodontal tissues after the use of ozone therapy in young people]. Sovremennaya stomatologiya. 2014; 4: 30-34. (In Ukrainian).
27. Kozlov V.A., Artyushenko N.K., Shalak O.V. Ul'trazvukovaya doplerografiya v otsenke hemodynamiky v tkanynakh shei, litsa i polosti rta v norme i pri nekotorykh patologicheskikh sostoyaniyakh [Doppler ultrasound in the assessment of hemodynamics in the tissues of the neck, face and mouth in norm and in some pathological conditions]. Spb. 2000, 32 p. (In Russian).

ORCID and contributionship:

Iuliia G. Romanova: 0000-0001-8578-2520^{A,E,F}
 Olena L. Zolotukhina: 0000-0001-5828-4884^{A,C,E}
 Georgy O. Romanov: 0000-0001-8334-1211^{B,C}
 Stanislav A. Shnaider: 0000-0001-8857-5826^{E,F}
 Iryna M. Tkachenko 0000-0001-8243-8644^{E,F}

Conflict of interest:

The Authors declare no conflict of interest.

CORRESPONDING AUTHOR**Olena L. Zolotukhina**

The Odessa National Medical University
 2 Valikhovsky st., 65082 Odesa, Ukraine
 tel: +380938518369
 e-mail: alenazoloto2@gmail.com

Received: 01.02.2021

Accepted: 28.08.2021

A - Work concept and design, B - Data collection and analysis, C - Responsibility for statistical analysis,
 D - Writing the article, E - Critical review, F - Final approval of the article



Article published on-line and available in open access are published under Creative Common Attribution-Non Commercial-No Derivatives 4.0 International (CC BY-NC-ND 4.0)