



Detection of Optic Disc and Hard Exudates using TWIN PLANE Gradient Windowing Technique

By G. Ferdic Mashak Ponnaiah & Capt. Dr. S. Santhosh Baboo

Bharathiar University, India

Abstract - Detection of Optic disc (OD) in a fundus image is a foremost important step in the process of screening the diabetic retinopathy [1,4,18]. Hard Exudates detection algorithms usually find lot of false positives since the intensity and color distribution of OD will much resemble that of a Hard Exudates region [15,16]. So, most of the Exudates detection algorithms will miss classify the pixels at the OD region as Hard Exudates [2].

In our previous works, we used Genetic Algorithm(GA)[23,24] to find the OD location and size and reduced overall time, even doing the search on the entire problem space and also removed false hard exudates. In this work we are improving Hard Exudates detection accuracy using gradient index mapping technique applied on two similar planes of the RGB. The new algorithm is termed as TWINGRAB use the two planes of the RGB after proper gradient projection. The database used for this preprocessing is DIARETDB1[10].

Index terms: *diabetic retinopathy, hard exudates, optic disc detection.*

GJCST-F Classification : *B.3.2*



DETECTION OF OPTIC DISC AND HARD EXUDATES USING TWIN PLANE GRADIENT WINDOWING TECHNIQUE

Strictly as per the compliance and regulations of:



RESEARCH | DIVERSITY | ETHICS

Detection of Optic Disc and Hard Exudates using TWIN PLANE Gradient Windowing Technique

G. Ferdic Mashak Ponnaiah ^α & Capt. Dr. S. Santhosh Baboo ^σ

Abstract- Detection of Optic disc (OD) in a fundus image is a foremost important step in the process of screening the diabetic retinopathy [1,4,18]. Hard Exudates detection algorithms usually find lot of false positives since the intensity and color distribution of OD will much resemble that of a Hard Exudates region [15,16]. So, most of the Exudates detection algorithms will miss classify the pixels at the OD region as Hard Exudates [2].

In our previous works, we used Genetic Algorithm(GA)[23,24] to find the OD location and size and reduced overall time, even doing the search on the entire problem space and also removed false hard exudates. In this work we are improving Hard Exudates detection accuracy using gradient index mapping technique applied on two similar planes of the RGB. The new algorithm is termed as TWINGRAB use the two planes of the RGB after proper gradient projection. The database used for this preprocessing is DIARETDB1[10].

Index terms: diabetic retinopathy, hard exudates, optic disc detection.

I. INTRODUCTION

Detecting hard exudates is a challenging process; hence there is research gap in fine tuning the process by introducing hybrid algorithms in finding the exudates which is a significant milestone to identify the diabetic retinopathy. The primary goal to achieve is a proper detection of Optic Disc which got similar pixel intensity and gradient like hard exudates. In the previous work based on the threshold value we have considered either the green plane or blue plane to detect the Optic Disc based on the colour intensity. In these work two similar planes of RGB plane is used to detect the feature candidates. A new algorithm called TWINGRAWB (TWIN PLANE INTENSITY GRADIENT WINDOWING BOUNDARY TECHNIQUE) is applied on two similar planes to find the Optic Disc and Hard Exudates.

Author α: Research Scholar, Dept of Computer Science and Engineering, Bharathiar, University, Coimbatore, India. e-mail: gfm08@gmail.com

Author σ: Associate Professor, PG & Research Center Dept of Computer Science, D.G. Vaishnav College, Arumpakkam, Chennai, India. e-mail: santhos2001@sify.com

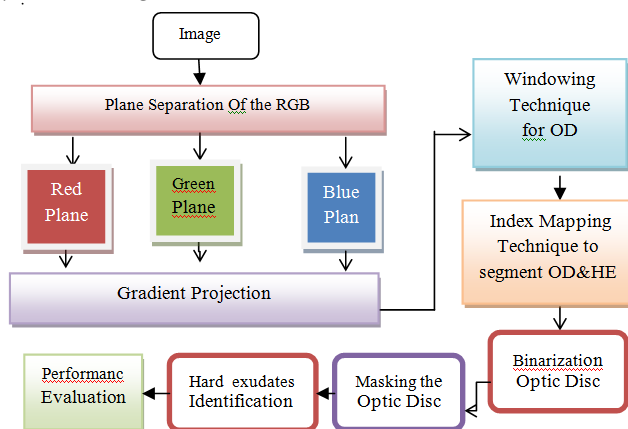
II. FUTURE METHOD

a) TWINGRAB Algorithm

The steps involved in the proposed method is as follows:

Step1. Input the Red, Green and Blue plane.
Step2. Enhance the gradient of each plane.
Step3. Compare the two similar planes showing the optic disc location.
Step4. Identify the optic disc using pixel gradient and Index mapping to detect the hard exudates.
Step5. Find the optic disc boundary using binarization technique.
Step6. Mask the Optic Disk region since the hard exudates also have the same pixel.
Step7. After masking the Optic Disk Identify the feature hard exudate candidates.

b) Flow Diagram



c) Gradient Projection & Windowing Technique

The gradient is a generalization of the usual concept of derivation to find the function of many variables. Consider the function $f(x_1, \dots, x_n)$ which is a differentiate function of several variables called scalar field. The gradient of the scalar field is the vector of the n partial derivate of the function f . By this a vector value function is termed as vector field.

The function of the graph is represented by the slope of and the tangent of the image. More exactly, the gradient points in the direction of the greatest rate of increase of the function and the slope of the graph is the

magnitude in that direction. The tangent space equation of the graph is the non-constant coefficient of the component of the graph.

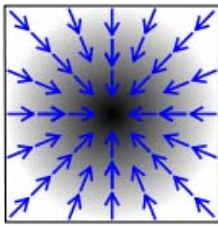


Figure 1




Figure 2

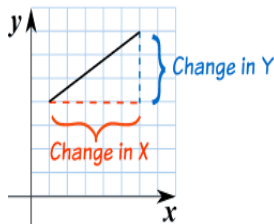
In the above Figure.1 and Figure.2, the values of the function are represented in black and white, black representing higher values, and its corresponding gradient is represented by blue arrows.

Consider a surface whose height above sea level at a point (x, y) is H(x, y). The gradient of H at a point is a vector pointing in the direction of the steepest grade or slope at that point. The steepness of the slope at that point is given by the magnitude of the gradient vector. The gradient may also be used to measure how a scalar field changes in other directions, than just the direction of greatest change, by making a dot product.

The gradient is a vector operator denoted by ∇. It is more often applied to a real function of three variables and may be denoted as,

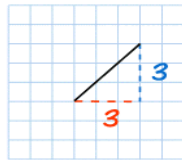
$$\nabla f = \text{grad}(f)$$

The method to calculate the Gradient is: Divide the change in height by the change in horizontal distance. It is denoted as,



Gradient = Change in vertical axis(Y) / Change in horizontal axis(X)

For example,



The gradient for this line = 3/3 = 1. So the gradient is equal to 1.

Gradient can be applied to the histogram equalized image. After equalization of the image, the gradient of the image is to be found to analyze the image edge strengths. In general gradient of the image returns gradient values with respect to both axis Gx and Gy respectively.

The final magnitude of the gradient is obtained by,

$$|G| = |G_x| + |G_y|$$

Gradient for each plane as shown in Figure.3, Figure.4 and Figure.5 is obtained with the help of above algorithm in which magnitude and direction can be calculated to identify edge strength.

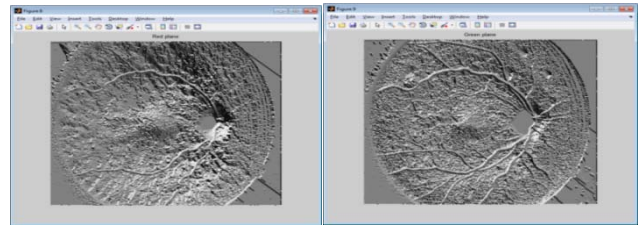


Figure 3 : Red Plane

Figure 4 : Green Plane

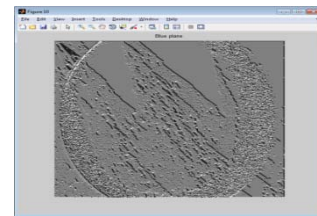


Figure 5 : Blue Plane

d) Advantage Of Twin Plane

The above gradient output image of blue plane shows no sign of Optic disk and Hard exudates when compare with the Red plane and Green plane. The Red plane and Green plane shows the feature extraction candidates clearly and considered as twin plane for the detection of Optic disk and Hard exudates. The twin plane technology helps to confirm the area of segmentation as there are more than one plane shows the same area of feature candidates for segmentation and provides a strong base for the further detection of true positive hard exudates.

e) Index Mapping Technique

The index mapping is a kind of technique to manage the digital images colors in a limited fashion, in order to save computer resource such as memory and storage of files when doing certain operations such as speeding up display refresh and file transfers. This is a kind of vector quantization compression.

Index mapping technique is used in which depends on pixel value arrangement index value to be assigned. The color index is a simple numerical expression that determines the color of an object, Index maps are a type of seeking tool that allow users find a set of maps covering their regions of interest along with the name or number of the relevant map sheet. In this segmentation for each index value, color to be assigned according to the value assigned for individual color.

It is limited to 256 colors, which can be any 256 from the set of 16.7 million 24 bit colors. Each color used is a 24 bit RGB value. Each such image file contains its own color palette, which is a list of the selected 256 colors (or 16 colors in a smaller palette). Images are called indexed color because the actual

image color data for each pixel is the index into this palette as color space. When an image is processed in this way, color information is not directly carried by the image pixel data, but is stored in a separate piece of data called palette array of color elements, in which every element, a color, is indexed by its position within the array. The image pixels do not contain the full specification of its color, but only its index in the palette. It also is done in two methods:

1. *Dithering* - Dithering means representing a color by combinations of dots of other colors. Dots is pretty much the definition. If the one exact shade of pink is not in the palette, then dots of other palette colors are mixed to simulate the color. Dithering often causes a visible and objectionable dotted or speckled image. But that simulated color may be much closer than a nearest color approximation.
2. *Nearest color* - This selection is the same as disabling dithering, or no dots. If the exact shade of pink is not in the palette, then the closest color in the palette is used, which might not be very pink at all. Sometimes exact color is not important. No dithering means no visible dots.

Indexation of images is a way of compressing the image without any data loss. Indexing an image will keep the resolution and color space intact, but the structure of the image will change. When an image is indexed an index table will be created. This is a list of the different colors that are used. The image itself will contain reference numbers to this index table as shown in fig 6. Especially when the image uses a lot the same colors, this can save a lot of space. Indexing an image won't change the way an image looks or will be printed. Each pixel will keep its original color.

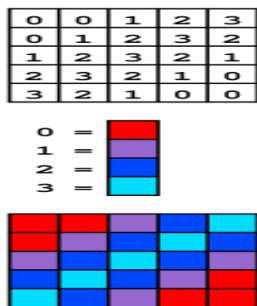


Figure 6 : color Index mapping

The above example represents the index mapping technique carried out for each image. Depends on the pixel value index value like 0,1, 2, 3 are to be assigned for each segmentation as shown in Figure.6. If an image uses a lot of different colors, indexing this image will not make decrease the file size. In this case the image will not be indexed.

f) *Binarization*

Binarization is used for segmentation process in which required portion can be separated from the object. Here threshold value to be fixed for the image in

which value below the threshold level then it will be assigned to binary '0' and above threshold level assigned to binary '1'. Depends on this process, image to be segmented in which optical disk portion can be detected from the iris image. This process is to be performed on the index mapped image from which threshold value to be labeled to corresponding pixel value in the image. Based on labeled pixel each are grouped to segment an image as shown in Figure.7. The output of the binarization fundus image is shown below in Figure.8 and the detection of Optic Disc is shown in Figure.9.

g) *Hard Exudates Detection*

Masking is the process of removing unwanted portion from an image. In this process, threshold value to be assigned for an image for removal of unwanted portion in the iris image in which masking is applied. It can do so by taking the minimum and maximum value in the image in which average one as taken as threshold value for segmentation. This masking method masks the image contains the value below threshold level and hard exudates are recovered from the image as shown in Figure.10.

Screen Shorts of The Output Image

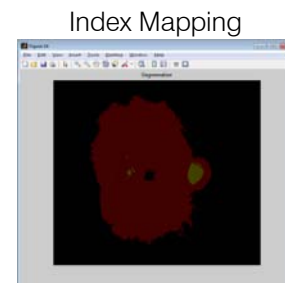

Figure 7

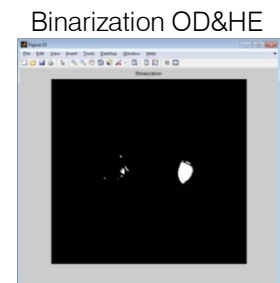


Figure 8

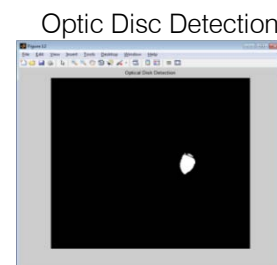


Figure 9

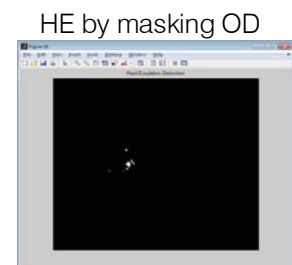
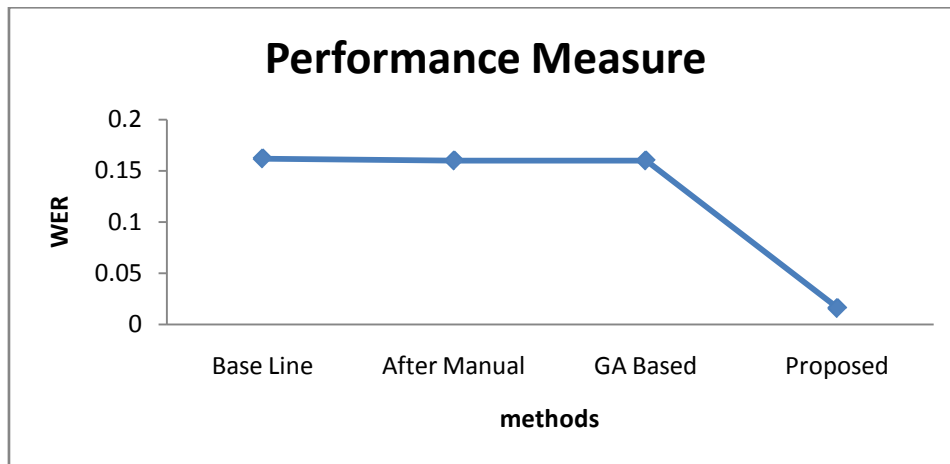
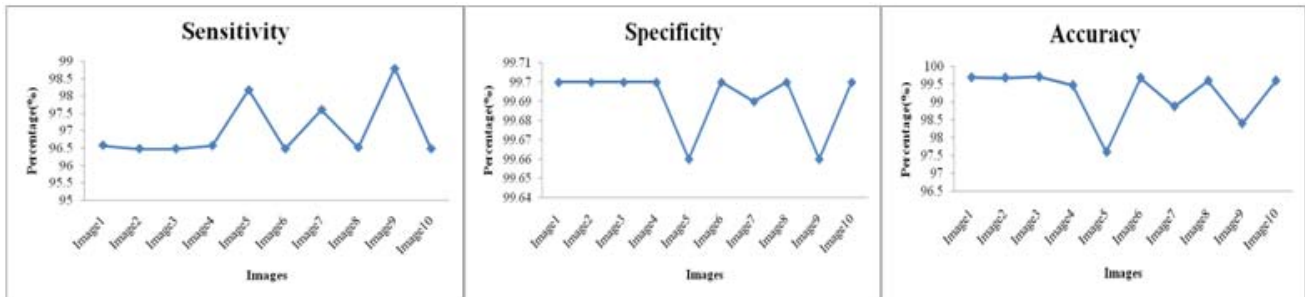


Figure 10

III. RESULT AND ANALYSIS

Images	TP	TN	FP	FN	Sensitivity(%)	Specificity(%)	Accuracy(%)
Image 1	1223	259404	781	43	96.58	99.69	99.69
Image 2	1223	259380	780	44	96.48	99.28	99.68
Image 3	1224	259466	781	45	96.48	99.73	99.71
Image 4	1221	258842	780	43	96.57	99.64	99.47
Image 5	1198	253962	870	22	98.18	99.66	97.6
Image 6	1224	259390	781	45	96.48	99.82	99.68
Image 7	1214	257307	807	30	97.61	99.69	98.88
Image 8	1223	259168	780	44	96.52	99.42	99.6
Image 9	1208	256048	867	15	98.8	99.66	98.4
Image10	1223	259181	780	45	96.48	99.55	99.6



performance	specificity	sensitivity	WER
Base line	0.927	0.75	0.162
manual	0.78	0.9	0.160
GA Based	0.78	0.9	0.160
Proposed	0.997	0.965	0.016

IV. CONCLUSION

The TWINGRAB algorithm is simple and efficient method to detect the Optic Disc and Hard exudates in the fundus image. A proper detection of Optic Disc and

Hard Exudates will help in the diagnosis of the DIABETIC RETINOPATHY eye disease in the fundus image of the eye retina which is the main cause of the vision loss in the diabetic society. This TWINGRAB algorithm may used as a diagnostic tool where the large volume of the patients to be screened and thus reduce the pain of the eye examiners in the eye hospital and eventually useful in generating accurate results of the patients and lead to proper treatment to prevent the vision loss of the diabetic eye. The Weighted Error Rate (WER) of the proposed TWINGRAB is low compare with the baseline, manual and GA based method. This can be used in health care service to prevent the vision loss by early detecting the diabetic retinopathy. Similarly this can be further enhanced to detect various symptoms in the eye fundus image.

REFERENCES RÉFÉRENCES REFERENCIAS

1. TomiKauppi, HeikkiKälviäinen, "Simple and Robust Optic Disc Localisation Using ColourDecorrelated Templates", Advanced Concepts for Intelligent Vision Systems, 10th International Conference, ACIVS 2008, Juan-les-Pins, France, October 20-24, 2008.
2. C.Jayakumari and T.Santhanam, "Detection of Hard Exudates for Diabetic Retinopathy Using contextual Clustering and Fuzzy Art Neural Network", Asian Journal of Information technology, Vol.6,No8,pp.842-846,2007.
3. C.Jayakumari and T.Santhanam,"An intelligent approach to detect hard and soft exudates using echo state neural etwork", Information Technology Journal 2008.
4. Analysis of retinal fundus images for grading of diabeticretinopathy severity M. H. Ahmad Fadzil• Lila Iznitalzhar•HermawanNugroho• Hanung Adi Nugroh.
5. Color Image Segmentation: A State-of-the-Art Survey L. Luccheseysz and S.K. MitrayDept. of Electrical and Computer Eng., University of California, Santa arbarazDept. Of Electronics and Informatics, University of Padua, Italy.
6. A Comparative Evaluation of Preprocessing Methods for Automatic Detectionof Retinal Anatomy Aliaa A. A. Youssif, Atef Z. Ghalwash, and Amr S. Ghoneim.
7. Removal of High Density Salt and Pepper noise Through Modified Decision Base Unsymmetric Trimmed Median Filter S. Esakkirajan, T. Veerakumar, Adabala N. Subramanyam, and C. H. PremChand.
8. Automatic detection of hard and soft exudates in fundus images using color histogram thresholding. S.kavitha, K.Duraisamy, European Journal of scientific research.
9. Automatic Exudates detection in diabetic retinopathy images using digital image processing algorithm. P.Aravindhan, P.N.Jebaranisargunar, proceedings on information science and applications ICISA 2010, Chennai, India.
10. "DIARETDB1 - Standard Diabetic Retinopathy Database Calibration level 1.
11. AkaraSopharak, BunyaritUyyanonvara, Sarah Barman, "Automatic Exudate Detection from Non-dilated Diabetic Retinopathy Retinal Images Using Fuzzy C-means Clustering", Journal of Sensors, Vol.9, No.3, pp.2148-2161, 2009.
12. Gonzalez .R and R.Woods 1993 Digital Image Processing, Addison - Wesley press.
13. MadhuriA.Joshi, Digital Image Processing, An algorithmic Approach.
14. The eye basic sciences in practice. SaunderLtd 2nd edition, 2001.
15. National Eye Institute, National Institute of Health.
16. Dr.lee Kai Yuen(private practice) Tsang CY Luke, Lam Hon Man,et.al. (Family Medicine Service, Department of Health, HKSAR).
17. DiabeticRetinopathy(online).CurrentCareGuideline. Working group setup by the medical society.
18. Wikipedia.Eyewikipedia,thefreeencyclopedia.Electro nicmaterial(Online).
19. C. Sinthanayothin, J. F. Boyce, H. L. Cook, and T. H.Williamson, "Automated localisation of the optic disk, fovea, and retinal blood vessels from digital colour fundus images," Br. J. Ophthalmol., vol. 83, no. 8, pp. 902–910, 1999.
20. T. Teng, M. Lefley, and D. Claremont, "Progress towards automated diabetic ocular screening: A review of image analysis and intelligent systems for diabetic retinopathy," Med. Biol. Eng. Comput., vol. 40, pp. 2–13, 2002.
21. L. Gagnon, M. Lalonde, M. Beaulieu, and M.C.Boucher, "Procedure to detect anatomical structures in optical fundus images," in Proc. Conf. Med. Imag. 2001: Image Process., San Diego, CA, Feb. 19–22, 2001, pp. 1218–1225.
22. H. Li and O. Chutatape, "Automatic location of optic disc in retinal images," in IEEE Int. Conf. Image Process., Oct. 7–10, 2001, vol. 2, pp. 837–840.
23. Automatic optic disk detection and removal of false exudates for improving retinopathy classification. G.Ferdic Mashak Ponnaiah, Capt, Dr.Santhosh Baboo.
24. GA based automatic optic disc detection in fundus image using the blue channel and green channel information G.Ferdic Mashak Ponnaiah, Capt.Dr.Santhosh Baboo.

This page is intentionally left blank

