

# Peritoneal Catheter Removal for Peritoneal Dialysis-Related Peritonitis Caused by Gram-Negative, Rod-Like *Pseudomonas aeruginosa* Infection During Antibiotic Therapy for *Enterococcus faecalis*

Kohsuke Terada, Yuichiro Sumi, Sae Aratani,  
Akio Hirama and Yukinao Sakai

Department of Nephrology, Graduate School of Medicine, Nippon Medical School, Tokyo, Japan

Peritonitis is a common complication of peritoneal dialysis (PD) and can result in PD catheter removal, permanent hemodialysis, and, potentially, death. Prediction and prevention of PD-related peritonitis are thus extremely important. In 2016, the International Society for Peritoneal Dialysis published guidelines for patients with peritonitis undergoing PD. The guidelines cover most cases of PD-related peritonitis caused by bacteria and include clear indications for catheter removal. However, difficulties often arise when deciding the timing of catheter removal. When multiple enteric organisms are identified in a culture of dialysis effluent, peritonitis may be caused by intra-abdominal pathology, which is associated with substantial mortality. In such cases, catheter removal is considered. In this report, we describe a case in which, during antibiotic therapy for PD-related peritonitis due to *Enterococcus faecalis* alone, the patient developed a relapse of peritonitis caused by a newly detected Gram-negative, rod-like *Pseudomonas aeruginosa*. He required catheter removal because of the possibility of peritonitis recurrence. Although additional study is required, early catheter removal may be effective when a new organism is detected during antibiotic therapy for PD-related peritonitis caused by an organism not meeting the definition of refractory peritonitis. (J Nippon Med Sch 2020; 87: 304–308)

**Key words:** PD-related peritonitis, recurrent, relapsing, multiple organisms, endogenous peritonitis

## Introduction

Peritonitis is a common complication of peritoneal dialysis (PD) and can result in PD catheter removal, permanent hemodialysis, and death<sup>1–3</sup>. In 2016, the International Society for Peritoneal Dialysis published guidelines for peritonitis patients undergoing PD—the ISPD Peritonitis Recommendations: 2016 Update on Prevention and Treatment<sup>1</sup>. Identification of the causative organism is important for PD-related peritonitis because the treatment protocol and prognosis for PD-related peritonitis usually depend on the organism responsible. Therefore, the guidelines detail management of various causative organisms and encompass most cases of PD-related peritonitis<sup>1</sup>. However, PD-related peritonitis can be caused by uncommon organisms or exhibit an unusual clinical course. Furthermore, although the guidelines detail the indications

for catheter removal, difficulties often arise when deciding the best time for catheter removal.

In this article, we report a case in which, during antibiotic therapy for PD-related peritonitis in which the first culture of PD effluent upon hospitalization revealed only *Enterococcus faecalis*, the patient required peritoneal catheter removal caused by peritonitis relapse caused by newly detected Gram-negative, rod-like *Pseudomonas aeruginosa*. The peritonitis guidelines for patients undergoing PD, published by the International Society for Peritoneal Dialysis in 2016, outline criteria for treating PD-related peritonitis and encompass most cases of PD-related peritonitis caused by bacteria.

## Case Presentation

A 71-year-old man had undergone PD for 3 months for

Correspondence to Yukinao Sakai, Department of Nephrology, Graduate School of Medicine, Nippon Medical School, 1–1–5 Sendagi, Bunkyo-ku, Tokyo 113–8603, Japan

E-mail: y-sakai@nms.ac.jp

[https://doi.org/10.1272/jnms.JNMS.2020\\_87-511](https://doi.org/10.1272/jnms.JNMS.2020_87-511)

Journal Website (<https://www.nms.ac.jp/sh/jnms/>)

Table 1 Laboratory findings at first admission

Urinalysis		T-Bil	0.25 mg/dL	Serology	
Protein	(3+)	LDH	179 IU/L	CRP	6.25 mg/dL
Occult blood	(-)	CK	119 IU/L		
WBC	(-)	TP	5.8 g/dL	Coagulation	
bacteria	(-)	Alb	2.8 g/dL	APTT	27.4 sec
CBC		BUN	49.9 mg/dL	PT	109.3 %
WBC	5,400 / $\mu$ L	Cre	7.78 mg/dL	D-dimer	2.9 $\mu$ g/mL
RBC	298 $\times$ 10 <sup>4</sup> / $\mu$ L	T-Cho	177 mg/dL		
Hb	9.6 g/dL	LDL-Cho	106 mg/dL	Effluent	
Hct	28.9 %	TG	211 mg/dL	WBC	2,091 / $\mu$ L
Plt	20.7 $\times$ 10 <sup>4</sup> / $\mu$ L	Na	141 mEq/L	Neutrophil	91 %
Biochemical		K	5.3 mEq/L		
AST	10 IU/L	Cl	107 mEq/L		
ALT	13 IU/L	Glucose	165 mg/dL		

WBC, white blood cell; RBC, red blood cell; CBC, complete blood count; Hb, hemoglobin; Hct, hematocrit; Plt, platelet; AST, aspartate aminotransferase; ALT, alanine aminotransferase; T-Bil, total bilirubin; LDH, lactate dehydrogenase; CK, creatine kinase; TP, total protein; Alb, albumin; BUN, blood urea nitrogen; Cre, creatinine; T-Cho, total cholesterol; LDL-Cho, Low-density-lipoprotein cholesterol; TG, triacylglycerol; CRP, C-reactive protein; APTT, activated partial thromboplastin time; PT, prothrombin time.

end-stage kidney disease caused by diabetic nephropathy and kidney trauma that had occurred 50 years previously. He had cloudy PD effluent for a 3-day period but did not seek treatment, because of a lack of symptoms such as abdominal pain, high fever, and diarrhea. The community nurse, who visited his house weekly, identified the cloudy effluent, which led to his hospital admission. He was conscious at admission, and his vital signs were blood pressure 159/81 mm Hg, pulse 85/min, and temperature 36.7°C. His medical history included hypertension, type 2 diabetes, and hyperuricemia. His medication use included 1 mg/day trichlormethiazide, 25 mg/day losartan, 80 mg/day furosemide, 10 mg/day febuxostat, 0.25  $\mu$ g/day calcitriol, and 60 mg/day *Clostridium butyricum*. **Table 1** shows the laboratory findings at the first hospital admission. Abdominal CT scans upon initiation of PD revealed colon diverticulum. He used an automated PD machine at night and an exchange system with ultraviolet light irradiation. There was no evidence of technical failure, and the community nurse visited his house once weekly after PD was begun.

The patient had no symptoms such as abdominal pain, high fever, diarrhea, redness or swelling, or pain or pus at the catheter exit site. His white blood cell count was within the normal range, but C-reactive protein (CRP) level was elevated. Furthermore, dialysis effluent was cloudy, and the white blood cell count in dialysis effluent was greater than 100 / $\mu$ L, with >50% polymorphonuclear cells. Therefore, PD-related peritonitis without catheter

exit-site infection was diagnosed, and he was started on empiric antibiotic treatment, in accordance with treatment guidelines.

We started intravenous (IV) ceftazidime (CAZ) and intraperitoneal (IP) vancomycin (VCM) administration on the first day of hospitalization (**Fig. 1**). CAZ was discontinued on day 5 of hospitalization because we detected only VCM-sensitive *E. faecalis* in effluent at the time of hospitalization. IP VCM administration was continued for 3 weeks. On day 4, dialysis effluent was no longer cloudy, and white blood cell count in dialysis effluent and CRP were better, which suggested that the antibiotic treatment had been effective. However, dialysis effluent became cloudy again on day 15. Although the patient had no symptoms, such as abdominal pain, high fever, diarrhea, or redness, swelling, pain, or pus at the catheter exit site, the white blood cell count in dialysis effluent was greater than 100 / $\mu$ L, with >50% polymorphonuclear cells. IV CAZ administration was started because of the possibility of peritonitis relapse, although this case did not exactly match the standard definition. We changed to IV gentamycin (GM) and IP CAZ because we detected Gram-negative rod-like *P. aeruginosa* alone, without *E. faecalis*. We continued antibiotic therapy for 3 weeks, without catheter removal, because of the absence of exit-site infection. The patient improved and was discharged on day 46.

However, 8 days later, dialysis effluent was again cloudy, and he was hospitalized for PD-related peritoni-

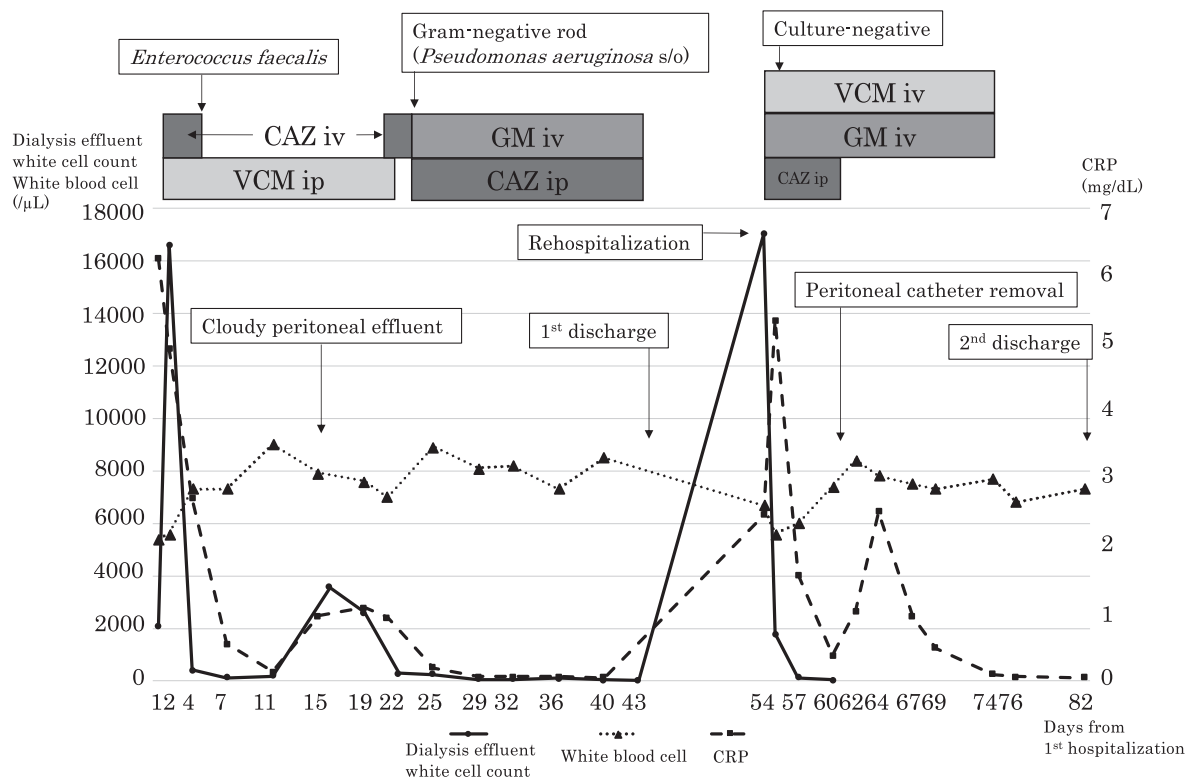


Fig. 1 Clinical course of patient

CRP, C-reactive protein; CAZ, ceftazidime; VCM, vancomycin; GM, gentamycin; iv, intravenous administration; ip, intraperitoneal administration.

tis. There was no catheter exit-site infection, and effluent cultures were negative. Recurrence of peritonitis—caused by Gram-negative, rod-like *P. aeruginosa*—was diagnosed on the basis of the treatment history, and antibiotic therapy with IV VCM, IV GM, and IP CAZ was started; the catheter was removed on day 61. We later continued IV VCM and IV GM administration, and peritonitis improved. He was discharged on day 82 after the initial hospitalization.

## Discussion

### PD-Related Peritonitis

Peritonitis—a common complication of peritoneal dialysis (PD)—can result in PD catheter removal, permanent hemodialysis, and death<sup>1-3</sup>. Thus, prediction and prevention of PD-related peritonitis are important.

The guidelines for peritonitis in patients undergoing PD, published by the International Society for Peritoneal Dialysis in 2016<sup>1</sup>, outline criteria for treating PD-related peritonitis and encompass most cases of PD-related peritonitis caused by bacteria<sup>1</sup>. We applied these guidelines in the present case. The peritonitis due to *E. faecalis* immediately improved with the initial antibiotic therapy but worsened at 16 days after the start of antibiotic ther-

apy. For PD-related peritonitis, the abovementioned guidelines provide the following definitions: “Recurrent: An episode that occurs within 4 weeks of completion of therapy of a prior episode but with a different organism,” “Relapsing: An episode that occurs within 4 weeks of completion of therapy of a prior episode with the same organism or one sterile episode,” and “Refractory: Failure of the effluent to clear after 5 days of appropriate antibiotics”<sup>1</sup>. In our patient, during antibiotic treatment for peritonitis caused by *E. faecalis*, we identified Gram-negative, rod-like *P. aeruginosa* in cloudy dialysis effluent but were unable to identify the organism responsible at that time because of the insufficient bacterial content. The present case did not fully satisfy the definitions of recurrence and relapse, because therapy was still underway and the condition was not diagnosed as refractory because the effluent cleared within 5 days after initial antibiotic treatment.

PD-related peritonitis due to *P. aeruginosa* is common and often requires catheter removal, particularly in cases of exit-site and tunnel infection<sup>1</sup>. The guidelines suggest that the indications for catheter removal—refractory peritonitis, relapsing peritonitis, refractory exit-site and tunnel infection, and fungal peritonitis—may also be consid-

ered for repeat peritonitis, mycobacterial peritonitis, and multiple enteric organisms<sup>1</sup>. When we identified Gram-negative, rod-like *P. aeruginosa*, our case did not fully satisfy these conditions. We thus did not remove the catheter at that time and limited treatment to antibiotics, because previous studies reported that PD-related peritonitis due to *P. aeruginosa* without catheter exit-site and tunnel infection did not require catheter removal<sup>4</sup>. In addition, our patient had already been discharged once. However, he was readmitted only 8 days later and underwent immediate catheter removal during the second period of hospitalization because of peritonitis relapse. As mentioned above, although the guidelines cover most cases of PD-related peritonitis, the decision to remove the catheter is sometimes difficult, as in our patient.

#### **PD-Related Peritonitis without Catheter Exit-Site or Tunnel Infection**

In this case, the lack of catheter exit-site and tunnel infection suggested an intra-abdominal pathological mechanism. Our patient had asymptomatic diverticulosis, and some studies reported that diverticulosis without symptoms such as abdominal pain or episodes of diverticulitis was not a risk for PD-related peritonitis<sup>5-7</sup>. However, another study reported that diverticulosis may cause PD-related peritonitis<sup>8</sup>, so we could not completely exclude the possibility of an association between peritonitis and diverticulosis.

#### **Responsible Organisms and Pathology**

Peritonitis associated with identification of multiple enteric organisms in a culture of dialysis effluent may be caused by an intra-abdominal pathological mechanism, which is associated with substantial mortality<sup>19</sup>. In addition, such cases have a high rate of transfer to hemodialysis<sup>10</sup>. Patients with PD-related peritonitis due to Gram-negative bacteria, with or without Gram-positive bacteria, have a worse prognosis<sup>11</sup>. In this case, we identified only *E. faecalis*, without Gram-positive bacteria, in the first culture of dialysis effluent. We started treatment because peritonitis was caused by *E. faecalis* alone, and the patient had no exit-site or tunnel infection. PD-related peritonitis caused by *E. faecalis* is common in elderly patients undergoing PD, and peritonitis due to multiple organisms with *E. faecalis* is associated with catheter removal, transfer to hemodialysis, and death in patients undergoing PD<sup>12</sup>. In peritonitis cases, catheter removal within 1 week of disease onset decreases the risk of transfer to hemodialysis<sup>12</sup>. In our patient, initial antibiotic therapy was effective, so refractory peritonitis was not diagnosed; however, during antibiotic therapy the patient

developed a relapse of peritonitis, caused by Gram-negative, rod-like *P. aeruginosa* alone without *E. faecalis*. If we had identified both Gram-negative, rod-like *P. aeruginosa* and *E. faecalis* in the same culture at the first hospitalization we would have performed catheter removal because of the presence of multiple-organism peritonitis; however, we did not do this because the organisms were detected at different times. *P. aeruginosa* is the second most common Gram-negative, rod-like bacteria that causes peritonitis<sup>13</sup>.

Peritonitis caused by *P. aeruginosa* has a higher rate of catheter removal and transfer to hemodialysis than peritonitis without *P. aeruginosa*<sup>14</sup>. In addition, patients more frequently receive antibiotic therapy for peritonitis caused by *P. aeruginosa* than for peritonitis caused by other organisms. Recent antibiotic therapy and peritonitis with catheter exit-site infection are associated with poor outcomes<sup>15</sup>. Peritonitis caused by *P. aeruginosa*, with exit-site and tunnel infection, requires catheter removal because of its poor prognosis<sup>1,14,15</sup>. In our patient, we identified Gram-negative, rod-like *P. aeruginosa* but were unable to identify it in a culture of dialysis effluent at hospitalization, perhaps because of antibiotic therapy for peritonitis due to *E. faecalis*. We did not remove the catheter, and the patient was discharged after undergoing antibiotic therapy only but soon returned to hospital because of new peritonitis, which was immediately improved by catheter removal. PD-related peritonitis due to *P. aeruginosa* often develops into relapsing peritonitis<sup>16</sup>. In our patient, we could not identify the responsible organism at the second hospitalization because a culture of dialysis effluent yielded negative results. Therefore, we could not diagnose relapsing peritonitis in accordance with the guidelines. However, the clinical course suggested a relapse of peritonitis caused by *P. aeruginosa*.

We have experienced few cases like this, so further studies are warranted. However, if an organism different from the causative organism is detected during initial antibiotic therapy for peritonitis, early catheter removal may be effective.

In conclusion, during antibiotic therapy for PD-related peritonitis caused by *E. faecalis* alone, the patient developed a relapse of peritonitis due to newly detected Gram-negative, rod-like *P. aeruginosa*. He required catheter removal for suspected relapse of peritonitis. Early catheter removal might be effective when a new organism is detected during antibiotic therapy for PD-related peritonitis caused by a different organism not meeting the definition of refractory peritonitis.

**Acknowledgements:** The authors thank the staff of the NMS Hospital Blood Purification Center.

**Conflict of Interest:** The authors declare no conflict of interest.

### References

1. Yip T, Tse KC, Lam MF, et al. Colonic diverticulosis as a risk factor for peritonitis in Chinese peritoneal dialysis patients. *Perit Dial Int* [Internet]. 2010 Mar-Apr;30(2):187–91. Available from: <https://www.ncbi.nlm.nih.gov/pubmed/20124196>
2. Wang HH, Huang CH, Kuo MC, et al. Microbiology of peritoneal dialysis-related infection and factors of refractory peritoneal dialysis related peritonitis: A ten-year single-center study in Taiwan. *J Microbiol Immunol Infect* [Internet]. 2019 Oct;52(5):752–9. Available from: <https://www.ncbi.nlm.nih.gov/pubmed/30665844>
3. Toda S, Ito Y, Mizuno M, et al. Asymptomatic diverticulosis identified by computed tomography is not a risk factor for enteric peritonitis. *Nephrol Dial Transplant* [Internet]. 2012 Jun;27(6):2511–6. Available from: <https://www.ncbi.nlm.nih.gov/pubmed/22189207>
4. Szeto CC, Kwan BC, Chow KM, et al. Recurrent and relapsing peritonitis: causative organisms and response to treatment. *Am J Kidney Dis* [Internet]. 2009 Oct;54(4):702–10. Available from: <https://www.ncbi.nlm.nih.gov/pubmed/19577352>
5. Szeto CC, Chow KM, Leung CB, et al. Clinical course of peritonitis due to *Pseudomonas* species complicating peritoneal dialysis: a review of 104 cases. *Kidney Int* [Internet]. 2001 Jun;59(6):2309–15. Available from: <https://www.ncbi.nlm.nih.gov/pubmed/11380835>
6. Siva B, Hawley CM, McDonald SP, et al. *Pseudomonas* peritonitis in Australia: predictors, treatment, and outcomes in 191 cases. *Clin J Am Soc Nephrol* [Internet]. 2009 May;4(5):957–64. Available from: <https://www.ncbi.nlm.nih.gov/pubmed/19406972>
7. Setyapranata S, Holt SG. The gut in older patients on peritoneal dialysis. *Perit Dial Int* [Internet]. 2015 Nov;35(6):650–4. Available from: <https://www.ncbi.nlm.nih.gov/pubmed/26702007>
8. Mehrotra R, Devuyt O, Davies SJ, Johnson DW. The current state of peritoneal dialysis. *J Am Soc Nephrol* [Internet]. 2016 Nov;27(11):3238–52. Available from: <https://www.ncbi.nlm.nih.gov/pubmed/27339663>
9. Li PK, Szeto CC, Piraino B, et al. ISPD peritonitis recommendations: 2016 Update on prevention and treatment. *Perit Dial Int* [Internet]. 2016 Sep 10;36(5):481–508. Available from: <https://www.ncbi.nlm.nih.gov/pubmed/27282851>
10. Kim GC, Korbet SM. Polymicrobial peritonitis in continuous ambulatory peritoneal dialysis patients. *Am J Kidney Dis* [Internet]. 2000 Nov;36(5):1000–8. Available from: <https://www.ncbi.nlm.nih.gov/pubmed/11054357>
11. Faber MD, Yee J. Diagnosis and management of enteric disease and abdominal catastrophe in peritoneal dialysis patients with peritonitis. *Adv Chronic Kidney Dis* [Internet]. 2006 Jul;13(3):271–9. Available from: <https://www.ncbi.nlm.nih.gov/pubmed/16815232>
12. Edey M, Hawley CM, McDonald SP, et al. Enterococcal peritonitis in Australian peritoneal dialysis patients: predictors, treatment and outcomes in 116 cases. *Nephrol Dial Transplant* [Internet]. 2010 Apr;25(4):1272–8. Available from: <https://www.ncbi.nlm.nih.gov/pubmed/19948875>
13. del Peso G, Bajo MA, Gadola L, et al. Diverticular disease and treatment with gastric acid inhibitors do not predispose to peritonitis of enteric origin in peritoneal dialysis patients. *Perit Dial Int* [Internet]. 2001 Jul-Aug;21(4):360–4. Available from: <https://www.ncbi.nlm.nih.gov/pubmed/11587398>
14. Boudville N, Kemp A, Clayton P, et al. Recent peritonitis associates with mortality among patients treated with peritoneal dialysis. *J Am Soc Nephrol* [Internet]. 2012 Aug;23(8):1398–405. Available from: <https://www.ncbi.nlm.nih.gov/pubmed/22626818>
15. Bernardini J, Piraino B, Sorkin M. Analysis of continuous ambulatory peritoneal dialysis-related *Pseudomonas aeruginosa* infections. *Am J Med* [Internet]. 1987 Nov;83(5):829–32. Available from: <https://www.ncbi.nlm.nih.gov/pubmed/3674090>
16. Barraclough K, Hawley CM, McDonald SP, et al. Polymicrobial peritonitis in peritoneal dialysis patients in Australia: predictors, treatment, and outcomes. *Am J Kidney Dis* [Internet]. 2010 Jan;55(1):121–31. Available from: <https://www.ncbi.nlm.nih.gov/pubmed/19932543>

(Received, March 12, 2020)

(Accepted, April 20, 2020)

Journal of Nippon Medical School has adopted the Creative Commons Attribution-NonCommercial-NoDerivatives 4.0 International License (<https://creativecommons.org/licenses/by-nc-nd/4.0/>) for this article. The Medical Association of Nippon Medical School remains the copyright holder of all articles. Anyone may download, reuse, copy, reprint, or distribute articles for non-profit purposes under this license, on condition that the authors of the articles are properly credited.