

Defining the Position of the Right Wall of the Esophageal Hiatus to Identify the Circumferential Distribution of Small Lesions of the Lower Esophagus

Yoshio Hoshihara¹, Akiyoshi Yamada¹, Shintaro Hoshino¹, Yoshimasa Hoshikawa¹,
Noriyuki Kawami¹, Junko Aida², Kaiyo Takubo² and Katsuhiko Iwakiri¹

¹Department of Gastroenterology, Nippon Medical School, Graduate School of Medicine, Tokyo, Japan

²Research Team for Geriatric Pathology, Tokyo Metropolitan Institute of Gerontology, Tokyo, Japan

Background: The reliability of methods for identifying the circumferential position of small lower esophageal lesions is unknown. We prospectively investigated a new method that presents lesion positions as times on a clock face.

Methods: Eighty-seven patients were consecutively examined by endoscopy. After observing the esophagus, an endoscope was inserted into the stomach and fixed, and the greater curvature folds at the upper gastric corpus were set as horizontal on the endoscope monitor display. The scope was retrogressed into the lower esophagus. At this point, the right wall at the hiatus is at the 3 o'clock position (R-line). The scope was then retrogressed from the gastric angle to the cardia along the center of the lesser curvature in the retroflexed view to obtain the LC-line (the center of the lesser curvature at the cardia). The LC-line in the esophageal hiatus in the frontal view was then identified, and the angle between the R- and LC-lines (R-LC) was measured.

Results: After excluding 7 patients with hernias >2 cm and 3 with esophageal stenosis, data from 77 patients were analyzed. The R-LC angle ranged from -38° to $+35^{\circ}$. The mean R-LC angle was $-0.3^{\circ} \pm 15.9^{\circ}$, and its 95% confidence interval was $[-4.0^{\circ}, 3.3^{\circ}]$ within $[-15^{\circ}, +15^{\circ}]$. When indicating lesion locations as times on a clock face, there was an error of ± 30 min ($\pm 15^{\circ}$); therefore, R- and LC-lines were shown to be identical on an equivalence test.

Conclusions: This new method allows the circumferential position of small lower esophageal lesions to be reliably represented as a clock face. (J Nippon Med Sch 2021; 88: 32–38)

Key words: endoscopy, small lower esophageal lesion, circumferential distribution, localization of the esophageal right wall

Introduction

The circumferential location of small lesions in the lower esophagus is usually represented on a clock face (Fig. 1). In previous studies, Los Angeles classification grade A and B mucosal breaks were frequently located from the right lateral to anterior wall¹ and from the right lateral to posterior wall². A difference of approximately 90° (3 h) was observed between these sites. This was also the case in studies of the circumferential distribution of small Barrett's neoplasia^{3–8}.

In previous studies, the endoscope was inserted so that

the anterior side¹ or right wall (i.e. gastric lesser curvature)² was always positioned at 12 o'clock on the screen. After endoscope insertion, the examination typically starts in the upper esophagus and advances to the middle and lower esophagus; however, it is difficult to fix the direction of the endoscope without rotating it. Furthermore, previous studies did not describe how the direction of the endoscope was maintained as prescribed during evaluations of the circumferential distribution of lesions or the findings of such validation analysis. Thus, the setting of a reference point is important for evaluat-

Correspondence to Yoshio Hoshihara, Department of Gastroenterology, Nippon Medical School, Graduate School of Medicine, 1-1-5 Sendagi, Bunkyo-ku, Tokyo 113-8603, Japan

E-mail: hoshihara@nms.ac.jp

https://doi.org/10.1272/jnms.JNMS.2021_88-102

Journal Website (<https://www.nms.ac.jp/sh/jnms/>)

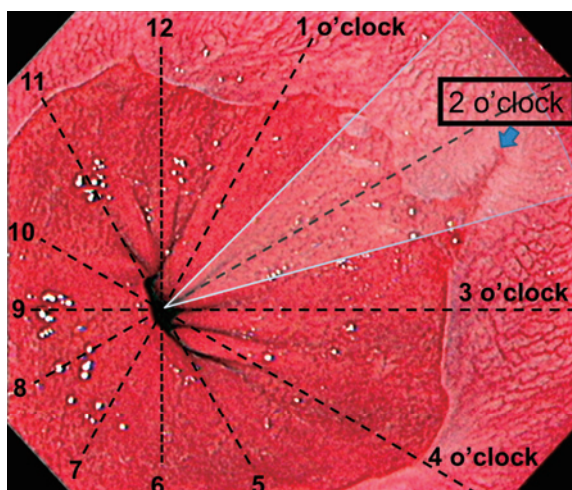


Fig. 1 A Los Angeles classification Grade B mucosal break (blue arrow) is present between the 2 o'clock and 3 o'clock positions but is closer to the 2 o'clock position. The position of a lesion between 1:30 and 2:30 (white area) is expressed as 2 o'clock.

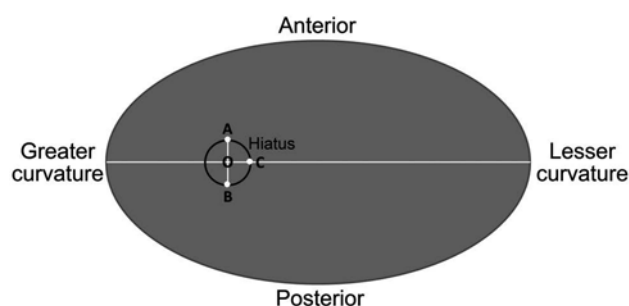


Fig. 2 Schematic diagram of a cranial view of the stomach and cardiac orifice during an examination with the patient in left lateral recumbent position. In the line segment AB passing through the center (O) of the cardiac orifice (esophageal hiatus) and orthogonally crossing the folds of the greater curvature of the stomach body, point A is theoretically the anterior wall (12 o'clock position), point B is the posterior wall (6 o'clock position), and point C is the direction of the right wall of the esophageal hiatus (3 o'clock position), i.e., the direction of the center of the lesser curvature of the stomach.

ing the circumferential distribution of lesions.

During endoscopy in the left lateral recumbent position, the line passing the center (O) of the cardiac orifice (esophageal hiatus) and perpendicularly running to the folds of the greater curvature in the gastric upper body theoretically converges with the esophageal hiatus at two points: on the anterior (A) and posterior (B) walls. Therefore, point C, at which the line passing through the center (O) and running perpendicularly in the right direction toward segment AB crosses the esophageal hiatus, is on the right wall (continuous with the line passing through the center of the lesser curvature of the stomach) (Fig. 2).

This prospective study investigated (1) whether the line (3 o'clock position) extending from the obtained segment OC to the esophagus coincides with the center line of the lesser curvature of the stomach and (2) whether their coincidence in a clock face localization of small lesions in the lower esophagus results in satisfactory clinical accuracy.

Materials and Methods

Participants

Eighty-seven patients were consecutively examined by using upper GI endoscopy at Nippon Medical School Hospital (Tokyo, Japan) during the period from February through June 2016. Patients were excluded if they had a history of gastrointestinal surgery, severe mucosal breaks (i.e., Los Angeles grades C and D), evidence of upper gastrointestinal malignancy, or any sign indicating serious or malignant disease.

The protocol of the present study was prepared in accordance with the World Medical Association Declaration of Helsinki and was approved by the Ethics Commission of Nippon Medical School (Approval Number: 27-10-509). All patients provided written informed consent for the endoscopic examination.

Endoscopic Procedure

The position of the right wall in the esophageal hiatus over the lower esophagus

Endoscopy was performed by three specialists (YH, AY, and KI) in gastrointestinal endoscopy, each of whom has greater than 10 years of experience. After inducing conventional anesthesia of the throat, an endoscope was inserted into the esophagus of fully conscious patients. Images were acquired with a high-resolution endoscope (Olympus GIF-260 and 290; Olympus Co., Tokyo, Japan, and Fujifilm GF-260WR and 280WR; Fujifilm Co., Tokyo, Japan), with patients in the left lateral position throughout. The images were stored in a Nippon Denko endoscopic image recording system.

After observing and recording the lower esophagus during deep inhalation, the endoscope was inserted into the stomach and immediately positioned horizontal to the folds of the greater curvature at the upper gastric corpus at a 3 o'clock position on the endoscope monitor display (Fig. 3).

The scope was then slowly retrogressed into the lower esophagus while recording video images. As shown in Figure 2, the posterior and right walls at this point are

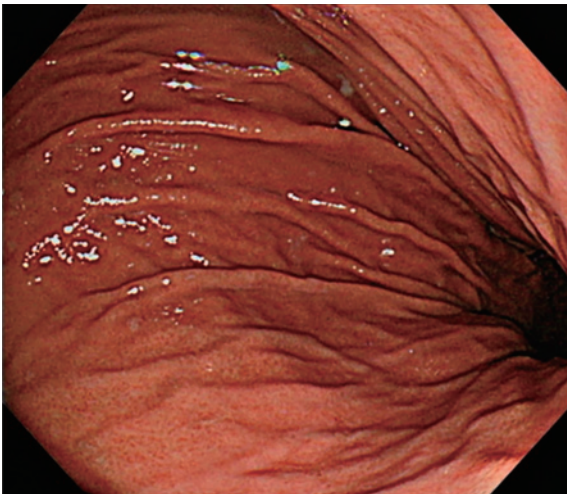

Fig. 3 After the endoscope is inserted into the stomach, torque is fixed to keep the folds of the greater curvature in the upper body of the stomach horizontal at the 3 o'clock position on the endoscope monitor display.

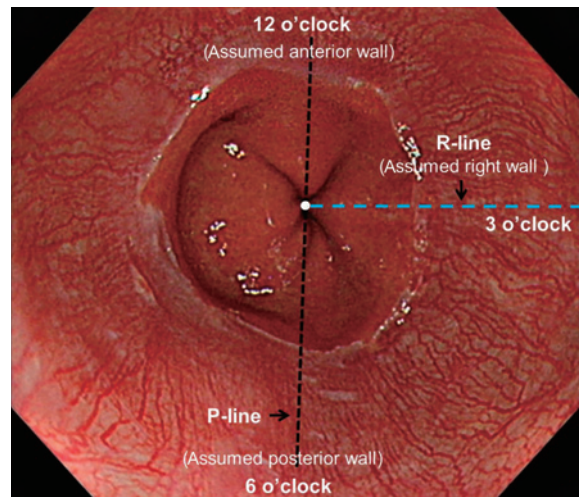


Fig. 4 The endoscope is slowly withdrawn to the lower esophagus while recording. The 6 o'clock (P-line: short black dashed line) and 3 o'clock (R-line: blue dashed line) positions are assumed to be the directions of the posterior and right walls, respectively.

theoretically located at the 6 o'clock and 3 o'clock positions, which are termed the P-line and R-line (Fig. 4), respectively.

Evaluation of Clinical Usefulness and Accuracy

The right side of the esophageal hiatus is continuous with the center of the lesser curvature of the stomach and was defined as 3 o'clock (R-line) by using the method above. Therefore, we examined whether the position 3 o'clock (R-line) and the center of the lesser curvature of the stomach were in agreement by using the method described below. In the present study, the center of the lesser curvature was defined as the line that connects the center of the lesser curvature of the gastric angle to the cardia along the folds of the lesser curvature.

Position of the Lesser Curvature at the Cardia and Lower Esophagus

To identify the position of the center of the lesser curvature (LC-line) at the cardia, the lesser curvature of the gastric angle was observed and recorded by retroflexion of the scope, after which the scope was retrogressed into the cardia along the lesser curvature in the retroflexed view while recording the folds prepared by removing the air in the stomach.

One of the authors (YH) compared still endoscopic images of the gastric lesser curvature recorded in the retroflexed view, observed several characteristic features captured in each image, and identified the center point of the lesser curvature of the gastric angle and the LC-line (long black dashed line), based on a line drawn from this center point to the cardia along the fold parallel to the

long axis (Fig. 5A). The position of the LC-line was decided by consensus among three authors (YH, AY, and KI). The LC-line in the esophageal hiatus in the front view (Fig. 5B) was also identified by comparing characteristic endoscopic findings near the esophageal hiatus on endoscopic images from the front and retroflexed views (Fig. 5A and B).

During this process, all investigators were blinded to the images recorded to decide the P- and R-lines.

Measurement of Divergence between R-Line and LC-Line

The LC-line was decided, and the P- and R-lines were identified on the endoscopic images of the lower esophagus obtained using the above method and by consensus among three authors (Fig. 4).

In the image on which the P- and R-lines were identified, the LC-line (long black dashed line) was drawn by comparing characteristic endoscopic findings near the squamocolumnar junction (SCJ). The angle of the LC-line was regarded as 90° and the angle of the R-line was measured clockwise. The R-LC angle was calculated by subtracting the angle of the LC-line (90°) from that of the R-line (Fig. 6).

Statistical Analysis

Clinical variables and patient data are expressed as ranges and means \pm SD. Statistical analysis was performed with the R statistics program (version 3.4.1; <https://cran.r-project.org>). The Shapiro-Wilk normality test and one-sample *t*-test were used to confirm whether the R-line coincided with the LC-line (whether the mean

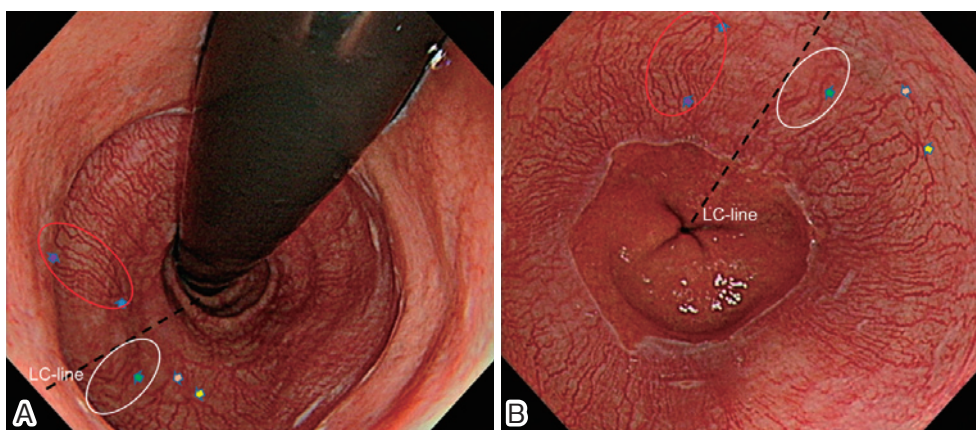


Fig. 5 (A) After retroflexing the endoscope in the stomach and confirming the center of the gastric angle, the endoscope is pulled upward along the center of the lesser curvature to the cardia, and retroflexed endoscopic images near the squamocolumnar junction are recorded. The direction of the LC-line (long black dashed line) from the cardiac region/squamocolumnar junction is determined by using these endoscopic images. (B) On the basis of the characteristics (indicated by arrows and circles) near the LC-line in the image of the cardia recorded in the retroflexed view (Fig. 5A), the LC-line in the esophageal hiatus is identified on an image of the lower esophagus recorded in the front view before insertion of the endoscope into the stomach.

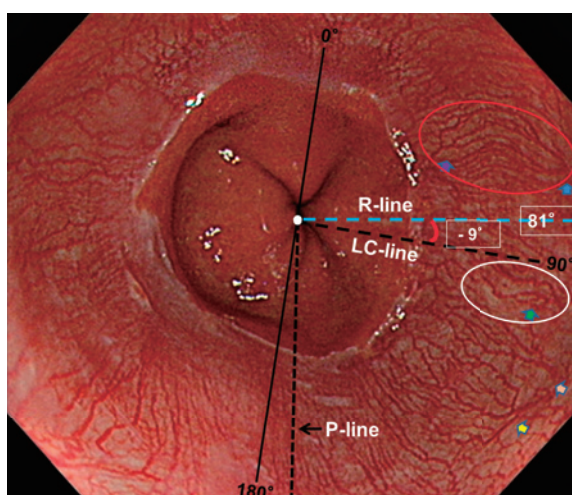


Fig. 6 In an image on which the P-line and R-line were identified (Fig. 4), the LC-line was drawn by comparing characteristic endoscopic findings (indicated by arrows and circles) between Figures 5B and 6 near the squamocolumnar junction, and the angle between the R-line and LC-line was measured. In calculations of the R-LC angle, the angle of the LC-line was regarded as 90° and that of the R-line was measured clockwise. The R-LC angle was calculated by subtracting the angle of the LC-line (90°) from that of the R-line. In this patient, because the R-line was 81° , the R-LC angle = $81^\circ - 90^\circ = -9^\circ$.

R-LC angle was 0°). A p value of less than 0.05 was considered to indicate statistical significance. The 95% confi-

dence interval of the mean R-LC angle was also calculated. The coincidence between the R- and LC-lines was examined by an equivalence test^{9,10}.

Results

Patient Characteristics

Among the 87 patients enrolled, 7 with a >2-cm esophageal hiatus hernia were excluded from the present study because of the need for further evaluation of whether the axis of the endoscope could be maintained from the esophageal hiatus to the SCJ. Three patients with mild stenosis of the SCJ, in whom the lower esophagus was difficult to examine by retroflexion, were also excluded. Thus, data from 77 patients were ultimately analyzed. The male/female ratio was 47/30. Patient age ranged from 26 to 86 years (mean: 64.8 ± 12.7 years). Seven of the 77 patients had mucosal breaks, which were classified as grade A in 4 patients and grade B in 3 patients.

Divergence between R- and LC-Lines

The assumed positions of the posterior wall (P-line) and right wall (R-line), and the LC-line in the esophageal hiatus over the lower esophagus, were identified on still endoscopic images from all 77 patients.

The angle between the R- and LC-lines (R-LC) ranged from -38° to $+35^\circ$ (Fig. 7), and the mean was $-0.3^\circ \pm 15.9^\circ$. The values were normally distributed (Shapiro-Wilk normality test, $p=0.73$), without outliers. Because

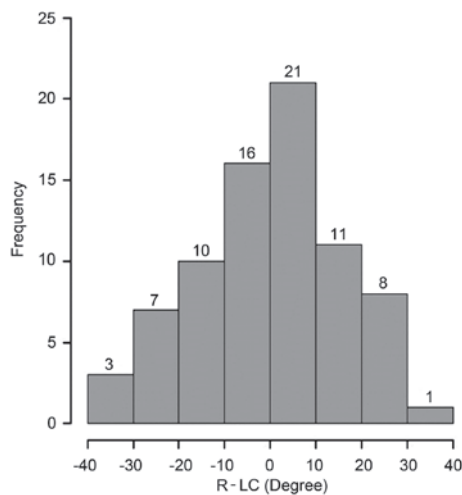


Fig. 7 Frequency distribution of R-LC angles.

The values above the histogram indicate the numbers of patients in each interval.

the one-sample *t*-test yielded a *p*-value of 0.85, the hypothesis that the mean R-LC angle was 0° was not rejected, using *p* < 0.05.

The 95% confidence interval (CI) of the mean R-LC angle was [-4.0°, 3.3°], which included 0° and was in the range of ±15°. Methods to identify the location of a lesion as time on a clock face have an error of ±30 min (±15°) because a lesion located between 1:30 and 2:30 is expressed as a lesion at the 2 o'clock position (white area in **Figure 1**). Because the 95% CI of the mean R-LC angle was within [-15°, +15°], the mean R-LC angle was regarded as 0° in an equivalence test. Specifically, the clinical accuracy of the R- and LC-lines coincided.

Discussion

All but one previous study⁵ reported that when the circumferential distribution of small lower esophageal lesions is represented on a clock face (**Fig. 1**), most low-grade mucosal breaks and neoplasms attributable to short-segment Barrett's esophagus^{1-4,6-8} were located between the 12 o'clock and 3 o'clock positions. This finding has attracted attention because if this circumferential distribution is observed in early Barrett's adenocarcinoma or dysplasia, it may be useful for early detection of Barrett's esophagus-associated neoplasia and surveillance of Barrett's esophagus^{8,11-14}. In addition, further clarification of the reason for the occurrence of mild mucosal breaks in limited areas could aid in understanding their pathogenic mechanism. However, in previous studies of the circumferential distribution of lesions, the 3 o'clock position was aligned with the lesser curvature of the stomach^{1,5-8},

whereas other studies reported that the 12 o'clock position corresponded to the gastric lesser curvature and right lateral wall of the esophagus^{2,4}. This difference in reference points indicates that caution is needed in comparisons of these methods, as there was a 3-h, or 90°, difference in the site of a lesion. Under these conditions, the use of findings for surveillance of Barrett's esophagus or clarification of the pathogenic mechanism of mild mucosal breaks is difficult; however, such a discrepancy is believed to occur because the consistency of the reference direction in evaluations of the circumferential distribution of lesions has not yet been confirmed, and a method for this confirmation has not been developed.

We thus investigated whether a reliable representation of the circumferential distribution of lesions on a clock face is possible by endoscopically defining the position of the right wall in the esophageal hiatus.

In our method, an endoscope is fixed to a position in which the folds of the greater curvature in the upper body of the stomach run horizontally in the endoscopic view. The endoscope is then pulled back from the cardia to the lower esophagus when the right wall is theoretically located at the 3 o'clock (R-line) position (**Fig. 2, 4**). Our results indicate that this 3 o'clock (R-line) position yields acceptable clinical accuracy to the center of the lesser curvature of the stomach, which is continuous with the right wall of the esophageal hiatus until the lower esophagus.

It is important to note that we need to validate our definition of the center of the lesser curvature (LC-line), which we defined as the line that connects the center of the lesser curvature of the gastric angle to the cardia along the folds of the lesser curvature. In Japan, barium X-ray examination is a common procedure for assessing gastric diseases. On single-contrast frontal barium X-rays of the stomach in the standing position and on double-contrast frontal images in the supine position, in which the U-shaped gastric angle appears without deformation, the inner lateral margin is considered the lesser curvature. Matsue et al¹⁵ termed this line "the center of the lesser curvature" and proposed a system to locate lesions in the stomach by dividing the stomach into 77 sections based on this center of the lesser curvature. This system, termed the Stomap, has been used widely in screening for gastric cancer¹⁶.

During gastroscopy performed while the patient is in a left lateral recumbent position, the greater curvature is placed in the direction of gravity (floor direction), and the lesser curvature is placed in the contralateral ceiling

when the stomach is sufficiently filled with air. Under these conditions, the gastric angle forms a symmetrical arc from the center of the lesser curvature to the anterior and posterior walls. A similar structure of the stomach filled with sufficient air is observed on CT-gastrography¹⁷, during which the center of the arc becomes the center point of the lesser curvature of the gastric angle. By removing air to enable observation of the gastric folds, the LC-line can then be identified as the line drawn from this center point to the cardia parallel to the folds of the lesser curvature.

The present study has several limitations. Errors can occur while identifying the LC-line along the lesser curvature in the body of the stomach. To accurately determine the position of the LC-line, we compared multiple consecutively captured images and followed several endoscopic features observed across the images. Errors may also occur during evaluation of the P-line and R-line. Moreover, although the endoscope must be horizontally withdrawn to the folds of the greater curvature in the upper body of the stomach, this withdrawal maneuver may vary among endoscopists. Bias was minimized by consensus among the 3 physicians. However, interobserver variation in the evaluation of the circumferential distribution of lesions needs to be further examined.

Some of the present patients had cascade stomach. Because the R-LC angle was in the range of -38° to $+35^{\circ}$ and exhibited a normal distribution, without outliers, this method is considered applicable and clinically valid for the present patients. This suggests that the R-line was set parallel to the greater curvature folds at the upper gastric corpus. However, further studies of patients with cascade stomach are necessary.

To date, studies of the circumferential distribution of small lower esophageal lesions have reached different conclusions because they lacked an effective reference marker that consistently identified the direction of the endoscope. By using our method, in which the right wall of the lower esophagus is identified in relation to the esophageal hiatus, the circumferential distribution of localized lesions in the lower esophagus may be straightforwardly represented as a clock face, with clinically reasonable precision.

Conflict of Interest: All authors declare that they have no conflicts of interest.

References

1. Katsube T, Adachi K, Furuta K, et al. Difference in localization of esophageal mucosal breaks among grades of esophagitis. *J Gastroenterol Hepatol*. 2006;21:1656–9.
2. Edebo A, Vieth M, Tam W, et al. Circumferential and axial distribution of esophageal mucosal damage in reflux disease. *Dis Esophagus*. 2007;20:232–8.
3. Moriyama N, Amano Y, Okita K, Mishima Y, Ishihara S, Kinoshita Y. Localization of early-stage dysplastic Barrett's lesions in patients with short-segment Barrett's esophagus. *Am J Gastroenterol*. 2006;101:2666–7.
4. Pech O, Gossner L, Manner H, et al. Prospective evaluation of the macroscopic types and location of early Barrett's neoplasia in 380 lesions. *Endoscopy*. 2007;39:588–93.
5. Kariyawasam VC, Bourke MJ, Hourigan LF, et al. Circumferential location predicts the risk of high-grade dysplasia and early adenocarcinoma in short segment Barrett's esophagus. *Gastrointest Endosc*. 2012;75:938–44.
6. Enestvedt BK, Lugo R, Guarner-Argente C, et al. Location, location, location: does early cancer in Barrett's esophagus have a preference? *Gastrointest Endosc*. 2013;78:462–7.
7. Cassani L, Sumner E, Slaughter JC, Yachimski P. Directional distribution of neoplasia in Barrett's esophagus is not influenced by distance from the gastroesophageal junction. *Gastrointest Endosc*. 2013;77:877–82.
8. Ishimura N, Okada M, Mikami H, et al. Pathophysiology of Barrett's esophagus-associated neoplasia: circumferential spatial predilection. *Digestion*. 2014;89:291–8.
9. Jones B, Jarvis P, Lewis JA, Ebbutt AF. Trials to assess equivalence: the importance of rigorous methods. *BMJ*. 1996;313:36–9.
10. Piaggio G, Elbourne DR, Altman DG, Pocock SJ, Evans SJW for the CONSORT Group. Reporting of Noninferiority and Equivalence Randomized Trials: An Extension of the CONSORT Statement. *JAMA*. 2006;295:1152–60.
11. Cooper GS, Yuan Z, Chak A, Rimm AA. Association of prediagnosis endoscopy with stage and survival in adenocarcinoma of the esophagus and gastric cardia. *Cancer*. 2002;95:32–8.
12. Corley DA, Levin TR, Habel LA, Weiss NS, Buffler PA. Surveillance and survival in Barrett's adenocarcinomas: a population-based study. *Gastroenterology*. 2002;122:633–40.
13. Cooper GS, Kou TD, Chak A. Receipt of previous diagnoses and endoscopy and outcome from esophageal adenocarcinoma: a population-based study with temporal trends. *Am J Gastroenterol*. 2009;104:1356–62.
14. Kearney DJ, Crump C, Maynard C, Boyko EJ. A case control study of endoscopy and mortality from adenocarcinoma of the esophagus or gastric cardia in persons with gastroesophageal reflux disease. *Gastrointest Endosc*. 2003;57:823–9.
15. Matsue H, Tobayashi K, Yamada T, et al. [X-ray diagnosis of lesions in the upper portions of the stomach]. I to Cho [Stomach and Intestine]. 1970;5:1071–83. Japanese. (abstract: in English).
16. Kono R, Mekada Y, Mori K, Ide I, Murase H, Hasegawa J. [The method for presentation of observed regions using Stomap in virtualized endoscope system]. *IEICE Technical Report*. 2004;104:21–6. Japanese. (abstract: in English).
17. Kim SH, Lee JM, Han JK, et al. Effect of adjusted positioning on gastric distention and fluid distribution during CT gastrography. *Am J Roentgenol*. 2005;185:1180–4.

1. Katsube T, Adachi K, Furuta K, et al. Difference in local-

(Received, June 29, 2019)

(Accepted, February 26, 2020)

(J-STAGE Advance Publication, March 31, 2020)

Journal of Nippon Medical School has adopted the Creative Commons Attribution-NonCommercial-NoDerivatives 4.0 International License (<https://creativecommons.org/licenses/by-nc-nd/4.0/>) for this article. The Medical Association of Nippon Medical School remains the copyright holder of all articles. Anyone may download, reuse, copy, reprint, or distribute articles for non-profit purposes under this license, on condition that the authors of the articles are properly credited.