

Transcatheter Closure of a Secundum Atrial Septal Defect with Deficient Aortic Rim Through the Left Internal Jugular Vein in a Child with Situs Inversus and Interrupted Inferior Vena

*Original*

Transcatheter Closure of a Secundum Atrial Septal Defect with Deficient Aortic Rim Through the Left Internal Jugular Vein in a Child with Situs Inversus and Interrupted Inferior Vena Cava: Device's Choice Matters / Piccinelli, Enrico; Bautista-Rodriguez, Carles; Aw, Tuan-Chen; Bates, Oliver; Fraise, Alain. - In: PEDIATRIC CARDIOLOGY. - ISSN 0172-0643. - 42:8(2021), pp. 1879-1881. [10.1007/s00246-021-02708-9]

*Availability:*

This version is available at: 11583/2970583 since: 2022-08-10T15:18:03Z

*Publisher:*

SPRINGER

*Published*

DOI:10.1007/s00246-021-02708-9

*Terms of use:*

openAccess


This article is made available under terms and conditions as specified in the corresponding bibliographic description in the repository

*Publisher copyright*

(Article begins on next page)



# Transcatheter Closure of a Secundum Atrial Septal Defect with Deficient Aortic Rim Through the Left Internal Jugular Vein in a Child with Situs Inversus and Interrupted Inferior Vena Cava: Device's Choice Matters

Enrico Piccinelli<sup>1,2</sup> · Carles Bautista-Rodriguez<sup>1,2</sup> · Tuan-Chen Aw<sup>1,2</sup> · Oliver Bates<sup>1,2</sup> · Alain Fraise<sup>1,2</sup> 

Received: 9 June 2021 / Accepted: 17 August 2021

© The Author(s), under exclusive licence to Springer Science+Business Media, LLC, part of Springer Nature 2021

## Abstract

Percutaneous closure of secundum atrial septal defect (sASD) in children with interrupted inferior vena cava is challenging, especially in case of deficient aortic rim. Trans-jugular access is generally preferred in this scenario. Patients with situs inversus and sASD also carry technical difficulties for transcatheter closure because of the orientation of the atrial septum. We report a successful case of percutaneous closure of a sASD with deficient aortic rim using an occlutech figulla flex II ASD device through the left internal jugular vein in a child with situs inversus, dextrocardia, and interrupted IVC. This case was facilitated by the absence of left-sided hub of the Occlutech device to provide stable opening of the device into the left atrium, whereas the ball-connection of the delivery system allowed an angle of almost 180 degrees between the device and the atrial septum.

**Keywords** Interrupted inferior vena cava · Secundum atrial septal defect · Occlutech ASD occluder · Transjugular approach

## Introduction

Percutaneous closure is the treatment of choice for secundum atrial septal defect (sASD) [1]. Generally, the procedure is performed using femoral venous access; however, in the case of interrupted inferior vena cava (IVC) with azygos continuation to the superior vena cava (SVC) this approach may be difficult. Alternative accesses such as transhepatic, jugular, or femoral via the azygos vein have been described [2–5]. Patients with situs inversus and sASD are rarely encountered and transcatheter closure is also feasible but carries technical difficulties due to the orientation of the atrial septum [6,

7]. We report a challenging case of percutaneous closure of a sASD in a child with interrupted IVC, situs inversus, and deficient aortic rim using an Occlutech Figulla Flex II ASD device (Occlutech; Helsingborg, Sweden) through the left internal jugular vein.

## Case Report

A 5-year-old, 20 kg girl with situs inversus, dextrocardia, interrupted IVC, and history of percutaneous closure of a patent ductus arteriosus at the age of 7 months was under follow-up for a sASD. Although asymptomatic, the last transthoracic echocardiogram (TTE) in the outpatient clinic demonstrated a large defect with deficient aortic rim and right ventricular volume overload. The PDA device was in a good position without residual shunt or left pulmonary artery stenosis. It was then decided to perform elective percutaneous closure of her sASD.

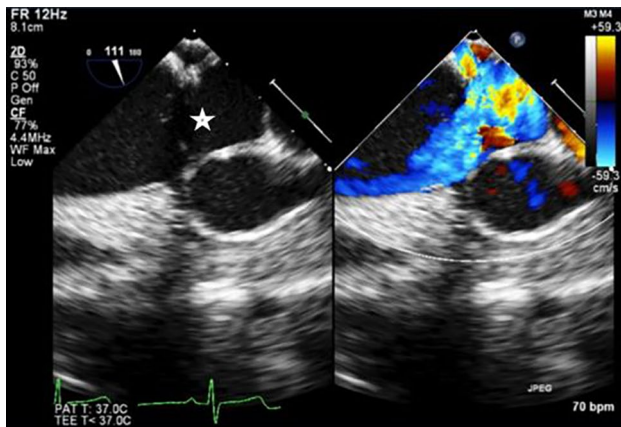
Under general anesthesia and transoesophageal echocardiography (TOE) guidance a 15 mm defect with aortic rim deficiency was seen [Fig. 1]. Through left internal jugular vein (LIJV) access, a 5F left internal mammary catheter

Enrico Piccinelli and Carles Bautista-Rodriguez have contributed equally to this work.

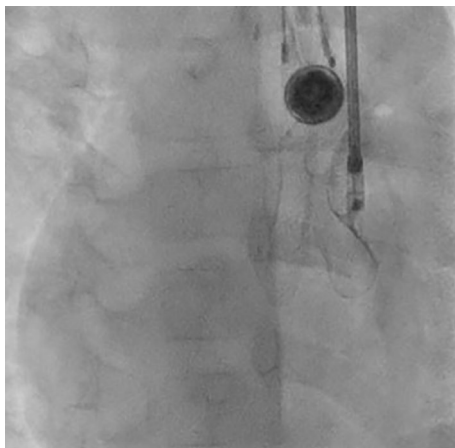
✉ Alain Fraise  
a.fraise@rbht.nhs.uk

<sup>1</sup> Paediatric Cardiology Services, Royal Brompton Hospital and Harefield NHS Foundation Trust, Sydney Street, London SW3 6NP, UK

<sup>2</sup> National Heart and Lung Institute, Imperial College London, London, UK

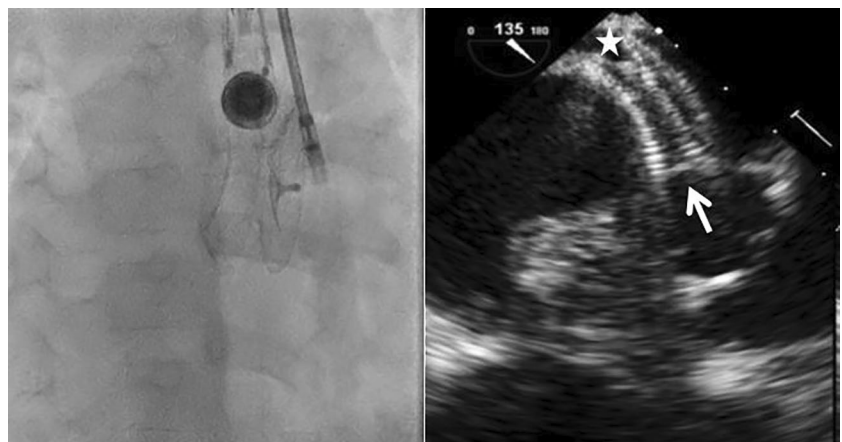


**Fig. 1** Transoesophageal echocardiogram confirmed large secundum atrial septal defect (white star) measured at 15 mm with deficient aortic rim



**Fig. 2** A 16.5 mm Occlutech Figulla Flex II ASD device was successfully positioned. Note the almost parallel angulation of the device and the Flex Pusher anchored to the Flex II hub

**Fig. 3** On fluoroscopy ASD device successfully released after confirmation of stability by pull–push motion. On transoesophageal echocardiogram device in situ with clear posterior rim between the disks (white star) and stable position toward the deficient aortic rim (white arrow)



was successfully used to cross the sASD and a semi-rigid 0.035" diagnostic "J" tip guidewire (Medline International B.V., Arnhem, Netherlands) was positioned in the left ventricle (LV). Because the long sheath of the delivery system (Occlutech; Helsingborg, Sweden) was felt to be too rigid for this case, a 9 Fr Cook flexor sheath (Cook Medical; Bloomington, U.S.A.) was advanced in the LV over the wire while a 16.5 mm Occlutech Figulla Flex II (FFII) ASD device (Occlutech; Helsingborg, Sweden) was loaded in an 9 Fr short sheath. The device was advanced at the distal end of the long sheath. The long sheath was then gently pulled into the left atrium (LA) while the LA disk was opened and then the right atrium (RA) disk was positioned over the defect. The ball-connection between the pusher and the device hub allowed achieving the correct orientation of the left and right atrial disks with the atrial septum [Fig. 2]. Further TOE and TTE images showed a good position of the device that was successfully released after confirmation of stability by pull–push motion [Fig. 3]. Post procedure echocardiography confirmed the excellent procedural result and the patient was discharged home on aspirin.

## Discussion

Percutaneous closure of sASD is generally performed via the femoral venous route. However, this may be very challenging in case of interrupted IVC with azygos continuation. Although transcatheter closure through the azygos vein has been reported [5], this may not be possible in cases with large defects and deficient rims. Transhepatic approach is feasible but can be associated with major complications, especially in young patients, such as retro/intraperitoneal bleeding, liver injury, and hemobilia [2]. Consequently, the jugular access is the preferred route to close such sASD due

to the possibility of accommodating relatively large sheaths and the favorable orientation to the atrial septum [3, 5, 6]. Several types of devices have been implanted using a transjugular approach in children and adults such as Amplatzer Septal Occluder (St. Jude Medical, Inc., Minnesota, USA) [6], Blockaid ASD Occluder (Shanghai shape memory alloy limited Shanghai, China) [4], and Ceraflex Septal Occluder (Lifetech, Shenzhen, China) [8]. The main difficulty encountered with this type of procedure is to ensure the correct orientation and alignment of the device with the atrial septum in order to avoid its prolapse in the right atrium. This technical difficulty is even more important in cases with associated situs inversus. Sreekanth Yerram et al. have addressed this problem in a patient with interrupted IVC and situs inversus by opening the left atrial disk in the left ventricle inflow, taking into account the risk of damaging mitral valve leaflets [8]. In the present case, the technical difficulty was almost abolished by using the FFII (Occlutech; Helsingborg, Sweden). The lack of a left-sided hub enabled the FFII to open in a stable way and a round shape during left atrial deployment, without the device prolapsing across the atrial septum. Moreover, the ball attachment connected with a bioptome-like system, allowed a tilted angle of 180 degrees without any stress or tension on the implant and optimal septum alignment [9].

This case report demonstrates that percutaneous closure of sASD with a deficient aortic rim in case of situs inversus, dextrocardia and interrupted IVC with azygos continuation is feasible through transjugular approach. The characteristics of the Occlutech FFII device and its specific delivery set facilitated the successful implantation.

**Author Contributions** EP, CBR, and AF contributed in the drafting of the manuscript and final approval of the manuscript submitted. TCA and OB revised critically the manuscript and gave final approval of the manuscript submitted.

## Declarations

**Conflict of interest** Alain Fraisse is consultant and proctor for Abbott and for Occlutech. The other four authors have nothing to declare.

**Ethical Approval** Yes.

## References

1. Du ZD, Hijazi ZM, Kleinman CS, Silverman NH, Larntz K (2002) Comparison between transcatheter and surgical closure of secundum atrial septal defect in children and adults. *J Am Coll Cardiol* 39(11):1836–1844
2. Shim D, Lloyd TR, Beekman RH (1999) Transhepatic therapeutic cardiac catheterization: a new option for the pediatric interventionalist. *Catheter Cardiovasc Interv* 47(1):41–45. [https://doi.org/10.1002/\(sici\)1522-726x\(199905\)47:1%3c41::aid-ccd8%3e3.0.co;2-y](https://doi.org/10.1002/(sici)1522-726x(199905)47:1%3c41::aid-ccd8%3e3.0.co;2-y)
3. Ozbarlas N, Kiziltas A, Kucukosmanoglu O, Erdem S (2012) Transjugular approach to device closure of atrial septal defect. *Tex Hear Inst J* 39(3):435–437
4. Seshagiri RD, Patnaik AN, Srinivas B (2013) Percutaneous closure of atrial septal defect via transjugular approach with blockaid device in a patient with interrupted inferior vena cava. *Cardiovasc Interv Ther* 28(1):63–65. <https://doi.org/10.1007/s12928-012-0113-4>
5. Truong QB, Dao AQ, Do NT, Le MK (2018) Percutaneous atrial septal defect closure through femoral and transjugular approaches in patients with interrupted inferior vena cava. *J Cardiol Cases* 18(3):106–109. <https://doi.org/10.1016/j.jccase.2018.05.007>
6. Oliveira EC, Moura MAG, Almeida JA, Ribeiro ALP, Nascimento BR (2019) Percutaneous closure of ostium secundum atrial septal defect using left internal jugular vein access in a child with situs inversus and absence of inferior caval vein. *Cardiol Young* 29(10):1310–1312. <https://doi.org/10.1017/S1047951119002099>
7. Acharya KP, Adhikari CM, Khanal A et al (2019) Transcatheter device closure of atrial septal defect in dextrocardia with situs inversus totalis. *Nepal Heart J* 16(1):51–53. <https://doi.org/10.3126/njh.v16i1.23901>
8. Yerram S, Aramalla S, Bhyravavajhala S (2020) Unconventional deployment of atrial septal occluder in a patient with atrial septal defect, dextrocardia, and interrupted inferior vena cava. *Cardiol Young* 30(8):1206–1208. <https://doi.org/10.1017/S104795112000178X>
9. Haas NA, Happel CM, Soetemann DB et al (2016) Optimal septum alignment of the Figulla® Flex occluder to the atrial septum in patients with secundum atrial septal defects. *EuroIntervention* 11(10):1153–1160. [https://doi.org/10.4244/EIJY14M12\\_09](https://doi.org/10.4244/EIJY14M12_09)

**Publisher's Note** Springer Nature remains neutral with regard to jurisdictional claims in published maps and institutional affiliations.

## Terms and Conditions

Springer Nature journal content, brought to you courtesy of Springer Nature Customer Service Center GmbH (“Springer Nature”).

Springer Nature supports a reasonable amount of sharing of research papers by authors, subscribers and authorised users (“Users”), for small-scale personal, non-commercial use provided that all copyright, trade and service marks and other proprietary notices are maintained. By accessing, sharing, receiving or otherwise using the Springer Nature journal content you agree to these terms of use (“Terms”). For these purposes, Springer Nature considers academic use (by researchers and students) to be non-commercial.

These Terms are supplementary and will apply in addition to any applicable website terms and conditions, a relevant site licence or a personal subscription. These Terms will prevail over any conflict or ambiguity with regards to the relevant terms, a site licence or a personal subscription (to the extent of the conflict or ambiguity only). For Creative Commons-licensed articles, the terms of the Creative Commons license used will apply.

We collect and use personal data to provide access to the Springer Nature journal content. We may also use these personal data internally within ResearchGate and Springer Nature and as agreed share it, in an anonymised way, for purposes of tracking, analysis and reporting. We will not otherwise disclose your personal data outside the ResearchGate or the Springer Nature group of companies unless we have your permission as detailed in the Privacy Policy.

While Users may use the Springer Nature journal content for small scale, personal non-commercial use, it is important to note that Users may not:

1. use such content for the purpose of providing other users with access on a regular or large scale basis or as a means to circumvent access control;
2. use such content where to do so would be considered a criminal or statutory offence in any jurisdiction, or gives rise to civil liability, or is otherwise unlawful;
3. falsely or misleadingly imply or suggest endorsement, approval, sponsorship, or association unless explicitly agreed to by Springer Nature in writing;
4. use bots or other automated methods to access the content or redirect messages
5. override any security feature or exclusionary protocol; or
6. share the content in order to create substitute for Springer Nature products or services or a systematic database of Springer Nature journal content.

In line with the restriction against commercial use, Springer Nature does not permit the creation of a product or service that creates revenue, royalties, rent or income from our content or its inclusion as part of a paid for service or for other commercial gain. Springer Nature journal content cannot be used for inter-library loans and librarians may not upload Springer Nature journal content on a large scale into their, or any other, institutional repository.

These terms of use are reviewed regularly and may be amended at any time. Springer Nature is not obligated to publish any information or content on this website and may remove it or features or functionality at our sole discretion, at any time with or without notice. Springer Nature may revoke this licence to you at any time and remove access to any copies of the Springer Nature journal content which have been saved.

To the fullest extent permitted by law, Springer Nature makes no warranties, representations or guarantees to Users, either express or implied with respect to the Springer nature journal content and all parties disclaim and waive any implied warranties or warranties imposed by law, including merchantability or fitness for any particular purpose.

Please note that these rights do not automatically extend to content, data or other material published by Springer Nature that may be licensed from third parties.

If you would like to use or distribute our Springer Nature journal content to a wider audience or on a regular basis or in any other manner not expressly permitted by these Terms, please contact Springer Nature at

[onlineservice@springernature.com](mailto:onlineservice@springernature.com)