



**Indonesian Journal of
Cardiology**

Indonesian J Cardiol 2021;42:suppl_C
pISSN: 0126-3773 / eISSN: 2620-4762
doi: 10.30701/ijc.1241



The 8th Annual Scientific Meeting

INDONESIAN HEART RHYTHM SOCIETY

Abstract: Case Report



Role of ECG in Thoracoabdominal Conjoined Twins: A Case Report

A. Lubis¹, A. C. Lubis², H. Hasan³

¹Cardiology Resident at Cardiac Center H. Adam Malik Hospital, Faculty of Medicine Universitas Sumatera Utara, Medan, Indonesia

^{2,3}Cardiologist at Cardiac Center H. Adam Malik Hospital, Faculty of Medicine Universitas Sumatera Utara, Medan, Indonesia

Background: The risk of cardiac anomaly is increased in monochorionic twin pregnancy. Cardiac defects are common in conjoined twins, affecting at least 1 twin in over 50% of conjoined twin pregnancies with thoracic level fusion. The ECG, recorded simultaneously from each twin, as the single most useful tool in the examination of thoracopagus. Recording of the standard limb leads and analysis of the vector direction have been helpful determining complex present. The extent of union of the hearts in thoracopagus twins varies but can include fusion of the large vessels, the atria, the atria and ventricles, and rarely, a single heart in one of the twins. New imaging modalities such as CTA and CMRI are more accurate with regard to the definition of fusion and to the great vessels anatomy.

Case Illustration: 1 day old thoracoabdominal conjoined twins presented with dyspnea and cyanosis since birth come to RSUP H. Adam Malik Medan. From the babygram we found fusion of the anterior thoracoabdominal wall. In the first Baby, ECG showed sinus tachycardia, extreme axis deviation and inverted P Waves in lead I. And for the second baby, ECG showed sinus tachycardia, extreme axis deviation and positive P in lead I. The mixed ECG showed 2 morphologies of P waves and one morphology QRS. Echocardiography showed that both of babies have complete heart structure with conjoined pericardial wall. We found that the first baby has double outlet ventricle, single ventricle, tricuspid atresia, patent ductus arteriosus, patent foramen ovale and dextrocardia. The second baby has mild TR, mild MR and balanced four chamber.

Conclusions: Cardiac assessment is an important component of fetal and postnatal evaluation. The extent of cardiac fusion and the severity of cardiac abnormalities play a major role in the medical decision of surgical separation and in long-term survival. Electrocardiogram demonstrating independent QRS complexes suggests isolated ventricle who have poor prognostic. Twins who had fused hearts at atrial, ventricular, or both levels were considered not to be candidates for surgical separation.



Cardiogenic Shock as Complication of Covid-19 at Rumah Sakit Daerah Sorong in West Papua: An Evidence-base Case Report

A. S. Siagian¹, J. A. Trixie², Y. Kurube³, E. Hartanto⁴

¹General Practitioner at Bhayangkara Hospital,

²General Practitioner at RSUD Sorong, West Papua,

³Internist at RSUD Sorong, West Papua,

⁴Cardiologist at RSUD Sorong, West Papua

Background: Covid-19 is an infectious diseases that becomes a Pandemic worldwide. Covid-19 contributes to cardiovascular complication. Current research reported that 12% of patients with covid-19 have cardiovascular complication and higher mortality rate. One of the cardiovascular complication is Cardiogenic Shock.

Case Illustration: A-72-year-Old Man came to emergency room with shortness of breath since 3 days before admission. His vital sign showed tachycardia. His oxygen saturation is 55% in room temperature. Rhonci was found during auscultation. His chest X-Ray showed bilateral pneumonia. His ECG is normal. During hospitalization, patient was having ramdesivir and heparin. There's no significant improvement of patient's saturation although NIV had already given. On the 10th day, patient complained of chest pain. His blood pressure was 70 per palpation, and his ECG showed ST elevation on anterior part. Double anti platelet and dobutamine were given to patient. Patient undergo the second cardiogenic shock one week after the first attack, and patient died afterward. The most common cardiology manifestation in covid-19 is Miocarditis, Miocard Infarction, arrythmia, and cardiogenic Shock. The pathophysiology of cardiovascular manifestation in covid-19 is remain unclear, yet direct viral infection and inflammation in myocardium suspected to be the cause. Inflammation in myocardium causes disfunction of the myocytes. The Inflammation process also causes hypercoagulation which simplify the thrombus formation and make the risk for plaque rupture higher. Hypercoagulation becomes the foundation of anticoagulant administration for patient with covid-19, especially those who has comorbid diseases. In this case, although after admission of anticoagulant, patient's condition still worsen. Consequently, prevention of covid-19 is important.

Conclusions: Covid-19 also contributes to cardiovascular dysfunction, causing multiple cardiac complication such as cardiogenic Shock. Prevention of Covid-19 especially in elderly and people who has comorbid disease is important.



Management Of Supraventricular Tachycardia, Is There Any Place For Amiodarone?: A Case Report

A.N. Kalandoro¹, S. Madiastuti²

¹General Practitioner, Cibinong General Hospital, Bogor.

²Cardiologist, Cibinong General Hospital, Bogor.

Background: Supraventricular Tachycardia (SVT) is an arrhythmia that is often found in patients with symptoms, which management is divided into stable and unstable conditions. this case presents a stable SVT management with a limited first-line drug of choice.

Case Illustration: A 56 years old woman came to an emergency room with complaints of palpitation two hours prior to admission. There are no chest pain, shortness of breath, and sweating. Blood pressure is 117/62 mmHg, heart rate is 210 bpm, respiration rate is 22 per minute. History of cardiovascular disease is denied by the patient. Other physical examinations are normal. The electrocardiography (ECG) showed SVT, and a vagal maneuver was performed on the patient but no conversion. Pharmacological cardioversion using amiodarone 150 mg was given due to a lack of adenosine or other intravenous AVN-blocking agents such as beta-blockers or calcium channel blockers. The ECG post intravenous Amiodarone showed a conversion to sinus rhythm.

Conclusions: SVT is an arrhythmia that involves cardiac tissue at the level of the bundle of His or above. The prevalence of SVT is 2.25/1000 persons with a female predominance of 2:1 across all age groups. A 12-lead ECG and physical examination are critical to establish the diagnosis and guide the management. Vagal maneuver can be used to terminate an episode of narrow QRS SVT. The effectiveness of conventional vagal maneuver in terminating SVT, when correctly performed, has been reported as between 19 and 54%. Adenosine (6-18 mg i.v. bolus) is recommended if vagal maneuver fail. Calcium channel blockers (verapamil/diltiazem i.v.) and beta-blockers (e.g., esmolol and metoprolol i.v.) are the next drug of choice and have been shown to terminate SVT in 64-98% of patients. Amiodarone 150 mg intravenous was given to the patient due to the lack of drug of choice, and success converted to the rhythm even though it was not mentioned in the European Society of Cardiology 2019 Guidelines.

Keywords: Amiodarone, Pharmacological Cardioversion, Supraventricular Tachycardia.

Pulse Dose Corticosteroid Improves Clinical Outcome in Pulmonary Hypertension Patient: A Potential of Immense Affordability and Availability Medication in Suburban Area.

A. R. Sudirman¹, S. I. Sitompul²

¹General Practitioner, Dr Doris Sylvanus Hospital Palangkaraya, Kalimantan Tengah, Indonesia

²Cardiologist, Dr Doris Sylvanus Hospital Palangkaraya, Kalimantan Tengah, Indonesia

Background: Pulmonary hypertension (PH) in adolescence is a devastating diagnosis with significant morbidity and mortality. Despite limited literature exists on treating PH with anti-inflammatory medications in humans, hereby we present the case of prednisolone induced clinical outcomes improvement in PH patient.

Case Illustration: A 20-year-old woman presented with exertional dyspnea. Her past-two-years medical history was remarkable for tricuspid regurgitation with multiple readmission. Upon arrival, her saturation- 75% and BP-110/60. She was in respiratory distress with increased in JVP and high-pitched-holosystolic murmur. Laboratory studies was unremarkable. Her initial x-ray revealed cardiomegaly with PAH and ECG showing RVH and RAE.

Conclusions: Inflammation plays unequivocal role in the pathogenesis of PH, which was involved in the development of pulmonary vascular remodeling. The possible mechanism of prednisolone was related with the inhibition of platelet-derived growth factor (PDGF)-induced accelerated proliferation and migration of pulmonary artery smooth muscle cell, and prevented the activation of NF- κ B, a key transcription factor that controls inflammation, cell-proliferation, and apoptosis. Thus, given the ready availability and features of this medication compared with other PH- medication, we decided to utilize steroid in this patient.

Keywords: Pulmonary hypertension, prednisolone

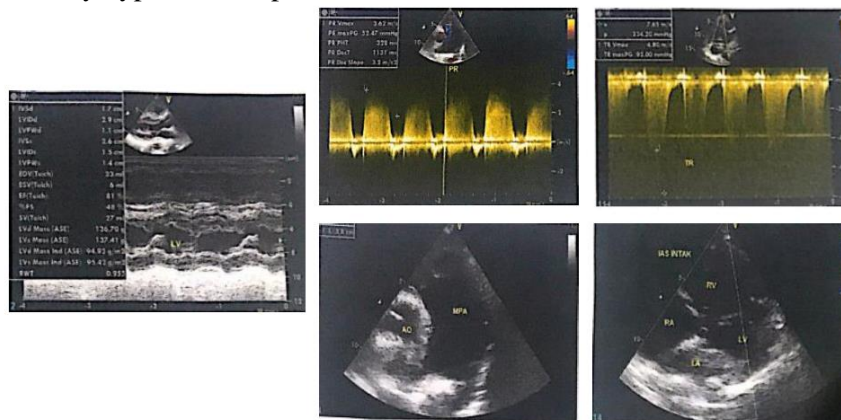


Figure 1. Initial echocardiography demonstrated TR-Vmax 4.55 m/s and PR-Vmax 3.62 m/s. The right ventricular systolic pressure was estimated around 107 mmHg, which was highly suggestive for pulmonary hypertension. PH caused by valvular heart disease was suspected. Due to the aggressive nature the disease, her condition deteriorated despite management with IV-furosemide-(40mg/d), beta-blocker-(2.5mg/d), and sodium beraprost-(60 μ g/d). Following days, a 5-days pulse-dose-steroid (methylprednisolone) at 2mg/kg/day was administered. Shortly after initiation, her condition improved with saturation from 50% to 90% and significant reduced in dyspnea. The steroid was tapering down for another 7 days and she was discharged for further referral.



Indonesian Journal of Cardiology

Indonesian J Cardiol 2021;42:suppl_C
pISSN: 0126-3773 / eISSN: 2620-4762
doi: 10.30701/ijc.1241



3D Ablation in 31 Years Old Man with Post Surgical ASD Closure Typical Atrial Flutter: A Case Report

A. Fauzan¹, A. C. Lubis², D. A. Hanafy³, A. N. Nasution⁴, H. Hasan⁵

¹Cardiology Resident at Cardiac Center H. Adam Malik Hospital, Faculty of Medicine Universitas Sumatera Utara, Medan, Indonesia ^{2,4,5}Cardiologist at Cardiac Center H. Adam Malik Hospital, Faculty of Medicine Universitas Sumatera Utara, Medan, Indonesia ³Cardiologist at National Cardiovascular Center Harapan Kita, Faculty of Medicine Universitas Indonesia, Jakarta, Indonesia

Background: Atrial tachycardias after surgical correction of congenital heart disease have proven better results for 3D mapping compared with conventional mapping technique due to the complex arrhythmogenic substrate and intricate macroreentrant circuits involving critical channels of slow conduction bordered by scattered scar tissue and/or anatomic boundaries. Atrial flutter is a form of supraventricular tachycardia due to re-entry in the macrocircuit that most often occurs in the right atrium. This case is the first 3D mapping and 3D ablation procedure in North Sumatera.

Case Illustration: A 31 years old male patient presented with palpitations due to history of ASD closure surgery was reported. 12 leads ECG showed Typical Atrial Flutter counter clockwise. From TEE thrombus was found attached along the LAA wall. Patient underwent 3D Electrophysiology Study with IntellaMap Orion catheter 8.5 F. The decapolar catheter is placed in the CS as a reference for impedance. Entrainment maneuvers were performed in the proximal CS and distal CS. Entrainment at C5p IN while C5D OUT with Right Sided AFL presentation. Then 3D ablation was performed.

Conclusions: Voltage mapping shows a scar in the RA septal area. Activation mapping shows activation corresponding to the CTI dependent Counter Clockwise Flutter. The voltage map option and the system's ability to depict scar regions allow delineation and estimation of the zones of the diseased tissue. An overdrive from RA was performed which successfully terminated the AFL. 3D mapping has been shown to offer advantages in delineating mechanisms and in guiding ablation of tachycardias after atrial septal defect.

Cardiac Memory After Narrow Qrs Tachycardia Attack : The Heart Reminds Us!

Thotuching A¹, Muzakkir A¹

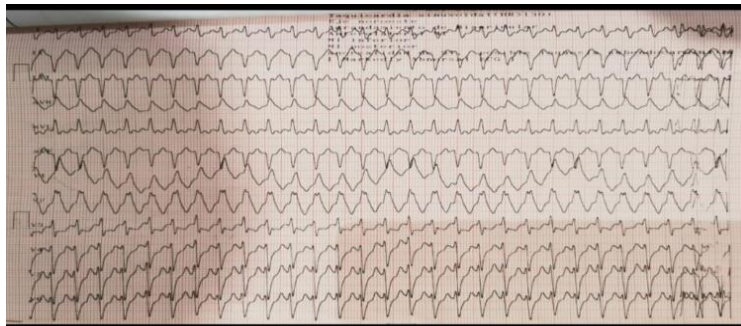
¹Department of Cardiology and Vascular Medicine, Faculty of Medicine, University of Hasanuddin
dr. Wahidin Sudirohusodo General Hospital, Makassar

Background: Cardiac memory is a phenomenon characterized by T wave changes on electrocardiogram (ECG) after a period of abnormal ventricular activation. Narrow QRS tachycardia is often considered as tachyarrhythmia of supraventricular origin. The presence of cardiac memory after resolution of a tachyarrhythmia attack can emphasize the diagnosis of Idiopathic Left Ventricular Tachycardia (ILVT) in Narrow QRS complex tachycardia.

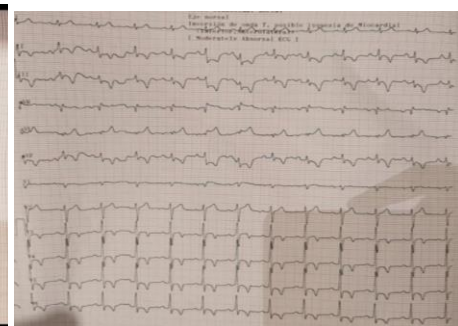
Case Illustration: We reported a 14-year-old boy with palpitation almost 2 days before admission to our centre. ECG showed narrow QRS complex tachycardia, regular, left axis deviation (LAD) and Right Bundle Branch Block (RBBB) morphology (Figure 1). Electrical cardioversion was done due to symptomatic hypotension. Then, ECG showed Sinus Rhythm, Normoaxis, T Inverted in lead II, III, aVF, V3-V6 (Figure 2). Based on the ECG, the diagnosis was likely ILVT-LPF. Echocardiographic examination showed false tendon type 4. The diagnosis of ILVT-LPF was confirmed on electrophysiological studies followed by successful ablation.

Conclusions:

ILVT-LPF is characterized during ECG by a RBBB pattern, LAD and relatively narrow QRS duration (127 ± 11 milliseconds). Although the criteria have been clearly described, it is often misinterpreted as Supraventricular Tachycardia (SVT) due to relatively narrow QRS duration. In our case, one of the important findings that emphasize diagnosis of ILVT is T changes in lead II, III, aVF, V3-V6 after electrical cardioversion. We conclude that T wave changes after resolution of the tachyarrhythmia are cardiac memory, suggested that there was previously an abnormal pattern of activation in the ventricles.



(Figure 1)



(Figure 2)

The criteria of cardiac memory after termination of ILVT as following : (1) positive T in aVL, (2) negative or isoelectric T in II, and (3) negative T in V₄₋₆ or (4) QTc < 430 ms. All of these criteria are met. The T wave axis on the frontal plane of cardiac memory approaches the direction of the abnormal QRS complex. The QRS complex of ILVT showed LAD. Therefore, the T wave of cardiac memory also showed LAD. Our patient had been experiencing tachyarrhythmia for almost 2 days. The longer duration of ILVT is associated with cardiac memory.

Congenital Junctional Ectopic Tachycardia in Neonate with Hyperthyroidism

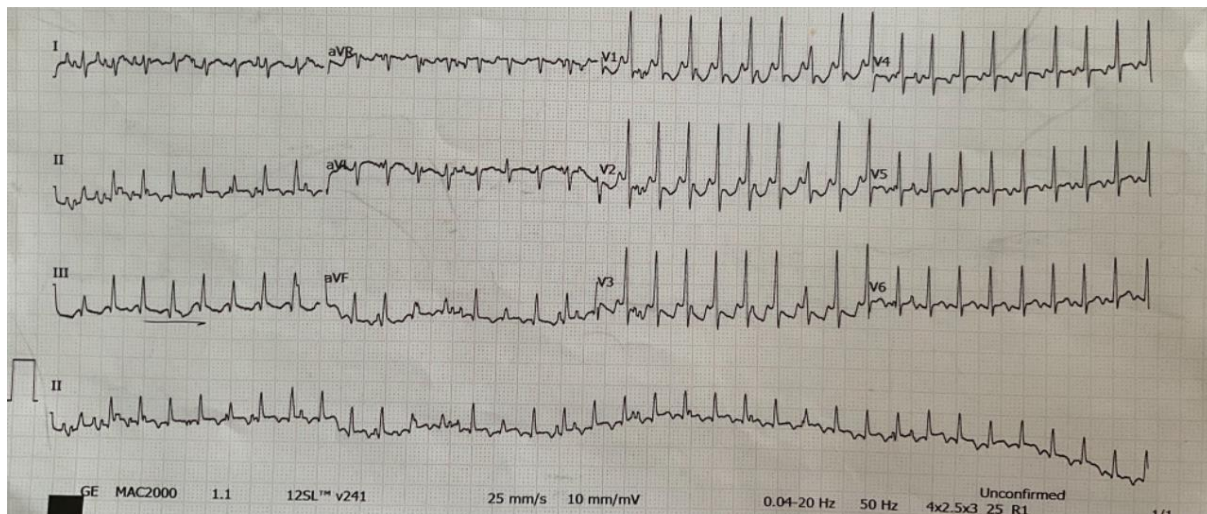
A.D. Prasetyo, D.W. Anggrahini, E. Maharani, I.K. Murni

Faculty of Medicine, Gadjah Mada University, D.I Yogyakarta, Indonesia, Dr. Sardjito General Hospital, Yogyakarta, Indonesia

Background: Junctional ectopic tachycardia (JET) is a rare arrhythmia presenting either as a primary or transient phenomenon following heart surgery. Congenital JET is a rare and usually occurs in the first six months of life as a persistent arrhythmia. Treatment strategies is challenging despite its fact of refracter of medical treatment and associated with high morbidity and mortality. We report a neonate with congenital JET who had hyperthyroidism and managed with propranolol and methymazol.

Case Illustration: An aterm (38 weeks) baby was delivered via emergency caesarean section. A routine antenatal care documented with heart rate of 200 bpm. Physical examination showed rate of 210 bpm with good peripheral pulses and perfusion. The respiratory system, cardiac and abdomen examination were normal. Echocardiogram revealed patent foramen ovale (PFO) with left to right shunt. Electrocardiogram (ECG) showed a narrow complex regular tachycardia with heart rate of 210 bpm (Figure 1). Thyroid function studies revealed hyperthyroidism. Patiens given propranolol 1 mg/kgBW/4 hours and methiamazole 0,5 mg/kgBW/24 hours. After 6 days of treatment, ECG still showed intermittent junctional rhythm with heart rate decrease into 140 bpm.

Conclusions: Congenital JET was first described by Coumel et al. in 1976. It defines as narrow complex tachycardia with evidence of AV dissociation or 1:1 retrograde VA condition. The mechanism is related to enhanced automaticity of the AV junction. One of the precipitating factors is hyperthyroidism. Acute therapy consists of propranolol as mono therapy and can combine with procainamide, verapamil, or procainamide, or flecainide. Amiodarone alone, or with propafenone or ivabradine, appears effective in managing congenital JET, but baseline thyroid function needs to observe during administration. Only one-third of cases can achieve complete or partial control of arrhythmia.





Indonesian Journal of Cardiology

Indonesian J Cardiol 2021;42:suppl_C
pISSN: 0126-3773 / eISSN: 2620-4762
doi: 10.30701/ijc.1241

Figure 1. ECG showing a regular narrow complex tachycardia with a heart rate of 210 bpm and evidence of A-V dissociation.

Transient AV Block During Catheter Ablation of CTI-Dependent

Counter-Clockwise Atrial Flutter: A Case Report

B. Dwiatmojo, F. Nicolas, A. Martin, M. Iqbal, A. Chaerul, G. Karwiky
Department of Cardiology and Vascular Medicine,
Faculty of Medicine Universitas Padjadjaran
Dr. Hasan Sadikin Hospital, Bandung, Indonesia

Background: Atrial flutter is one of the most common types of arrhythmias. Cavotricuspid isthmus (CTI) catheter ablation using radiofrequency (RF) energy is currently the first-line therapy for CTI-dependent atrial flutter. AV block is one of the complications that can occur, although rarely, during the RF CTI ablation procedure. This case report will present a patient with counterclockwise atrial flutter who successfully underwent a CTI RF ablation procedure but was accompanied by a transient complication of total AV block.

Case Illustration: A 58-year-old man came with symptomatic atrial flutter for which an AFL ablation procedure was planned. The activation mapping was noted earlier on CTI. Atrial flutter was successfully terminated by CTI ablation procedure. Second 3D mapping evaluation showed a residual gap in the CTI (CTI pouch). Further ablation was performed in the CTI pouch and a transient total AV block appeared (Figure 1.) which then spontaneously reverted to sinus rhythm. Overall, previous studies discussing RFA for the treatment of patients with atrial flutter reported a high efficacy rate with a low complication rate. Previous studies reported incidence rates of transient AV block ranging from 0.4% to 6%. AV block requiring pacemaker implantation after CTI radiofrequency catheter ablation is even less common, reported in 0.12% - 5% of patients. Injury to the AV node may have contributed to AV block in this case. Two other potential mechanisms are increased vagal tone and right coronary artery occlusion, but this does not appear to have occurred in this case.

Conclusion: AV node injury is a possible mechanism in this case. The placement of the ablation catheter position at the lateral isthmus location is expected to minimize this potential risk.

Keywords: Atrial flutter; Cavotricuspid isthmus; Radiofrequency ablation; Atrioventricular block

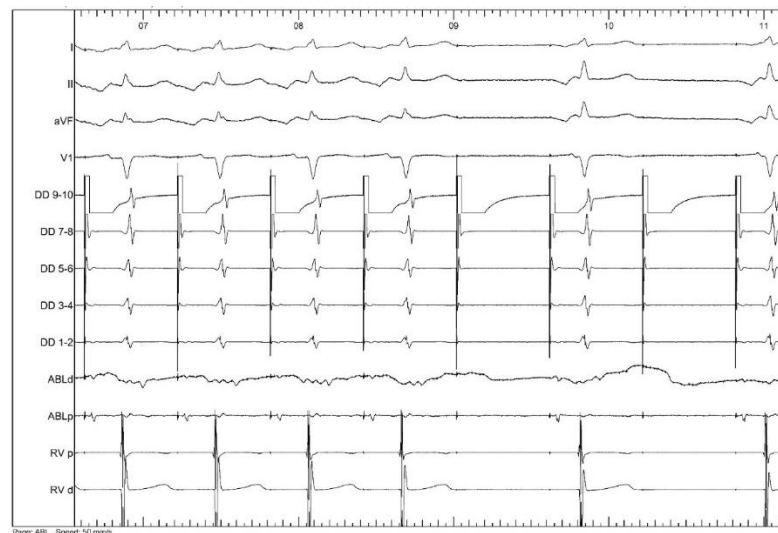




Figure 1. Transient total AV block during CTI pouch ablation.

Ventricular tachycardia and VPC RVOT septal origin : a Case Report

Mahmada, B.¹, Sulisty, N.A.², Sudiyoko².

¹ General practitioner, Tidar General Hospital, Magelang

² Cardiologist, Cardiology and Vascular Department, Tidar General Hospital, Magelang

Background: VPC originating from right ventricular outflow tract (RVOT) is the most common form of idiopathic ventricular tachycardia occurring in patients without organic heart disease, and idiopathic RVOT extrasystole are generally considered benign arrhythmias. We report a case of VPC RVOT type septal origin who developed nonsustained Ventricular tachycardia (VT). Patient undergoes successful ablation with EPS report showing a retrograde block with septal RVOT VT and VPC.

Case Illustration: We report our patient, a 30 years old Asian woman with history of VPC. She was clinically stable on medical therapy but developed dizziness and near syncope. Echocardiography showed a normal left ventricular ejection of 67%, normokinetics and mild Tricuspid Regurgitation. During outpatient echocardiography, patient undergoes nonsustained VT with stable hemodynamic.

Patient undergoes successful catheter ablation with EPS showing retrograde Atrioventricular block, normal SA and AV function, septal RVOT VT/VPC and successful ablation of septal RVOT VT/VPC.

Conclusions: It is particular importance to distinguish malignant form from benign form of idiopathic VT or VPCs since the malignant form of idiopathic VT or VPCs can often lead to unexpected sudden cardiac death. Noda et al suggested a significant difference in cycle length (CL) of VT between malignant and benign forms of RVOT VT. These suggest that a shorter CL during monomorphic VT as well as history of syncope with malignant characteristics, may predict of coexistence of malignant VF or polymorphic VT in patients with idiopathic VT originating from RVOT. In consideration of available evidence, it is needed to do a holter monitoring on patient with benign form of RVOT PVC with short CL interval and history of syncope.

Keywords: VT, VPC RVOT

Is It Possible for The Coexistence of Brugada Syndrome Type-1 and Arrhythmogenic Right Ventricular Dysplasia? : a Case Report

B. Mendel¹, R. Prakoso¹, S. N. Siagian¹

¹Division of Pediatric Cardiology and Congenital Heart Disease, National Cardiovascular Centre of Harapan Kita, Jakarta, Indonesia

Background: The coexistence of Brugada syndrome (BrS) and arrhythmogenic right ventricle dysplasia (ARVD) is possible. Their possible consequences made healthcare should be familiar with the electrocardiographic features.

Case Illustration: A 25-year old man presented with no complaints, but had episodes of syncope, chest pain, and palpitations 10 years ago. During examination, the ECG showed incomplete right bundle branch block, Brugada-type 1 pattern, with signs of Epsilon wave. However, his echocardiography showed no structural abnormality with good ventricular function. ARVD and BrS are distinct clinical entities with respect to both clinical presentation and genetic predisposition. In contrast to BrS, imaging techniques such as echocardiography in patient with ARVD showed right ventricular morphological and functional changes. Clinically, there is some crossover between these conditions, and some researchers reported that BrS is a form of ARVD. It is possible, given the fact that in early stage of ARVD, fatty deposits could be so minimal that it is undetectable.

Conclusions: This patient should underwent electrophysiology study and further imaging examination to observe the likelihood of these diseases and suitability for implantation of ICD.

Keywords: Brugada syndrome, Epsilon wave, case report, sudden cardiac death

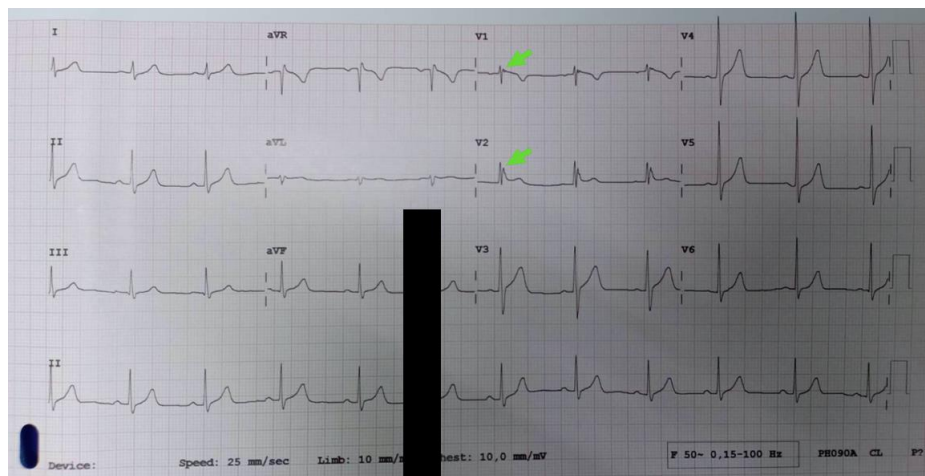


Figure 1. Previous ECG showed fragmented QRS complex with incomplete right bundle branch block (Rsr'), coved-shaped ST elevation pattern with J-point elevation of 1 mm, gradually descending ST segment and T inversion with Epsilon-like pattern in the anterior precordial leads indicated by the green arrow.

Arrhythmia induced by Tricyclic Antidepressant Drugs in anxiety disorder patient : a case report

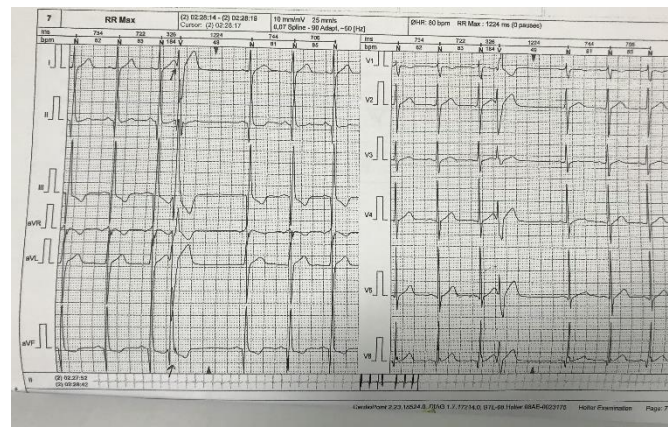
Octavani C¹, Wulandari P², Hakim A²

^{1,2}Badan Pengusahaan Hospital, Batam, Indonesia

Background: Palpitation is one of the most common symptoms in psychiatric disorder. However, frequently this symptom is missed out with its correlation in the effect of psychotropic drug. Several studies have demonstrated the link of anti psychotic drugs with cardiovascular effect. Amitriptyline is a Tricyclic Antidepressants drug that is reported to have disturbance in the electrophysiological properties of the heart. In ECG reported with prolongation of the PR, QRS and QT intervals, nonspecific ST segment and T wave changes, AV block, right axis deviation and the Brugada pattern are observed.

Case Illustration: A 29 years old male patient presented with chief complain of palpitation since the last 1 month. Patient had a history of anxiety disorder and was in routine medication with amitriptyline. He reported that he had been feeling extra skip beat especially during exercise and his heart rate can reach up to 140x/min. Patient was advised for a 24 hour Holter Monitoring. The result was infrequent PVC with R on T phenomenon (shortest CI 340 msec). Holter follow up was conducted after 1 month cessation of Amitriptyline found normal sinus rhythm without PVC.

Conclusions: Amitriptyline acts in blocking the hERG human cardiac potassium channel which contribute to arrhythmogenic side effects. In our report, infrequent PVC with R on T phenomenon (shortest CI 340 msec) was seen. Holter follow up was conducted after 1month cessation of amitriptyline revealed with normal sinus rhythm without PVC. Based on the algorithm in indication for treatment of psychiatric medications, ESC classified amitriptyline into class B drug with the risk of developing arrhythmia. Prior assessing cardiac risk factor is necessary upon therapy and a follow up heart check up after 1-2 weeks of drug initiation should be done. Missed out intervention in cardiac problems among psychiatric patients remain high. Therefore, we should never under look the symptomatic complaint of psychiatric patients and highly recommend on a careful observation of patient with amitriptyline medication in the presence of arrhythmia symptoms. Re-evaluation of ECG or Holter monitor should be performed.





A Case of Myocardial Bridging complicated by Postural Tachycardia Syndrome in Young Adult

C. A, Maulana¹, A. P. Pratama¹, I. Puspita¹

¹Department of Cardiology and Vascular Medicine – Mohammad Hoesin General Hospital Palembang

Background: Chest pain is a discomfort feeling on the trunk, commonly resulted by myocardial ischemia (MI). MI develop due to imbalance between the supply and demand of oxygen. Myocardial bridging (MB) is one type of MI where the coronary artery, that normally lie through the surface of epicardium, deepen intramurally into the myocardial walls causing the narrowing of the lumen on systolic phase leading to myocardial ischemia and chest pain. Postural tachycardia syndrome (POTS) is an orthostatic tachycardia characterized by increased heart rate ≥ 30 bpm without symptoms of orthostatic hypotension.

Case Illustration: A 22-year-old man admitted due to prolonged chest pain, palpitation. Physical examinations were within normal limits. Electrocardiography (ECG) was normal yet holter monitor showed POTS in a form of supraventricular tachycardia (SVT). Normal LV and RV function was found from echocardiography. Cor-angiography was decided and showed mild MB at proximal and distal part of left anterior ascending (LAD) artery.

Conclusions: Although ECG and echocardiography respectively showing normal result, we found MB at LAD through cor-angiography and POTS during holter monitoring. MB and POTS are both rare diseases, when they co-exist, they present a therapeutic challenge and a pathogenic overlap. Tachycardia could worsen MB effect in causing MI and MB could lead to MI and further induce tachycardia. Despite the young age, MB and POTS could cause inadequate heart recoil and lumen dilatation resulting in imbalance between supply and demand of oxygen that leads to MI.

Keywords: Chest Pain, MB, POTS.



A Supraventricular Tachycardia Episode in a Patient with the History of Wolf Parkinson White Syndrome

D. H. Pradipta¹, W. Hastuti², B. A. Pramono³

¹General Practitioner Panembahan Senopati Hospital

²General Practitioner Panembahan Senopati Hospital

³Cardiologist Panembahan Senopati Hospital

Email: d.h.pradipta@gmail.com

Background: Wolf Parkinson White syndrome (WPWs) is characterized by the present of an accessory pathway between the atrium and ventricles which allow an alternative route for ventricular depolarization. Although the patients with WPWs are mostly remain asymptomatic, but some are predisposed to have a life threatening tachyarrhythmia episode and need a right treatment. This case will show the episode of supraventricular tachycardia (SVT) related WPWs and its history of another episode of Atrial Fibrillation with Rapid Ventricular Respond (AFRVR).

Case Illustration: A 55 year old male was administered to the emergency room with palpitation. The patient was fully alert, blood pressure was 140/70 mmHg, heart rate 208 bpm, SpO₂ 94%, no rales on both lungs, and no signs of shocks. The echocardiography (ECG) showed SVT. The patient got administered Diltiazem 15mg IV bolus, and the rhythm was converted to a sinus with a delta wave pattern and ventricular premature beats. Two years before the case, the patient was diagnosed with AFRVR with WPWs, Non ST Elevation Myocardia Infarct, and required electrical cardioversion. The patient transferred to a referral hospital to get an ablation for further treatment. According to the patient, the ablation was failed.

Conclusions: In this case, associated with the WPWs, the patient has developed SVT and also had a history of AFRVR. One of the effective pharmacological treatment for SVT with WPWs is a calcium channel blocker. This patient got administered Diltiazem 15mg IV bolus to terminate the SVT because there was no sign of any instability on the examination. During sinus rhythms, WPWs causes characteristic ECG appearance like short PR interval, delta wave, wide QRS complex, as shown in this patient right after administration of Diltiazem. Although the outcome was good, this patient should be referred for another electrophysiology study to find the accessory pathway because the patient had a history of AF Rapid Ventricular Respond which require electrical cardioversion.



Electrocardiogram manifestation in profound hypokalemia masquerading myocardial ischemia: an emergency general practitioner's perspective

D. Ulfiarakhma¹,

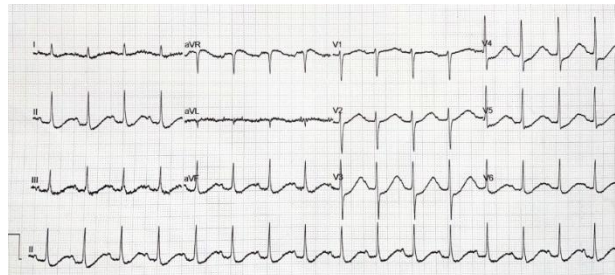
¹General Practitioner, Lahat General District Hospital, Lahat,
South Sumatera

Background: Hypokalemia is one of the commonly encountered electrolyte disturbances. The physician in emergency room should be aware of ECG changes caused by hypokalemia, as it might lead to arrhythmia if left untreated.

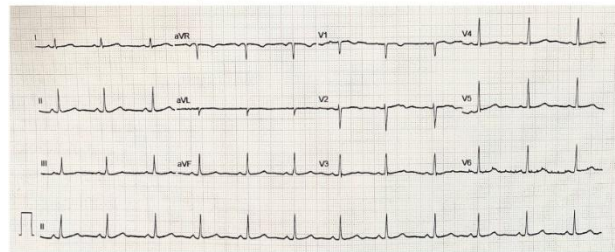
Case Illustration: A 27-year-old non-pregnant woman presented with nausea and severe vomiting. She also complained chest discomfort spreading from chest to the neck. The pulmonary and cardiac examinations were unremarkable. ECG showed upsloping ST-depression in leads II, III, aVF, V3-V6; and corrected QT interval prolongation at 582 ms. Patient was initially suspected with myocardial ischemia. A detailed history taking revealed that patient had been suffered from vomiting since two weeks and functional dyspepsia for two years. On neurologic examination, she demonstrated a slow gait. Laboratory values revealed potassium of 1.2 mmol/L and CKMB levels were within normal limits. So the diagnosis of severe hypokalemia was made. Intravenous potassium chloride (KCl) 50 mEq over 5 hours were administered with continuous cardiac monitoring. Patient was discharged 7 days after admission with normal serum electrolyte levels and ECG

Conclusions: Hypokalemia results in slowed conduction, delayed ventricular repolarization, shortened refractory period, and increased automaticity which can lead to ST-T segment changes and QT prolongation on ECG. Hypokalemia induced ST depression might mimic in those of myocardial ischemia, and its interpretation might be difficult when accompanied with chest discomfort. In our patient, normal CKMB level and normalization of ECG findings after potassium correction suggests that ECG abnormalities on admission were secondary to severe hypokalemia.

Keywords: Hypokalemia, electrocardiogram, ST depression



a. ECG on admission showed up sloping ST depressions in leads II, III, aVF, and V3-V6 with QTc interval prolongation at 442 ms. Serum K⁺ level: 1.2 mmol/L.



b. ECG on day 7 after correction of hypokalemia showed normal sinus rhythm with improvement in ST-segment depression and decreased QT prolongation. Serum K⁺ level: 3.4 mmol/L.

A Case Report: Total Av Block, Anterior Stemi, Right Bundle Branch Block in Young Woman with Covid-19 Infection

DP Burnama¹, IF Fiska²

¹General Practitioner, Semen Padang Hospital, West Sumatera, Indonesia

²General Practitioner, General Hospital of Padang Panjang, West Sumatera, Indonesia,

Background: The outbreak of corona virus disease 2019 (COVID-19) has progressed to a global pandemic. COVID-19 not only causes respiratory problems but also other systems such as cardiovascular. There are complications with or without prior cardiovascular disease.

Case Illustration: A-22-year-old female came to the emergency room due to vomit for 2 days, fatigue, dizziness, and middle chest pain. Physical examination found BP 100/70 mmHg, HR 40 x/minutes. The ECG showed a Total AV Block and received dopamine drip start from 5 mcg/kg. The patient cannot be referred for pacemaker procedure because the referral hospital was full. The laboratory showed an elevation Troponin-I and chest X-ray was normal. The ECG was repeated several times and showed an elevation of ST-segment in lead V1 and V2, also wide QRS showed Right Bundle Branch Block (RBBB). Loading Clopidogrel and Aspilet was given to this patient. The patient went for a fibrinolytic procedure using drip of Streptokinase 1.5 million IU. COVID-19 antigen test showed positive. During fibrinolytic, the patient went to sudden cardiac arrest so CPR procedure was performed then patient went to ROSC. Patient admitted to isolation Intensive Care Unit. The PCR sample for COVID-19 showed positive the next day. The patient fully recovered after 10 days of hospitalization.

Conclusions: Manifestations of cardiovascular can be found in a patient with COVID-19 infection. Possible etiology involves inflammatory surge from the cytokine storm. Cytokine storm leads to severe microvascular, macrovascular endothelial, and myocardial dysfunction that evolves into acute coronary syndrome and even arrhythmia.

1.

Keywords: COVID-19, Total AV block, Anterior STEMI, RBBB

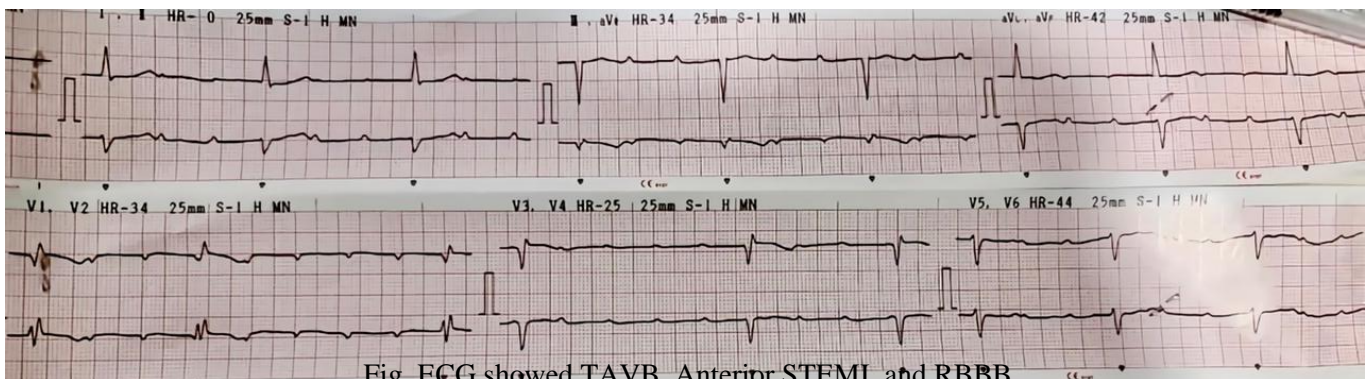


Fig. ECG showed TAVB, Anterior STEMI, and RBBB



Brugada Syndrome with chest pain as clinical manifestation: Case Series

D. P. Andryan, M. F. Adam, D. Y. Hermanto¹

¹Department of Cardiology and Vascular Medicine, Faculty of Medicine Universitas Indonesia, National Cardiovascular Center Harapan Kita, Jakarta, Indonesia

Background: Brugada syndrome (BrS) is an inherited condition responsible for ventricular fibrillation (VF) and sudden cardiac death (SD) and currently defined by the presence of type 1 ST elevation in the right precordial leads and not related to any structural heart disease. The initial of BrS diagnosis are diverse, from asymptomatic to nocturnal sudden cardiac death. Chest pain is a clinical feature that is considered less typical for a BrS.

Case Illustration: A 26 yo man, came to outpatient clinic with history of syncope and chest pain. From ECG finding showed ST elevation in V1-V3 with camel humpback appearance. He previously admitted due to chest pain episode, suspected with STEMI. He got no any risk factor of CAD. Lab showed normal serial troponin level and normal echocardiogram, not showing any regional wall motion abnormality or reduced contractility. The patient was suspected with Chest pain related to Brugada pattern type 2. Patient underwent Ajmaline test, the results was positive. The patient underwent ICD implantation (Medtronic Protecta XT VR) afterwards.

A 30 yrs patient was referred to our expectations with a referral for a diagnosis of STEMI due to clinical chest pain and ST elevation V1-V3. Troponin results were normal, echocardiography did not show RWMA. The ECG results showed a Brugada pattern type 2. The patient was then performed an ajmaline test with a positive result.

Conclusions: Chest pain is a clinical manifestation that should be considered when diagnosing BrS. Myocardial ischemia and vasospasm related to vagal are suspected to have a role in BrS with chest pain.

Keywords : *brugada syndrome, chest pain, sudden cardiac death*



Sustained Ventricular Tachycardia (VT) in Patient with Implantable Cardioverter Defibrillator (ICD): What's wrong with it?

E. K. Rofiah¹, R. I. Rismawanti², A. E. Radittyanto¹, M. U. A. Jomansyah¹

¹JIH Hospital Yogyakarta, Indonesia

²Faculty of Medicine, Public Health and Nursing, Universitas Gadjah Mada, Yogyakarta, Indonesia

Background: Ventricular Tachycardia (VT) is considered as a malignant arrhythmia that most commonly cause sudden cardiac death. Sustained VT is characterized by VT that lasts for ≥ 30 seconds and can be hemodynamically stable or unstable. Implantable Cardioverter Defibrillator (ICD) is the best treatment of choice for unstable sustained VT. However, several factors can still cause ventricular tachycardia in patients with ICD.

Case Illustration: A 62-year-old male patient came to the emergency unit complaining persistent palpitation since the past several hours accompanied by diaphoresis. Chest angina and dyspnea were ignored. Since 2009, he had ICD implantation and was routinely treated by Loprolol 2x25mg and Loprolol 25mg-0-50mg, alternatingly. Nevertheless, he did not continue his routine control and therapy for the past 8 months because he has been feeling better and had not undergone ICD battery replacement since 2009. He had Diabetes Mellitus Type 2 and hyperuricemia on therapy. On arrival in ER, he was fully conscious, BP: 80/53 mmHg, HR: 206 x/m palpable, RR: 20, SpO₂: 100% RA. Physical examination was normal. First ECG finding was VT HR 210x/m. The patient was then diagnosed with unstable VT on ICD and was managed aggressively in the ER. The ECG was then converted, patient was stable hemodynamically, and observation was continued in Intensive Care Unit.

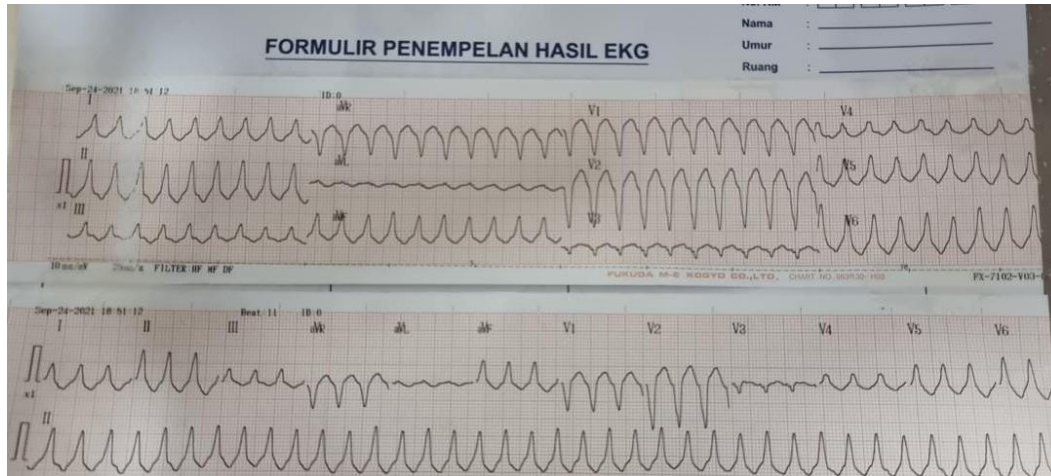
Conclusions: Patients with sustained unstable VT are at high-risk of sudden cardiac death. ICD implantation has been considered to effectively reduce the mortality rate in the high-risk group. However, VT is still possible to occur upon ICD implantation. For this case, there are at least 2 factors contributing to this event, first, there is reentry mechanism from cardiac tissue scar that produce new focal arrhythmia. Second, the ICD is malfunctioned due to run out of battery (end-of-life ICD), undersensing, electromagnetic interference (EMI), or lead fracture. Therefore, routine and careful monitoring of patient and device conditions are important in ICD-implanted patients.

Keywords: ventricular tachycardia, implantable cardioverter defibrillator



Indonesian Journal of Cardiology

Indonesian J Cardiol 2021;42:suppl_C
pISSN: 0126-3773 / eISSN: 2620-4762
doi: 10.30701/ijc.1241





Lidocaine As A Potent Antiarrhythmic For Prolonged Ventricular Tachycardia When Electrical Cardioversion Could Not Be Performed: A Case Report In Rural Area

E. Siregar¹, Y. S. Situmorang²

¹General Practitioner, Cut Meutia Hospital, North Aceh, Indonesia

²Cardiologist, Cut Meutia Hospital, North Aceh, Indonesia

Background: Lidocaine is a class IB antiarrhythmic drug, a sodium-channel blocker that acts to shorten the refractory period. It may be used as an alternative to amiodarone managing recurrent or shock refractory ventricular fibrillation/tachycardia (VF/VT). According to the Advanced Cardiac Life Support (ACLS) guideline, lidocaine is intended to be prophylactic antiarrhythmic for cardiac arrest with VF/VT.

Case Illustration: We report the case of a 61-year man with four days history of chest pain and palpitation. Upon arrival, he is alert with BP 110/80 mmHg, HR 150/min, RR 17/min, without a sign of shock. The ECG showed monomorphic ventricular tachycardia, he received intravenous (IV) amiodarone 150 mg, but no response was noted. The patient was admitted to intensive care with continuous amiodarone. On the second day of admission, VT still presents. Electrical cardioversion was planned, but the patient refused to do so. On the third day, 1mg/kg lidocaine was given by slow bolus and maintenance. The rhythm was converted to sinus 12 hours later. Still, it showed a new left bundle branch block consistent with ST-elevation myocardial infarction (STEMI) according to Smith-modified Sgarbossa criteria, and troponin level was elevated. We treated the patient with standard acute coronary syndrome protocol therapy, and he refused to be referred for an immediate invasive strategy. After four days of follow-up, the patient remained clinically stable and was discharged from the hospital.

Conclusions: A wide complex tachycardia may represent either VT (80%) or a supraventricular rhythm with aberrant conduction (20%). This patient's Wide QRS complex represents a VT, according to Brugada and Vereckeï algorithm. Based on the ACLS guideline, each unstable VT with a pulse should be given synchronized cardioversion; however, when such action could not be performed for various reasons, intravenous lidocaine might serve as a possible treatment.

Idiopathic Left Ventricular Tachycardia Posterior Originating from Left Posterior Fascicle in Young Man

F. Siddiq¹, D.W. Anggrahini², E. Maharani²

¹Resident of Cardiology and Vascular Medicine, Faculty of Medicine, Public Health and Nursing, Gadjah Mada University, Yogyakarta, Indonesia

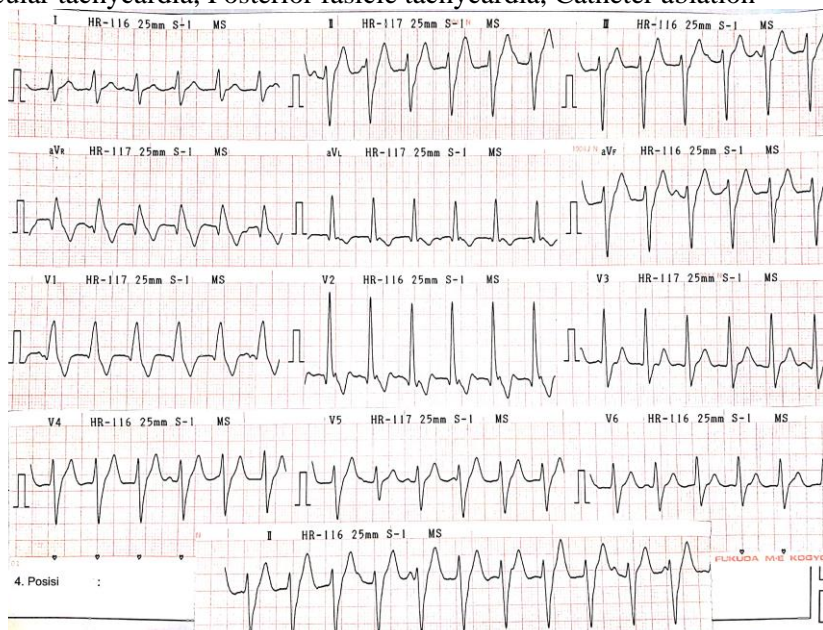
²Staff of Cardiology and Vascular Medicine, Faculty of Medicine, Public Health and Nursing, Gadjah Mada University, Yogyakarta, Indonesia

Background: Most ventricular tachycardias encounter in clinical practice occur in patients with structural heart disease. Idiopathic left ventricular tachycardia represents almost 10% to 15% of idiopathic ventricular tachycardia related to the left ventricle. We report a case of a 20-year-old male with idiopathic left ventricular tachycardia from posterior fascicle.

Case Illustration: A 20-year-old man was admitted to Emergency Room (ER) due to episode of palpitation. Clinical examination was unremarkable. His blood pressure was stable at 120/80 on admission and his pulse was 140 beats/min. ECG showed right bundle branch block morphology, corresponding to the left ventricular origin. It has left superior frontal plane axis and relatively narrow QRS duration. He was given verapamil and the ventricular tachycardia was terminated. Echocardiogram showed no structural heart disease. He was continued on regular dose of oral calcium channel antagonist. Catheter ablation was performed with successful result.

Conclusions: ILVT also known with verapamil sensitive tachycardia. Seen in second to fourth decade of life and occurs more often in man. Symptoms during tachycardia include palpitations, dizziness, presyncope, and syncope. Mechanism of tachycardia is focal reentry due to area of slow decremental conduction in Purkinje fibres. The reentry circuit has been demonstrated to be confined to the left posterior Purkinje network. This tachycardia has RBBB morphology with left axis configuration. The use of calcium-channel blockers, particularly verapamil, is effective for ILVT. Radiofrequency catheter ablation has successful rate up to 85% in resistant or incessant ILVT.

Keyword: Ventricular tachycardia, Posterior fasicle tachycardia, Catheter ablation





Indonesian Journal of Cardiology

Indonesian J Cardiol 2021;42:suppl_C
pISSN: 0126-3773 / eISSN: 2620-4762
doi: 10.30701/ijc.1241

Figure 1. ECG at Emergency Room



**Identification of Deceleration Zone using Isochronal Late Activation Mapping:
A Functional Substrate Mapping during Sinus Rhythm of Scar-related VT
in Ischemic Cardiomyopathy**

Hidayati, F.^{1,2}, Raharjo, S.B.², Hermanto, D.Y.², Hanafy, D.A.², Yuniadi, Y.²

1. Department of Cardiology and Vascular Medicine, Faculty of Medicine, Public Health and Nursing, Universitas Gadjah Mada, Indonesia/RSUP Dr. Sardjito Yogyakarta Indonesia
2. Department of Cardiology and Vascular Medicine, Faculty of Medicine, Indonesia University, Indonesia/National Cardiovascular Center Harapan Kita Jakarta Indonesia

Background: Scar-related ventricular tachycardia (VT) is the most common cause of sustained VT in patient with structural heart disease such as myocardial infarction. Since most VT causes hemodynamic instability, sinus rhythm (SR) surrogates for critical sites of re-entry are highly desirable. Isochronal late activation map (ILAM) identifies the entry sites into the latest regions of ventricular activation during sinus over 8 isochrones. Regions of isochronal crowding defined as deceleration zone (DZ) typically harbours VT critical isthmus. Targeted ablation guided by high-density ILAM during SR is feasible and effective.

Case Illustration: A 59-year-old male patient with history of myocardial infarction and coronary artery disease came to emergency room due to worsening of dyspnoea on effort. Electrocardiography showed sustained VT with right bundle branch block (RBBB) morphology, superior axis, late reverse precordial R-wave progression pattern in V6, dominant R in I and aVL. During interrogation of implantable cardioverter-defibrillator (ICD), VT storm was noted. Guided by sinus ILAM, DZ were identified around midseptal left ventricle. Multiple radiofrequency ablation (RFA) were delivered with irrigating catheter at the DZ area and successfully terminated the VT. Following this, the clinical VT was not inducible anymore. The procedure was concluded with successful ablation of midseptal left ventricular VT. Three months follow up showed 3 episodes of non-sustained VT.

Conclusions: ILAM, a voltage-independent high-density mapping, identifies functional substrate and guides targeted ablation. In our case, localization of DZ resulted in successful targeted RFA application and there was no need for homogenization of the scar, rendering a faster and safer procedure.

Keywords

Ventricular tachycardia; Catheter ablation; Isochronal late activation mapping; Deceleration zone.

Inferoposterior STEMI with total AV block management in a non-PCI center hospital: a case report

G. I. Kairupan¹, A. Hidayatullah²

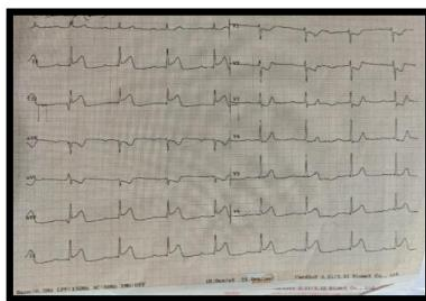
¹General Practitioner, Hermina Arcamanik Hospital, Bandung, West Java – Indonesia

²Cardiologist, Hermina Arcamanik Hospital, Bandung, West Java – Indonesia

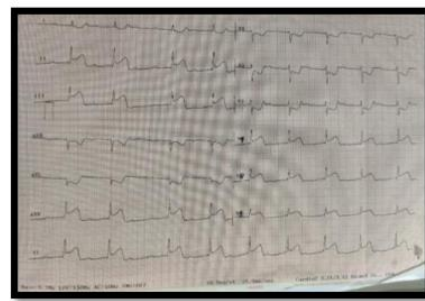Background: Ischemic injury can produce conduction block at any level of the cardiac conduction system. Such blocks result in various grades of AV block. AV block associated with inferior wall infarction may resolve spontaneously or needing reperfusion. Fibrinolytic therapy is an important reperfusion strategy in settings where primary PCI cannot be offered in a timely manner.

Case Illustration: A 49-year-old male came to the ER of a non-PCI Center Hospital with a left-sided typical anginal chest pain 30 minutes prior to admission. Patient was alert, with BP of 90/60 mmHg, pulse rate of 50 times per minute, RR of 20 times per minute, and afebrile. Other exams finding were normal. 12-lead, right-sided and posterior ECGs showed inferoposterior STEMI with total AV block. Troponin-I result was 51.9 ng/L. Patient was planned to be referred to a PCI Center Hospital, but refused the option. Hence, he was planned to undergo fibrinolysis using streptokinase. Fibrinolysis resulted in ECG conversion to sinus rhythm and patient was given antiplatelet and anticoagulant therapy afterwards. Patient's condition improved and was discharged after 5 days of hospitalization.

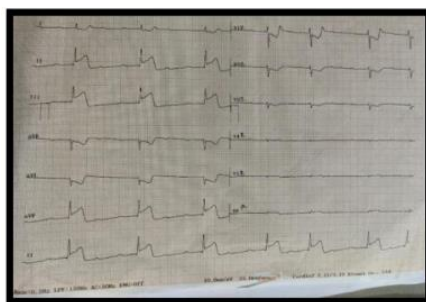
Conclusions: Fibrinolysis can recanalize the thrombotic-occluded vessel associated with STEMI, restoration of coronary flow reduces infarct size resulting in improved myocardial function and short- and long-term survival. High-grade AV block with inferior/posterior STEMI usually is transient and can be managed conservatively.



(A)



(B)



(C)

Figure 1. ECG of the patient (A) 12-lead ECG; (B) posterior ECG; (C) right-sided ECG upon arrival to the ER



Look Deeper into Thyrotoxicosis Atrial Fibrillation: A Case Report

H. Khairunnisa¹, R. Kurniawan², D. Fitriani², D. G. Arilaksono³

¹Emergency Department at Depok District General Hospital, Indonesia

²Internal Medicine Department at Depok District General Hospital, Indonesia.

³Cardiovascular Department at Depok District General Hospital, Indonesia.

Background: Atrial fibrillation (AF) is one of the thyrotoxicosis manifestations with a prevalence to be in the range of 16% to 60% in hyperthyroid patients. It is well known that hyperthyroid is associated with the increase of worsening of preexisting heart disease, but hyperthyroid, by itself, can also cause cardiac diseases.

Case Illustration: A fully oriented 37-year-old-female with no history of traditional risk factors of heart disease was admitted to our hospital with chest discomfort worsening over the past 3 days. The electrocardiograph showed AF with a heart rate approaching 185 bpm, blood pressure 121/84 mmHg. The heart rate persisted above 120 bpm after 2 doses of digoxin intravenous. Clinical manifestations of hyperthyroid and heart failure with elevated free thyroxine and suppressed thyroid-stimulating hormone were found. Due to the thyrotoxicosis AF, rate control and anti-thyroid agent were given. In addition, the echocardiograph showed left and right atrium dilatation with mitral regurgitation and tricuspid regurgitation. Based on CHA2DS2-VASC (2 points), warfarin was given as an anticoagulant to prevent thromboembolic events with close bleeding risk monitoring. After 3 days of hospitalization, the AF rhythm converted to sinus rhythm.

Conclusions: In this case, the patient had overt hyperthyroidism with clinical manifestations of thyrotoxicosis. The patient denied any traditional risk factors of heart disease thus we estimated that AF and abnormalities of heart structure founded by echocardiography were caused due to thyroid heart disease. Hyperthyroid can cause AF, and chronic AF, in some theories, can cause atrium dilatation through several mechanisms. Based on the underlying mechanism, the therapeutic targets, in this case, were to achieve a normal heart rate (rate control) and euthyroid state. Rhythm control isn't usually recommended in such cases because normal sinus rhythm can be achieved after the euthyroid state. In addition, the choice of anticoagulants in thyrotoxicosis AF is per the clinician's decision.

Comparing the risk prediction of cardiovascular complications in pregnant women with heart disease using CARPREG I VS CARPREG II score VS ZAHARA score: a case based study

H. Hendsun¹, D. Dickson¹, A.K. Dewi², A. Adrianus³,

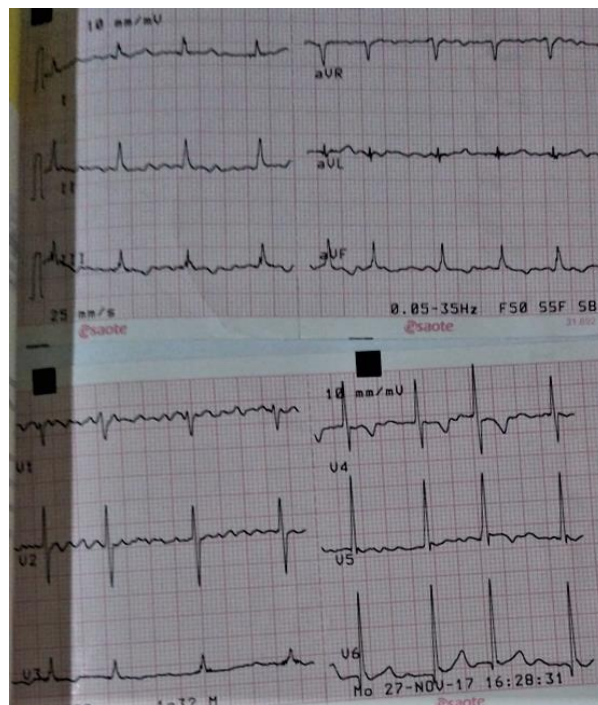
¹General Practitioner, Tarumanagara University, Jakarta, Indonesia; ²Obstetric and Gynecologist, Sumber Waras Hospital, Jakarta, Indonesia; ³Cardiologist, Sumber Waras Hospital, Jakarta, Indonesia

Background: Pregnancy produces significant hemodynamic changes that may not be well tolerated in women with heart disease, especially in whose heart function has been disrupted before their pregnancy. Many scoring system further advances and improves our ability to predict risk by using a combination of factors. This study aims to compare the risk prediction of cardiovascular complication based on the case of a pregnant woman with heart disease.

Case Illustration: A 33-year old pregnant woman presented to Obstretician to do routine check up for the 13th weeks pregnancy with the history of atrial fibrillation, chronic heart failure, and post balloon mitral valvuloplasty. No complaints occurred during the check up. Vital sign shows pulses 100 x/m with irregular rhythm. Obstetrics examination revealed as normal. Cardiopulmonary examination shows 3/6 grade diastolic mitral murmur, ECG shows asinus and irregular rhythm, with echocardiography showed MVA 1,26m². The patient was diagnosed with G2P1A0 13th weeks pregnancy with persistent atrial fibrillation, moderate mitral stenosis and history of Balloon Mitral Valvuloplasty.

Conclusions: the CARPREG I, CARPREG II, and ZAHARA risk score was used to calculate the mortality risk of this patient. CARPREG I risk score shows cardiac complication by 75%, CARPREG II risk score by 41%, and ZAHARA risk score by 43.1%. The difference between CARPREG I VS CARPREG II is 34%, CARPREG I VS ZAHARA II is 31.9%, CARPREG II VS ZAHARA is 2.1%. Antenatal care in women with heart disease requires greater attention and conjunction care between cardiologists and obgyn. The CARPREG I risk index has been widely used, independently validated, and expanded by others in an attempt to improve risk prediction for their patient population, yet is the least well in predictive capacity. The ZAHARA risk score was a weighted risk score that included components of the CARPREG I risk index. Antenatal care in women with heart disease requires greater attention and conjunction care between cardiologists and Obgyn.

Keywords: Atrial Fibrillation, Scoring System, Womens' Cardiology



Late Onset Permanent Pacemaker Pocket Infection in Elderly Female with Diabetes Mellitus

Citra I¹, Sarayar AM¹, Rantung NOH¹, Setiadi BM²

1 Cardiology Resident of Sam Ratulangi University, Faculty of Medicine

2 Department of Cardiology and Vascular Medicine, Sam Ratulangi University, Manado

Background: Late onset permanent pacemaker (PPM) pocket infection can occur after six months in about one percent of PPM implantation. This condition could result in higher morbidity and mortality due to risk of endocarditis. Intravenous antibiotic administration followed by pacemaker extraction remains as the current definitive therapy.

Case Illustration: A 67-year-old diabetic woman was admitted with chief complaint of pus over the wound above PPM generator site since two days beforehand, accompanied by erythema and localized pain. Permanent pacemaker was implanted two years prior with indication of total atrioventricular block. Her resting ECG revealed pacing rhythm. Her laboratory result was unremarkable beside poor glycaemic control with HbA1C level 11.1%. Pus and blood culture showed no bacteria colonization. Transthoracic echocardiography revealed no valvular and lead vegetation. Following six days of intravenous ceftriaxone and oral clindamycin administration, PPM extraction and temporary pacemaker implantation were performed (Fig. 1). Tissue culture that was obtained during debridement in pocket area also showed no bacteria colonization. After five days of intravenous vancomycin administration, PPM reimplantation was performed on contralateral side.

Conclusions: Late onset pacemaker pocket infection possesses a great risk to systemic involvement and development of endocarditis. Early detection of infection and awareness for risk factors are necessary to prevent hospitalization and further complication due to PPM pocket infection. Risk factors include previous infection, diabetes mellitus and age above 60-year-old. Infections are generally caused by Gram-positive bacteria, namely *Staphylococcus aureus*, which can be confirmed by pus, blood and tissue culture examination. Negative culture may result from Gram-negative bacteria involvement including HACEK organisms. Aside from broad spectrum intravenous antibiotic administration, PPM extraction is definitive therapy because biofilm formed due to infection in pacemaker lead reduce antibiotic effectiveness to eradicate bacteria colonization. Reimplantation should be performed in the contralateral area to reduce future risk infection.



Figure 1. PPM extraction

A Case Report: Multifocal PVC With Anterior-Inferior ST-Elevation

Fiska IF¹ DP Burnama²

¹ General Practitioner, General Hospital of Padang Panjang, West Sumatera, Indonesia. irafiska@gmail.com

² General Practitioner, Semen Padang Hospital, West Sumatera, Indonesia. dianpratiwib@yahoo.com

Background: Premature ventricular contraction (PVC) is the initiate heartbeat by the Purkinje fibers rather than the SA node. The actual mechanism of PVC in many case still unknown, but There are numerous cardiac and non-cardiac pathologies that are causative of PVCs, include cardiomyopathy, mitral valve prolapse, and myocardial infarction. Non-cardiac examples are hyperthyroidism, anemia, and even hypertension.

Case Illustration: Male, 65 years old came to the emergency room due to shortness of breath, chest pain, and palpitations for the past 2 hours. The pain radiates to the left shoulder and back. The patient has a cardiovascular history, which undergo a PCI procedure but failed 4 months ago and the treatment continued medically. In vital signs was found compos mentis, BP 213/103 mmHg, HR 81 x/minute, RR 34 x/minute, and SpO2 98%. The ECG showed multifocal PVC, ST elevation in lead II, III, aVF, v1-v3, and ST depression in aVL. The patient was given loading aspilet 160 mg and CPG 30 mg, furosemide injection 40 mg, and drip NTG 30 micro/hour. The patient refuses to be transferred to a hospital that provides a PCI procedure. The laboratory was normal and a chest x-ray showed cardiomegaly with early signs of pulmonary congestion. The patient was admitted to the HCU and given digoxin and anticoagulants. After 5 days of anticoagulation, the patient still complained of chest pain and palpitations. The ECG still showed ST elevation. After that, the patient was agreed to be transferred.

Conclusions: The presence of PVC could be related to myocardial infarction. The potential pathophysiology for any given PVC include triggered activity, automaticity, and reentry. These mechanisms can occur from a previous scar or underlying heart disease, that can triggered activity from afterdepolarizations from a previous action potential precipitated. PVCs in the setting of myocardial ischemia or previous infarction is associated with increased mortality, but if patients receiving antiarrhythmic for suppression of PVCs in myocardial infarction had significantly decreased ventricular ectopy as well arrhythmic death.

Keyword: VES multifocal, ST-Elevation, Anterior-posterior

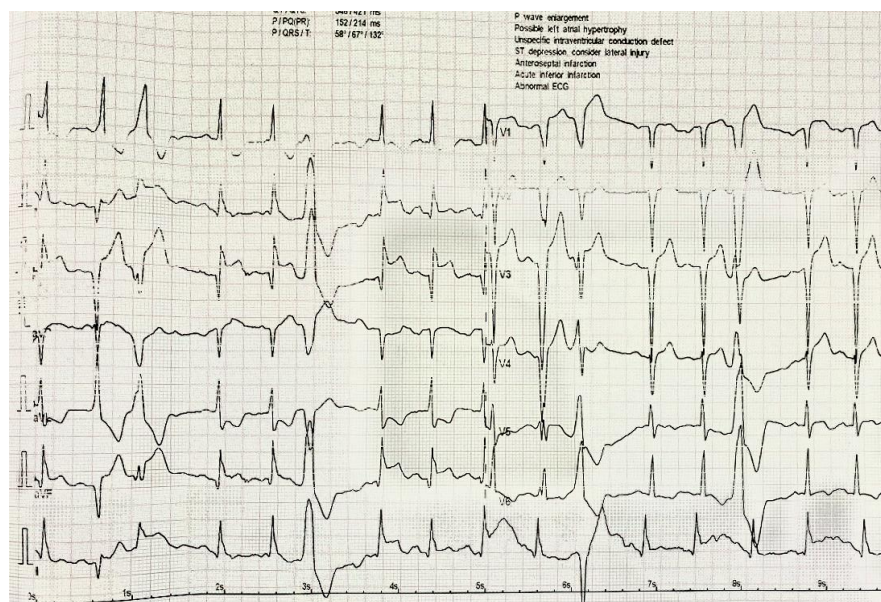




Fig. ECG showed multifocal PVC, ST elevation in lead II, III, aVF, v1-v3, and ST depression in aVL

Late Diagnosis of Ebstein Anomaly During Pregnancy: A rare case report

Lesmana J¹, Barri M², Ramadhan M¹, Gabriana J¹

¹General Practitioner at Jantung Diagram Hospital, West Java, Indonesia.

²Interventional Cardiologist at Jantung Diagram Hospital, West Java, Indonesia.

Background: Ebstein Anomaly (EA) is a rare congenital heart disease of the tricuspid valve and caused atrialization of the right ventricle occurring in 1 to 200.000 birth. This anomaly is characterized by displacement of the tricuspid leaflet associated with atrial septal defect, patent foramen ovale (PFO) and an accessory pathway. Patient varies on clinical presentation depending on anatomic and hemodynamic factors. Women in childbearing age usually show no symptoms until adulthood where pregnancy is feasible. This particular age group however experience severe maternal complication during pregnancy or at the time of delivery and may cause fatal consequence.

Case Illustration: A 25year-old woman came to the emergency department with worsening shortness of breath in the last week during rest and accompanied with decreased physical activity tolerance. Symptoms is sometimes accompanied with edema on both ankle and bluish color of the lips and nail bed. Her evaluation in detecting EA was with echocardiography and cardiac multi-slice computed tomography before and after delivery of her first child, respectively. She was well controlled with loop diuretic, phosphodiesterase type 5 inhibitor and Beta blocker, but unable to provide care for her child due to her heart condition. The patient was discharged after symptoms relieved and was planned for further interventional evaluation.

Conclusions: Although EA is rare but has a high maternal morbidity and mortality especially in woman of childbearing age since it may be asymptomatic during childhood. Therefore, early recognition of EA is probably necessary in women who are planning pregnancy

Keyword: Ebstein Anomaly, Congenital Heart Disease, Pregnancy.

Heart Failure Accompanied By First-Diagnosed Atrial Fibrillation With Rapid Ventricular Response: Management In Limited-Resource Rural Area

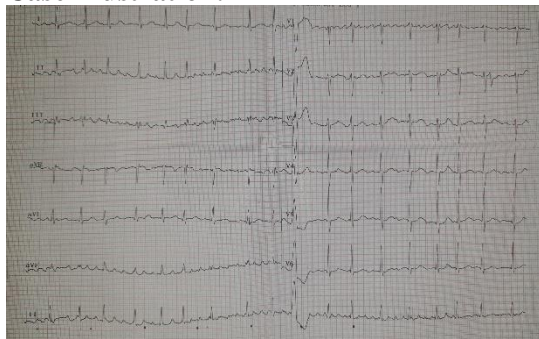
L. Jordy¹, W. Setiawan²

¹ General Practitioner, Puskesmas Batuparigi, Mamuju Tengah, Indonesia

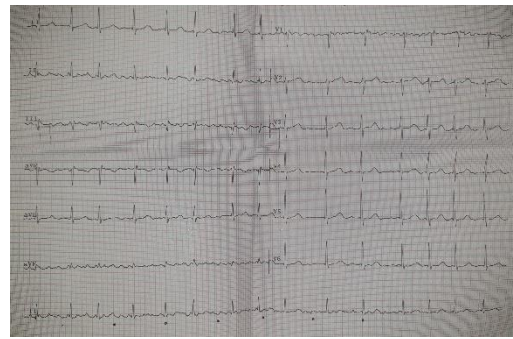
² General Practitioner, RSUD Dr. M. Haulussy, Ambon, Indonesia

Background: Heart failure is a disease affecting about 26 million people worldwide and about 29,550 people in Indonesia. Heart failure management requires a variety of modalities to establish the diagnosis and determine appropriate therapy. Since required modalities are only available at advanced health facilities, heart failure patients need to be referred after initial treatment at the first health facility by a general practitioner (general practitioner competency level 3).

Case Illustration:



Picture 1 (09/07/21)



Picture 2 (16/07/21)

A 52 years old woman presented to public health center with palpitation and dyspnea during exertion (NYHA functional class II) accompanied by sudden lightheadedness. She had paroxysmal nocturnal dyspnea and slept with two pillows at night. There wasn't history of chest pain and ankle edema. She was still capable to do her daily activities but barely sustained strenuous activities (e.g, gardening). Patient had history of transient ischemic attack and poorly controlled hypertension with amlodipine 10 mg. Physical examination showed blood pressure 168/91 mmHg, fast-irregular pulse on wrist palpation, enlarged heart border on chest percussion, and others found to be normal. Electrocardiography investigation revealed atrial fibrillation with rapid ventricular rate (about 120 BPM) and occasional ventricular extrasystoles. CHA2DS2-VASc Score was 4. The patient refused to be referred and was treated with ramipril 5 mg OD, bisoprolol 2.5 mg OD, and spironolactone 25 mg OD. After a week of monitoring, the patient felt better and blood pressure was 143/108 mmHg. ECG finding indicated atrial fibrillation with normal ventricular rate (about 90 BPM). The patient then agreed to be referred.

Conclusions: In this case, the patient was treated with ACE-I, B-blocker, and MRA which are the basic regiment of Heart Failure Treatment based on ESC Heart Failure Guideline. After a week of follow up, the patient was showing a better improvement from NYHA functional class II to NYHA functional class I. Even after better improvement, this patient need to be referred for further examination since she also had Atrial Fibrillation with CHAD2DS2-VASc Score of 4 which will need anticoagulant therapy and further laboratory or imaging examination.



HYPOKALEMIA INDUCED ACQUIRED LONG QT SYNDROME (LQTS): A CASE REPORT

K.A.A.P. Pramana¹, Y. Pintaningrum^{1,2}

¹Faculty of Medicine Mataram University

²Department of Cardiology and Vascular Medicine, West Nusa Tenggara General Hospital,

Background: The long QT syndrome (LQTS) is a one type of severe cardiac arrhythmia syndrome, characterized with impaired ventricular repolarization that can caused by hereditary disorder in sodium and potassium channels on cardiac myocyte and acquired caused by drugs or electrolyte imbalance, especially hypokalemia. This condition result in abnormality on the electrocardiogram (ECG) examination as QT interval prolongation and may lead increased risk the patients to syncope, seizure like activity, ventricular arrhythmias, and sudden cardiac death.

Case Illustration: A 46-year-old woman came to emergency department with a chief complaint of dizziness. Three days before this complaints, the patient also complaints of epigastric pain and profuse vomiting more than five times. The patient has no history of taking certain any medications before. On physical examination, there is no abnormality in patient's vital signs and only tenderness on epigastric region. On clinical laboratory examinations showed electrolyte imbalance such as hypokalemia. From electrocardiography showed prolongation of QTc interval (638 ms) and ventricular extrasystole trigeminy. On echocardiography, the patient had diastolic dysfunction grade I and concentric left ventricular hypertrophy with normal ejection fraction. From that examination, the patient diagnose with acquired long QT syndrome and the focus of therapy in this patient is to restore the electrolyte balance.

Conclusions: The diagnostic for LQTS in this patient are based on QTc interval ≥ 500 ms in electrocardiography examination. This diagnose criteria was based on Heart Rhythm Society guidelines. Electrolyte imbalance, especially hypokalemia is one of the most common indirect mechanisms of QT interval prolongation. The focus of the management of LQTS in this patient includes the identification and discontinuation of any precipitating drug and the aggressive correction of any metabolic abnormalities, such as electrolyte imbalance.

Keywords: Long QT syndrome, arrhythmia, hypokalemia

Far-field R Wave Oversensing and Extremely Prolonged PR Interval Causing Inappropriate Mode Switch in Dual Chamber His Bundle Pacemaker

K. Prakoso¹, G. Karwiky¹, M. Iqbal¹, C. Ahmad¹

¹Department of Cardiology and Vascular Medicine, Universitas Padjadjaran, Bandung, Indonesia

Background: Symptomatic bradycardia, if indicated, should be managed using a pacemaker. His bundle pacing (HBP) is one of the best methods to achieve physiologic electromechanical activation or relaxation of the left ventricle for optimal cardiac output. This case will elaborate troubleshooting in case of pacing failure in young patient with HBP.

Case Illustration: A 40-year-old male was referred to Hasan Sadikin General Hospital due to syncope resulted from symptomatic bradycardia. There is no history of prior cardiac disease, and this was the first syncopal episode. The ECG obtained during hospitalization showed a transient total AV block, marked first degree AV block (PR interval of 360 ms). The patient was then managed with HBP and afterwards had no residual symptoms. At the following day, the patient's pacemaker was evaluated as a preparation before discharge. Unfortunately, the number of ventricular pacing in this patient is low, therefore further investigation was carried out to determine the etiology for this condition.

Conclusions: In this case, the presence of marked first-degree AV block and intermittent complete heart block was the primary consideration to give HBP to the patient. The use of HBP in case of marked PR interval prolongation was aimed to achieve atrioventricular synchrony. Initially, implantation of HBP in this patient was deemed to be successful due to the presence of His capture on the surface ECG after the procedure was done. Unfortunately, it was later documented that half of the intrinsic atrial rhythm of the patient was not detected correctly as it fell at the post-ventricular atrial refractory period (PVARP) resulted in failure to pace in this patient (Figure 1). Furthermore, the close proximity between the right atrial appendage and right ventricular outflow tract, where a signal coming from ventricular pacing can be detected, leading to atrial oversensing in this patient, and aggravate this condition. For that reason, lowering the sensitivity of the HBP and shortening the PVARP in this case served as a solution for the His Bundle Pacing so that it can work properly.

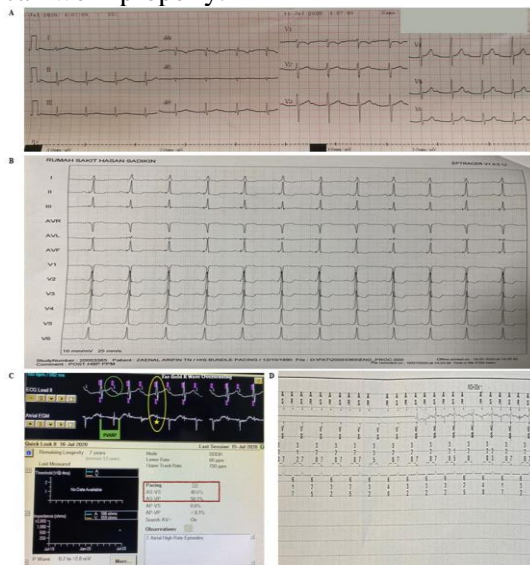


Figure 1. A. ECG obtained at the time of hospital admission; B. ECG obtained immediately after successful HBP implantation showing His capture characterize by spike before wide QRS complex with pseudo delta wave; C. Evaluation of the HBP showing undetected intrinsic atrial rhythm due to it being fell at the PVARP depicted by green color box as well as far field R wave oversensing depicted by yellow circle; D. ECG obtained during HBP reprogramming showing far-field R Wave oversensing and extremely prolonged PR Interval causing Inappropriate Mode Switch.

Subcutaneous Heparin Use in Atrial Fibrillation with COVID-19 Complicated by Acute Kidney Injury

L. Widiyanto¹, M. Sinaga¹, M. Limbong², D. Setiawan²,

¹ General Practitioner, North Kalimantan General Hospital, Tarakan, Indonesia.

² Department of Cardiology, North Kalimantan General Hospital, Tarakan, Indonesia

Background: Atrial fibrillation (AF) is common in COVID-19 patient. Anticoagulant is used for prevent thrombosis in AF and COVID-19. Anticoagulant therapy has shown benefit in AF and COVID-19.

Case Illustration: We reported 74-year-old female hospitalized for COVID-19 pneumonia complicated with acute kidney injury. She has history of hypertension treated with antihypertensive drugs. She didn't had any cardiac complaint in the first admission. Vital signs were BP: 92/67 mmhg, HR: 77 bpm irregular, RR: 24 rpm and SpO2: 98% room air. Standard 12 lead ECG revealed atrial fibrillation (AF) with normoventricular response. Laboratory showed normal blood count and impairment of renal function (CrCl 10 ml/min). Calculated CHA2DS2-VASc score in this patient was 3 point, moderate-high risk of stroke (age, female, hypertension). IMPROVE-BRS score was 4, not increased risk of bleeding. PADUA score was 5 and patient indicated for thromboprophylaxis treatment. Patient received COVID-19 treatment include remdesivir, aiztromisin and dexamethasone. Patient also received heparin 5000 units bid subcutan to prevent stroke in AF and VTE in COVID-19.

Conclusions: Most patients with AF require anticoagulant to prevent the risk of stroke. Risk of thrombosis are increase in case of AF with COVID-19. Anticoagulation will be recommended based on the risks of benefits of the individual patients with women with CHA2DS2-VASc ≥ 3 . The choice of anticoagulant should be considered on an individual based on renal function, COVID-19 severity, and potential interaction with COVID-19 treatment. Heparin is recommended as an anticoagulant of choice in this case caused by its range of safety in renal function impairment, its free of interactions with COVID-19 treatment, and its action may be quickly reversed in case of bleeding. LMWH is not recommended in this patient caused by renal function impairment. Oral anticoagulants are not recommended in hospitalized patient caused by risk of drugs interaction with COVID-19 therapy. Heparin dosage recommend for this patient is 5000 units bid sc for thromboprophylaxis in COVID-19. Prophylactic dose showed lower bleeding risk than full dose (intravenous). Heparin prophylactic dose might be consider in AF patient who are admitted for COVID-19.

Keywords: Heparin, stroke, thromboprophylaxis, atrial fibrillation, COVID-19.

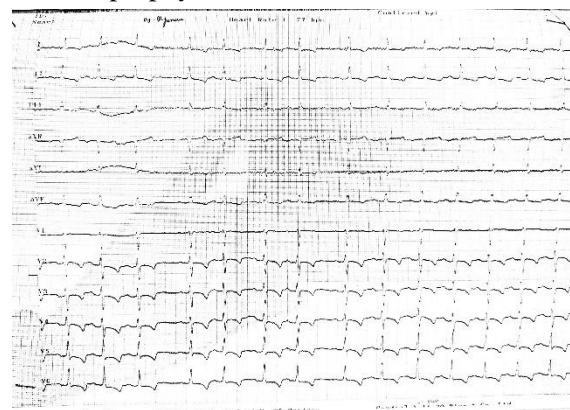


Figure 1. Patient's ECG

Tachycardia-Bradycardia Syndrome in Cor Pulmonale: A Controversy of Antiarrhythmic Drugs in Limited Facilities

L. Widiyanto¹, D. Setiawan², M. Limbong²

¹ General Practitioner, North Kalimantan General Hospital, Tarakan, Indonesia.

² Department of Cardiology, North Kalimantan General Hospital, Tarakan, Indonesia

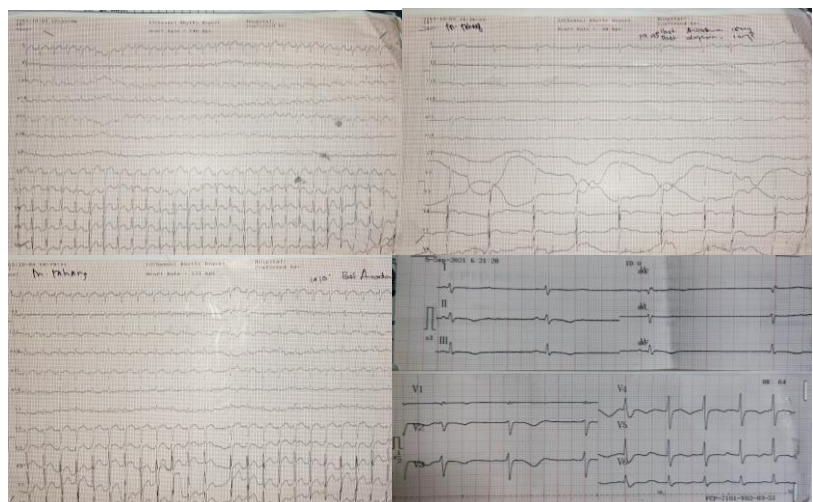
Background: Supraventricular arrhythmias (SVAs) are the most common cardiac arrhythmias in cor pulmonale. There was challenging caused by controversy over the use of antiarrhythmic in cor pulmonale and its arrhythmogenic effect in tachycardia-bradycardia syndrome (TBS).

Case Illustration: 65-year-old male re-admitted to ER with sudden palpitation. He had history of asymptomatic bradycardia with SVT, cor pulmonale and tuberculosis on intensive phase medication. Vital sign are BP: 120/71 mmHg, HR: 145 bpm, RR: 24 rpm, T: 36.7°C, Spo2: 98%. Physical examination revealed pansystolic murmur in 4th ICS parasternal. ECG examination discovered tachyarrhythmia with regular narrow QRS complex (Figure 1). Laboratory test (Table 1) was in normal range. Echocardiography revealed right atrial and ventricle dilatation, TAPSE 1.2 cm, severe tricuspid regurgitation. Patient was diagnosed as SVT-AVNRT and atrial tachycardia in TBS, cor pulmonale, and tuberculosis. This stable symptomatic tachyarrhythmia was treated with vagal maneuver and failed. We chose intravenous amiodarone and digoxine. Rhythm was converted to sinus bradycardia 48 bpm and maintaining with oral amiodarone and digoxine.

Conclusions: There are still limited data about antiarrhythmics implementation in cor pulmonale. The drugs were used for SVAs including adenosine, digoxin, amiodarone, β -blockers, calcium channel blockers (CCBs), sodium channel blockers (SCBs). We only have digoxine and amiodarone intravenous in our hospital setting. Amiodarone is the most frequent used for SVAs in acute setting. Prophylaxis with oral amiodarone was recommended since its absent of negative inotropic effects. Digoxine may given to slow ventricular rate and has been shown to improve cardiac output in cor pulmonale. Its efficacy is unknown when administered chronically. Adenosine is a short acting agent to treat AVNRT. Adenosine related to significant air flow limitation in obstructive lung disease. It is reasonable to advise against the use of this drug in cor pulmonale. The use of β -blockers in pulmonary hypertension can provoke heart failure and circulatory collapse based on negative inotropic and chronotropic effects eventhough it may be helpful in restoring sinus rhythm. CCBs also have negative inotropic effect, and sodium channel blockers are contraindicated in structural heart disease. Patients should be monitored intensively because antiarrhythmics can triggered bradycardia to life-threatening arrhythmias in TBS.

Keywords: Tachycardia-bradycardia syndrome, cor pulmonale, antiarrhythmic.

Figure 1. Patient's ECG



Unstable Junctional Bradycardia in Elderly: Focus on Hemodynamic and Identify All Possible Reversible Causes

L. Widiyanto¹, S. R. Ratri¹, M. Limbong², D. Setiawan²

¹ General Practitioner, North Kalimantan General Hospital, Tarakan, Indonesia.

² Department of Cardiology, North Kalimantan General Hospital, Tarakan, Indonesia

Background: Junctional bradycardia originate when the electrical activity of the SA node is blocked or is less than the automaticity of the AV node or His Bundle. Although the incidence of sudden death in bradyarrhythmia is extremely low, unstable hemodynamic condition could still be life threatening.

Case Illustration: A 61-year-old woman, came to emergency room with lightheadedness and vomiting with history of junctional bradycardia. Patient's risk factors are hypertension and coronary arterial disease. Her routine medication are salbutamol, antihypertensive drugs, simvastatin, clopidogrel. Physical examination showed BP: 138/58, HR: 26 bpm regular, RR: 20 rpm, T: 36.7°C. No congestive signs were found. 12-Lead ECG examination revealed junctional bradycardia (Figure 1). Laboratory test (Table 1) revealed hyperkalemia, elevation of urea and creatinine, also metabolic acidosis. Patient was diagnosed as symptomatic junctional bradycardia, hyperkalemia, acute kidney injury, with metabolic acidosis. As stated in the ACLS algorithm, this stable symptomatic bradycardia was treated with intravenous atropine sulphate, dopamine. Metabolic acidosis was immediately treated via central venous line with natrium bicarbonate. Calcium gluconas, D40%, and insulin combination was used to treated hyperkalemia. Patient was transferred to ICCU when heart rate returned to sinus rhythm 64 bpm. During observation in ICCU, she became somnolent. ECG monitor showed recurrence of junctional bradycardia (32 bpm) with hypotension (BP: 85/60 mmHg). Laboratory evaluation described refracter hyperkalemia and acidosis metabolic. In unstable state, we decided to increase dopamine dosage combined with epinephrine maintenance, and consulted for emergency hemodialysis. Hyperkalemia, metabolic acidosis, and uremic syndrome sequentially resolved after hemodialysis, continually marked by return of sinus rhythm (86 bpm). On 6th day, patient discharged from hospital with routine prescription of salbutamol and candesartan.

Conclusions: Treatment of a junctional bradycardia primarily depends on the underlying cause. Eventhough junctional bradycardia is typical in SND, clinicians still have to look for all reversible causes which can be treated such as drugs, ischemia or infarction, infection, or metabolic state. Treatment in bradycardia determined by hemodynamic state, according to ACLS algorithm. In unstable or symptomatic case, we can give atropine, dopamine, epinephrine, or transcutaneous pacing.

Keywords: Junctional bradycardia, hemodynamic, hyperkalemia, metabolic acidosis.

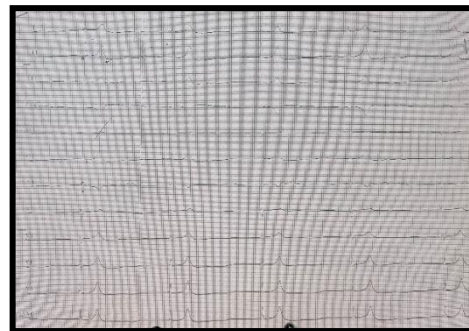


Figure 1. Patient's ECG

A narrow QRS complex tachycardia in structurally normal heart: SVT or VT?

M. Septian¹, I.F.A. Putra¹, A.F. Prianda², A.R. Ruhukail²

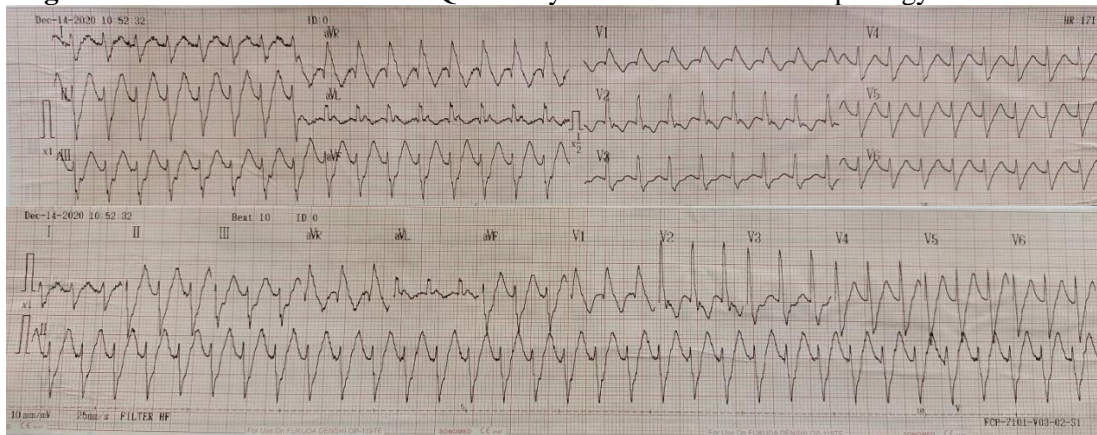
¹General Practitioner, Kuningan Hasna Medika Cardiac Hospital, West Java, Indonesia

²Cardiologist, Kuningan Hasna Medika Cardiac Hospital, West Java, Indonesia

Background: Ventricular tachycardia (VT) is usually associated with structurally abnormal heart, but it can also occur in a healthy individual with no structural heart disease, it is called with idiopathic VT (IVT). The IVT accounts for 10% of all VT diagnosis.

Case Illustration: A 24 years old female patient present with palpitation two hours before admission. There were no dyspnea, chest pain, dizziness, or history of syncope. It was not the first complaint. No history for heart disease and patient's symptom-mimicked familial disease. Heart rate was about 162 times per minute on admission, other vital signs were stable. Physical examination revealed normal jugular vein pressure and no rales for both lungs. Neither murmur nor gallop heard from the heart examination. Electrocardiogram (ECG) showed a relatively narrow QRS tachycardia with right bundle branch block (RBBB) morphology and righted axis. Left ventricle ejection fraction (EF) was 76% and there were no valves abnormality nor dilated heart chamber from echocardiography. The patient was given a 80 milligrams verapamil and twice a day afterward. The ECG was sinus rhythm when the patient have been discharged. Holter monitoring was planned in the referral hospital.

Fig 1. ECG at arrival showed wide QRS tachycardia with RBBB morphology



Conclusions: It is a challenging condition where a relatively narrow QRS tachycardia appear in a young female patient. It may a supraventricular tachycardia (SVT) especially with aberrancy or VT. Moreover, SVT with aberrancy are commonly has RBBB pattern. Using the Brugada algorithm, the diagnosis consistent with VT where RS interval was 120 millisecond in lead V3. In this case VT is affirmed since there is occurrence of atrioventricular (AV) dissociation. It is reasonable to consider anterior fascicular VT (A-IFLVT) because IVT is classified according to and the QRS morphology on the ECG could use to predict the origin. Therapy for hemodynamically stable patient is verapamil, as the basic mechanism is a reentry that involve tissue which is verapamil-sensitive. Catheter ablation is useful when medication is neither effective nor tolerated. Although the majority of IVTs have excellent prognosis, one to prevent is tachycardia-related cardiomyopathy (TCM).



Role of dopamine in AV conduction recovery of Complete Heart Block in late onset inferior STEMI

M. Rahmah, A. A. Haura, D. Almeidi
Pertamina Hospital Balikpapan

Background: Complete Heart Block (CHB) is commonly found complication to Inferior ST elevation Myocardial Infarction (STEMI). Reperfusion and cardiac pacing, as the mainstay therapy, could be unavailable due to certain limitation in rural area. we present a case concerning the role of dopamine, frequently used as bridging to cardiac pacing, in elderly patient resulting in recovery to sinus rhythm in non-reperused inferior STEMI.

Case Illustration: A 73 years old male complains of dizziness and weakness that develops gradually for a week without any episode of chest pain. He was hemodynamically unstable with extreme bradycardia. Electrocardiogram showed ST segment elevation inferior wall and complete atrioventricular (AV) block. He was then suspected for Covid-19 infection prior to routine screening for hospitalization. Both coronary reperfusion and cardiac pacing were not performed. Continuous intravenous dopamine was given and significantly improved clinical condition. Spontaneous recovery to sinus rhythm happened day 8.

Conclusions: In STEMI, reperfusion is still the principal strategy, but due to several limitations, reperfusion cannot be done. According to ESC, 5 to 10 days if CHB still occur in acute MI patient, a permanent pacemaker should be implanted. In this geriatric patient with CHB that happened more than 5 days, where pacing cannot be inserted due to several limitation, dopamine was used as a therapy to stimulate myocardial contractility and increase electrical conductivity. AHA 2018 stated that dopamine dose for treating AV Block is 5 to 20 mcg/kg/min IV, starting at 5 mcg/kg/min. Dopamine might be considered as a therapy in STEMI patients with conduction disorder, where reperfusion or revascularization and pacing is not available due to any limitation.

Atrial Standstill Corrected with His Bundle Pacing: A Case Report

M. A. Lesmana¹, G. Karwiky¹

¹Department of Cardiology and Vascular Medicine, Universitas Padjadjaran, Dr. Hasan Sadikin General Hospital, Bandung, Indonesia.

Background: Atrial standstill is a rare condition that characterized by absence of electrical and mechanical activity in the atria. It presents with bradycardia and absence of p waves in electrocardiography and causes by many different etiologies including hereditary mutational causes to secondary causes such as amyloidosis. We report a case of atrial standstill with with junctional rythm and VES multifocal frequent.

Case Illustration: A 49 years old woman who came to our emergency department with chief complaints of dizziness since 3 days before admission. The patient also has a history of coronary artery disease undergoing percutaneous coronary intervention 1 year before admission. On Electrocardiography showed atrial standstill with junctional rythm and VES multifocal frequent. Echocardiography showed Normal LV systolic function (EF 55%), with normokinetic at rest and atrial paralysis. Holter monitoring results was junctional rhythm with VES multifocal frequent and chronotropic incompetence. Electrophysiology study results an Atrial Paralysis Ventricular premature depolarization susp. originating from posteromedial/septal LV. Patients undergoing his bundle pacing in setting sensivity of 2.4 mV, threshold 13. mV and impedance 562 Ω with patients showing good results by Aquarel score 100 and SF-36 score 100% in all areas.

Conclusions: Atrial standstill is a rare clinical condition and misdiagnosis of atrial standstill might often occure because of other various clinical condition that exhibit absence of P waves in ECG. It generally classified into two types: persistent and transient and the spatial distribution of atrial lesion can be diffuse or partial. AS is a progressive disease; therefore, atrial pacing failure might occur. In such patients implanting a PPM is thought to be associated with symptoms reduction and better quality of life. His bundle pacing can be choice of management for patient with atrial standstill because His pacing is a better method for delivering pacing since it can maintain normal conduction via the His-Purkinje system and prevents ventricular dyssynchrony

Keywords: atrial standstill, his bundle pacing

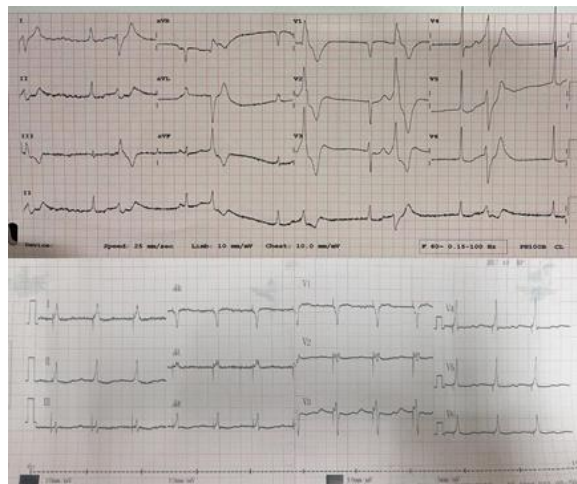


Figure 1. Electrocardiography of atrial standstill before and after his bundle pacing

New Arrhythmic Event associated with COVID-19

M.J. Simorangkir^a, A. Primawati^b, F. Nurwidya^c, M.S. Abdaly^d

^aGeneral Practitioner, Bunda General Hospital Jakarta, Indonesia

^bCardiologist, Bunda General Hospital Jakarta, Indonesia

^cPulmonologist, Bunda General Hospital Jakarta

^dInternist, Bunda General Hospital Jakarta

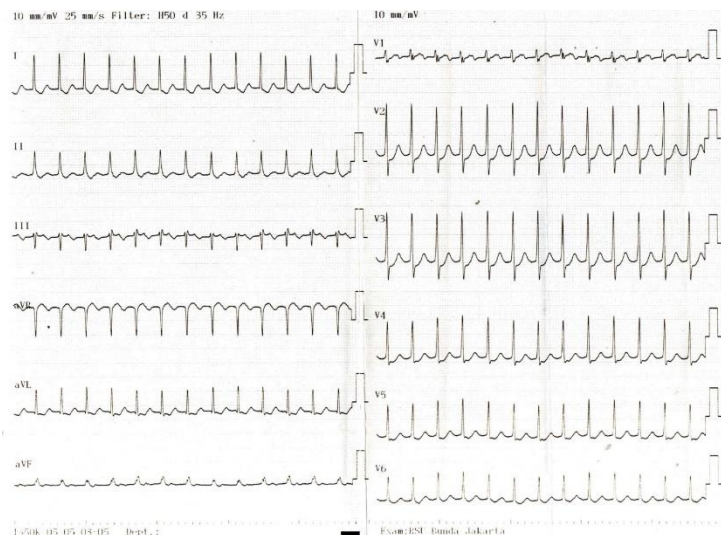Background: Corona Virus Disease 2019 (COVID-19) is caused by severe acute respiratory syndrome coronavirus 2 (SARS-CoV-2). Although its primary infection is respiratory, cardiovascular involvement has been reported. Worldwide survey recorded that 18.3% of COVID-19 patients had arrhythmias associated with significant mortality. We reported a 66-year-old woman with new arrhythmic event associated with COVID-19 that resolved with rhythm control.

Case Illustration: A 66-year-old woman presented with fever, cough, and dyspnea for three days. She had no known history of cardiovascular disease. She had previously taken paracetamol, acetylcysteine, and dexamethasone. Upon admission, her physical examination showed tachypnea (24x/minute), pyrexia (38°C), hypoxia (92%), and bilateral pulmonary rhonchi. Her electrocardiogram (ECG) showed sinus rhythm, 72 bpm (**Figure 1**). Her initial laboratory test showed normal hemoglobin level, white blood cell count ($7.1 \times 10^3/\mu\text{L}$), increased neutrophil (86.4%), ESR (45 mm), CRP (175.2mg/L), IL-6 (9.42 pg/mL), D-dimer (0.67 ug/mL), and mild hypokalemia (3.2 mmol/L). Thorax CT-scan showed bilateral ground glass opacities. She was hospitalized with initial diagnosis of Moderate COVID-19 pneumonia and hypokalemia. On the seventh day of hospitalization, she had palpitation and dyspnea. Her vital signs showed BP 90/60 mmHg, HR 165 bpm, RR 24 x/minute, SpO2 91%. Her ECG revealed regular, narrow-complex tachycardia, 170 bpm. Amiodarone 150mg bolus and continued infusion 600mg for 24 hours was given, the rhythm converted to sinus. She was discharged with oral amiodarone 100mg once daily for 7 days. Arrhythmias are one of cardiac complications found in COVID-19 infection and lethal ones have high mortality risk. SARS-CoV-2 entry to angiotensin-receptor-II causes excessive systemic inflammatory and sympathetic response that trigger arrhythmogenic event. This effect may be due to hypoxia, volume depletion, electrolyte imbalance, neurohormonal and autonomic dysfunction. Management is targeted in conversion to sinus rhythm and treating the precipitating factors.

Conclusion: We presented a case of new arrhythmic event in COVID-19 patient without previous history of cardiovascular disease. Immediate diagnosis and rhythm control treatment was given to prevent deleterious complications. Further studies are required to make recommendations regarding management of arrhythmias in COVID-19 pandemic.

Keywords: atrioventricular arrhythmia, COVID-19, hypokalemia, new arrhythmic event,

Figure 1. Slow-Fast AV Nodal Re-entry Tachycardia (AVNRT). No visible P waves, pseudo R' wave in V1, pseudo S wave in lead II, HR = 170 bpm, QRS = 76 ms, ST depression V2, V3, V4.



Right Ventricular Septal Pacing to Produce Narrow QRS Duration in Patient with High Degree 2:1 AV block

Santoso M E¹, Setiadi B M², Setiawan S¹, Sunarto H¹

¹. Cardiology Resident of Sam Ratulangi University, Faculty of Medicine

². Department of Cardiology and Vascular Medicine, Sam Ratulangi University, Kandou General Hospital, Manado

Background: Prolonged right ventricular (RV) apical pacing has been recognized to be associated with progressive left ventricular (LV) dysfunction. This impairment of LV function resultant from RV apical pacing is a remodelling process consequent to abnormal ventricular activation and contraction. RV septal pacing theoretically is associated with a more physiological ventricular activation results in shorter electrical activation delay and consequently less mechanical dyssynchrony.

Case Illustration: A-75-year-old woman presented to emergency department (ED) with dyspnea only on exertion in the last 3 weeks before admission, she also complaint near syncope episode while doing activities. She had history of hypertension. Clinical examination in ED showed her blood pressure was 210/70 mmHg. Her electrocardiogram (ECG) result was high degree AV block with 2:1 conduction with ventricular rate 40 beats per minute. Her echocardiogram showed an ejection fraction of 70% with no regional wall abnormality. The treatment plan was to implant permanent pacemaker (PPM). PPM implantation was performed with VVIR mode, ventricle lead inserted into mid-septal RV which showed that output threshold was 0.6 v; current 0.8 mA; R wave 23.9 mV, impedance was 832 ohm and rate 60 bpm. ECG post implantation showed pacing rhythm with narrow QRS duration (110 msec). (Fig 1.)

Conclusions: Pacemaker-related LBBB is associated with an adverse prognosis. RV septal pacing produces more synchronous contraction denoted by narrow QRS, preventing the deterioration of LV structure and function. Successful reduction in QRS duration can be achieved with cardiac resynchronization therapy. His bundle pacing is an alternative strategy to produce normal QRS duration but faces many technical challenges. RV septal pacing, although not as good as intrinsic conduction or His bundle pacing, may be more desirable for chronic RV pacing compared to the RV apex as a narrow QRS is associated with improved LV dynamics. RV septal pacing was safely done in this patient, but further study needed to evaluate its long-term effect.

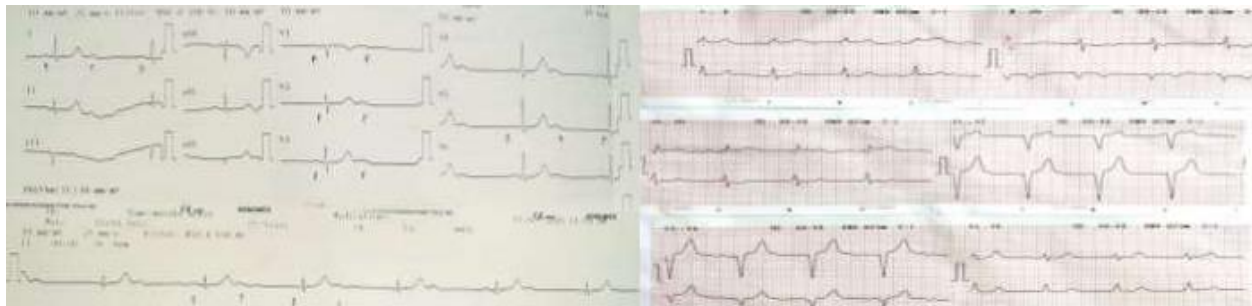


Fig 1. ECG preoperative and after PPM implantation.



Recurrent Atrioventricular Reentrant Tachycardia in A Six-month Old Baby with Congenitally Corrected Transposition of Great Arteries: The Strategy Dilemma

M. F. Adam,¹ Y. Kurniawati,² D. A. Hanafy,³ O. Lilyasari²

¹ Department of Cardiology and Vascular Medicine Faculty of Medicine Universitas Indonesia/National Cardiovascular Centre Harapan Kita, Jakarta, Indonesia

² Division of Pediatric Cardiology and Congenital Heart Disease, Department of Cardiology and Vascular Medicine, Faculty of Medicine University of Indonesia / National Cardiovascular Centre Harapan Kita, Jakarta, Indonesia

³ Division of Arrhythmia, Department of Cardiology and Vascular Medicine, Faculty of Medicine University of Indonesia/ National Cardiovascular Centre Harapan Kita, Jakarta, Indonesia

Background Congenitally corrected transposition of the great arteries (ccTGA) is a rare cardiac malformation characterized by the combination of discordant atrioventricular and ventriculoarterial connections (AV-VA discordance). The main problem in ccTGA usually comes from cardiac arrhythmia, such as AV block, AV node reentry tachycardia (AVNRT), and in a rare case, presence of accessory pathway (AP), which manifests as atrioventricular reentrant tachycardia (AVRT). Catheter ablation of AP is a definite treatment for terminating AVRT. Nevertheless, finding the proper anti-arrhythmic agent is a must for controlling recurrent AVRT because of the high risk of doing ablation in infants.

Case Illustration. A 6-month old baby came to the emergency department with sudden onset palpitation. ECG showed narrow regular QRS-complex tachycardia, long RP-interval with ventricular rate of 234bpm. After successful electrical cardioversion, ECG showed Wolf-Parkinson-White (WPW) pattern suggesting left-lateral AP. Echocardiography revealed situs solitus, AV-VA discordance (ccTGA), and secundum ASD. Due to recurrent AVRT and inability to perform catheter ablation, several trials of anti-arrhythmic regimen were given to terminate the tachycardia. Freedom of tachycardia was achieved after five days of intravenous amiodaron, bisoprolol, and oral digoxin, followed with four-days free of tachycardia with only oral amiodaron and bisoprolol.

Conclusion. We present a rare case of orthodromic AVRT due to WPW syndrome of left lateral AP in ccTGA. Optimal anti-arrhythmic management should be the first-line therapy in infants with recurrent AVRT. Due to its high risk, Catheter ablation could be the last option of treatment for AVRT.

Keyword: Atrioventricular Reentrant Tachycardia, Congenitally Corrected Transposition of Great Arteries, WPW syndrome, Anti-Arrhythmic drugs, Catheter Ablation



Ventricular Fibrillation due to Early Repolarization Syndrome Concomitant with Wolff- Parkinson-White Syndrome

M. F. Adam,¹ D. A. Hanafy,² D. Y. Hermanto,² Y. Yuniadi,² S. B. Raharjo.²

¹Department of Cardiology and Vascular Medicine, Faculty of Medicine Universitas Indonesia, National Cardiovascular Center Harapan Kita, Jakarta, Indonesia

² Division of Arrhythmia, Department of Cardiology and Vascular Medicine, Faculty of Medicine Universitas Indonesia, National Cardiovascular Center Harapan Kita, Jakarta, Indonesia

Background: Ventricular fibrillation (VF) in Wolf-Parkinson-White (WPW) syndrome can occur because of several causes, such as degeneration from atrial fibrillation (AF), iatrogenic, or concomitant with structural or channelopathy disease. Early repolarization syndrome (ERS) could be the cause of VF.

Case Illustration: A 28-year-old man presented to the emergency department with palpitation one hour before admission. ECG confirmed diagnosis pre-excited AF. After synchronized cardioversion delivered, ECG showed WPW pattern suggestive left lateral accessory pathway (AP). Radiofrequency ablation for left lateral AP had been successfully performed. However, electrophysiology study after ablation found that VF was easily inducible. 12-lead ECG after that showed no delta waves seen, but there was concave ST-segment elevation at V1-V4, followed with notched J point at inferolateral lead, suggesting malignant pattern of early repolarization. Further examination to find the cause of VF (right ventricle biopsy, cardiac MRI, echocardiography, and Brugada provocation test) showed no abnormality was found.

Conclusion: The cause of VF of this patient was more likely from ERS after excluding every possible causes. So the final diagnosis was inducible VF due to ERS concomitant with WPW syndrome

Keywords: Early repolarization syndrome, ventricular fibrillation, WPW syndrome.



Covid-19 as possible cause of severe exacerbation of the previous acute coronary syndrome: initial management and its limitation in rural hospital – a case report

M. A. Suryo¹, Izwar², D. A. Basri³

¹ General Practitioner, Tengku Rafi'an Siak General Hospital, Riau, Indonesia

² Internist, Tengku Rafi'an Siak General Hospital, Riau, Indonesia

³ Pulmonologist, Tengku Rafi'an Siak General Hospital, Riau, Indonesia

Background: Coronary artery disease has been long known as the first leading cause of death worldwide. Covid-19 has emerged to become the global pandemic and is associated with increase mortality to people with comorbidity especially heart disease.

Case Illustration: A 62-years old male with history of acute coronary syndrome (ACS) 5 months ago was re- admitted with severe angina and difficulty breathing 30 minutes before admitted to ER. The patient hasn't got covid-19 vaccination. Physical examination showed BP 90/60 and HR 50 bpm. ECG showed sinus bradycardia with significant ST elevation in inferior and anterior leads with ST depression in lateral leads (Figure 1). Troponin I and Chest X-ray examination showed no significant abnormalities. The patient was found confirmed with covid-19 in PCR test and wide myocardial infarction with confirmed covid-19 diagnosis were made. The patient died after 1 day hospitalisation due to cardiac arrest and cardiogenic shock despite vasopressor support also due to hospital limitation.

Conclusions: We suspected covid-19 as a trigger to exacerbation of the ACS in this case. Myocardial injury may be related to upregulation of ACE 2 in the human heart and coronary vessels in covid-19 patients which related to Covid-19 pathophysiology. The mechanism underlying covid-19 induced ACS might involve plaque rupture, coronary spasm or microthrombi owing to systemic inflammation or cytokine storm. In Myocardial Ischaemia National Audit Project (MINAP) cohort, patients with Covid-19 ACS had higher in-hospital rate and higher 30-day mortality rate compared to non-covid-19 ACS (24.2% vs 5.1% and 41.9 vs 7.2% respectively). Short door-to-balloon (D2B) time is associated with better outcomes for patient with STEMI. However, the location from Siak regency to nearest primary PCI center requires almost 3 hours transportation. In addition, the fibrinolytic drug was not regularly available in our rural hospital. Our patient also had no history of covid-19 vaccination which has proven to decrease hospitalization in patient with Covid-19. This limitation shows the need for cardiologists, primary PCI facilities, availability of fibrinolytic drugs in non-PCI capable center, and faster covid-19 vaccination across Indonesia especially rural area to decrease the mortality and global burden.

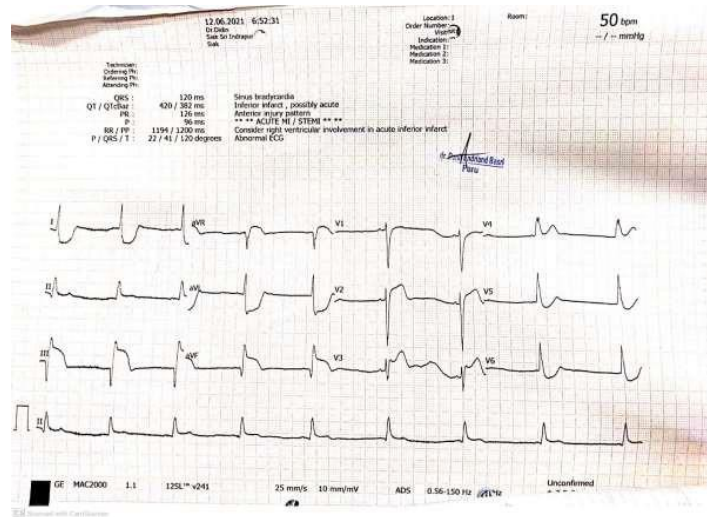


Figure 1

Case Report: Subclavian Crush Syndrome in Patients with Permanent Pacemaker

M. A. Basith¹, M. G. Satwiko², E. Maharani²

¹)Resident of Cardiology and Vascular Medicine at Gadjah Mada University / Sardjito General Hospital, Yogyakarta, Indonesia.

²)Staf of Cardiology and Vascular Medicine at Gadjah Mada University / Sardjito General Hospital, Yogyakarta, Indonesia.

Background: Subclavian crush syndrome is a well-described cause of pacemaker lead failure. It usually occurs after medial intrathoracic puncture of the subclavian vein and results in damaging of the pacemaker lead body by entrapment within the costoclavicular ligament and/or the subclavian muscle.

Case Illustration: A 60-year-old man with history of permanent pacemaker implantation came to the emergency with weakness. The device was implanted in 2014 with indication of total AV block (TAVB). The vital sign showed bradycardia 40 beats per minute. The ECG showed sinus rhythm with TAVB and failure to capture. The chest radiograph didn't show disruption lead. The device interrogation showed Biotronik® VVIR mode with lower rate at 70 bpm and upper rate at 130 bpm, high threshold, output 2/0.5 V, sensitivity 2.5, impedance >3000 ohms, current 5.4 mA, battery 2 years/2.7 V. Failure to capture on ECG and increasing of impedance leading the diagnosis to lead fracture. The patient was then planned for lead ventricular and pacemaker replacement.

Conclusions : Normal pacemaker function is characterized by effective stimulation and proper sensing of intrinsic depolarization of the chamber in which the lead is implanted. Malfunction of the pacing system can be detected by ECG and device interrogation. Failure to capture on ECG and abrupt increasing of impedance is specific for lead fracture. Most fractures occur in the area just lateral to the subclavian venous entry site as a result of compression of the lead between the clavicle and the first rib or entrapment of the lead by soft tissue in the costoclavicular space. Subclavian crush syndrome resulting from lead (or leads) entrapment between the clavicle and the first rib following subclavian vein puncture. Although the subclavian vein approach has shown a high success rate, it has also been reported to be associated with lead fractures at the point where the pressure between the clavicle and the first rib.



Managing Supraventricular Tachycardia in Limited Facilities: A Challenge for Rural Hospital

M. F. Alhas¹, S. Subijakto²,

¹General Practitioner, RSUD Konawe, Konawe, Sulawesi Tenggara, Indonesia; ²Cardiologist,
Department of Cardiology RSUD Bahtheramas, Kendari, Sulawesi Tenggara, Indonesia

Background: Managing Supraventricular Tachycardia (SVT) is detaily explained in many guidelines and have been updated several times, following the latest research done by experts. Unfortunately, applicating the latest guideline is not always feasibly done in rural areas.

Case Illustration: A 48 years-old female presented to the emergency department with chest discomfort and palpitation. The physical exam revealed within normal limit. ECG showed supraventricular tachycardia of 200 bpm suggesting atrioventricular nodal reentrant tachycardia and no finding of infarction. Patient was treated as a stable SVT with vagal manoeuvres twice by doing carotid massage, but the rhythm did not convert. We decide to do rate control with oral bisoprolol, as we do not have other medication mentioned in guideline. Since the rhythm did not convert after oral rate control, we decide to do rhythm control with intravenous lidocaine, as amiodarone nor cardioversion were not available. Referring the patient to tertiary healthcare was not an option in this case due to several reasons. Following lidocaine administration, the patient complained dizziness and sensation of going to pass out. The rhythm did convert into sinus rhythm with 90 bpm, without chest pain and dizziness. We send the patient to ICU for intensive observation.

Conclusion: Managing supraventricular tachycardia and other types of arrhythmias in limited facilities is a common challenge for emergency department in rural area. In some cases, physician needs to go out of the guideline and improvise to decide an alternative management available and based on evidence based medicine.

Keywords: Supraventricular tachycardia, Lidocaine, Limited facilities, Rural

Treatment for Patient with TAVB on COVID-19 Era

M. Farhan, N. Fathika A.R, Hernandes
Faculty of Medicine, Andalas University

Background: Total Atrio-Ventricular Block (TAVB) is a life-threatening disease. While it has unspecific clinical characteristics, electrocardiography (ECG) test is recommended to diagnose TAVB. In this report, we are reporting a case about a patient who came with a dyspnea as a chief complaint in this COVID-19 era.

Case Illustration: A 69 years old male came with increasing dyspnea since a week ago. The dyspnea worsened by cough and triggered by mild activity. PND history was found, meanwhile history of chest pain, palpitation, nausea, and vomiting were not found. The patient was smoking for 20 years, 1-2 packs/day. On physical examination, the vital sign showed HR at 51x/min, RR at 30x/min, and the rest were on normal range. On the ECG test we found Total AV Block with bradycardia sinus rhythm. QRS rate 42x/min, ST depression at II, aVF, and V4-V6 leads, and T-inverted at II, III, aVF, and V3 leads. CXR results were normal. Laboratory test result was leukocytosis and the Troponin-I test result was 35 ng/L, and SARS-CoV2 PCR test result was negative. The patient diagnosed with TAVB with COPD on Acute Exacerbation. The patient was treated with oxygen 2 lpm, RL 500cc/24h, dobutamine drip started at 5 mcg/kg/min, and the patient had Temporary Pacemaker insertion on 60x/minute rate settings. The patient went on Coronary Angiography test and non-specific lesion found at RCA. Permanent Pacemaker insertion was delayed because the patient had Community Acquired Pneumonia while on the hospital.

Conclusions: In this pandemic era, dyspnea symptom are often associated with COVID-19, so cardiovascular diagnosis is often neglected by doctors. Smoking is a well-known risk factor for atherosclerosis and myocardial infarction which can trigger disruption in cardiac conduction systems including AV Block. The patient's age is 69 years old and it is known that degenerative factor is included among AV block risk factors. The patient was on Temporary Pacemaker because we considered to treat the CAP first before PPM installation.

Keyword: *Total Atrio-Ventricular Block, Electrocardiography, COVID-19*

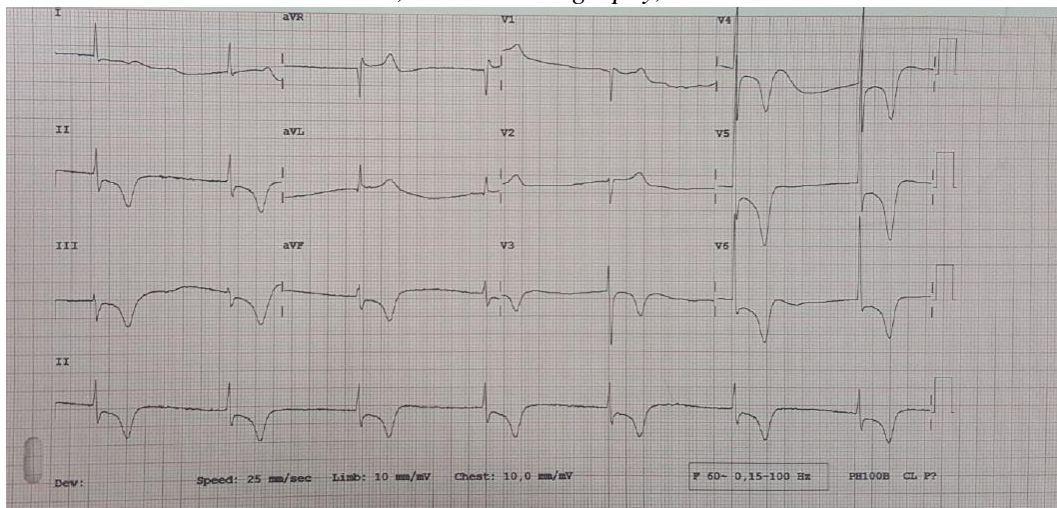


Figure 1. ECG on Emergency Department



Bizzare Rhythm Changes in Acute Brain Injury Patients: A Case Series.

M. K. Pratama, P. Wulandari, A. A. Hakim
Badan Pengusahaan Batam General Hospital

Background: ECG changes in comprehensive management of acute brain injury is gaining more attention, despite being introduced back in the 1980s, due to its relation to the prognosis and outcome of the patients. Even though these changes have been seen as secondary event following the direct insult to the brain, it is still an important factor, and challenging situation in the clinical decision making and management of the case.

Case Illustration: Two patients, 27- and 44-years old male, were referred to the emergency unit due to acute brain injury. In the first case, a wide-QRS-tachycardia was developed before the craniotomy procedure, followed by declining of the hemodynamic status, despite normal findings in laboratory and chest x-ray examination. These threatening conditions were later found to be resistant of the given treatment. Perioperative assessment showed a very high-risk status and the prognosis prior to the procedure was poor. Even after the craniotomy was done, overall condition did not change significantly. In the second case, a strange rhythm was found after the operative procedure. A very high-risk perioperative assessment was identified in advanced to the procedure. Therefore, poor prognosis was also been considered. the rhythm was converted to sinus with first degree AV-Block after treatment was given, but the hemodynamic status continues to declined.

Conclusions: These cases showed an event of bizzare ECG changes, that presented on the acute brain injury patients with unknown cardiovascular disease history. These changes were documented quite frequently in the previous studies and case reports, but it remains challenging until now. Massive catecholamines secretions, electrolyte imbalance, direct insult to the brain, and blunted feedback from the injured nervous system were said to contribute as the main pathophysiology. Although it is still unclear, comprehensive clinical decisions have to be made carefully with consideration over the ECG changes as it is related to the outcome and prognosis of the patients.

Table 1. Clinical Presentation



Clinical Presentation	Case 1	Case 2
Age	27	44
Gender	Male	Male
Haemodynamic Status	Unstable	Stable
GCS	3	7
CT Scan	EDH	SAH
Chest Xray	Normal	Normal
Routine Blood Exam	Normal	Normal
Natrium (mmol/L)	142	130
Potassium (mmol/L)	4.3	5.2
Chloride (mmol/L)	104	98
ECG	Wide-QRS-Tachycardia	Wide-QRS-Tachycardia
Conversion to Sinus Rhythm	Converted	Converted
Prognosis	Ad Malam	Ad Malam
Outcome	Deceased	Deceased

Ischaemic Ventricular Tachycardia due to STEMI Equivalent without Revascularization and Concomittant Subarachnoid Haemorrhage

¹Felani MR, ¹Sugiharto NA, ²Rahardjo SB

¹Resident of Cardiology and Vascular Department, National Cardiovascular Center Harapan Kita

²Staff of Electrophysiology and Arrhythmia, Cardiology and Vascular Department, National Cardiovascular Center Harapan Kita

Background: Acute myocardial infarction (AMI)-induced ventricular tachycardia frequently occurs without warning, often leading to death within minutes in patients who do not receive prompt medical attention. The occurrence of ventricular arrhythmia in the setting of myocardial ischemia is the result of interplay between substrate, trigger, and modulating factors. These factors differ depending on the time course of ischemia, and so produce different electrophysiological mechanisms of arrhythmia.

Case Illustration: A 50-year-old male, with history of CAD 2VD, came to emergency room due to sudden black out and diagnosed as unstable VT (suspected RV moderator band origins), then got synchronized cardioversion immediately. 12-lead ECG revealed new Left Bundle Branch Block (LBBB) with positive Barcelona algorithm and Sgarbossa-Smith criteria for AMI in LBBB, but unfortunately he couldn't undergo primary PCI due to unknown onset of proven subarachnoid haemorrhage (SAH) from brain CT scan. He was treated only with single anti platelet (SAPT), and bisoprolol as chosen anti-arrhythmic agent due to prolonged JTc led to unavailability for amiodarone to be given.

Conclusions: The echocardiography of the patient showed 16% of LV ejection fraction and large area of akinetic – hypokinetic wall motion in anterior and inferior wall. Last data showed history of CAD 2VD, and newest AMI in LBBB criteria was met from Barcelona Algorithm, which could led the suspected cause of ischaemic VT was STEMI equivalent. We decided to optimize the anti-ischaemic therapy. The patient did not experience any recurrent VT without revascularization and was discharged from the hospital in stable condition.

Keywords: Ischaemic Ventricular Tachycardia, Left Bundle Branch Block, Barcelona Algorithm, Subarachnoid Haemorrhage

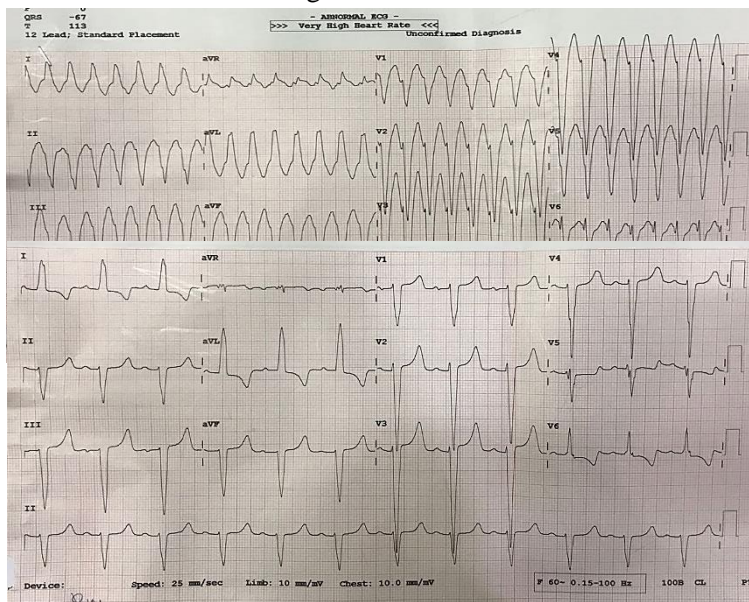


Figure 1. (Upper) Initial ECG showed Monomorphic VT from RV Apex Origins; (Lower) 12-lead ECG after cardioversion showed SR, Complete LBBB with Barcelona algorithm (+), LVH, Poor R Wave Progression

**The Wellens' Syndrome :
An Impactful Warning Sign of Critical Proximal LAD Stenosis**

¹Felani MR, ¹Baskoro C, ²Rosimarina V

¹Resident of Cardiology and Vascular Department, National Cardiovascular Center Harapan Kita

²Staff of Intensive and Acute Cardiovascular Care, Cardiology and Vascular Department, National Cardiovascular Center Harapan Kita

Background: The pattern of clinical findings and electrocardiography (ECG) changes known as Wellens' syndrome is associated with significant stenosis of the proximal left anterior descending coronary artery. Cases can be classified according to the ECG pattern into type 1 (biphasic T waves) or type 2 (deeply inverted T waves). These patterns are especially seen in V2–V3 leads during pain-free periods, and upright T-waves with possible elevated or isoelectric ST segments usually seen during pain episodes.

Case Illustration: We present a 61-year-old female, had diabetes and hypertension, who presented with typical chest pain. 12-lead ECG showed inferolateral subendocardial injury and left ventricular hypertrophy, the cardiac HsTroponin T was high, then we assessed as NSTEMI. Next day in Intensive Care Unit, wellens' syndrome type B was recognized. Emergent coronary angiography revealed severe CAD 3VD with subtotal stenosis of proximal left anterior descending coronary artery. Then the Heart Team Conclusions result for the case was coronary bypass arterial graft.

Conclusions: It is important to recognize the typical ECG findings of Wellens' Syndrome, because these characteristic ECG findings are considered as a marker for critical LAD occlusions. This case report underlines the importance of recognizing the electrocardiographic sign and its association with critical stenosis of the left anterior descending coronary artery. The recognition of these subtle ECG changes is crucial as early intervention could prevent significant morbidity and mortality.

Keywords : Wellens' Syndrome, LAD occlusion, Wellens', Acute MI

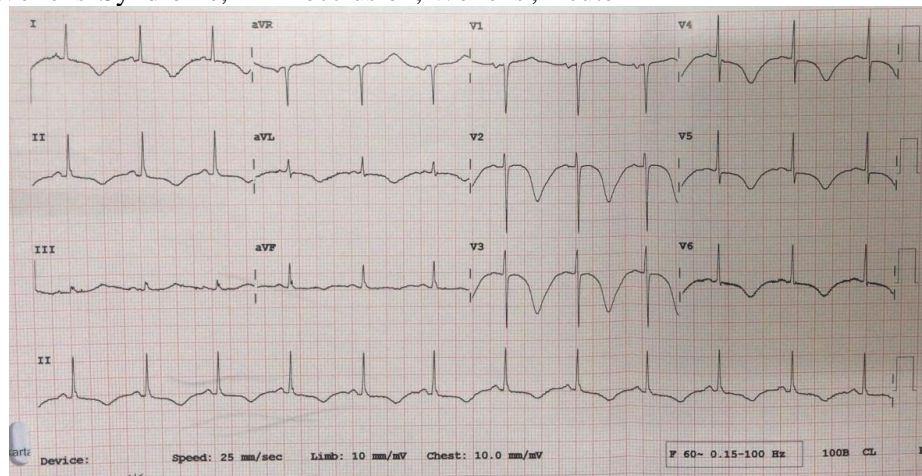


Figure 1. ECG of the following day in Intensive Care

Incessant Ventricular Tachycardia in Non ST Elevation Myocardial Infarction Patient: A Challenging Management in the Setting of Limited Cardiac Intervention Modalities

Prakasa M.D.¹, Handayani R.²

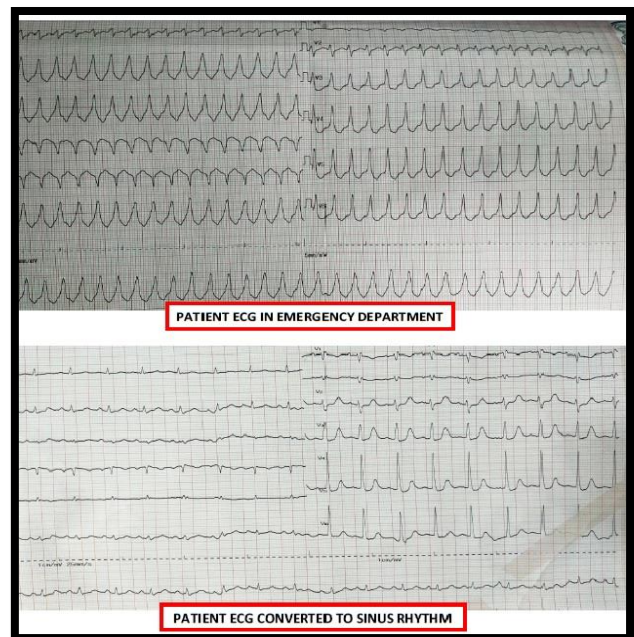
¹General Practitioner, Department of Cardiology, Urip Sumoharjo General Hospital Bandar Lampung, Lampung, Indonesia

²Cardiologist, Department of Cardiology, Urip Sumoharjo General Hospital Bandar Lampung, Lampung, Indonesia

Background: Ventricular Arrhythmias (VA) are important cause of cardiovascular morbidity and mortality, particularly in structural heart disease.¹ Obstinate Ventricular Tachycardia (VT) poses a threat to cardiovascular outcome and was quite frustrating to emergency physicians.²

Objective: Aim to review the case and literature of ventricular tachycardia

Case Illustration: Woman, 67 yo, was admitted with substernal heavy sensation since 2 weeks accompanied by palpitation 2 hours before admission. Examinations suggested unstable hemodynamic condition, BP was 80/50 mmHg, HR 192 bpm, Twelve-lead ECG showed monomorphic VT. The monomorphic VT was unresponsive to six progressive cardioversions which was given in arrow. Then antiarrhythmic drugs, magnesium sulfate and amiodarone were given intravenously followed by the maintenance dose and the patient was observed in ICU. After 3 hours the heart rhythm



began converted to sinus but still with several episodes of non-sustained VT. The imaging and laboratory examination was revealed cardiomegaly and marked increase of CKMB, then double antiplatelet, diuretic, nitrate and anticoagulant agent was administered. On the next day after several hours in stable condition, monomorphic VT was once again occurred with hypotension. Cardioversion then was given accompanied by antiarrhythmic drugs and once again the heart rhythm was converted to sinus and the unstable condition was overcome. After several hours of stable condition, the patient was transferred to hospital with more advance cardiac intervention modalities.

Conclusions: Incessant VT is defined as continuous sustained VT during several hours, which recurs promptly despite repeated intervention for termination.³ VA was associated with myocardial infarction (MI), the healing infarct undergoes structural changes which can lead to monomorphic VT when appropriate trigger occurs.⁴ In acute treatment of sustained ventricular arrhythmias presenting with monomorphic VT and haemodynamic instability should undergo direct cardioversion. Intravenous amiodarone may be considered in patients with HF or suspected ischaemia.⁵

Conclusion: Sustained VAs are a major cause of morbidity and mortality in patients with structural heart disease.¹ Refractory VT or Vfibr present many challenges for clinicians and devastating consequences may occur suddenly. Hemodynamic stability takes priority when any patient with tachycardia is being evaluated. Terminating VT in a timely manner is our first priority.²



Indonesian Journal of Cardiology

Indonesian J Cardiol 2021;42:suppl_C
pISSN: 0126-3773 / eISSN: 2620-4762
doi: 10.30701/ijc.1241

Keywords: *Incessant Ventricular Tachycardia, NSTEMI, Cardioversion*



Arrhythmia-Induced Heart Failure with Prolonged PR Interval, NSTEMI and Intraventricular Block in Young Woman at Primary Health care

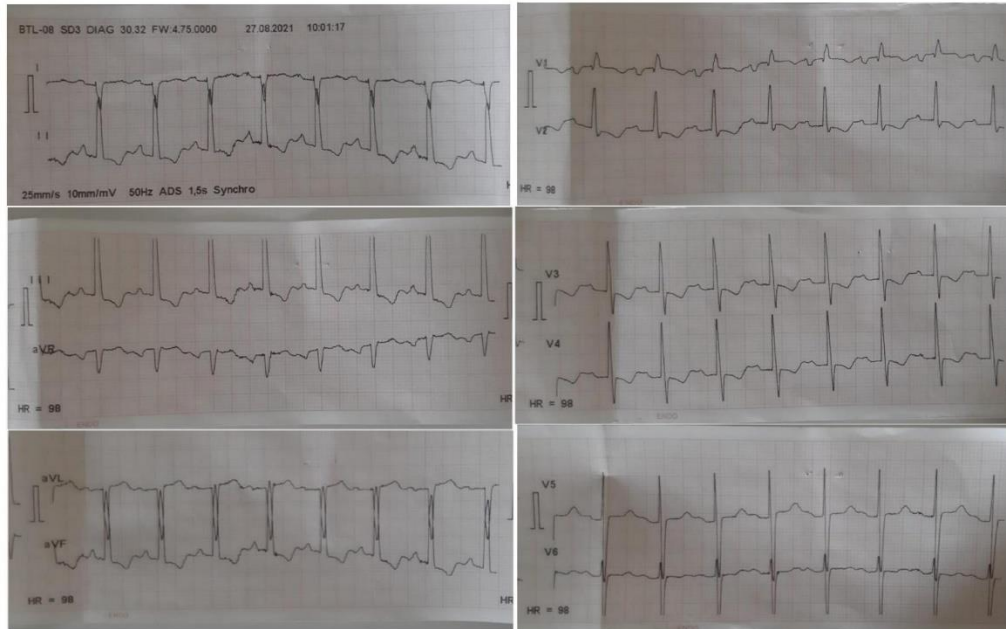
Rahmadhani, M.A.,

UPT. Puskesmas Singkawang Selatan 2, Singkawang, Indonesia

Background: Acute heart failure is a general condition we have seen in the emergency room. Even though, its condition can happen in primary health care. Acute heart failure in young woman, especially caused by NSTEMI and intraventricular block also have been made us pay attention in management and prognosis although in primary health care.

Case Illustration. 34 Years old woman came to primary health care with worsen dyspnea in 1 month. She denied any history of other diseases before. Initial vital sign examination: patient looks dyspnea, sits on the bed with extra respiratory muscle aid, Blood pressure 100/70 mmHg, pulse rate 90X/minute, respiratory rate 30x/minute, temperature 36^oC, saturation 99% with O₂ nasal cannula 6 lpm. Physical examination showed: JVP 5+3, heart sound S₃, ronchi both of basal lung, pitting edema in both of lower leg. Laboratorium was taken: SARS COV-2 antigen-negative and random blood glucose was 110 mg/dl. ECG was taken and showed: both atrial enlargement, LVH and RVH, prolonged PR interval, NSTEMI with LBBB and RBBB. Initial treatment was O₂ 6 lpm nasal cannula (there was no NRM), aspirin 320 mg, and ISDN 5 mg tablet sublingual one time.

Conclusions. When we get heart failure in a primary setting, not only how to recognize and initial treatment, but also how to keep quality of life after emergency treatment. Arrhythmia- induced heart failure can be seen in many variations. One of them is altered LV synchrony such as LBBB and RBBB which is seen in this patient. A young woman with heart failure, atrial enlargement, ventricular hypertrophy, NSTEMI, and intraventricular block was a complex case. We can assume there was another basic abnormality such as cardiomyopathy and need further investigation. Maybe this patient candidate for cardiac resynchronization therapy. We also can see prolonged PR interval in ECG that seems to be a marker of atrial and structural remodeling and it is associated with more severe heart failure disease.



Picture 1. ECG Of This Patient



Management of Reccurent SVT (AVNRT) on COVID-19 Patient in Remote Area

N. E. Sumolang¹, M. Fr. Hutapea²

¹General Practitioner, Harapan Insan Sendawar Hospital, West Kutai, East Borneo

²Cardiologist, Harapan Insan Sendawar Hospital, West Kutai, East Borneo

Background: Supraventricular tachycardia (SVT) is one of the commonly reported arrhythmia types in Corona Virus Disease-19 (COVID-19) patients. Reccurent SVT events might increase the mortality risk in patients, thus require ablation therapy. However, it is hard to receive ablation therapy in hospitals in remote areas due to limited facilities and human resources. Besides, it is also difficult to refer patients in this pandemic era due to the lack of available hospitals due to the high incidence of COVID-19 cases. In this paper, we report a case of reccurent SVT (AVNRT) in a COVID-19 patient relying on medical therapy at our Hospital in a remote area.

Case Illustration: A 70-year-old man was in seventh-day COVID-19 treatment complaining of weakness and palpitations. The ECG examination showed an atrioventricular nodal re-entrant tachycardia (AVNRT) with stable hemodynamics. He previously had Congestive Heart Failure (CHF) and Coronary Artery Disease (CAD) seven days ago. He is treated with Amiodarone 600 mg injection/day and Digoxin 0.25 mg once daily (OD). He had a resolution on the ninth day of COVID-19 treatment. We then reduced the therapy to Amiodarone 300 mg injection/day and Digoxin 0.25 OD. However, he repeatedly experienced an AVNRT-type SVT with stable hemodynamics on the 12th day of COVID-19 treatment. We continued his previous therapy and had a resolution three days later. We adjusted his therapy to amiodarone 200 mg t.i.d and digoxin 0.25 mg OD. On the 16th day of COVID-19 treatment, he had a repeated SVT type AVNRT with stable hemodynamics. We treated him with Amiodarone 150 mg bolus injection in 10 minutes followed by Amiodarone 600 mg/day and Digoxin 0.25 mg OD. He had a resolution the next day. Three days later, we adjusted his therapy to amiodarone 200 mg t.i.d and digoxin 0.25 mg OD. On the 23rd day, he had no symptoms with a negative COVID-19 PCR swab result, and he was discharged.

Conclusion: Medical therapy in COVID-19 patients with reccurent SVT cases shows a good prognosis. Thus, it might be considered as an alternative treatment if there is no access to gold-standard therapy (ablation).

Keywords: Reccurent supraventricular tachycardia, COVID-19, medical therapy



Chronic Coronary Syndrome with Uncontrolled Hypertension in Rural Area: How Far Can We Go?

N. V. Riana¹, A. Billy¹, Y. Sari²

¹General Practitioner, *Santo Antonius Jopu Hospital, Ende, Indonesia*

²Internist, *Santo Antonius Jopu Hospital, Ende, Indonesia*

Background: Chronic coronary syndrome (CCS) is a newly described classification devised by the European Society of Cardiology to replace the term “Stable Coronary Artery Disease (CAD).” Using this new lexicon, the disease atherosclerosis manifests as CAD is categorized into Acute Coronary Syndrome (ACS) and CCS

Case Illustration: A 57 years old woman came to outpatient clinic, complained about chest pain. She has felt this pain for 1 year. The chest pain gets worse when she does strenuous activity like climbing the stairs. She cannot locate the exact area of the pain, and it feels just like a discomfort or heaviness on the chest. The pain sometimes radiates to her left shoulder. The pain goes away after she took some rest. She has a history of uncontrolled hypertension and high total cholesterol level. Her blood pressure was 190/90 mmHg, heart rate 74 beats per minute, respiratory rate 20 breaths per minute, temperature 36° C, and oxygen saturation in room air was 98%. Her ECG showed T inverted in V1-V3, and total cholesterol level was 383 mg/dl. The patient was diagnosed with Angina Pectoris - Chronic Coronary Syndrome Class I, Hypertension Grade III, and Dyslipidemia. We treated the patient with oral Bisoprolol, Amlodipine, Simvastatin, and Aspilet. In her second visit to outpatient clinic, her chest pain was getting better, her blood pressure became 110/70 mmHg and the T inverted on her V3 lead came to isoelectric line.

Conclusions: Management of CAD has 2 main goals: reduce symptoms and ischemia and prevent myocardial infarction and death. The ideal approach toward patients with CCS continues to prove controversial in regard to the use of percutaneous coronary intervention and optimal medical therapy as compared to only optimal medical therapy. Medical management is pivotal in all patients with CAD. The first step is to identify and treat any associated diseases that can precipitate angina by increasing myocardial oxygen demand or by decreasing the amount of oxygen delivered to the myocardium. The second step is to manage CAD risk factors as well as to prevent myocardial infarction with lifestyle changes and pharmacological treatment.



Cardiogenic Shock in Atrial Fibrillation With Wolff-Parkinson-White Syndrome In Rural Area : What Can We Do?

N. V. Riana¹, A. Billy¹, Y. Sari²

¹General Practitioner, *Santo Antonius Jopu Hospital, Ende, Indonesia*

²Internist, *Santo Antonius Jopu Hospital, Ende, Indonesia*

Background: Atrial fibrillation (AF) is a potentially life-threatening arrhythmia in patients with WPW syndrome as it can degenerate to ventricular fibrillation (VF). Wolff-Parkinson-White syndrome (WPW) is the most common form of ventricular pre-excitation. It appears on electrocardiogram as a short PR interval, a wide QRS complex and a delta wave. Patients with WPW syndrome are potentially at risk for ventricular arrhythmias due to conduction in the lateral passageway, resulting in very rapid ventricular depolarization if an atrial fibrillation or atrial fibrillation occurs.

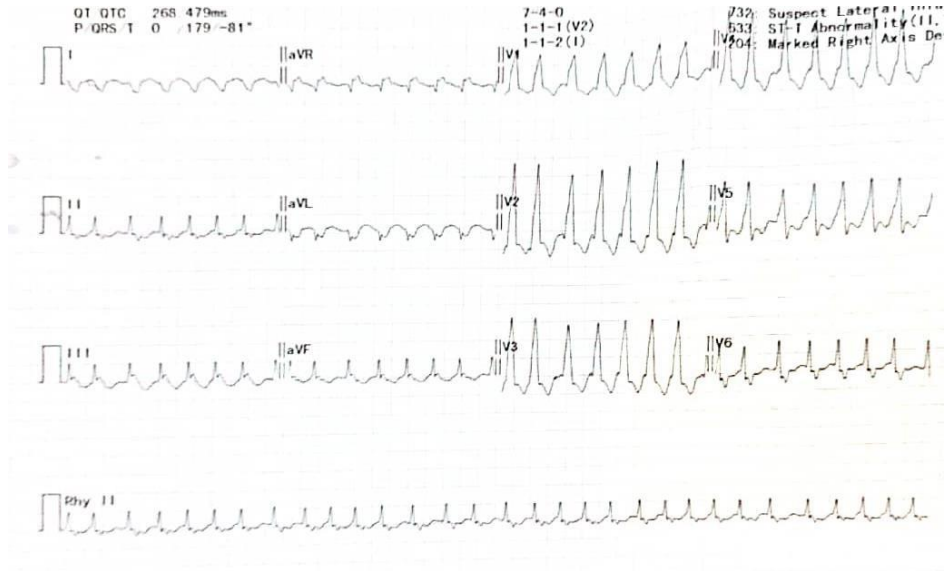
Case Illustration: A 52 years old woman came to emergency department with palpitations and shortness of breath since 2 days ago. Ankle swelling, ascites, and bilateral basal rales was found on her physical examination. Her blood pressure was 80/60 mmHg, heart rate 180 beats per minute, respiratory rate 28 breaths per minute, temperature 36° C, and oxygen saturation 93% on room air. The initial 12- lead ECG revealed irregularly irregular rhythm, narrow and broad complexes at a rate of 207 beats per minute. The patient was diagnosed with Cardiogenic Shock with Atrial Fibrillation and Wolff-Parkinson-White Syndrome. We treated the patient with Furosemide Injection, oral Bisoprolol, Digoxin, and Clopidogrel. The patient was admitted to the hospital and after 2 days, her heart rate went down to 97 beats per minute, her condition was better and prepared for referral.

Conclusions: The management of atrial fibrillation with pre-excitation is complex and can result in significant morbidity and mortality if not correctly recognized and treated appropriately. One of the treatments that is more aggressive but is also recommended for the treatment of WPW is accessory pathway ablation. By doing this, accessory pathways are eliminated, or their number is reduced, which in addition to treating WPW and removing the delta wave. In those who do not have surgery, flecainid is used in combination with bisoprolol, which is an effective way to control PSVT or AF, which can eventually eliminate the wave on the ECG. Class III anti arrhythmic (amiodarone) and AV node blockers (β -blockers, calcium channel blockers and digoxin) should not be used for pre-excited AF.



Indonesian Journal of Cardiology

Indonesian J Cardiol 2021;42:suppl_C
pISSN: 0126-3773 / eISSN: 2620-4762
doi: 10.30701/ijc.1241





Managing Pediatric Rheumatic Heart Disease With Massive Pleural Effusion In Limited Setting

N. Alexandra¹, J.D. Sutantio²

¹General practitioner RSUD Ende, East Nusa Tenggara

²Pediatrician RSUD Ende, East Nusa Tenggara

Background: Rheumatic heart disease (RHD) is still prevalent in developing countries, especially in places with limited access to health facility and dense population. Numerous issues may arise as congestive heart failure develops. Massive pleural effusion counts as a rare complication, but often results in grave outcomes. We aim to report the management of massive pleural effusion as a complication of RHD in a limited facility.

Case Illustration: An 11-year old boy was referred to the emergency room with shortness of breath for month, worsening in the past 2 days, despite resting. Since the last 3 months, he also complained of pink frothy sputum and generalized edema, from face to limbs. Recurrent upper respiratory infections with no antibiotic treatment were reported. There was no history of fever, cyanotic appearance, nor tuberculosis contact. On admission he presented with tachycardia, tachypnea, oxygen desaturation, hypotension, severe chest retraction, generalized edema, and severe malnutrition. Chest physical examination also revealed diminished bilateral lung sounds, mid-diastolic and holosystolic murmur at the heart apex radiating to the axilla. Laboratory results showed positive ASTO and slight hypoalbuminemia (2,8 g/dL). ECG test was consistent with left atrial enlargement and left ventricle hypertrophy, while the chest X-ray demonstrated bilateral pleural effusion, and cardiomegaly. The patient went through repeated pleural drainage procedures, and was treated with benzathine penicilin G. Fluid restriction, captopril, furosemide, and dobutamine were administered to treat the heart failure. Intensive nutritional therapy was also given to overcome the malnutrition. A repeat chest X-ray two weeks later showed significant improvement. The patient recovered well, and was planned to be referred to a pediatric cardiologist for echocardiography and further monitoring.

Conclusions: Despite health and medical developments, RHD is still common and sometimes complicated with atypical presentation, such as massive pleural effusion. Timely interventions, including treatment of heart failure and pleural drainage are important to improve patients' condition and should be taken regardless of limited facilities.



Paroxysmal Atrial Flutter Associated With Covid-19 Infection Concomittant With Av Block : A Case Report

O. S. Hasan, A. H. Nashar, M. Amira

*Cardiology and Vascular Medicine Department, Medicine Faculty of Hasanuddin University

Background: Severe Acute Respiratory Syndrome Coronavirus 2 (SARS-CoV-2) infection that causes Coronavirus disease 2019 (COVID-19) has reached pandemic state. Some cases have been reported that there are cardiac manifestations caused by COVID-19 infection, including atrial flutter. In other side, patient with pre-existing Coronary Artery Disease may have silent AV Conduction disturbance. Atrial flutter with AV nodal blockade is a condition that tends to be life-threatening for bradycardia, especially when the co-morbid such as COVID-19 infection occurs. This case report will discuss a patient with arrhythmia concomittant with COVID-19 infection.

Case Illustration: A 60-year-old patient with complaints of sudden loss of consciousness was referred with diagnosis NSTEMI, Atrial Flutter. Patient also complaints of shortness of breath, electrocardiography rhythm indicating Total AV Block, then changed to Atrial Flutter with 8:1 conduction. On SARS-CoV-2 nasopharynx swab there is reactive result, so that the patient is also diagnosed as COVID-19 infection. Then the pacing was performed and single-chamber pacemaker was installed.

Conclusions: Treatment options for arrhythmia have increased in recent years to include a combination of drugs, medical tools, and non-invasive procedures that can relieve symptoms and improve survival. Although in the course of progressive supraventricular arrhythmia can be life-threatening concomittant with treatment of coronary event, will be challenging if there is concomittant with COVID-19 infection. Future research on the pathophysiology of Arrhythmial-related Coronary Artery Disease concomittant with COVID-19 infection and therapeutic options is needed to improve quality and life expectancy.

Keywords: Atrial Flutter, Total AV Block, COVID-19, Management and Therapy



Recurrent Supraventricular Tachycardia In Neonates: Wolff-Parkinson-White Syndrome, Should We Ablate?

P. A. Trisnasari, D. W. Anggrahini, E. Maharani, I. K. Murni,

Faculty of Medicine, University Gadjah Mada, D.I. Yogyakarta, Indonesia; National General Hospital Dr. Sardjito, Yogyakarta, Indonesia

Background: Supraventricular tachycardia (SVT) is the most common non-benign tachycardia among neonates, and reentry tachycardia via accessory pathway (AP) is the most common SVT in neonates and infants. Most episodes of SVT occur during the 1st month of life. Approximately 55-60% of AP will manifest on the surface electrocardiogram (ECG) as varying degrees of ventricular pre-excitation, the Wolff-Parkinson-White (WPW) ECG pattern or WPW syndrome in symptomatic individuals. The natural history and prevalence of neonatal SVT is in striking contrast to those seen in older children and adults, making it an important issue for the physician to be vigilant for diagnostic and therapeutic options.

Case Illustration: We report a 16-days old neonate that was referred from regional hospital with persistent SVT and pneumonia. The chief complaint was poor breastfeeding and looked lethargic. Patient had tachycardia (rate 250 bpm) with stable hemodynamic condition. Electrocardiogram showed long RP SVT. In NICU of Sardjito Hospital, although the patient got oral propranolol, we suspected the ECG was auto-convert to normal sinus rhythm after the pneumonia was resolved. The converted ECG showed short PR interval and delta wave in precordial lead especially in lead V1-V3. Since echocardiography showed functionally and structurally normal heart, so we diagnosed the patient with WPW syndrome. In the follow up, this patient had recurrent SVT every month especially when the patient had fever despite routine consumption of high dose of propranolol.

Conclusions: Supraventricular tachycardia in neonates will eventually cease spontaneously, usually early in the first year of life. Chronic treatment is considered in the first few years of life in case of poorly tolerated symptoms and frequent attacks until the patient reaches the age at which nowadays elective invasive and curative treatment with ablation. Ablation is recommended for children with age > 4 years old or weight > 15 kg, especially patient with pre-excitation syndrome who had recurrent SVT after getting optimal doses of drugs therapy.



HIS Bundle pacing in young patient with Sinus Node Dysfunction

R. Bernardus¹, G. Karwiky¹

Department of Cardiology and Vascular Medicine, University of Padjajaran, Dr Hasan Sadikin General Hospital, Bandung Indonesia.

Background: Sinus node dysfunction in young adult who underwent permanent pacing have been studied since 1960 and 1983. The incidence is relatively uncommon in normal cardiac anatomy and the exact incidence is unknown. However, it is a common problem in those who have had surgery for congenital heart disease (CHD), especially patients with Mustard, Senning, and Fontan procedures. The incidence of AV block in young adults is approximately 8%. Scientific literature is surprisingly scarce regarding the etiology of complete AV block in healthy young and middle aged adult population. Coronary artery disease, autoimmune disorders such as systemic lupus erythematosus or rheumatoid arthritis, history of acute or chronic infectious or hypersensitivity myocarditis, infiltrative process, hypothyroidism, congenital cardiopathies such as left ventricular noncompaction or Ebstein anomaly, lamin A/C mutations, and pathologic hypervagotony and idiopathic degenerative scleroatrophy or the atrioventricular junctional specialized tissue (Lenegre – Lev disease) are among the most frequent etiologies. Right ventricular pacing has been reported to result in ventricular dyssynchrony, heart failure, and increased mortality. Pacing associated deterioration of left ventricular systolic function has been termed pacing-induced cardiomyopathy (PICM), permanent His-bundle pacing (HBP) can be physiological alternative to biventricular pacing (BiVP) which is an effective therapy for PICM. We present a young patient with SA and AV nodal block who underwent HBP.

Case Illustration: A 20 years old male with symptoms of weakness and syncope, the patient was hemodynamically stable with sinus bradycardia and 1st grade AV block. Electrophysiology study was performed and His bundle pacing was implanted. Electrophysiology study results showed sinus node and AV node dysfunction with infrequent premature ventricular contraction and non sustained atrial flutter. AH interval was extremely prolonged (312 ms) with normal HV interval (45 ms), Prolonged sinus node recovery time and corrected sinus recovery time. AV node effective refractory period was 820 ms. His bundle pacing in dual chamber was the treatment for this patient with stable threshold in 1.75.

Conclusions: Young age patient with symptoms related to cardiac conduction abnormality should be worked up for its reversible etiology. The patient first present to cardiologist with ECG showing sinus node dysfunction but pacing was deferred due to his young age and possibility of reversing the arrhythmia. However, after 1 year of follow up the symptoms persists and further evaluation by electrophysiology was performed and the result suggest for HBP pacing. Pacing the His bundle normalized the conduction abnormality and resolved the symptoms in patient. Follow-up after pacing for evaluation of symptoms and echocardiography to measure cardiac function, contractility, and synchrony using global longitudinal strain (GLS) has been performed.

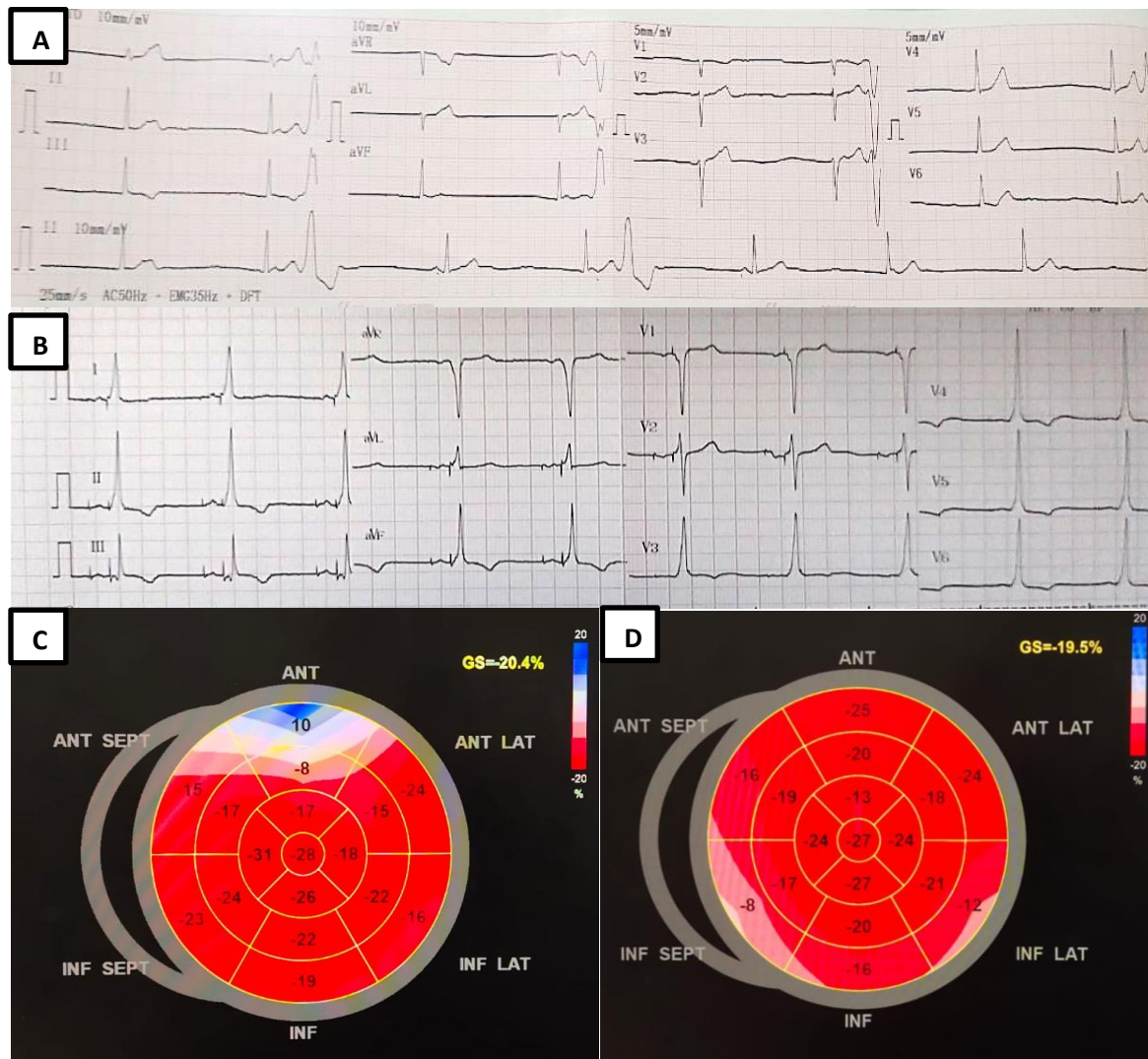


Figure 1. (A) ECG before pacing showed sinus node dysfunction with ventricular extrasystole. (B) ECG after successful His bundle pacing with threshold 1.75 (C) Echocardiography global longitudinal strain pre HBP (D) GLS 1 week post HBP

Keywords.: His bundle pacing, young age, sinus node dysfunction, GLS, syncope.



Congenital Total Atrioventricular Block: A Case Report

R. Maulidia¹, A. C. Lubis², H. Hasan³

¹Cardiology Resident at Cardiac Center H. Adam Malik Hospital, Faculty of Medicine Universitas Sumatera Utara, Medan, Indonesia

^{2,3}Cardiologist at Cardiac Center H. Adam Malik Hospital, Faculty of Medicine Universitas Sumatera Utara, Medan, Indonesia

Background: The incidence of congenital heart block has been estimated to be about 1 in 22,000 live births. The pathophysiological process is believed to be due to immune-mediated injury of the conduction system. Although this is clearly an uncommon disorder, it may be associated with high mortality and morbidity and therefore requires a high index of suspicion for early diagnosis and aggressive therapy when appropriate.

Case Illustration: A 3-days-old newborn baby came to emergency room with slow heart rate. This condition already known since 4 months into pregnancy and we found out that the mother was diagnosed with SLE. The baby was delivered by c-section with birth weight of 2380 gram, no sign of cyanotic or dyspnea. From the ECG we found a total atrioventricular block with recorded heart rate 51 bpm. From the echocardiography we found a moderate ASD secundum and small PDA. We implanted the pacemaker mode VVI, heart rate adjusted to age. We placed the lead in epicardial and the generator in peritoneum. From the ECG evaluation after PPM implantation showed a ventricular pacing rhythm with heart rate 120 bpm. In follow up, baby who previously failed to thrive are now gaining weight after implantation.

Conclusions: Although the indications for PPM implantation are clearly defined, the issue whether endocardial versus epicardial lead placement remains to be clarified. However many groups standardly used epicardial pacing as endocardial pacing carried significant venous thrombus in infant. The smaller volume of paced pediatric patients does not provide enough information and clinical decisions, and needs further investigation regarding this issue.

**Adult woman with a permanent pacemaker,
Suffering from Breast Cancer on the same side and its complications**

R. Novia¹, S. Murdiati¹, T. Heriansyah¹

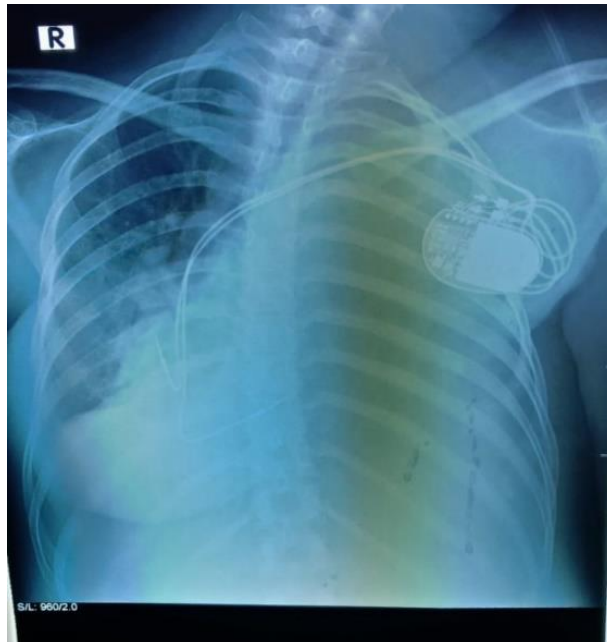
¹Department of Cardiology and Vascular Medicine, Medical Faculty, Universitas Syiah Kuala, Banda Aceh, Indonesia

Background: Breast cancer is the most common cancer among Indonesian women, with a prevalence rate of 42.1 per 100,000. However, breast cancer and the need for a pacemaker are rare, and implantation of the device in these cases may be a technical challenge. A patient who has had a pacemaker implanted and develops cancer on the same side of the body may be an example.

Case Illustration and Conclusions: A 30-year-old woman presented to the emergency room with a report of a rotting wound on her left breast, paleness, swelling of her left hand and leg, and shortness of breath despite even light movement. The woman had a Permanent Pacemaker implanted two years prior and had her breast surgically removed six months later due to breast cancer. On physical examination, we found the left pulmonary sound was very weak compared to the right, superior oedema on the left side, as well as on the inferior Sinistra limb, with limited range of motion. The laboratory found that Hb 8,5g/dL. On the ECG, we found V-Paced Rhythm with a QRS rate of 100Bpm. Massive left Pleural Effusion with Pacemaker-type DDDR discovered on the Thorax Photo. Then we administered intensive care, performed blood transfusions, and installed a water seal drainage system (WSD), When the patient was stable, she was provided chemotherapy, and performed an integrated PPM evaluation.

Conclusion: Although the patient had breast cancer in the same region, no anomalies in PPM function were discovered due to the pacemaker location and positioning accuracy. On otherwise, radiation therapy may have a variety of results.

Keyword: Pacemaker, Breast cancer, ECG



Atrial Fibrillation with Rapid Ventricular Response in Community Health Center Setting: What Should We Do?

R. I. Rismawanti¹, L. A. Wijaya², S. P. Agus¹, M. B. Rachmanadi¹

¹Faculty of Medicine, Public Health and Nursing, Universitas Gadjah Mada, Yogyakarta, Indonesia

²Tempel I Community Health Center, Sleman, Yogyakarta, Indonesia

Background: Atrial fibrillation (AF) is one of the most common arrhythmias that has high mortality and morbidity due to the risk of cardioembolic stroke and heart failure. Thus, proper and prompt treatment is the key to a better prognosis. However, the type of health service where the patient is located is clearly an important factor in determining the therapy's precision and quickness.

Case Illustration: A woman, 62 years old, presented to the ER of Tempel I Community Health Center with recurrent vomit and nausea an hour before admission. She admitted having cold sweat without angina symptoms but refused to have headache and syncope. Previously, she had arrhythmia and hypertension in the last 3 years but was non-adherent to drug consumption. On physical examination, BP 229/126, HR 123, RR 20, SpO₂ 99% room air, non-febrile, body weight 37kg, height 150cm, other findings within normal limits. ECG showed AF with rapid ventricular responses. A routine blood test showed leucocytosis 15.100, neutrophil segment 82%, lymphocyte 11%, and rapid antigen SARS-COV2 negative. She was diagnosed with AFRVR, hypertensive emergency, and suspect angina atypical, then received oxygen, captopril 25mg SL, and ISDN 5mg SL. She got referred to RS PKU Gamping.

Conclusions: The community health center (CNC) is one of the health facilities that are widely spread in the community. Due to its close location, people tend to go to CNC first before going to the hospital to get initial therapy. When it comes to initial care for serious illnesses, the medications offered at the CNC are limited in comparison to those at the hospital. As a result, it is vital to give patients initial treatment based on their condition, then find an appropriate hospital to get them referred to. But, in a pandemic situation, this is quite difficult to do. Obstacles can be obtained from the readiness of supporting examinations at the CNC, the availability of transportation modes, and the availability of services at the destination hospital. Therefore, good cooperation between health services is needed to provide the best service for patients.

Keywords: atrial fibrillation, atrial fibrillation with rapid ventricular response, community health care

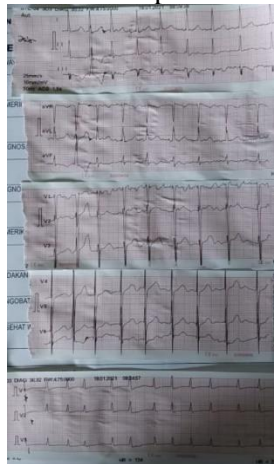


Figure 1. ECG at ER Tempel 1 CNC showed AFRVR

A Rare Case of Newly Onset Complete Heart Block in a COVID-19 Patient with ARDS: a case report

¹S.G. Pradipta, ¹C. R. Kurniawan, ²A. B. Kurniawan,

¹*Emergency Department, General Hospital of Sidoarjo, Sidoarjo, Indonesia.*

²*Cardiovascular Department of General Hospital of Sidoarjo, Sidoarjo, Indonesia.*

Background: Corona Virus Disease-19 (COVID-19) has become a major concern in the world. Respiratory manifestation is the main manifestation but it can also have other manifestation, one of them is cardiovascular manifestation. The arrhythmia manifestation of COVID-19 is one of the rare cardiovascular manifestations and is still not well understood and reported. To provide more insight and triggering further research, we present a case of Complete Heart Block in a COVID-19 patient.

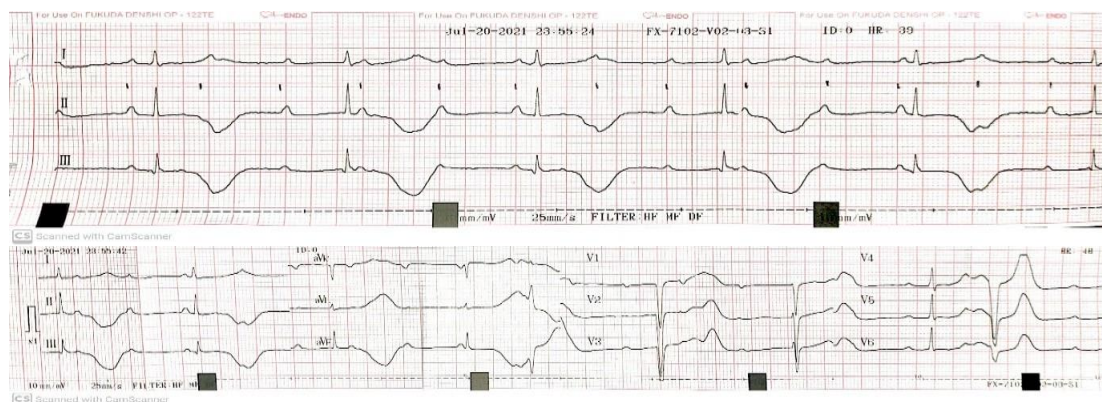
Case Summary: A 45-year old woman presented with decreased consciousness preceded by fever, dry-cough, and *dyspnea*. She has no prior significant illnesses. She was somnolent, tachypneic, and bradycardic, hypoxic, and having crackles on both lung fields. The Electrocardiography showed complete heart block. Her laboratory results showed leukocytosis, increased High Sensitivity Troponin, and D-Dimer. The BGA showed that she had respiratory acidosis compensated with metabolic alkalosis. Her chest radiograph was pneumonic. Her RT-PCR for COVID-19 was positive. Transient pacemaker wasn't available at the moment, and referral to the higher center wasn't possible due to the COVID-19 surge. Our management includes oxygen supplementation, antibiotics, dopamine infusion, and heparin. The patient kept deteriorating and ended up dead on her fourth day of hospitalization despite our best effort at that moment.

Conclusions

New-onset high degree AV block may occur in patients with COVID-19. The mechanisms are still not well understood but may be vagally mediated because of neuroinvasion or hypoxia. Direct injury to cardiac myocytes systemic inflammation, and drug interaction may be considered as the culprit mechanism. All medication and drug interactions causing bradycardia should be avoided. Dopamine or atropine should be injected. The need of transient and permanent pacemaker implantation should be checked, rechecked and considered. Our patient was presented with complete heart block. It may be caused by multiple causes including myocardial injury, systemic inflammation, and the severe hypoxia creating vicious cycle and inducing the heart block. Transient pacemaker was a must but impossible due to the limited resources and inability of referring into the higher center caused by the COVID-19 surge.

Keyword: Complete Heart Block, Bradyarrhythmia, Covid-19

Fig. 1 The ECG of the patient showed Total AV block with 42 Ventricular rate and Junctional Escape Rhythm.



Sinus Node Dysfunction in a patient with Multimorbidity: A Case Report

S.P. Agus¹, H.H. Qolbi², R.I. Rismawanti³, M.B. Rachmanadi³, R. Yandriani⁴

¹Internship Doctor, Semen Padang Hospital, Padang, Indonesia

²General Practitioner, Semen Padang Hospital, Padang, Indonesia

³Faculty of Medicine, Public Health and Nursing, Universitas Gadjah Mada, Yogyakarta, Indonesia

⁴Cardiologist, Semen Padang Hospital, Padang, Indonesia

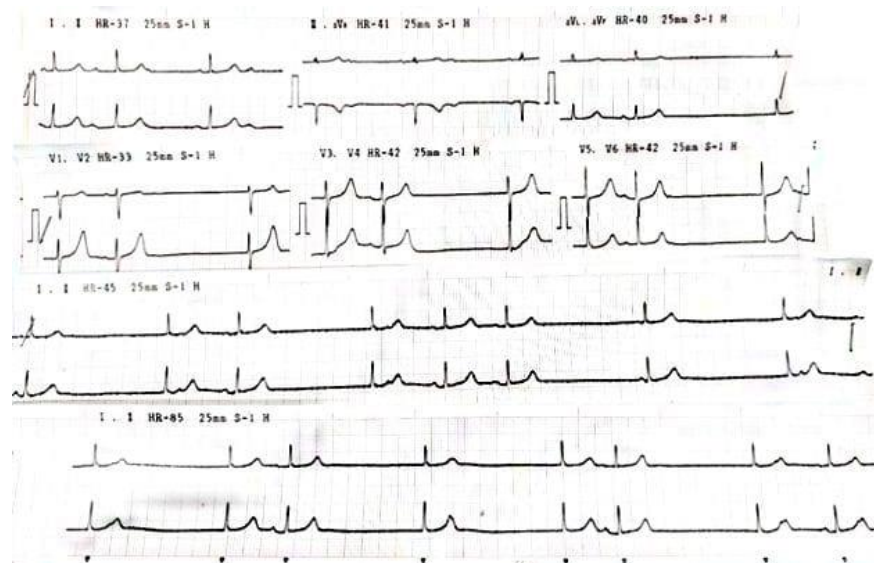
Background: Sinus Node Dysfunction (SND) occurs when the sinus node fails to function as the pacemaker of the heart. SND can be caused by intrinsic or extrinsic causes. The relationship between SND and mortality is difficult to understand as SND patients are generally older and have pre-existing comorbidities which are known to increase mortality.

Case Illustration: A 77-year-old female presented to the ER with dyspnea, severe fatigue, and chest discomfort 5 hours before admission. She had history of Coronary Artery Disease (CAD) which was treated conservatively, hypertension, and Diabetes Mellitus (T2DM) on insulin therapy. On physical examination, BP 127/77, HR 42 irregular, RR 28, non-febrile, SaO₂ 96%, E4V5M6, pulmonary rales ++ and pitting edema ++. ECG Test: Sinus Bradycardia with periods of complete heart block and junctional escape beat. We assessed the patient with SND ec suspect intrinsic causes with differential diagnosis ec suspect mild hyperkalemia with CAD, CHF NYHA fc IV, AKI dd CKD grade 4, mild anemia, and T2DM. She received oxygen and atropine sulfate 0.5 mg but there was no improvement, then dopamine 5 mcg/kg/min up-titration until 10 mcg/kg/min was added. The hyperkalemia was treated with Glucose-Insulin protocol which is calcium gluconate 1 gram and Insulin 10 IU with 50 cc D40% followed by 20 mg furosemide injection and Calcium Polystyrene Sulphonate oral. After 15 minutes, there was an improvement, RR became 22, HR increased to 62, serum potassium was still 5.7 mmol/L but the ECG rhythm hadn't changed. We repeated the Glucose-Insulin protocol 3 times, but there were no improvements. Then she got referred to Dr. M. Djamil Central General Hospital for further assessment and definitive treatment.

Conclusions: In this case, we couldn't determine the primary causes of SND, but we suspected the intrinsic causes such as ischemia, fibrosis, degenerative disease and extrinsic cause which was mild hyperkalemia might alter the sinus node function. The goal of our treatment was to improve the patient's symptoms using pharmacological agents. Further specific examination is needed to determine the cause of SND.

Keywords: sinus node dysfunction, hyperkalemia

Figure 1



Recurrent of Atrioventricular Nodal Reentry Tachycardia (AVNRT) Initiated with Sinus Tachycardia and Atrial Flutter 2:1 Block Episode in Covid-19 Patient A Case Report

S. S. Nugrahanti¹, S. A. Taroeno², A. Yasa³

¹General Practitioner of PKU Muhammadiyah Surakarta Hospital, Central Java

²Internal Medicine of PKU Muhammadiyah Surakarta Hospital, Central Java

³Cardiologist of PKU Muhammadiyah Surakarta Hospital, Central Java

Background: Atrial Arrhythmias are common among patients with COVID-19 who require admission to an intensive care unit and are often followed by hemodynamic deterioration.²

Case Illustration:

First Hospitalization

A 51 years old female patient came to Emergency Department with shortness of breath, cough, nauseous, vomit and fever. Blood pressure was 174/105. Respiratory rate was 30. Pulse was 137. Body temperature was 38,5. Arterial Oxygen Saturation was 80%. PCR of SARS Cov2 was positive. The initial 12 Lead-ECG recording showed Sinus Tachycardia. After 4 days treatment, the patient's heart rate become faster and the 12 Lead-ECG showed Atrial Flutter with 2:1 Block. In the 22nd days of treatment, the ECG monitor changed to Atrioventricular Nodal Reentrant Tachycardia (AVNRT). But, after 29 days treatment, patient's heart rate become normal steadily and patient was discharged from hospital.

Second Hospitalization

After 6 days being discharged, the patient admitted to Emergency Department again with palpitation. Blood pressure was 91/63. Respiratory rate was 32. Pulse was 174 beat per minute. The 12 Lead-ECG recording showed as below:

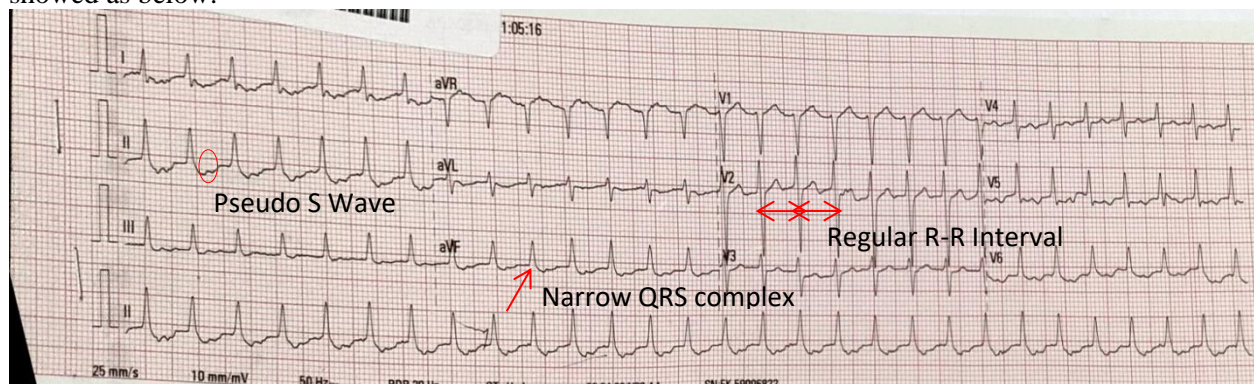


Figure 1. Slow-Fast AVNRT

The underlying mechanisms of cardiac arrhythmia in patients with COVID-19 are thought to be multifactorial: (i) Cardiac injury (ii) Over-activation of the immune system (iii) QTc-interval prolongation (iv) Precipitated by other co-pathologies (v) Arrhythmias independent of COVID-19

Conclusion: Cardiac Arrhythmia, including atrial arrhythmias may be the consequences of direct effects of COVID-19 infection, but also the outcome of the detrimental effects of systemic illness and the adverse proarrhythmic reactions to drugs.

Keyword: COVID-19, Cardiac Arrhythmia, Atrial Arrhythmia, Complications

From Total Atrioventricular Block (TAVB) Switched to Ventricular Tachycardia (VT) in Different Episode in 41 Years-Old Male Patient with Low Ejection Fraction

A Case Report

S. S. Nugrahanti¹, A. Yasa²

¹General Practitioner of PKU Muhammadiyah Surakarta Hospital, Central Java

²Cardiologist of PKU Muhammadiyah Surakarta Hospital, Central Java

Background: Cardiac Arrhythmia is simply defined as a variation of the normal heart rate and/or rhythm that is not physiologically justified¹.

Case Illustration:

First Hospitalization

A 41 years old male patient came to Emergency Department with general weakness, shortness of breath, chest pain with diaphoresis, vomit and having cold and cough for two days. Blood pressure: 92/56. Respiratory rate : 24. Pulse : 42 . There were cardiomegaly and bronchopneumonia on Chest X Ray. The ECG recording showed Total Atrioventricular Block and his Echocardiography showed: LV Dilatation, Akinetic of Mid Anteroseptal Segment (Apical Anterior), Hypokinetic of other segment and LVEF was 23 %.

Second Hospitalization

Two months after discharged, the patient got re-admission with vomit, diaphoresis, shortness of breath and general weakness. Blood pressure: 79/54. Respiratory rate: 28. Pulse: 172. The Calcium serum was 9,9. The ECG recording showed as below:

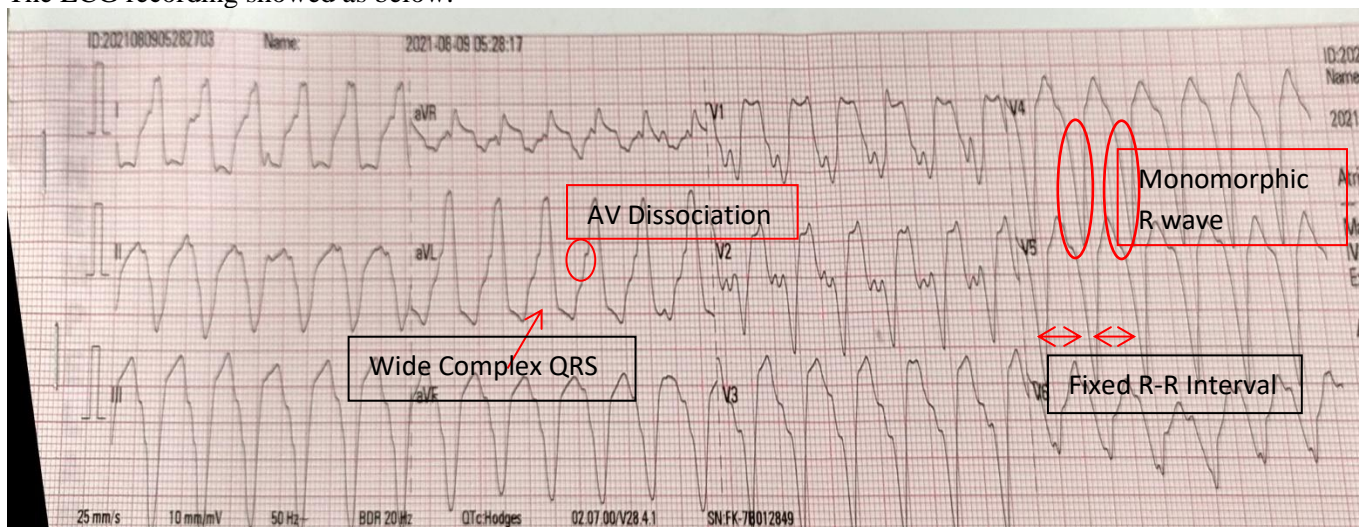


Figure 1. Monomorphic Ventricular Tachycardia

Monomorphic VT in structural heart disease is often caused by scar related re-entry, besides DAD mechanism. Delayed After-Depolarizations (DADs) are transient depolarizations in the diastolic phase following an action potential (AP). If the Amplitudo of Delayed After Depolarization reaches threshold voltage, an action potential will be generated that can be self perpetuating and lead to tachyarrhythmias. DADs are observed under conditions of intracellular calcium overload²



Indonesian Journal of Cardiology

Indonesian J Cardiol 2021;42:suppl_C
pISSN: 0126-3773 / eISSN: 2620-4762
doi: 10.30701/ijc.1241

Conclusion: In the form of Monomorphic Tachycardia that was recorded in the second admission, probable relates to Scar related Re-entry or Delayed After-Depolarization mechanism that was caused by high intracellular calcium (Ca: 9,9) condition.

Keyword: Total Atrioventricular AV Block, Ventricular Tachycardia, Delayed Afterdepolarization, Tachyarrhythmia



His Bundle Pacing in Complete Heart Block with alternating RBBB and LBBB Escape Rhythm

S. V. Putri¹, W. W. A. Shariefuddin², G. Karwiky², M. Iqbal², C. Achmad²

¹ Department of Cardiology and Vascular Medicine, Universitas Padjadjaran, Dr. Hasan Sadikin General Hospital, Bandung, Indonesia.

² Department of Cardiology and Vascular Medicine, Universitas Padjadjaran, Dr. Hasan Sadikin General Hospital, Bandung, Indonesia.

Background Conventional right ventricular (RV) apical pacing has been the standard practice for patients requiring permanent ventricular pacing. However, RV apical pacing have a long-term effect associated with structural changes, conduction dyssynchrony and increased risk of death. His bundle pacing (HBP) has become a new frontier in the prevention and treatment of heart failure. HBP can normalize complete heart block with infranodal disease in 76% patient.

Case Illustration A 60 years man with a chief complaint of shortness of breath and fatigue. Electrocardiography examination revealed complete heart block with alternating ventricular escape rhythm, complete right and left bundle branch block. After a TPM placement, ECG showed RV pacing without any own beat. Echocardiography examination show concentric LV remodeling, normal LV systolic function with normokinetic at rest, diastolic dysfunction grade I. Global longitudinal strain (GLS) echocardiography in this patient after TPM placement show GLS score -9.7%. We decided to perform HBP for this patient due to consideration sign of bundle branch block. HBP successfully implanted with threshold non-selective capture 0.75 V and corrected the bundle branch block with QRS duration 116 msec. In a month follow-up, we carefully manage the reprogramming of the pacemaker, based on the best cardiac output calculation from echocardiography, we found an improvement of the GLS score to -19.5% for this patient. Follow up in 1 year patient was asymptomatic with preserved echo and stable pacemaker parameter.

Conclusions HBP is become a new frontier in management of third-degree AV block and most commonly been considered as an alternative to RV pacing, increasingly considered in patients with bundle branch blocks. The needs to evaluate the hemodynamic and function of the heart after HBP implantation become important to prevent any problems regarding HBP and to make a better outcome for the patient. In this patient, after HBP implantation, there is an improvement of the sign and symptoms and also a narrower of QRS duration on the ECG. After AV delay management in this patient there was an improvement in GLS scoring and an improvement in hemodynamic functions.

Keywords His Bundle Pacing; Third-degree AV block, Bundle branch blocks, GLS, Case report

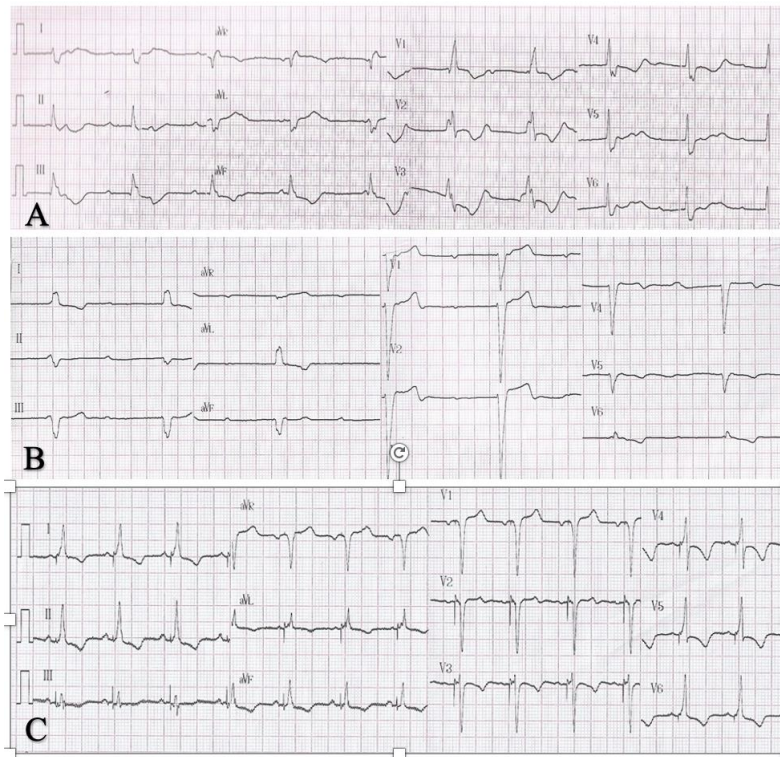


Figure 1. **A.** Complete Heart Block with RBBB escape rhythm with QRS duration 155 ms, **B.** Complete Heart Block with LBBB escape rhythm with QRS duration 160 ms, **C.** His Bundle Pacing corrected a complete heart block with QRS duration 116 ms.

Twenty Years-Old Primipara with Late Onset PPCM Complicated by Cardioembolic Stroke: A Rare Case Report

T. A. Mirza¹, R. D. Akbar², A. N. Rukanta³, A. Rifai⁴

¹Emergency Department, Ciremai Army Hospital, Cirebon, Indonesia,

²Cardiology Department, Ciremai Army Hospital, Cirebon, Indonesia

³Emergency Department, Pertamina Hospital, Cirebon, Indonesia

⁴Radiology Department, Dr. Hasan Sadikin General Hospital, Bandung, Indonesia

Background: We encounter a case of primipara with Peripartum Cardiomyopathy (PPCM) complicated by cardioembolic stroke.

Case Illustration: A 20-year-old woman came to the ER with worsening dyspnea 3 days before admitted to hospital. She also experienced right hemiparesis, nausea and vomiting 2 days ago. The woman developed progressing shortness of breath, orthopnea, and ascites started 4 months ago after she delivered her firstborn spontaneously helped by midwife. She had a history of hypertension in 8-months of pregnancy without symptoms and didn't get a proper medication. On examination, she was global aphasia, dyspneic, oedemic, her pulse was 140 bpm, respiratory rate 28 per minute, free air SpO₂ was 94%. Bilateral rales and slight hepatomegaly were also present. Electrocardiogram was sinus tachycardia. Cardiomegaly and pulmonary edema found in her chest x-ray. Her transthoracic echocardiography (TTE) showed dilated all chambers of heart, global severe hypokinetic of left ventricle with ejection fraction (EF) 18%, mild mitral regurgitation, and moderate tricuspid regurgitation. Computed Tomography (CT) scan showed wedge-shaped large infarction of frontotemporoparietal region as shown in figure 1. We started loading furosemide 80 mg intravenous, followed 5 mg per hour with syringe pump, ramipril 5 mg, spironolactone 25 mg, citicoline 500mg, and mannitol. On 5th day, we started enoxaparin sodium 60 mg subcutaneously once a day for 4 day. She was discharged on the 14th day.

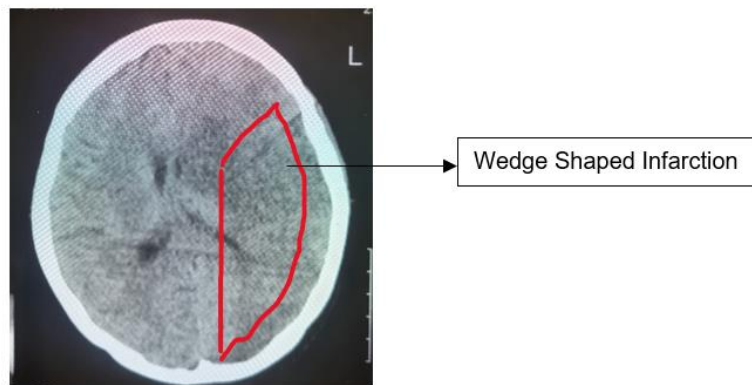

Figure 1. Wedge-shaped large infarction in CT scan, one of cardioembolic stroke characteristic in neuroimaging study found in patient.

Conclusions: Peripartum cardiomyopathy is a life-threatening disease characterized by heart failure occurring in the last month of pregnancy or in the first 5 months after delivery in patients without a history of cardiovascular disease with echocardiographic features of left ventricular dysfunction and an ejection fraction of <45%. Left ventricular akinesis found in her TTE is a high risk factor for intracardiac thrombus formation and may lead to cardioembolic stroke. Paroxysmal AF which maybe we didn't capture are highly suggested present and can be included as another risk factors. Hypercoagulable state of the peripartum period itself, endothelial injury, and immobility may contribute to the increased propensity of embolism, but cardioembolic stroke in PPCM is reported very rarely. There are no recommendations available for the management of stroke in such patients. The guidelines from the ESC 2018 recommend anticoagulation in women with PPCM with LVEF < 25%, as we



Indonesian Journal of Cardiology

Indonesian J Cardiol 2021;42:suppl_C
pISSN: 0126-3773 / eISSN: 2620-4762
doi: 10.30701/ijc.1241

gave for patient in this case, but there is also controversy regarding the use of anticoagulation in PPCM patients with stroke because of the risk of intracranial hemorrhage (ICH).

In conclusion, we present a rare case of PPCM with cardioembolic stroke, which patient was hemodynamically improved but not neurologically.

Modified Valsava Manuever in Management Supraventricular Tachycardia After Failed Conversion Using Standard Valsava Manuever in Emergency Unit Rural Hospital

U. Panjaitan¹, Kartika Apshanti²

¹General Practitioner in RSUD Kalabahi, Alor, NTT

²Cardiologist in RSUD Kalabahi, Alor, NTT

Background: Supraventricular tachycardia (SVT) is a common tachyarrhythmia in emergency unit. Non-pharmacological therapies such as carotid massages, Valsava manuever, and facial immersion are used in stable SVT. If there is no response to non-pharmacological therapy, we can initiate pharmacological therapy. However, in rural hospital the availability of drugs is very difficult.

Case Illustration: A male, 68-year-old, complained palpitations 6 hours before admission, accompanied with shortness of breath. He had history of hypertension and CAD and was on routine therapy. At presentation, his pulse rate was 150x/min, regular, blood pressure 110/60 mmHg, respiratory rate 20 tpm and saturation 98%. On physical examination, normal JVP, no carotid bruit, vesicular breathing sound without ronchi, no additional heart sound. ECG (figure 1) showed supraventricular tachycardia (AV re-entry tachycardia) with heart rate 150 bpm. Carotid massage and standard manuver valsava were given, but did not show conversion. Due to unavailable drugs in our hospital, and patient was still in stable condition, we tried to do modified valsava manuever and found rhythm conversion accompanied normal rate. The patient was observed for recurrence of SVT and received ACE-Inhibitor, diuretics, and B-blockers.

Conclusions: Management for dysrhythmia is based on stable or unstable. Stable if there is no sign of acute heart failure, hypotension, altered mental status, ischemic chest discomfort, and sign of shock. Among the various non-pharmacological therapies for tachyarrhythmia, standard valsava manuever is the highest conversion rate ranges from 5-20%. However, modified valsava manuever, modification to standard valsava manuever such as an elevation of lower leg followed by supination and straining, can increase conversion rate more than 40% according to Appelboam's study. This recommendation is consistent with our case report. In addition, as long as the patient in stable condition, non-pharmacological therapy can be continued especially in rural hospital with unavailable drugs.

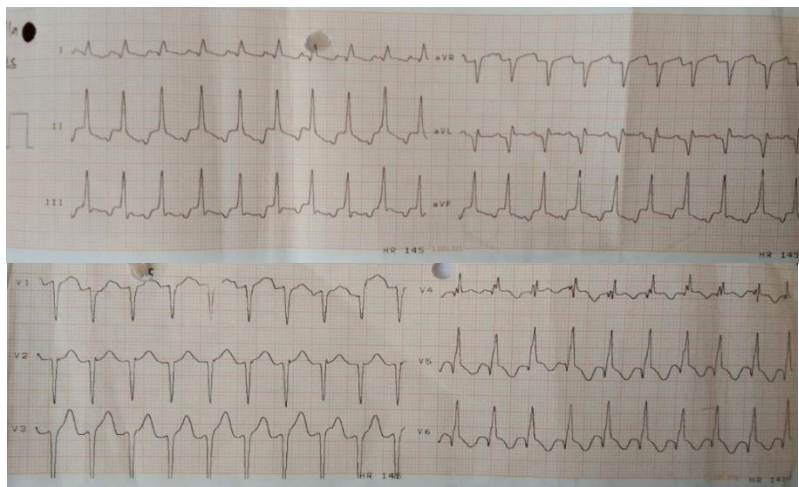


Figure 1. Electrocardiograph when admission in emergency unit

Recurrent Non-sustained Ventricular Tachycardia in A COVID-19 Patient with Chronic Kidney Disease on Hemodialysis: A Case Report

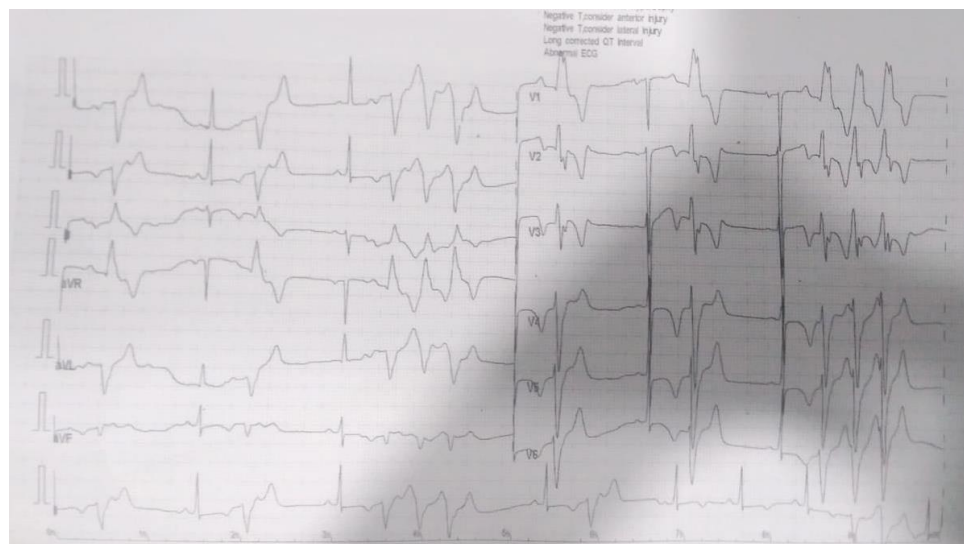
V.A.N. Fatimah¹, N.S. Istiqomah¹

¹Pertamina Jaya Hospital, Jakarta, Indonesia

Background: Cardiac arrhythmias, including ventricular tachycardia, are commonly found in COVID-19 cases. Meanwhile, dialysis patients are susceptible to the occurrence of ventricular arrhythmia. Amiodarone is a well-known drug to treat arrhythmia but also possesses arrhythmogenic properties and can lead to the development of polymorphic ventricular tachycardia.

Case Illustration: A 59-year-old male patient experienced recurrent episodes of non-sustained ventricular tachycardia (NSVT) during COVID-19 inpatient care. He had a history of chronic kidney disease (CKD) on routine hemodialysis since around 5 years ago but no history of previous arrhythmia. On admission his ECG showed no arrhythmia, but blood pressure (BP) was high. On the fifth day of hospitalization, he felt non-cardiac chest pain with hemoptoe and had hypertensive urgency. ECG showed supraventricular tachycardia (SVT). No significant abnormality was found in echocardiography. Then he was treated with bisoprolol, but after 3 days he experienced the worsening of dyspnea while the hemoptoe remained. Pulse deficit was found in the physical examination. Initially the ECG showed frequent ventricular extrasystole (VES) but then progressed into NSVT. Treatment with amiodarone drip 300mg/24hours had resolved the tachyarrhythmia but led to sinus bradycardia. The amiodarone dosage was then reduced to half. He was scheduled to have hemodialysis every 24-48 hours because his consciousness tended to be impaired from uremic encephalopathy. However, every time he underwent hemodialysis, the NSVT recurred. The amiodarone drip was then maintained at 300 mg/24 hours and escalated to 450 mg/24 hours during hemodialysis. No cardioversion was ever attempted. As the result, the NSVT appeared less often.

Conclusions: The possible causes for the new-onset of NSVT in this case are COVID-19-related cardiac abnormality or COVID-19-induced exacerbation of renal dysfunction which leads to cardiac disorders from metabolic disturbances. Amiodarone could effectively control ventricular arrhythmia in a COVID-19 with CKD. However, strict ECG monitoring is mandatory to prevent the transformation into polymorphic ventricular tachycardia as one of the possible side effects and to adjust the dosage of amiodarone.



ECG showed non-sustained ventricular tachycardia
Exercise Induced Ventricular Arrhythmia in Patient with Coronary Artery Disease: Acute Coronary Syndrome or Scar VT?

W. Prabowo¹, N. Taufiq², I.A. Arso²

¹Resident of Cardiology and Vascular Medicine, Faculty of Medicine, Public Health and Nursing, Gadjah Mada University, Yogyakarta, Indonesia

²Staff of Cardiology and Vascular Medicine, Faculty of Medicine, Public Health and Nursing, Gadjah Mada University, Yogyakarta, Indonesia

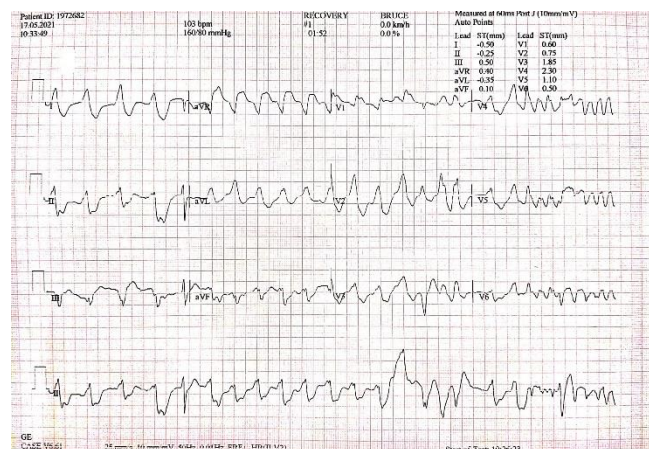
Background: Exercise induced ventricular arrhythmias (EIVA) are common findings during clinical treadmill testing. In patients following myocardial infarction, EIVA are a predictor of poorer prognosis. Moreover, in the post-myocardial infarction patient, the occurrence of EIVA may itself represent a clue to the presence of residual viability within the infarct.

Case Illustration: A 64-year old man was admitted to Emergency Room (ER) due to episode of cardiac arrest during treadmill stress test. Monomorphic ventricular tachycardia (VT) rhythm progresses to ventricular fibrillation (VF) at recovery phase 01.52 minute. Cardiopulmonary resuscitation with defibrillation was performed and patient successfully managed to return of spontaneous circulation. This patient had medical history of Anterior STEMI one month ago who did not undergo revascularization. ECG evaluation in the ER showed sinus rhythm with rate 86 bpm, left heart axis deviation, pathological Q in III, AVF, and V1-V3. No new ST-segment elevation or ST-T-segment dynamic changes were found on the ECG evaluation. We performed hs-Troponin I examination showed result 37.2 ng/L and evaluation was done in 2 hours showed result 44.2 ng/L. The patient did not complaint angina neither dyspnea at ER evaluation with stable hemodynamic. The patient underwent coronary angiography with result coronary artery three vessel disease and was planned for a surgical conference regarding the preferred revascularization method.

Conclusions: Sustained VT that is not associated with an ACS is often monomorphic as it is usually due to scar-related re-entry, but it may degenerate to VF. Based on clinical examination, ECG, and cardiac enzyme which did not show a significant increase, this patient did not have an acute myocardial infarction. The mechanism of ventricular arrhythmias in this patient may be due to a re-entry in the former infarct area with contributing aggravating factors such as an increase in the sympathetic nervous system triggered by exercise testing, increased automaticity in the peripheral of the ischemic zone, and transient ischemia in the area around the infarct. EIVA could serve as markers of arrhythmogenic substrates even in the absence of myocardial injury or infarction. Re-entry may occur around a fixed anatomical obstacle, such as scar after an MI.

Keyword: Exercise testing, Arrhythmia, Coronary artery disease, Scar VT

Figure 1. ECG during treadmill stress test recovery phase





**Management Atrial Fibrillation Accompanied with Left Bundle Branch
Block In Chronic Heart Failure Due to Thyroid Heart Disease
In Rural Hospital: A Case Report**

Y. Pratama¹, E. Supriadi²

¹General Practitioner, KH Daud Arif General Hospital, Kuala Tungkal, Indonesia

²Cardiologist, Department of Cardiology and Vascular Medicine Raden Mattaher General Hospital,
Jambi, Indonesia

Background: The relationship between thyroid hormone and the cardiovascular system has been extensively demonstrated in numerous experimental and clinical studies. Untreated hyperthyroidism is associated heart failure and atrial fibrillation. Thyroid heart disease with complication requires modalities to established diagnosis and appropriate therapy.

Case Illustration: A 41-years-old man was presented to the ER with worsening dyspnea for 6 hours after mild activities. He also complained about palpitation, feeling excessive of body-heat. The patient had history of uncontrolled hyperthyroidism for 10 years with non-regular medication thiamazol and propranolol. BP: 170/100 mmHg, pulse: 140 bpm regular, RR: 32 breathes/min, SpO2 91%. Physical examination showed palpable symmetrically enlarged thyroid gland, auscultation showed irregular heartbeats, minimal ronchi in lower part of both lungs. ECG showed atrial fibrillation rapid ventricular response with left bundle branch block (LBBB). Chest x-ray showed biventricular enlargement. Thyroid-function-tests (TFTs) showed increased level T3 (3,31 nmol/L), T4 (167,31 nmol/L) and low TSH (0,05 mIU/L). CHA₂DS₂-VASc score was 2. The patient was treated with intravenous furosemide 40 mg, bisoprolol 1,25 mg, aspirin 80 mg, clopidogrel 75 mg, candesartan 8 mg, thiamazole 5 mg. Our hospital had limited-resources for diagnostic equipment and drugs such as anticoagulants for preventing embolism and stroke-events. After 6 hours observation, patient's hemodynamic status was stabilized, patient was referred to province general hospital.

Conclusions: Hyperthyroidism caused increase in heart rate, cardiac preload, and reduction of peripheral vascular resistance, resulting in a hyperdynamic circulation. If left untreated, it can lead to heart failure. Hyperthyroidism also associated with increased left atrial pressure and decreased duration of action potential resulting in atrial ectopic activities. LBBB is associated with atrial fibrillation and systolic heart failure, the QRS prolongation is indicating intraventricular conduction abnormality. In limited-facility hospital, our focus treatments are stabilizing heart failure symptoms and arrhythmia along with correcting hyperthyroidism, also strategies for preventing embolism, and stroke-events. Management of thyroid heart disease with complication heart failure and atrial fibrillation in rural hospital are not always competent to manage according to guidelines because of limited resources, but prompt diagnosis and treatment is critical point for patient's survival.

Keywords: Thyroid heart disease, atrial fibrillation, heart failure.