

Philadelphia College of Osteopathic Medicine

DigitalCommons@PCOM

Orthopedic Surgery Resident Research

Graduate Medical Education Research

9-2022

Arthroscopic Suprapectoral Biceps Tenodesis: The Best of Both Worlds

Tyler Pratte

Philadelphia College of Osteopathic Medicine

Tyler Smith

Alfonso Arevalo

Philadelphia College of Osteopathic Medicine

Joseph Wazen

Philadelphia College of Osteopathic Medicine

David Rubenstein

Follow this and additional works at: https://digitalcommons.pcom.edu/orthopedic_surgery_residents



Part of the [Orthopedics Commons](#)

Recommended Citation

Pratte, Tyler; Smith, Tyler; Arevalo, Alfonso; Wazen, Joseph; and Rubenstein, David, "Arthroscopic Suprapectoral Biceps Tenodesis: The Best of Both Worlds" (2022). *Orthopedic Surgery Resident Research*. 67.

https://digitalcommons.pcom.edu/orthopedic_surgery_residents/67

This Article is brought to you for free and open access by the Graduate Medical Education Research at DigitalCommons@PCOM. It has been accepted for inclusion in Orthopedic Surgery Resident Research by an authorized administrator of DigitalCommons@PCOM. For more information, please contact jaclynwe@pcom.edu.

Arthroscopic Supraperectoral Biceps Tenodesis: The Best of Both Worlds



Tyler Pratte, D.O., Tyler Smith, D.O., Alfonso Arevalo, D.O., Joseph Wazen, D.O., and David Rubenstein, M.D.

Abstract: Biceps tendinopathy and superior labrum anterior posterior lesions are a common source of shoulder pain and disability and can be effectively treated with biceps tenodesis. There are a variety of open and arthroscopic tenodesis techniques, but no one technique has demonstrated superiority. Arthroscopic techniques often disregard the extra-articular portions of the biceps tendon as a potential source of pain. Open techniques address this concern; however, they can be associated with wound complications, increased blood loss, nerve injury, and disruptions to surgical workflow. Here, we describe an all arthroscopic tenodesis technique at the supraperectoral zone of the tendon. This method addresses extra-articular sources of pain, while limiting the potential pitfalls of open surgery.

Introduction

Long head of the biceps tendinopathy (LHBT) is a well-known cause of anterior shoulder pain. Although simple tenotomy is effective in reducing pain, it can lead to cosmetic deformity, muscle cramping, and decreased supination strength.¹⁻⁴ Tenodesis has been shown to decrease anterior shoulder pain in patients with bicipital tendinopathy, while avoiding several complications associated with tenotomy.³⁻⁵ Taylor et al. described the anatomy of the bicipital tunnel as having three distinct zones.⁶ Zone 1 extends from the articular margin to the distal subscapularis tendon. Zone 2 extends from the distal subscapularis tendon to the proximal border of the pectoralis major tendon. Zone 3 is the sub-pectoral region. Zones 1 and 2 are enclosed by a dense connective tissue sheath and synovium, while Zone 3 is not. Arthroscopic tenodesis techniques are most commonly performed in Zone 1, and may disregard the

distal segments of the pathologic tendon.⁷⁻⁹ This may lead to the higher reported revision rate with proximal tenodesis.¹⁰ Open tenodesis techniques address this concern; however, they may result in additional blood loss, wound complications, nerve injuries, undesirable cosmetic appearance, and disruptions to surgical workflow.^{7,11} This Technical Note describes an all-arthroscopic distal tenodesis technique at the supraperectoral zone of the tendon. This method addresses extra-articular sources of pain, while limiting the potential pitfalls of open surgery.

Surgical Technique

The patient is in a beach-chair position with the operative extremity prepped and draped in a sterile fashion. A standard posterior portal is used as the initial primary viewing portal (Fig 1). A standard 30° arthroscope (Arthrex, Naples, FL) is inserted, and a diagnostic arthroscopy is performed. An anterior portal is established by outside-in technique, and a 5.5-mm cannula (Arthrex) is inserted and directed superior to the biceps tendon. Once the diagnostic arthroscopy confirms the surgical indication for biceps tenodesis, a BirdBeak device (Arthrex) is loaded with #2 FiberWire suture (Arthrex) and is inserted through the anterior cannula. The BirdBeak pierces the biceps tendon as laterally as possible. The BirdBeak is then withdrawn from the tendon anteriorly, but it remains within the anterior cannula before passing superiorly over the tendon to retrieve the suture. A percutaneous spinal needle can temporarily hold the loop of the stitch to facilitate the passage (Table 1). The suture is then retrieved from the anterior cannula, and the single end is passed through

From the PCOM Orthopedic Residency Program, Philadelphia, Pennsylvania (T.P., A.A., J.W.); University of Massachusetts Medical Center Orthopedic Sports Medicine Fellowship, Worcester, Massachusetts (T.S.); and Rothman Orthopedics, Wynnwood, Pennsylvania, 19096 (D.R.).

Received March 8, 2022; accepted May 18, 2022.

Address correspondence to Tyler Pratte, D.O., PCOM Orthopedic Residency Program, 4190 City Ave., Suite 409, Philadelphia, PA, 19131, U.S.A. E-mail: tp181968@pcom.edu

© 2022 THE AUTHORS. Published by Elsevier Inc. on behalf of the Arthroscopy Association of North America. This is an open access article under the CC BY-NC-ND license (<http://creativecommons.org/licenses/by-nc-nd/4.0/>).

2212-6287/22324

<https://doi.org/10.1016/j.eats.2022.05.008>

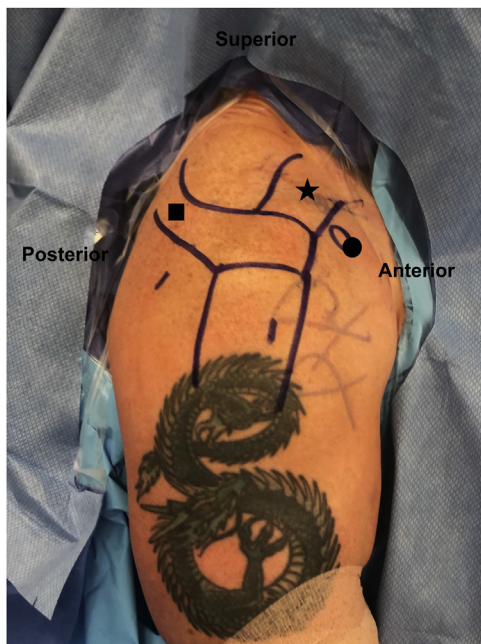

Fig 1. Landmarks and portal placement. The right shoulder is draped, while the patient is in the standard beach chair position. A standard accessory lateral portal is established 2 to 3 fingerbreadths from the lateral border of the acromion, at ~25% of the anterior to posterior distance in line with the acromio-clavicular joint. A standard posterior portal is used as the initial primary viewing portal. The ■ overlies the area marked out to represent the scapular spine. The ★ overlies the area marked out to represent the clavicle. The ● overlies the area marked out to represent the coracoid.

the looped end to complete a luggage tag of the biceps tendon. An arthroscopic biter is introduced from the anterior portal, and a tenotomy is performed as medially as possible. A shaver is used to debride any remaining tendon stump from the anchor at the superior labrum. The tagged biceps tendon is clamped from the anterior portal to maintain tension.

Table 1. Pearls and Pitfalls

Pearls

- An accessory spinal needle may be used to help remove the FiberWire tag stitch from the BirdBeak device.
- Identification of the biceps tendon in Zone 2 of the groove may be facilitated by visualization of a white fascial band of the pectoralis tendon as it crosses the bicipital groove.
- A probe is used to retract the tendon medially during drilling to prevent damaging tendon.
- A grasper may be used to prevent the tendon from rotating in the tunnel during insertion of the interference screw.

Pitfalls

- Failure to perform a thorough subdeltoid bursectomy can lead to difficulty identifying the biceps tendon and lead to increased operative time. Bicortical drilling should be avoided as it may lead to a stress riser.

From the previously established posterior portal, the scope is introduced into the subacromial space. A standard accessory lateral portal is established 2 to 3 fingerbreadths from the lateral border of the acromion, at approximately 25% of the anterior to posterior distance in line with the acromio-clavicular joint (Fig 1). An additional 5.5-mm cannula is introduced through the lateral portal. A standard subacromial bursectomy is performed with a shaver and radiofrequency probe. The camera is switched to the lateral portal and an extensive anterior subdeltoid bursectomy is performed with the arm in abduction and forward flexion. It is critical that a thorough anterior bursectomy is performed for proper visualization of the biceps within the groove.

After the subacromial and subdeltoid bursectomies are complete, the camera is positioned in the lateral portal looking distally and anteriorly with the shoulder positioned in ~75° of forward flexion and neutral rotation. An accessory low anterior portal is created via the outside-in technique using an 18-gauge spinal needle ~1.5 cm proximal to the pectoralis major tendon insertion. A radio frequency probe is introduced and used to dissect along the delto-pectoral interval to visualize the pectoralis major tendon insertion lateral to the bicipital groove. Identification of the proper interval can be facilitated by visualization of a white fascial band along the anterior humerus (Fig 2). The biceps tendon can be identified by rolling over the tendon with a probe, while the first assistant tensions the stump using the tagged suture from the anterior portal. An 11-blade

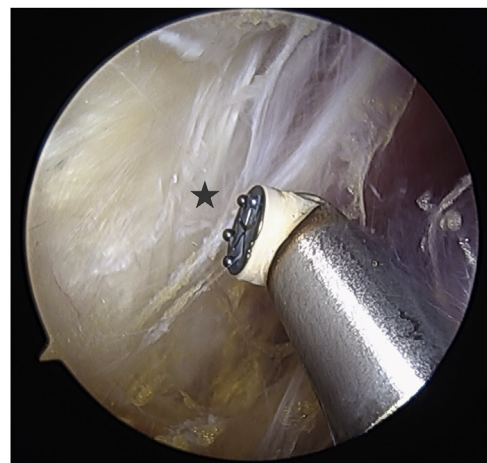


Fig 2. Interval identification. Viewing from the lateral portal in a right shoulder in standard beach chair position, a radio frequency probe via the standard anterior portal is used to dissect along the delto-pectoral interval to visualize the pectoralis major tendon insertion lateral to the bicipital groove. Identification of the proper interval can be facilitated by visualization of a white fascial band ★ along the anterior humerus.

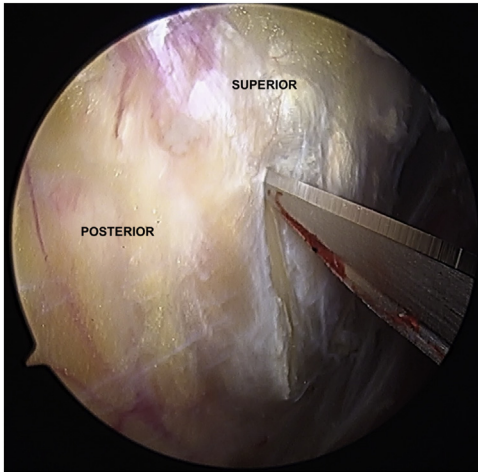


Fig 3. Biceps tendon sheath release. Viewing from the lateral portal of the right shoulder of the patient while in standard beach chair position, an 11-blade is inserted through the low anterior portal and is used to release the THL. THL, transverse humeral ligament.

is introduced through the accessory low anterior portal and used to release the biceps tendon sheath (Fig 3). A probe is introduced by the first assistant through the traditional anterior portal and used to retract the biceps tendon anteriorly. An 8-mm cannula is placed into the low anterior portal, and a radio frequency probe is introduced to debride the tissue overlying the bicipital groove until the bleeding bone is present. An 8-mm noncannulated reamer is then introduced into the low

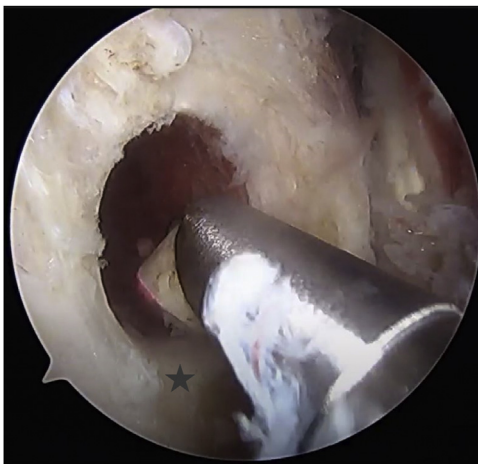

Fig 4. Tunnel preparation. Viewing from the lateral portal in the right shoulder of the patient while in the standard beach chair position, an 8-mm noncannulated reamer is introduced via the low anterior portal, and a unicortical hole is reamed within the groove. Once drilled, the tunnel is debrided with use of the shaver and/or radio frequency probe to ensure a smooth inferior border to prevent fraying of the tenodesis site. The ★ overlies the smooth inferior border of the tenodesis site.

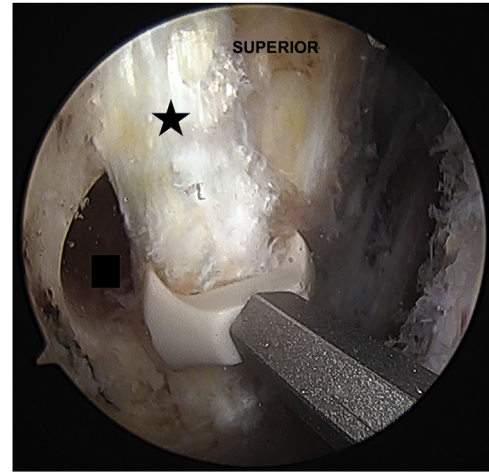


Fig 5. Interference screw insertion. Viewing from the lateral portal in the right shoulder of the patient while in the standard beach chair position, a fork-tipped 8 × 23 mm interference screw is inserted through the low anterior portal and is used to introduce the tendon into the tenodesis site. The ★ overlies the area of the tendon distal to the tenodesis site. The ■ overlies the drill hole for the tenodesis site.

anterior portal, and a unicortical hole is reamed within the bicipital groove. During removal, it is important to keep the reamer centralized to prevent oblique enlargement of the tunnel. Once drilled, the tunnel is debrided with use of the shaver and/or radio frequency probe until the inferior border of the tunnel is smooth in order to prevent fraying of the tendon (Fig 4). The biceps is tensioned by the first assistant with a mild superior force to represent physiological tension. A

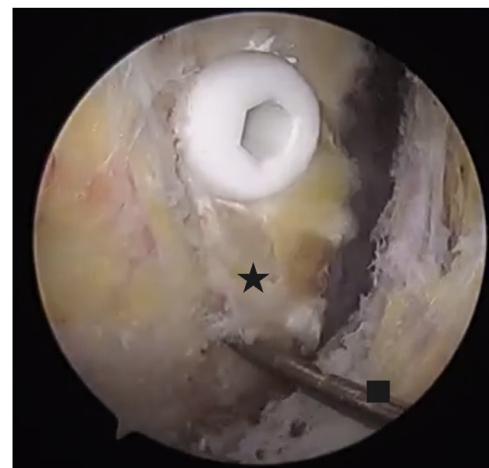

Fig 6. Tenodesis. Viewing from the lateral portal in the right shoulder of the patient while in the standard beach chair position, the interference screw is tightened such that it is left 1 mm proud. The residual proximal tendon is then amputated after the tenodesis and is removed through the proximal lateral portal. The ★ overlies the biceps tendon distal to the tenodesis site. The ■ overlies the arthroscopic probe.

Table 2. Advantages and Disadvantages

Advantages
Addresses pathology in Zones 1 and 2 of the bicipital groove.
Improved cosmesis
Unicortical fixation
Reduced blood loss and risk of neurovascular injury
All-arthroscopic procedure resulting in less disruption of workflow
Disadvantages
Requires extensive subacromial and subdeltoid bursectomies.
May lead to increased fluid extravasation and swelling
Requires a learning curve regarding dissection and recognition of the anatomy
Large 8-mm tunnel
Does not allow for visualization of the bicep musculotendinous junction to assist in determining muscle length and tension

fork-tipped 8 × 23 mm interference screw is used to straddle the tendon and introduce it into the tenodesis site (Fig 5). During insertion of the screw, the proximal tendon is held with a grasper to prevent the tendon from twisting. Our preference is to leave the screw 1 mm proud (Fig 6). The residual tendon proximally can be tenotomized with use of a biter or burner.

Postoperatively, the patient is placed in a sling for comfort only. Passive range of motion exercises are permitted immediately, and active range of motion is encouraged after 1 week. Formal physical therapy begins around 6 weeks after surgery, with light resistance exercises permitted. Weight training may start at 8 weeks postoperatively, and return to sports is permitted at 12 weeks.

Discussion

Several authors have reported that LHBT pathology within the bicipital groove is common.^{2,4,5,10,12,13} This region is both a vascular watershed area and prone to frictional attrition.^{13,14} Although the ideal location and technique of tenodesis remains controversial, proximal tenodesis may be a cause of increased rate of revision surgery.¹⁰ Alpantaki et al. identified a large neuronal network in the distal tendon zones and transverse humeral ligament, which may act as a pain generator following proximal tenodesis.¹⁵ In addition, Moon et al. reported that 80% of interstitial tendon tears propagated into the extra-articular zones and described these “hidden lesions” commonly extending to the distal aspects of Zone 2.⁸ For these reasons, we believe the ideal tenodesis location is at the distal extent of the bicipital groove.

We also believe the ideal technique for proximal biceps tenodesis should be arthroscopic. Arthroscopic management reduces the risks of open treatment, including infection, blood loss, and nerve damage. Arthroscopic tenodesis can be performed in combination with other arthroscopic procedures, such as rotator cuff or labral repair. Additionally, the use of open

tenodesis in an otherwise all-arthroscopic procedure would require additional surgical trays, disruptions to surgical workflow, and increases in surgical time for closure of the incision.^{7,11} However, several authors have presented concerns regarding the ability to adequately visualize the distal tendon segments arthroscopically.¹⁶⁻¹⁸ Murthi et al. reported a 50% rate of missed pathology during arthroscopy due to the inability to visualize distal tendon segments.¹⁹ Festa et al. demonstrated that only 30.8% of the extra-articular tendon could be visualized with the commonly performed arthroscopic pull-down maneuver from the anterior portal.¹⁶ Similarly, Taylor et al. reported that only 55% of Zones 1 and 2 could be visualized arthroscopically.¹⁸ The authors termed Zone 2 as “no man’s land” due to the inability to visualize this zone from either arthroscopic or open subpectoral methods.^{7,18} However, it should be noted that the above authors did not use a subdeltoid bursectomy and extensive arthroscopic debridement. Other authors have described improved arthroscopic visualization with the use of a 70° arthroscope and an accessory Navaiser portal.^{20,21} Although these techniques may prove useful for some authors, we prefer to avoid additional instrument trays and the potential for suprascapular nerve injury.

We describe a technique to perform an all arthroscopic suprapectoral LHBT tenodesis at the distal bicipital groove. For the described technique, the surgeon uses a standard 30° arthroscope from the lateral portal and performs a thorough bursectomy, which allows for extensile exposure of Zones 1 and 2 of the LHBT. At this location the LHBT lies within the distal groove, and the degree of residual distal pathology is minimal.^{8,22} Screws placed distal within the groove may additionally avoid previously described pain secondary to biologic screw reaction.⁹ This technique presents a reliable and reproducible surgical treatment for patients with symptomatic biceps tenodesis and can be used for both proximal and distal biceps pathology. Other advantages of this technique include the ease of use during concomitant arthroscopic procedures. No additional instrumentation or trays are needed, and there is no disruption to surgical workflow. Limitations of this technique include possible increased swelling and fluid extravasation in the arm, the presence of a surgeon learning curve, and the possibility that the pathology of the subpectoral zone of the tendon is not addressed (Table 2).

Conclusion

This Technical Note describes an all-arthroscopic distal tenodesis technique at the suprapectoral zone of the tendon. Utilization of this method addresses extra-articular sources of pain, while limiting the potential pitfalls of open surgery.

References

1. Lim TK, Moon ES, Koh KH, Yoo JC. Patient-related factors and complications after arthroscopic tenotomy of the long head of the biceps tendon. *Am J Sports Med* 2011;39:783-789.
2. Belk JW, Kraeutler MJ, Houck DA, Chrisman AN, Scillia AJ, McCarty EC. Biceps tenodesis versus tenotomy: A systematic review and meta-analysis of level I randomized controlled trials. *J Shoulder Elbow Surg* 2021;30:951-960.
3. Ahmed AF, Toubasi A, Mahmoud S, et al. Long head of biceps tenotomy versus tenodesis: A systematic review and meta-analysis of randomized controlled trials. *Shoulder Elbow* 2021;13:583-591.
4. Pozzetti Daou J, Nagaya DY, Matsunaga FT, Sugawara Tamaoki MJ. Does biceps tenotomy or tenodesis have better results after surgery? A systematic review and meta-analysis. *Clin Orthop Relat Res* 2021;479:1561-1573.
5. Nho SJ, Strauss EJ, Lenart BA, et al. Long head of the biceps tendinopathy: Diagnosis and management. *J Am Acad Orthop Surg* 2010;18:645-656.
6. Taylor SA, Fabricant PD, Bansal M, et al. The anatomy and histology of the bicipital tunnel of the shoulder. *J Shoulder Elbow Surg* 2015;24:511-519.
7. Mazzocca AD, Cote MP, Arciero CL, Romeo AA, Arciero RA. Clinical outcomes after subpectoral biceps tenodesis with an interference screw. *Am J Sports Med* 2008;36:1922-1929.
8. Moon SC, Cho NS, Rhee YG. Analysis of "hidden lesions" of the extra-articular biceps after subpectoral biceps tenodesis: The subpectoral portion as the optimal tenodesis site. *Am J Sports Med* 2015;43:63-68.
9. Provencher MT, LeClere LE, Romeo AA. Subpectoral biceps tenodesis. *Sports Med Arthrosc Rev* 2008;16:170-176.
10. Sanders B, Lavery KP, Pennington S, Warner JJP. Clinical success of biceps tenodesis with and without release of the transverse humeral ligament. *J Shoulder Elbow Surg* 2012;21:66-71.
11. Nho SJ, Reiff SN, Verma NN, Slabaugh MA, Mazzocca AD, Romeo AA. Complications associated with subpectoral biceps tenodesis: Low rates of incidence following surgery. *J Shoulder Elbow Surg* 2010;19:764-768.
12. Becker DA, Cofield RH. Tenodesis of the long head of the biceps brachii for chronic bicipital tendinitis. Long-term results. *J Bone Joint Surg Am* 1989;71:376-381.
13. Refior HJ, Sowa D. Long tendon of the biceps brachii: sites of predilection for degenerative lesions. *J Shoulder Elbow Surg* 1995;4:436-440.
14. Cheng NM, Pan W-R, Vally F, Le Roux CM, Richardson MD. The arterial supply of the long head of biceps tendon: Anatomical study with implications for tendon rupture. *Clin Anat* 2010;23:683-692.
15. Alpantaki K. Sympathetic and sensory neural elements in the tendon of the long head of the biceps. *J Bone Joint Surg Am* 2005;87:1580.
16. Festa A, Allert J, Issa K, Tasto JP, Myer JJ. Visualization of the extra-articular portion of the long head of the biceps tendon during intra-articular shoulder arthroscopy. *Arthroscopy* 2014;30:1413-1417.
17. Saithna A, Longo A, Leiter J, Old J, MacDonald PM. Shoulder arthroscopy does not adequately visualize pathology of the long head of biceps tendon. *Orthop J Sports Med* 2016;4:232596711562394.
18. Taylor SA, Khair MM, Gulotta LV, et al. Diagnostic glenohumeral arthroscopy fails to fully evaluate the biceps-labral complex. *Arthroscopy* 2015;31:215-224.
19. Murthi AM, Vosburgh CL, Neviasser TJ. The incidence of pathologic changes of the long head of the biceps tendon. *J Shoulder Elbow Surg* 2000;9:382-385.
20. Bennett WF. Visualization of the anatomy of the rotator interval and bicipital sheath. *Arthroscopy* 2001;17:107-111.
21. Bhatia DN, van Rooyen KS, de Beer JF. Direct arthroscopy of the bicipital groove: A new approach to evaluation and treatment of bicipital groove and biceps tendon pathology. *Arthroscopy* 2008;24:368.e1-368.e6.
22. Johannsen AM, Macalena JA, Tompkins M. Anatomic and radiographic comparison of arthroscopic and open biceps tenodesis site. *Orthop J Sports Med* 2013;1:2325967113S0008.