

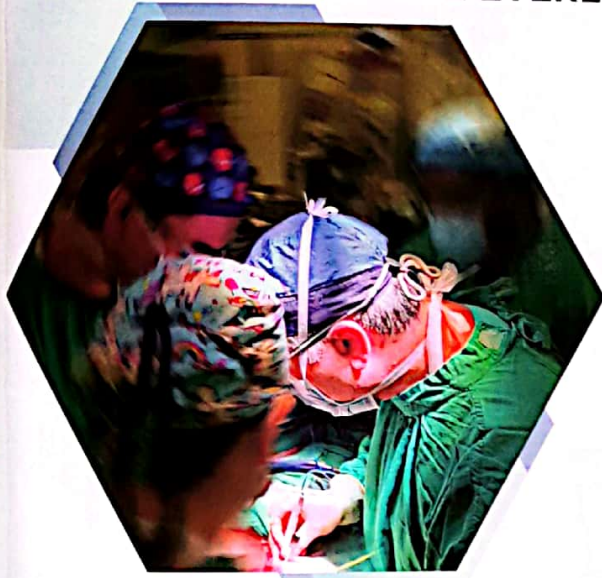

Malaysian Association of
PAEDIATRIC SURGERY

**1ST ANNUAL SCIENTIFIC MEETING &
12TH ANNUAL GENERAL MEETING**

4 JUNE 2022

THE EVERLY HOTEL, PUTRAJAYA



Q.U. is a 5-year-old boy, survivor of Esophageal Atresia with Tracheoesophageal Fistula Complicated with Severe Tracheo-malacia

Platinum Sponsor



Gold Sponsor



Silver Sponsor



Anastomosis Workshop Sponsor



AMYAND'S HERNIA COMPLICATED WITH PERFORATED APPENDICITIS IN NEONATES: A CASE REPORT

Nabila Yuliyanty Kamarul Zaman^{1,3}, Norhafiza Ab Rahman^{2,3}, , Abhirami Lechmiannandan³, Mohd Yusran Othman³,
Mohd Yusof Abdullah³

¹Department of Surgery, Hospital Tuanku Ja'afar, Seremban, Negeri Sembilan, Malaysia

²Department of Surgery, Kulliyah of Medicine, International Islamic University Malaysia, Kuantan, Pahang, Malaysia

³Department of Paediatric Surgery, Hospital Tunku Azizah, Kuala Lumpur, Malaysia

Introduction: Inguinal hernia (IH) is a common condition encountered in premature neonates. Amyand's hernia (AH) is an uncommon form of inguinal hernia in which the hernia sac contains appendix. Surgical repair of AH is similar to usual IH, however if it contains a perforated inflamed appendix, the diagnosis and repair can be challenging.

Case summary: A premature baby boy was referred to surgical team for a diagnosis of incarcerated right inguinal hernia. In view of no obstructive symptoms, he was sent to our out-patient clinic. Upon clinic review, irreducible right inguinal hernia was seen clinically with erythematous scrotum and tender. Urgent ultrasound confirmed the diagnosis of inguinal hernia containing mesentery and bowel. He was brought to theater urgently concerning bowel compromise. Intraoperatively, an Amyand's hernia was found. However, the appendix was enlarged with evidence of perforation at its tip with surrounding pus collection. Appendicectomy was performed via the same incision followed with herniotomy. He recovered well post-operatively and discharged after three days.

Conclusion: Incarcerated inguinal hernia in neonates without symptoms of intestinal obstruction should raise a suspicion of Amyand's hernia. And the presence of inflammation should prompt the possibility of appendicitis or even perforated appendicitis as reported in this case.

Keywords: Amyand's hernia, Perforated Appendicitis, Neonate

AMYAND'S HERNIA COMPLICATED WITH PERFORATED APPENDICITIS IN NEONATES: A CASE REPORT

Nabila Yuliyanty Kamarul Zaman^{1,3}, Norhafiza Ab Rahman^{2,3}, Abhirrami Lechmiannandan³, Mohd Yusran Othman³, Mohd Yusof Abdullah³

¹Department of Surgery, Hospital Tuanku Ja'afar, Seremban, Negeri Sembilan, Malaysia

²Department of Surgery, Kulliyah of Medicine, International Islamic University Malaysia, Kuantan, Pahang, Malaysia

³Department of Paediatric Surgery, Hospital Tunku Azizah, Kuala Lumpur, Malaysia

INTRODUCTION

Inguinal hernia (IH) is a common condition encountered in premature neonates. Amyand's hernia (AH) is an uncommon form of IH in which the hernia sac contains appendix. It was first described by Claudius Amyand in 1735, a British surgeon who performed an appendicectomy on an eleven-year old boy while operating on an IH^[1]. Surgical repair of AH is similar to the usual IH, however if it contains a perforated or inflamed appendix, the diagnosis and repair can be challenging.

CASE SUMMARY

A premature baby boy was referred for a diagnosis of incarcerated right IH. In view of no obstructive symptoms, he was seen as outpatient. Upon clinic review, irreducible right IH was seen clinically with erythematous scrotum and tender (figure 1). An urgent ultrasound confirmed the diagnosis of IH containing mesentery and bowel. He was brought to theater urgently due to the concern of inflammation. Intraoperatively, AH was found. However, the appendix was inflamed and enlarged with evidence of perforation at its tip with pus collection (figure 2-4). Appendicectomy was performed via the same incision followed by herniotomy. He recovered well post-operatively and discharged after three days.

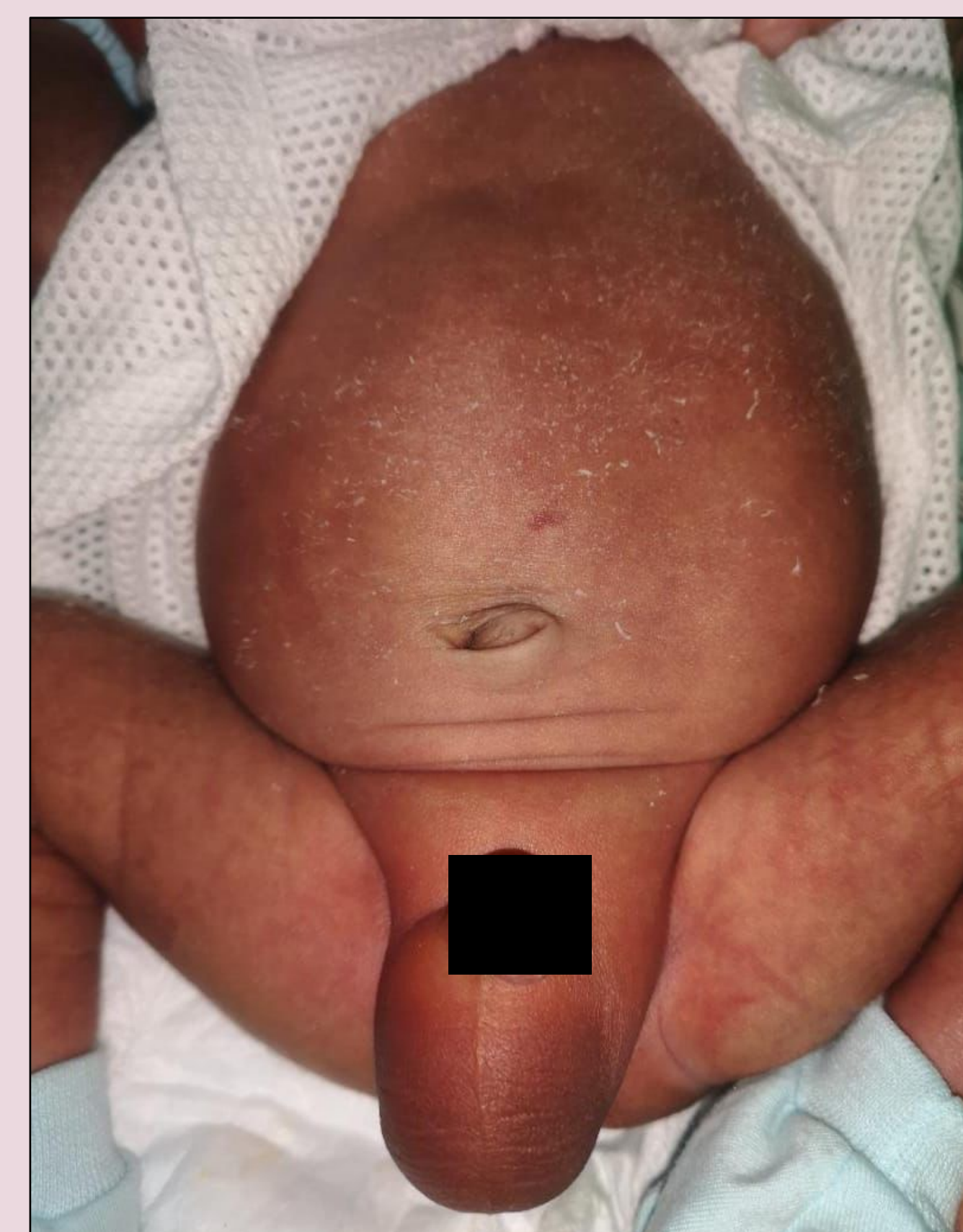


Figure 1: Right scrotal swelling with erythematous scrotal skin

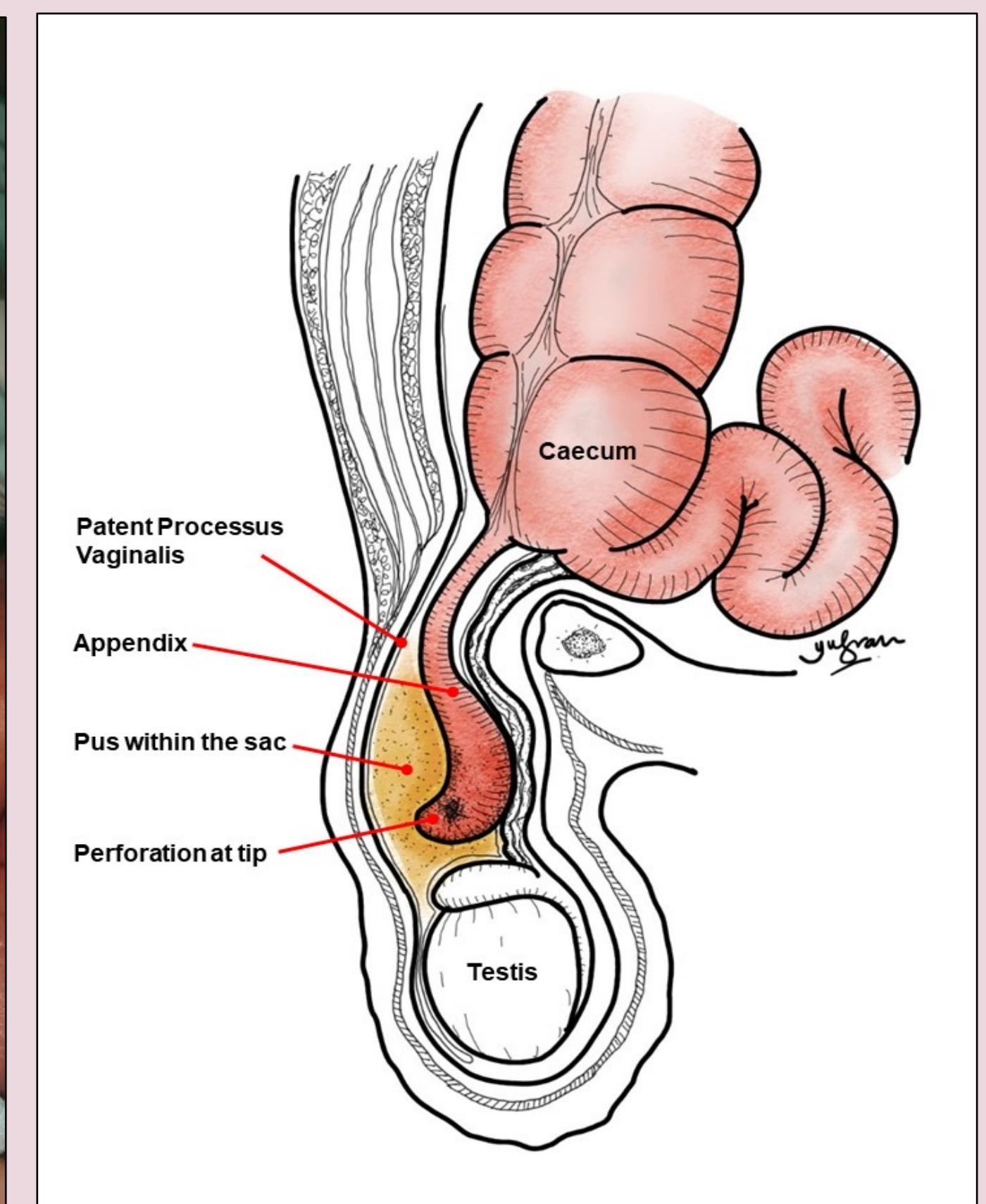


Figure 2: Illustrations of the perforated appendicitis within the hernial sac

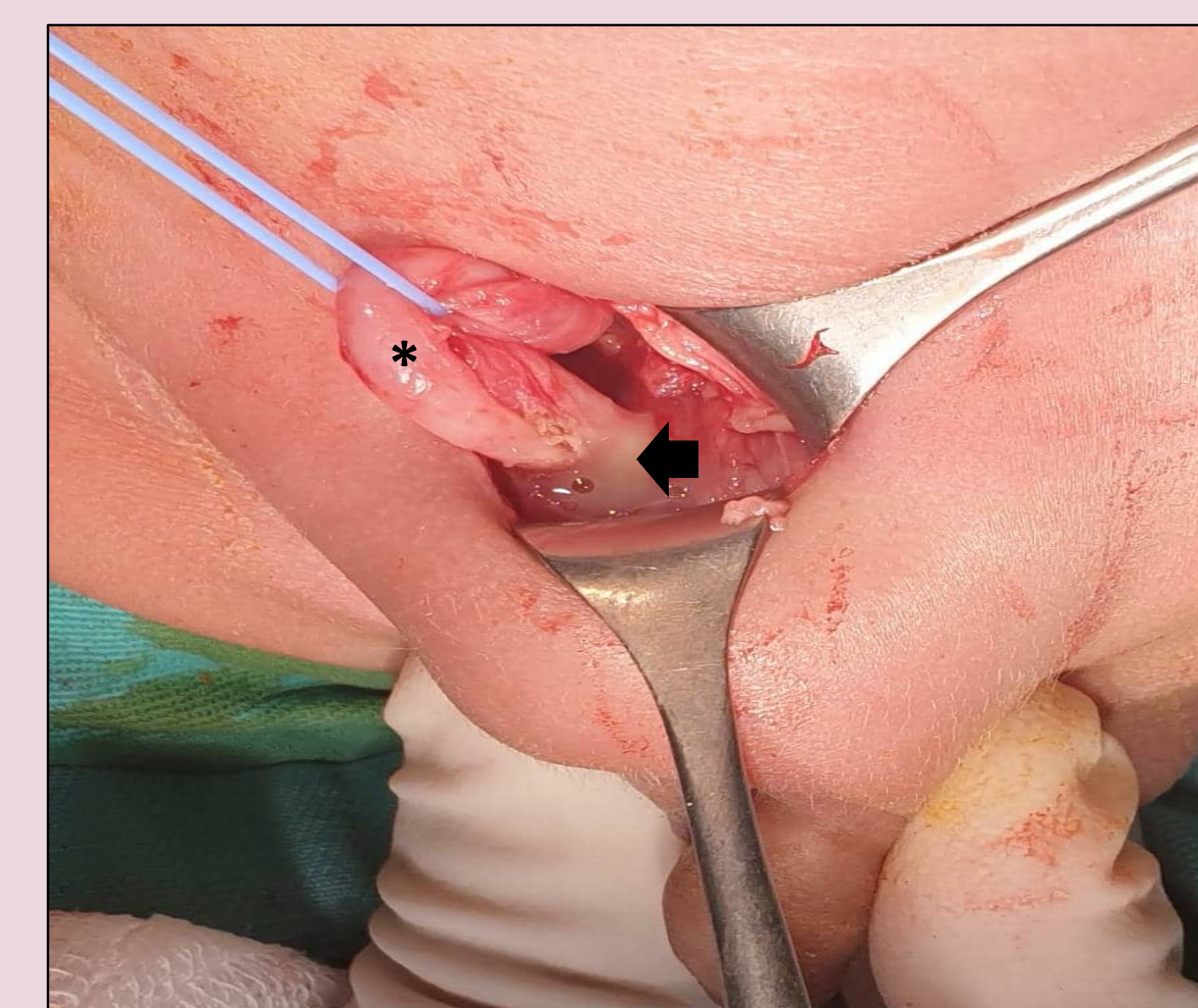


Figure 3: Inflamed and perforated appendix (asterisk) with pus collection (arrow) within the sac

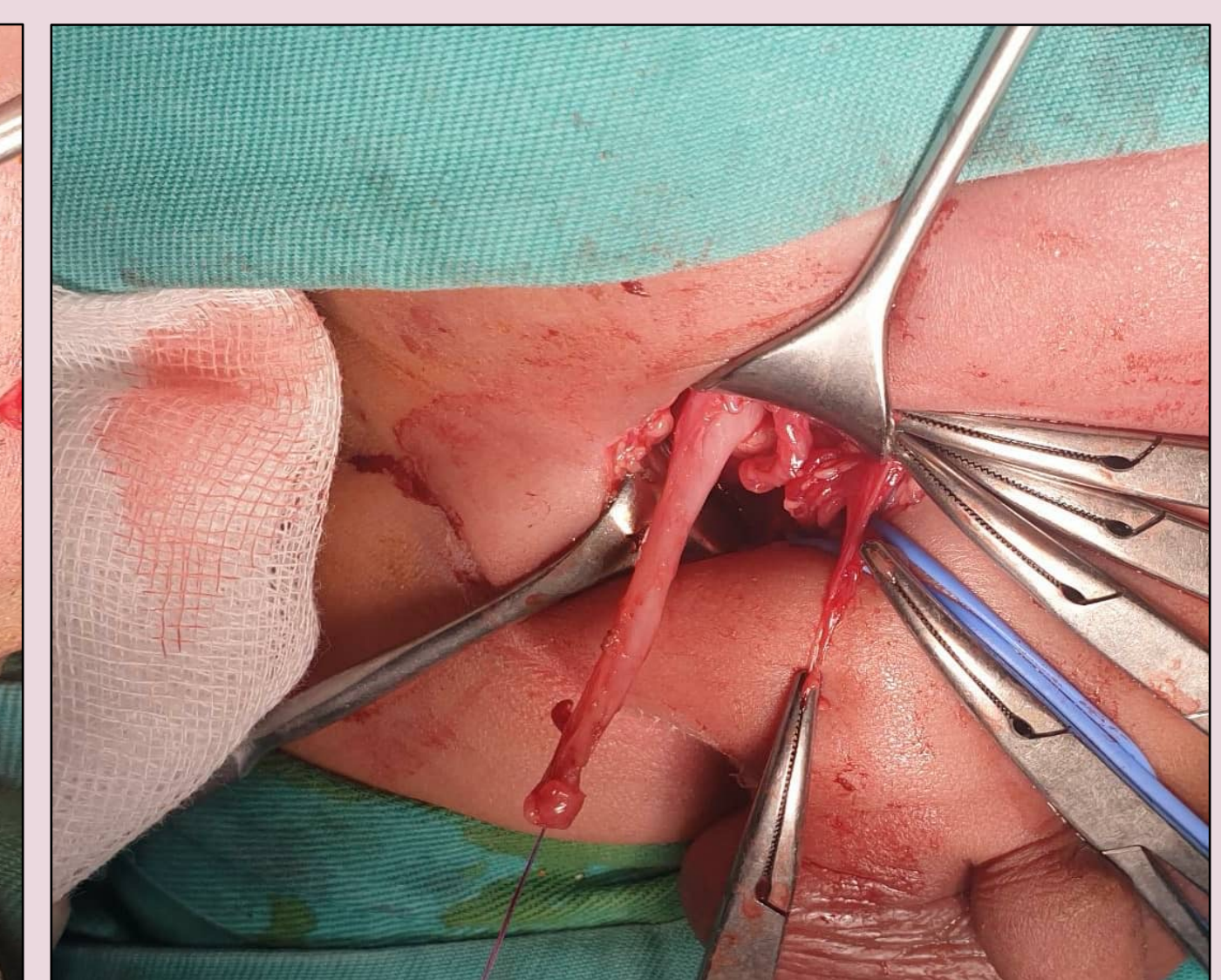


Figure 4: The appendiceal mobilization prior to appendicectomy

DISCUSSION

- The prevalence of AH is approximately 1%. However, just 0.1% of the condition is complicated by an acute appendicitis and lesser for perforated appendicitis^[2].
- The preoperative diagnosis of AH is difficult. Clinically, most cases presented as incarcerated inguinal hernia. The general manifestation like fever, vomiting and abdominal distension may be obscured due to narrow neck of the hernial sac which limits the spread of peritonitis^[3].
- The pathophysiology of appendicitis in AH is unknown. Some authors believed decrease vascularization during incarceration and manoeuvre to reduce the hernia leads to inflammation of the appendix^[3].
- Ultrasound and CT scan is questionable in view of limitation of ultrasound to appreciate appendix and radiation risk associated with CT^[4].
- Losanoff and Basson described types of AH and the management for adults^[1]. However, there is still lacking of consensus regarding how to deal with the normal appendix in pediatric patients with AH. Prophylactic appendectomy along with the hernia repair is not favored in non-inflamed appendix due to the increased risk of infection and hernia recurrence. Otherwise, in presence of an appendicitis, appendicectomy is recommended^[2,4].

CONCLUSION

Incarcerated inguinal hernia in neonates without symptoms of intestinal obstruction should raise a suspicion of Amyand's hernia. Presence of inflammation should prompt the possibility of acute appendicitis or even perforated appendicitis as reported in this case.

REFERENCES

- J.E. Losanoff, M.D. Basson, **Amyand hernia: what lies beneath—a proposed classification scheme to determine management.** *Am Surg*, 73 (12) (2007), pp. 1288-1290
- Asma Jabloun, Habib Bouthour, Samer Bustame, Fatma Trabelsi, Rabiaa Ben Abdallah, Najib Kaabar. **Amyand's hernia with appendicitis in the children: A delayed diagnosis.** *Journal of Paediatric Surgery Case Reports*, vol 13, October 2016, Pages 6-7
- M.N. Srouji, B.E. Buck. **Neonatal appendicitis: ischemic infarction in incarcerated inguinal hernia.** *J Pediatr Surg*, 13 (2) (1978), pp. 177-179
- Almetaher, H.A., Mansour, M.A. & Arafa, M.A. **Management of Amyand's hernia in children: should appendectomy be mandatory or not?** *Ann Pediatr Surg* 16, 14 (2020)