

The 5th International Academy of Pathology Malaysian Division, Annual Scientific Meeting: Mediastinal and Breast Pathology, was held at Shangri-la's Tanjung Aru Resort and Spa, Kota Kinabalu, Sabah on 27th - 28th October 2018. Abstracts of paper (poster) presented are as follows:

P1. A rare case of bilateral mucinosis of the breast

Barani Karikalan¹, Thanikachalam Meenakshi Pasupati²

¹Perdana University, Malaysia; ²Clinipath Pathology Laboratory, Malaysia

Introduction: Mucinosis of the breast is a very rare non-neoplastic breast lesion with only few cases reported in the literature. We present here one such rare case occurring as multiple nodules involving both breasts. *Case Report:* 43-year-old female presented with multiple lumps on both breasts for the past 6 months. The lumps had gradually increased in size. On palpation, the lumps were soft and mobile. The lumps were excised and sent for histopathological examination. *Pathological findings:* Grossly, lumps from both right and left breasts were received in multiple fragments and measured about 6 cm and 3 cm in aggregate, respectively. The lumps were soft in consistency. Sectioning of the lumps revealed cystic areas filled with mucinous material surrounded by adjacent normal breast tissue. Microscopically, multiple representative sections of the lumps from both breasts showed extensive areas of pale basophilic mucinous content, dispersed within the fibrocollagenous framework. There is no apparent lining of these cystic lesions containing the mucinous material within them. Normal appearing breast lobules are seen in the surrounding breast tissue. *Conclusion:* Primary mucinous neoplasms of the breast are the major differential diagnoses in this benign breast lesion. It is very important to identify this lesion in order to avoid inadequate treatment of the patient.

P2. A rare case of primary squamous cell carcinoma of thyroid: Diagnosed from fine needle aspiration

Mawarni Sharif¹, Najah Momin¹

¹Department of Pathology, Hospital Melaka

Introduction: Primary squamous cell carcinoma (SCC) of thyroid is extremely rare representing less than 1% of all primary thyroid malignancies. It grows rapidly and often present with tracheal or oesophageal compression. The prognosis is very poor with median survival of patient is less than 6 months. *Case Report:* A 57-year-old Malay lady, presented with anterior neck swelling for the past 3 months, associated with difficulty of breathing. Clinical examination showed huge thyroid nodules with diffuse, fixed, solid cystic inconsistency. The CT neck and thorax revealed huge thyroid mass occupying the left lobe with involvement of right lobe, measured 6.4 cm x 4.2 cm x 7.5 cm. The mass caused compression to the airway and displaced the trachea to the right. Multiple necrotic enlarged cervical lymph nodes were also seen. There were extensive scattered metastatic lung nodules. Nasopharynx, Fossa of Rosenmuller, oropharynx, laryngopharynx, parotid glands and submandibular glands were unremarkable. *Pathological findings:* Seven millilitres of brownish aspirate were obtained from fine needle aspiration (FNAC) of the thyroid nodules. Smears show a few clusters of atypical cells with irregular nuclear outlines, hyperchromatic nuclei and inconspicuous nucleoli. Cell block shows the atypical cells are positive for CKAE1/AE3, CK 7, CK 5/6 and p63. They are negative for CK 20, CEA, TTF-1, Thyroglobulin, CD 68, CD 45 and Calcitonin. *Conclusion:* SCC of thyroid is very rare and is an aggressive entity with poor prognosis. Excision of the tumour is highly recommended for proper histopathological evaluation. However, FNAC can give quick and reliable diagnosis to help clinician to determine the treatment plan.

P3. A review of anterior mediastinal mass pathology diagnosed in Hospital Universiti Sains Malaysia and Hospital Sultanah Bahiyah

Farhana Mohammad Mohaidin¹, Omar Mohammed Alzallal^{2,3}, Pavitratha Puspanathan¹, Faezahtul Arbaeyah Hussain^{2,3}

¹Department of Pathology, Hospital Sultanah Bahiyah, Alor Setar, Kedah, Malaysia; ²Department of Pathology, School of Medical Sciences, Universiti Sains Malaysia, Health Campus, Kubang Kerian, Kelantan, Malaysia; ³Hospital Universiti Sains Malaysia, Kubang Kerian, Kelantan, Malaysia

Introduction: Anterior mediastinal masses are relatively uncommon with wide variety of pathology. The mass can be divided into congenital or acquired, cystic or solid and primary or secondary. The most common diagnoses in childhood are germ cell tumours whereas lymphoma and thymic lesions are common in adults. We aim to review the various histopathology diagnoses of anterior mediastinal mass in two centres. *Materials and Methods:* Retrospective analysis of all cases retrieved from the Laboratory Information System database of Pathology Departments of Hospital Universiti Sains Malaysia (HUSM) and Hospital Sultanah Bahiyah (HSB), between 1st August 2014 until July 31st 2018. The clinicopathological parameters such age, gender, ethnic and histopathology diagnoses were included. The data were analysed using SPSS 24.0. *Results:* Sixty-two patients with anterior mediastinal mass were studied, 47 cases from HUSM and 15 cases from HSB. There were 34 males and 28 females with 53 adults and 9 children. The mean age was 23 years old. The histopathological diagnoses include lymphoma (22.6%), thymoma

(22.6%), germ cell tumours (19.4%), neuroendocrine tumour (8.1%), sarcoma (6.5%) and others (21%). Both germ cell tumour and sarcoma were common in paediatric age group with 55.6% and 11.1% incidence respectively. Whilst in adults, lymphoma and thymoma were the most diagnosed with 14 cases (26.4%) each. *Conclusion:* Anterior mediastinal mass has wide range of pathology and biopsy of the lesion is a challenging task. On most occasions, only small tissue sample is successfully obtained. Providing an accurate diagnosis is equally challenging to the pathologists as the sample is limited.

P4. Adrenomedullin and BCL2 distinguish normal endometrium from premalignant and malignant endometrium

Sugunah Sallapan¹, Nur Maya Sabrina Tizen¹, Muaatamarulain Mustangin¹, Noraidah Masir¹

¹*Department of Pathology, Universiti Kebangsaan Malaysia Medical Centre, Universiti Kebangsaan Malaysia, Kuala Lumpur, Malaysia*

Introduction: Adrenomedullin (AM) is angiogenic peptide implicated in the growth and differentiation of endometrium. B cell lymphoma 2 (BCL2) is an anti-apoptotic protein essential in regulation of cyclical endometrial breakdown. The present study aims to investigate Adrenomedullin and BCL2 protein expression in normal endometrium, hyperplastic endometrium without and with atypia, and endometrial carcinoma. *Methods:* Formalin-fixed paraffin-embedded tissues from 152 cases were selected. Tissue microarrays (TMA) were constructed from 56 cases of normal endometrium, 29 cases of hyperplasia without atypia, 11 cases of hyperplasia with atypia, and 56 cases of endometrial carcinoma. Immunohistochemistry study was performed for Adrenomedullin and BCL2 expression on these cases. Scoring of the protein expression was performed with Allred scoring system. *Results:* The mean expression of Adrenomedullin increases in endometrial carcinoma (7.5 +/- 1.009; p<0.05) than in normal endometrium (6.5 +/- 0.831), hyperplastic without atypia (6.28 +/- 1.509) and hyperplastic with atypia (6.55 +/- 1.293). The mean expression of BCL2 decreases in endometrial carcinoma (2 +/- 2.639; p<0.05) than in normal endometrium (5.7 +/- 2.763), hyperplastic without atypia (6.21 +/- 2.351) and hyperplastic with atypia (5.64 +/- 3.042). In addition, the expression of these 2 markers is significant between endometrial hyperplasia with and without atypia from endometrial carcinoma (p<0.05). Conversely no statistical different is seen between normal endometrium and hyperplasia with or without atypia (p>0.05). There is an inverse correlation between Adrenomedullin and BCL2 expressions (r: -0.327, p<0.001). *Conclusion:* In summary the expression of Adrenomedullin and BCL2 may be useful in distinguishing endometrial hyperplasia with and without atypia from endometrial carcinoma.

P5. Androgen receptor expression in triple negative breast carcinoma

Pei Yeing Teoh¹, Geok Chin Tan¹, Mahsin Hakimah², Yin Ping Wong¹

Department of Pathology, ¹Universiti Kebangsaan Malaysia Medical Centre; ²Penang General Hospital

Introduction: Androgen receptor (AR) was found to be the most frequently expressed biomarker in all breast carcinoma subtypes. AR immunopositivity in triple negative breast carcinomas (TNBC) has recently come into focus as a novel prognostic and predictive marker as well as potential index for targeted therapy. TNBC by definition is breast carcinoma lacking the immunopositivity of oestrogen and progesterone receptors and the absence of *HER2/neu* gene amplification. This study was to evaluate AR expression by immunohistochemistry in TNBC and its association with clinicopathological parameters. *Materials and Methods:* A total of 97 TNBC cases presented to Penang General Hospital from year 2014 to 2017 were reviewed and their AR immunopositivity were analysed. The cut-off point for AR immunopositivity was $\geq 1\%$ stained tumour cell nuclei regardless of staining intensity. *Results:* Of 97 TNBC, AR was expressed in 30 (31%) cases, with the proportion of AR-positive tumour cells ranged from 1% to 90%. These include 23 invasive carcinomas, no special type (NST) and 7 other carcinoma subtypes (invasive papillary, invasive lobular, clear cell and medullary carcinomas). Sixty-seven cases (69%) that showed AR immunonegativity were invasive carcinomas, NST (n=60), clear cell carcinoma (n=1) and metaplastic carcinoma (n=6). Positive AR immunoreactivity was inversely correlated with tumour grade and mitotic count (p<0.01), but not the tumour stage, tumour size and nodal status. *Conclusion:* AR is expressed in TNBC, in agreement with others. Loss of AR immunopositivity was observed in about 2/3 of breast cancer and it correlated with higher grade tumour. Larger cohorts for better characterisation of the role of AR immunopositivity in TNBC are warranted.

P6. Blastic plasmacytoid dendritic cell neoplasm: Diagnostic challenge with limited IHC in a referral centre

Faezhtul Arbaeyah Hussain¹, Ahmad Toha Samsudin²

¹*Department of Pathology, School of Medical Sciences, Universiti Sains Malaysia, Health Campus, Kubang Kerian, Kelantan, Malaysia; ²Hospital Universiti Sains Malaysia, Kubang Kerian, Kelantan, Malaysia; ³Department of Pathology, Queen Elizabeth Hospital, Kota Kinabalu, Sabah, Malaysia*

Introduction: Blastic plasmacytoid dendritic cell neoplasm (BPDCN) is a rare tumour that frequently presents with cutaneous lesions with or without bone marrow involvement and leukaemic dissemination. It is a clinically aggressive lesion with poor prognosis. The tumour derives from the precursors of plasmacytoid dendritic cells. *Clinical Case:* There were 4 cases of BPDCN

that were referred to Queen Elizabeth Hospital between 2014 to 2018. All four cases were from male patients aged between 35 to 78 years old, presented with localised skin lesions, which later spread. Three patients had constitutional symptoms. All patients had skin biopsy and 2 had trephine biopsy. To date, one patient died of the disease whilst the outcomes of the other three are unknown. *Pathological findings:* All of the skin biopsies showed no epidermotropism. The neoplastic cells were diffusely infiltrating within the dermis. They exhibit blastic features with high N:C of medium to large nuclear size, with small to prominent nucleoli. The cytoplasm was scanty to moderate amount. The ki67 was between 30 to 90%. Two cases were CD4+/CD56+/CD123+, 1 case with CD4-/CD56+/CD123+ and 1 case with CD4+/CD56-/CD123+. One of the trephine biopsies showed tumour infiltration (also has ki67 >90%). All of the cases were negative for B cell markers, CD34, Tdt, myeloperoxidase and cytotoxic markers. *Conclusion:* The differential diagnoses of BPDCN include Mature plasmacytoid dendritic cell proliferation (MPDCP), AML with monocytic differentiation and other myeloid disorders. TCL1 and CD303 are two other immunomarkers that are useful in making the diagnosis of BPDCN.

P7. Case report of a teratoid Wilms tumour

Chelvam Rajesvaran¹, Sukanya Banerjee Nair², Arni Talib², Zakaria Zahari³, Normawati Mat Said⁴, Teh Kok Hoi⁵

¹Department of Pathology, University of Malaya (UM); ²Department of Pathology, Kuala Lumpur Hospital, Ministry of Health Malaysia; ³Department of Paediatric Surgery, Kuala Lumpur Hospital, Ministry of Health Malaysia; ⁴Department of Radiology, Kuala Lumpur Hospital, Ministry of Health Malaysia; ⁵Department of Paediatrics, Kuala Lumpur Hospital, Ministry of Health Malaysia

Introduction: Wilms tumour, or nephroblastoma, is a childhood neoplasm with an incidence rate of 6 to 7%. Teratoid Wilms is a rare variant of Wilms tumour, defined as a Wilms tumour with more than 50% of heterologous elements. The heterogeneity of such tumours may result in misdiagnosis on biopsy material. There is no specific treatment guideline for the teratoid variant of Wilms tumour. Adjuvant therapy shows poor response due to the presence of mature heterologous elements, which are not chemo-sensitive. *Case Report:* A 13-month-old boy, with no known medical illness, presented with abdominal distension for 6 months. Computed tomography (CT) scan showed a huge heterogeneously enhancing mass arising from the right kidney. Pre-operative biopsy was reported as Wilms tumour. He was treated with chemotherapy. However, he did not show clinical response to the chemotherapy, with worsening abdominal distension. Repeat CT scan confirmed an enlarging tumour. Right nephrectomy was subsequently carried out. *Pathological findings:* Macroscopic examination showed a solid cystic firm white tumour involving the entire kidney, with a thin rim of normal kidney. Histological examination showed a predominance of heterologous stromal elements, mainly composed of glial tissue, amounting up to more than 50% of the overall tumour bulk. Typical blastemal and epithelial components were also identified. Histopathological diagnosis was a teratoid Wilms tumour. *Conclusion:* We report a rare case of teratoid variant of Wilms tumour. Due to the heterogeneity of such tumours, this diagnosis might be missed on biopsied material. It is generally a non-aggressive and non-metastatic tumour; however, adjuvant treatment is not beneficial due to presence of mature heterologous component. Adequate surgical excision is the mainstay of treatment.

P8. Chondrocutaneous branchial remnants

Tee YS¹, Chow TK¹

¹Department of Pathology, Faculty of Medicine, University Malaya

Introduction: Chondrocutaneous branchial remnant also known as congenital cartilaginous rest, wattle or cervical accessory tragus, is a rare cartilaginous choristoma of the neck. It arises either from the primordial laryngeal remnants of the branchial arches or ectopic auricular tissue. Associated congenital anomalies (auditory, gastrointestinal, genitourinary, cardiovascular) are present in about one-third of patients. *Clinical Cases:* A 19-month old boy presented with asymptomatic left neck swelling since birth. The 1x1cm, firm, mobile swelling is located over the lower third of left sternocleidomastoid muscle. The swelling is painless and not fixed to the underlying structures. The boy was also noted to have a hemangioma over his left lower limb at birth. He was delivered at full term without complications. *Pathological findings:* Small white firm glistening nodules of 0.3 to 0.5cm were present in the subcutaneous tissue of the excised neck swelling. The overlying ellipse of skin was unremarkable and covered in fine vellus hair. Histology revealed discrete islands of mature cartilage surrounded by fibrocollagenous bands within the subcutaneous tissue. Pacinian corpuscles were also noted adjacent to the cartilaginous tissue. The overlying skin adnexa, dermis and epidermis are within normal morphological limits. *Conclusion:* Chondrocutaneous branchial remnant is a benign congenital condition that can be treated by complete surgical excision. Its awareness is needed to eliminate diagnostic dilemmas and highlight its association with other congenital anomalies.

P9 Clinicopathological Spectrum of Epstein Barr virus (EBV) related B cell Non-Hodgkin Lymphoma (NHL) in KelantanFatin Muhamad Tamyez^{1,2,3}, Saleena Awang¹ and Faezahtul Arbaeyah Hussain^{2,3}

¹Department of Pathology, Hospital Sultanah Zainab II, Kota Bharu, Kelantan, Malaysia; ²Department of Pathology, School of Medical Sciences, Universiti Sains Malaysia, Health Campus, Kelantan, Malaysia; ³Hospital Universiti Sains Malaysia, Kubang Kerian, Kelantan, Malaysia

Introduction: EBV-related lymphoma is not a new entity in the WHO classification of the haematolymphoid neoplasms. It is relatively rare; and the distribution of this entity varies according to gender, age group, ethnic and type of B-NHL. The aim of this study is to enlist the epidemiological background of EBV-related B cell Non-Hodgkin lymphoma in the Kelantan population. **Materials and Methods:** We evaluated a total of 86 cases material formalin fixed paraffin embedded tissue block previously diagnosed B-NHL in Pathology Department of Hospital Universiti Sains Malaysia (HUSM) Kubang Kerian and Hospital Raja Perempuan Zainab II (HRPZ II). These cases were retrieved from LIS database from both centres, over a period of four years (2014-2017). PDLIM7 (LMP1 analogue) immunohistochemistry was used to detect the LMP1 EBV antigen. **Results:** Out of 86 cases of B cell NHL, 16 cases were positive for EBV. They were from 10 males and 6 females. Malays was the predominant ethnic (90%). The most common age group was between 40-45 years old. 13 cases were from nodal and 3 from extranodal sites. EBV was found mostly in diffuse large B cell lymphoma (14), 1 each from follicular lymphoma and high-grade B cell lymphoma. **Conclusion:** EBV-related B-NHL maybe under diagnosed in our society, due to EBV markers are not frequently used in the daily diagnostic work up. In addition, EBER is an expensive test to do routinely.

P10. Concurrent breast carcinoma and sarcoma – A rare caseNorhidayah Jalani¹, Noraini Mohd Dusa², Rafis Ruzairie Awang³

¹Department of Pathology, University Malaya Medical Center; ²Department of Pathology, Hospital Kuala Lumpur; ³Department of Surgery, Hospital Kuala Lumpur

Introduction: Women with newly diagnosed breast carcinoma have 0.2 to 3% risk of developing synchronous or metachronous carcinoma. This feature is usually seen in lobular carcinoma. However, we report a rare case of bilateral breast tumour with different histological features, an invasive lobular carcinoma of the right breast and a sarcoma of the left breast. **Case Report:** A 59-year-old lady presented with sepsis due to left breast abscess. On physical examination, there was a huge fungating left breast lump and another lump from right breast was also palpable. Biopsy from the right breast shows invasive carcinoma and the left breast biopsy is highly suggestive of malignant phylloides tumour. Bilateral mastectomy, right axillary clearance and resection of sixth and seventh ribs were done. **Pathological findings:** Gross examination shows retraction of the right nipple associated with three ill-defined tumours. The left breast shows a huge tumour, 130x105x100mm at lower outer quadrant with ulcer and necrotic skin surface. Serial sections show solid tumour with tan grayish cut surface. Microscopic examination shows invasive lobular carcinoma, no special type at the right breast. Three out of 14 right axillary lymph nodes are infiltrated by the malignant cells. The left breast tumour is composed of malignant spindle cells with focal positivity for SMA and negative for CD34, Desmin, H-caldesmon, Myogenin, S100 and CKAE1/AE3. **Conclusion:** Concurrent breast carcinoma and breast sarcoma is rare and aggressive. Thus, early detection and treatment is needed for proper management of the patient.

P11. Depth makes a difference: Microcystic adnexal carcinoma – A case report

Chew Man Fong, Toh Yen Fa

Department of Pathology, Faculty of Medicine, University of Malaya

Introduction: Cutaneous appendageal neoplasms are diagnostic challenges to many histopathologists. We report a case of microcystic adnexal carcinoma, an uncommon appendageal tumour. The cell of origin is considered to be pluripotential adnexal keratinocyte which is capable of follicular and sweat gland differentiation. **Case Report:** A 55-year-old Chinese female presented with slow growing right upper lip swelling for 3 years. Physical examination revealed a firm indurated lesion measuring 2x1cm, adherent to buccal mucosa and overlying skin surface. **Pathological findings:** Initial biopsy measured 1.8x0.5cm displaying intact epidermis and dense sclerotic stroma infiltrated by tadpole shaped ducts, basaloid keratinocytic nests, horn cysts and abortive follicles with little cytologic atypia and mitotic figures. The depth of the biopsy revealed aggressive intramuscular infiltration and extensive perineural invasion. Subsequent wide local excision included part of buccal mucosa and residual tumour was seen deep seated within muscle at previous biopsy site. Intraoperative frozen section declared margin clearance. **Conclusion:** Awareness of microcystic adnexal carcinoma as a distinct clinicopathologic entity (typically indurated growth in upper lip of female patients) and a deep biopsy are the cornerstone for accurate diagnosis, optimal management and outcome. The characteristic biphasic growth pattern and most importantly extensive local invasion should be demonstrated on biopsy with adequate depth. Superficial biopsy may be particularly challenging. Immunoperoxidase is usually unhelpful, as no single stain has proven absolute reliability in distinguishing the various entities of the differential diagnoses.

P12. Diagnostic difficulties in the interpretation of fine needle aspiration cytology in salivary gland lesions: Lessons from our institution

Aliza A¹, Nor Akmar T¹, Suryani MY¹

¹Department of Pathology, Hospital Tuanku Jaafar Seremban, Negeri Sembilan

Introduction: Salivary gland fine needle aspirations (FNA) are a common specimen in most pathology practices and present difficult interpretation challenges because of overlapping cytologic characteristics of salivary gland tumours. *Objectives:* To determine the sensitivity and specificity of FNAC diagnosis of salivary gland tumours and to identify the contributing factors of diagnostic errors. *Materials and Methods:* A retrospective review of 151 FNA samples of salivary glands tumours were compared with its corresponding histopathology diagnosis. The false positive and false negative cases were reviewed to identify cytological characteristics that contributed to its false diagnoses. *Results:* Out of 151 FNA samples, 60 cases had a histologic diagnosis with interpretations of benign or malignant. The sensitivity and specificity for correct interpretation were 54% and 84% respectively. The most common false positive diagnoses from FNA were adenocarcinoma, acinic cell carcinoma and mucoepidermoid carcinoma. Benign cases with false positive diagnoses from FNA were Warthin tumour and Pleomorphic adenoma. All discordant cases were reviewed and possible explanations for diagnostic errors are also discussed. *Conclusion:* These data confirm the difficulty associated with diagnosis of salivary glands FNA. Pathologists should be aware of cytological characteristics overlap and its pitfalls.

P13. Diagnostic value of EZH2 immunomarker in malignant effusion cytology

Piao Piao Ang¹, Karim Norain², Geok Chin Tan¹, Yin Ping Wong¹

Department of Pathology, ¹Universiti Kebangsaan Malaysia Medical Centre, Kuala Lumpur; ²Hospital Raja Permaisuri Bainun, Ipoh, Perak

Introduction: Distinguishing reactive mesothelial cells from metastatic carcinoma in effusion cytology can sometimes be problematic and diagnostically challenging. A panel of at least four monoclonal antibodies comprising of two mesothelial markers (calretinin, WT-1) and two epithelial markers (Ber-EP4, MOC-31) are helpful in this distinction, however is not applicable as routine in centres with limited resources. Enhancer of zeste homolog 2 (EZH2), a novel immunomarker, is found aberrantly expressed in various malignant solid tumours. We conducted a cross-sectional study to investigate the utility of EZH2 as a single immunomarker in the diagnosis of metastatic carcinoma in effusion samples. *Materials and Methods:* A total of 101 pleural, pericardial and peritoneal effusions/washings diagnosed by cytomorphology as unequivocally reactive (n=34) and metastatic carcinoma (n=67) over two-year were reviewed. Among the metastatic carcinoma, 65 were adenocarcinoma and the other two was squamous cell carcinoma and giant cell tumour respectively. Cell block sections were immunostained by EZH2 (Cell Marque). The cut-off point for EZH2 immunopositivity was taken as nuclear staining in $\geq 10\%$ of tumour cells. *Results:* None of the reactive effusions was stained positive for EZH2, while 64 out of 67 (95%) metastatic carcinoma cases exhibited EZH2 immunoreactivity. The three EZH2-negative cases were all metastatic adenocarcinomas, denoting false-negative results. EZH2 demonstrated diagnostic sensitivity, specificity, positive predictive value and negative predictive value of 95%, 100%, 100% and 92% (p<0.0001) respectively as a single marker. *Conclusion:* EZH2 could serve as a novel single diagnostic immunomarker which is inexpensive and yet reliable in malignant effusion cytology that may be incorporated into routine practice, especially in resource-limited centres.

P14. Giant cell lung carcinoma: A case report

Rita Cempaka S¹, Didik Setyo Heriyanto¹, Lini Sunaryo², Iswanto³, Nungki Anggorowati¹

¹Anatomic Pathology Department, Faculty of Medicine, Universitas Gadjah Mada, Yogyakarta, Indonesia; ²Anatomic Pathology Laboratory, Muntilan General Hospital, Muntilan, Indonesia; ³Pulmonology Department, Panti Rapih Hospital, Yogyakarta, Indonesia

Introduction: Giant cell lung carcinoma (GCLC) is a rare lung carcinoma. GCLC is a variant of sarcomatoid carcinoma of the lung. GCLC is one of more aggressive form of lung carcinomas. GCLC has no specific radiological features. Cytological examination is a superior diagnosis approach than biopsy because it can reduce the likelihood of tumour dispersal. Cytological examination should be able to distinguish giant cell carcinoma from large cell carcinoma. *Case Report:* A 72-year-old man referred to the hospital because of right chest pain and dyspnoea. The symptom was getting severe during the last 6 months. The patient was a heavy smoker until 6 months ago. Chest CT scan showed round, solitary, well circumscribed mass of the right superior lobe. *Pathological findings:* Cytological features from the lung mass showed anaplastic and pleomorphic giant cells, multinucleated forms to large mononuclear forms. Few areas showed anaplastic and pleomorphic giant cells surrounded by a pretty much leucocyte neutrophils. Several anaplastic and pleomorphic giant cells phagocytised leucocyte neutrophils (emperipolesis). *Conclusion:* The clinical presentation, history of smoking, radiological appearance and most importantly the cytological features addressed the diagnosis toward giant cell lung carcinoma.

P15. Gliosarcoma with predominance sarcomatous component that mimics high-grade meningiomaNor Haizura Abd Rani¹, Fadhli Mustaffa², Chuan Wui Teoh³, Flora Li Tze Chong³, Nornazirah Azizan⁴

¹Department of Pathology, Queen Elizabeth Hospital, Sabah, Malaysia; ²Department of Pathology, Hospital Tengku Ampuan Afzan, Pahang, Malaysia; ³Department of Radiotherapy and Oncology, Nuclear Medicine and Radiotherapy Centre, Sabah Women and Children Hospital (SWACH), Sabah, Malaysia; ⁴Department of Pathobiology and Medical Diagnostic, Faculty of Medicine and Health Sciences, Universiti Malaysia Sabah, Sabah, Malaysia

Introduction: Gliosarcoma is a rare primary malignant tumour of a central nervous system. It is a glioblastoma variant with biphasic tissue pattern of glial and mesenchymal differentiation. Gliosarcoma with predominant sarcomatous component mimicking a meningioma with prolonged survival rate has been reported. **Case Report:** A 28-year-old gentleman presented with multiple episodes of unprovoked fitting with severe headache. Contrast-enhanced computed tomography (CT) brain revealed right parietal intracranial mass with surrounding mass effect. Radiology and intra-operative findings give an impression of convexity anaplastic meningioma. Tumour debulking was performed. Patient was asymptomatic with no tumour recurrence for 3 years after completion of adjuvant chemotherapy. **Pathological findings:** Histology shows a biphasic cellular tumour composed of predominant sarcomatous and glial components. The sarcomatoid component is composed of cellular spindle cells arranged in interlacing fascicles. The glial component exhibits pleomorphic cells with palisading necrosis, endothelial hyperplasia and occasional bizarre nuclei. Pseudopapillary pattern surrounded by extensive necrosis and haemorrhage are noted. Mitotic figures, invasion into brain parenchyma and effacement to the dura are present. The glial cells expressed Glial Fibrillary Acid Protein, Vimentin and S-100; negative for Epithelial Membrane Antigen, Progesterone Receptor, ruling out the diagnosis of meningioma. The sarcomatous component is immunoreactive to Vimentin. Reticulin stain shows biphasic tissue pattern of reticulin-rich sarcomatous and reticulin-free gliomatous areas. Proliferative index Ki-67 is increased. **Conclusion:** In case of gliosarcoma with predominance sarcomatous component that mimics high-grade meningioma, a strong correlation between clinical, radiological, intraoperative findings and histopathology are needed to establish the diagnosis.

P16. HBME-1 expression in differentiating benign and malignant thyroid lesionsNoor 'Ain Mohd Nasir¹, Azyani Yahaya¹, Nordashima Abd Shukor¹, Mohd Rohaizat Hassan², Mazne Mahasin¹

¹Department of Pathology, University Kebangsaan Malaysia Medical Centre, Kuala Lumpur, Malaysia; ²Department of Community Health University Kebangsaan Malaysia Medical Centre, Kuala Lumpur, Malaysia

Introduction: Thyroid carcinomas are classically diagnosed based on specific histomorphological criteria. However, in some cases, definitive diagnosis may be difficult when morphological features are equivocal. This study evaluates the utility of Hectort Battifora mesothelial-1 (HBME-1) as an immunohistochemical marker to differentiate malignant from benign thyroid lesions and to compare its expression in different types of thyroid lesions. We also study the sensitivity and specificity of HBME-1 as a specific marker for thyroid carcinoma. **Materials and Methods:** We collected 54 malignant and 54 benign thyroid lesions diagnosed in our centre between January 2010 and December 2016. All cases were immunohistochemically stained with HBME-1 and evaluated by three independent observers. The cases were scored based on proportion of staining and finally graded as negative, weak positive (1+), moderate positive (2+) or strong positive (3+). In addition, the score of malignant cases were correlated with their pathological tumour stage. **Results:** HBME-1 staining expression was higher in malignant compared to benign lesions ($p < 0.001$). Papillary thyroid carcinoma (PTC) showed the highest expression among the carcinoma cases (87%). Benign lesions were mostly negative (96%), except two follicular adenoma cases having weak positivity. HBME-1 had sensitivity of 57% and specificity of 96% in thyroid carcinoma. There was no correlation between HBME-1 expression and TNM primary tumour stage (pT). **Conclusion:** HBME-1 is a useful marker in differentiating malignant from benign thyroid lesions, especially in PTC cases.

P17. Hepatic sarcoidosis: Single centre's experience in Malaysia – A Case SeriesSyuhada Dan Adnan¹, Ameera Ashyila Kamaruzaman², Wan Azura Wan Yaacob³, Hajar Ahmad Rosdi⁴, Ooi Boon Han⁵

¹Department of Hepatology, Hospital Selayang; ^{2,3}Department of Pathology, Hospital Selayang; ⁴Clinical Research Centre, Hospital Selayang; ⁵Department of Gastroenterology, Hospital Kuala Lumpur

Introduction: Sarcoidosis is a multisystemic disease of unknown aetiology with the liver being the third most commonly affected organ. It occurs 0.1 to 0.9 percent in sarcoidosis patient. These cases compare patient demographics, clinical features, radiological findings, histopathological findings, extrahepatic manifestations and response to treatment of patients with hepatic sarcoidosis. **Materials and Methods:** Retrospective study on all patients with histological diagnosis of hepatic sarcoidosis between year 2014 and 2017 at our centre. **Results:** There were only two patients with histology diagnosis of hepatic sarcoidosis identified. Both are women but from different ethnicities. The mean age was 45. Both cases were associated with different extrahepatic manifestations including lungs and bone marrow. All cases were treated with steroids and their symptoms and blood parameters improved. **Conclusion:** This case series include small number of patients but represent hepatic sarcoidosis in Malaysia. Hepatic sarcoidosis is very rare in Malaysia and diagnosis may be challenging due to no single laboratory test or radiographic findings can diagnose this systemic disease. Diagnosis is based on a combination of clinical, laboratory and histological manifestations. The treatment of hepatic sarcoidosis is also difficult with no large randomised controlled trials done to date.

P18. Immunohistochemical detection of Hepatitis B antigen in hepatocellular carcinoma

Chelvam Rajesvaran¹, Shobana Mukunda Devan², Hoo Hui Ling³, Rosmawati Mohamed⁴, Wong Kum Thong¹

¹Department of Pathology, Faculty of Medicine, University of Malaya, Malaysia; ²Department of Pathology, Hospital Selayang, Ministry of Health, Malaysia; ³Department of Pathology, Straits Medical Centre, Malacca, Malaysia; ⁴Department of Medicine, Faculty of Medicine, University of Malaya, Malaysia

Introduction: Chronic Hepatitis B virus (HBV) infection is associated with the development of hepatocellular carcinoma (HCC) by inducing a spectrum of chronic necroinflammatory and cirrhotic changes in the liver. We investigate the prevalence, cellular localisation and persistence of HBV surface antigens (HBsAg) in HCC in formalin-fixed, paraffin-embedded tissues by standard immunohistochemistry (IHC). **Materials and Methods:** From 2012 to 2016, 95 out of 180 of archived liver resection biopsies of HCC were suitable for HBsAg IHC staining. **Results:** Ninety-one HCC cases were serologically HBV positive. Four cases were serologically negative for both Hepatitis B and Hepatitis C viruses. All serologically negative Hepatitis B and C cases were also negative for HBsAg staining. Among the serologically positive HBV cohort, 73 out of 91 (80%) were positive for the HBsAg IHC. The distribution of HBsAg was patchy, and found in <25% of the non-tumoural liver tissue, which was mostly cirrhotic. Three cases showed IHC positivity in the HCC cells alone, while 4 cases were positive in both the HCC cells and adjacent non-tumoural liver. **Conclusion:** HBsAg is important in the development of hepatocellular carcinoma. The expression of the antigen in liver tissue can be patchy and limited, and primarily expressed in cirrhotic liver tissue.

P19. Intramuscular angioma with a significance admixture of fat with vascular transformation

Lini Sunaryo¹, Wawan Suci², Rita Cempaka³

¹Pathological Anatomy Laboratory RSUD Muntilan, Kabupaten Magelang, Indonesia; ²Surgical Department RSUD Muntilan, Kabupaten Magelang, Indonesia; ³Pathological Anatomy, Faculty of Medicine, Gadjah Mada University, Jogjakarta, Indonesia

Introduction: Intramuscular angioma is one type of vascular malformation that is composed of combinations of blood vessels and lymphatic involvement and it is a rare entity. Intramuscular vascular malformations are also likely to be confused with a malignant vascular tumour. Presence of fat in this lesion may lead to diagnosis of lipoma. **Case Report:** We report a case of a 38-year-old woman who was diagnosed with sarcoma tumour. She presented with a mass in her left thigh for more than 10 years, since childhood. The palpable mass grew bigger and painful, rather firm. Radiological finding was a vivid soft tissue mass. **Pathological findings:** The tumour mass showed skeletal muscles with atrophic areas, which was infiltrated by fibrous tissue, fat tissue, and back-to-back venous vascular and lymphoid vessels. **Conclusion:** Correlation of patient's information, clinical, radiological and histopathological findings are essential to make the right diagnosis.

P20 Leiomyomatosis peritonealis disseminata masquerading as disseminated ovarian malignancy

Siti Shakinah Sobri¹, Pavitratha Puspanathan¹

¹Pathology Department, Hospital Sultanah Bahiyah, Alor Setar, Kedah

Introduction: Leiomyomatosis peritonealis disseminata (LPD) is a rare condition consisting of multiple leiomyomas within the peritoneal cavity and clinically can mimic disseminated abdominal carcinoma. Our patient is a 43-year-old lady who presented with a solid ovarian tumour and underwent radical surgery. Diagnosis of this uncommon condition was made on histological examination. **Case Report:** This is a case of a 43-year-old lady, Para 4, with underlying hypertension and diabetes. She complained of abdominal discomfort with progressive enlargement of abdominal mass for one-month duration. Physical examination revealed a mass around the umbilical region. CT scan showed a solid mass with necrotic component suggestive of a left ovarian tumour with no evidence of metastasis. Operative findings revealed bilateral ovarian tumours with the left side adhered to pelvic wall, as well as presence of capsular involvement and multiple nodules over pelvic peritoneum, bladder peritoneum, abdominal peritoneum and omentum, consistent with FIGO stage 3B. TAHBSO, appendectomy and omentectomy was performed. **Pathologic findings:** There were a 5 cm right ovarian chocolate cyst and a 15 cm solid left ovarian tumour with nodular capsular surface. The tumour was firm to hard with whitish whorled surfaces. Multiple small (<1 cm) nodules were present on uterine surface and omentum. Three fibroids were seen within the myometrium. Histopathological examination revealed all the lesions to be leiomyomas (h-caldesmon immunostain positive). The right ovary and appendix showed presence of endometriosis. **Conclusion:** LPD is a benign condition that has a grossly malignant appearance. Differentiation from malignant disease can only be made through histopathological examination.

P21. Low grade fibromyxoid sarcoma with osteosarcoma-like features

Nasrun Hasenan^{1,2}, Sharifah Emilia Tuan Sharif^{1,2}, Seoparjoo Azmel Mohd Isa^{1,2}, Malisalaora M^{1,2}

¹Department of Pathology, School of Medical Sciences, Universiti Sains Malaysia, Health Campus, 16150, Kelantan, Malaysia;

²Department of Pathology, Hospital Universiti Sains Malaysia, 16150, Kota Bharu, Kelantan, Malaysia

Introduction: Low grade fibromyxoid sarcoma (LGFMS) is generally a soft tissue tumour affecting deep soft tissue typically occurs in young adults. LGFMS with osseous metaplasia is very rare and the metaplastic component resembled osteosarcoma was not reported yet. *Case Report:* Here we report a case of 30-year-old Malay male presented with slow growing painless mass over his left leg for 5 years duration. Physical examination revealed a rounded mobile mass of 15x10cm on the calf. Magnetic resonance imaging showed a solid cystic mass arising from the lateral head of gastrocnemius muscle. *Pathological Findings:* Grossly, it was a lobulated tumour exhibiting greyish solid and yellowish soft myxoid surface. Histologically, it is composed of fibrous and myxoid tumour arranged in vague nodular pattern. The lesional cells display bland looking oval to spindle shaped cells. Scattered curvilinear vessels are seen in the myxoid background. Lace-like osteoid intermingled with large hyperchromatic atypical cells resembled osteosarcoma were seen in focal areas. The lesional cells are focally positive for SMA, Desmin, CD34 and MUC-4. *Conclusion:* The presence of osteosarcoma-like features was alarming, despite the deceptively bland histological appearance. Hence, along with its rarity, the diagnosis was a challenge.

P22. Metaplastic thymoma in mediastinum

CC Fang¹, Basheer A Kareem¹, Isnisyam Saaya²

¹Department of Cardiothoracic Surgery, Penang General Hospital, Penang, Malaysia; ²Department of Pathology, Penang General Hospital, Penang, Malaysia

Introduction: Metaplastic thymoma (MT) is an extremely rare, biphasic, primary thymic epithelial tumour consisting of a mixture of polygonal cell components and spindle cell components. Its biologic behaviour is uncertain. *Case Report:* A 55-year-old woman presented to our hospital with cough and chest discomfort. An abnormally widened mediastinum shadow was seen on chest x-ray. Chest computed tomography (CT) revealed a well-circumscribed lesion measuring 5.2x4.8cm in the anterior mediastinum. The thymus was resected with the surrounding fat tissue by performing a median sternotomy. *Pathological findings:* The resected sample was a well-circumscribed lobulated 5x5cm tumour, and its cut surface was yellowish-tan and solid with cystic cavity within. Pathological findings include a biphasic pattern of epithelial and spindle cells. AE1/AE3 was strongly positive in the epithelial component, while vimentin and EMA were positive in the spindle cell component. The patient was diagnosed with biphasic, metaplastic thymoma with polygonal cell and spindle cell components histologically. *Conclusion:* Metaplastic thymomas are more commonly found to be benign tumours based on molecular analysis and relatively long survival rate. Surgical excision alone is sufficient and recommended unless the histopathological findings show malignant features. In view of the distinctive histologic appearance and indolent clinical behaviour, MT should be distinguished from other more aggressive mediastinal neoplasms which also display biphasic pattern.

P23. Metastasis from cervical cancer manifesting as a duodenal polyp: An odd presentation

Noor 'Ain Mohd Nasir, Fazarina Mohammed

Department of Pathology, Universiti Kebangsaan Malaysia Medical Centre, Kuala Lumpur, Malaysia

Introduction: Cervical cancer is the third most common cancer in Malaysian females. The occurrence of duodenal metastasis from cervical squamous cell carcinoma (SCC) is rare. We report a case of a 61-year-old woman with cervical SCC presenting with a duodenal polyp diagnosed as metastatic SCC with primary from the cervix. *Case Report:* This is a case of a 61-year-old lady with cervical carcinoma stage 2b who completed concurrent chemoradiation therapy and three cycles of brachytherapy. She also had peptic ulcer disease. She presented in January 2018 with poor oral intake; associated with nausea, vomiting, generalised lethargy and painful defaecation. An upper gastrointestinal (GI) scope was performed and revealed pan-gastritis and a duodenal polyp which was biopsied. Later, her condition worsened and succumbed to the illness after three weeks of hospitalisation. *Pathological findings:* The duodenal polyp showed fragments of duodenal tissue with scattered small clusters of malignant cells within small-sized vascular channels and stroma. The cells were positive for CK7, p63 and p16. The cells were negative for CK20 and synaptophysin. The polyp was diagnosed as metastatic SCC, primary likely from cervix. *Conclusion:* The clinical manifestation of upper GI symptoms due to duodenal metastasis from SCC of cervix is unusual and clinicians should have awareness of such rare presentation. Confirmation by histopathological evaluation is crucial for best therapeutic management in these patients.

P24. Methotrexate related EBV-positive mucocutaneous ulcer

Noor Afidah Abdullah , Najah Momin

Department of Pathology, Hospital Melaka

Introduction: Epstein–Barr virus-positive mucocutaneous ulcer (EBVMCU) comprises part of the spectrum of B-cell lymphoproliferative disorders, reported in the settings of immunosenescence and iatrogenic immunosuppression, affecting the oropharyngeal mucosa, skin, and gastrointestinal tract. **Case Report:** We report a case of a 64-year-old female, a known case of rheumatoid arthritis on Methotrexate (MTX) for 5 years. She presented with a painful ulcer at lateral border of tongue for one month. There was no evidence of systemic lymphadenopathy, hepatosplenomegaly and bone marrow involvement. Biopsy was taken from the ulcer site and diagnosis of anaplastic large cell lymphoma was made. The clinician stopped MTX, in which one month later, the patient was found well without tongue ulcer. The initial biopsy slides were reviewed and final diagnosis was revised as EBV-positive mucocutaneous ulcer. **Pathological findings:** Histopathological examination shows large atypical lymphoid cells with enlarged vesicular nuclei, prominent nucleoli, and moderate eosinophilic cytoplasm. The atypical lymphoid cells are positive for CD30 but negative for CD3, CD5, CD20, CD15 and CD246. Ki-67 shows high proliferative index. EBV-encoded small RNA (EBER) is positive. **Conclusion:** EBVMCU is a unique entity that must be considered as a differential diagnosis in a case presenting with mucosal ulceration. Differentiation from aggressive lymphoma which is a histologic mimicker is essential because EBVMCU due to methotrexate can resolve with the withdrawal of immunosuppressive agents.

P25. MMR protein expression in colorectal carcinoma in Hospital Sultanah Bahiyah Alor Setar (HSBAS)Yi-Shuang Tan, Masitah Hamid, Nik Raihan Nik Mustapha*Jabatan Patologi, Hospital Sultanah Bahiyah, Alor Setar*

Introduction: Colorectal adenocarcinoma (CRC) is one of the commonest cancers worldwide and 12-15% results from deficiency in DNA mismatch repair (MMR), giving a phenotype called microsatellite instability (MSI). MSI tumours develop either from germline mutation in MMR gene (namely MLH1, MSH2, MSH6 and PMS2; i.e. Lynch syndrome) or more commonly, from epigenetic inactivation of *MLH1* (sporadic MSI). They have more favourable prognosis than microsatellite stable tumours and are often resistant to 5-FU-based chemotherapy. Known MSI tumour-related clinicopathologic features include young age (<50 years), proximal colon involvement, abundant tumour-infiltrating lymphocytes (TILs), mucinous and signet-ring morphologies, as well as, poor differentiation. **Materials and Methods:** Clinicopathologic information was obtained from e-Hospital Information System HSBAS for all patients who had bowel resection for CRC, from January to December 2017. Immunohistochemical (IHC) tests for MLH1, MSH2, MSH6 and PMS2 proteins were performed on tumour tissue for cases that had one or more MSI tumour-related clinicopathologic features. **Results:** Twenty-seven out of 66 cases had MSI tumour-related clinicopathologic feature(s) and were selected for MMR IHC testing. Nine showed loss of MMR protein expression, i.e. absent MLH1 and PMS2 (four), absent MSH2 and MSH6 (three) and absent PMS2 only (two). There were 4 right-sided, 3 mucinous and 3 poorly-differentiated tumours. Two had marked TILs. Three patients were <50 years old. **Conclusion:** Deficiency in MMR protein expression is detected in 13.6% of CRC in HSBAS. These patients require referral for germline mutation testing to detect those with Lynch syndrome. Chemotherapy regime and prognostication also need to be tailored for this group of patients.

P26. Nasopharyngeal carcinoma in a young boy presented with cervical lymphadenopathyNurul Shuhada Abdul Hamid¹, Wan Faiziah Wan Abdul Rahman¹, Faezahtul Arbaeyah Hussain¹, Norhafiza Mat Lazim², Norsarwany Mohamad³¹*Department of Pathology;* ²*Department of Otorhinolaryngology-Head & Neck Surgery;* ³*Department of Paediatric, School of Medical Sciences, Universiti Sains Malaysia Health Campus, Kelantan, Malaysia*

Introduction: Nasopharyngeal carcinoma (NPC) is very uncommon in young children. The diagnosis is also challenging as the clinical presentation may mimic infection or haematolymphoid malignancy. **Case Report:** We report a case of a 9-year-old Malay boy presented with painless right neck swelling for 3 months. Physical examination showed right cervical lymphadenopathy, with no organomegaly. FNAC was reported as granulomatous lymphadenopathy and excisional biopsy as metastatic carcinoma. Following that, panendoscopy was carried out and revealed friable tissue over the nasopharynx. Computed tomography detected an ill-defined heterogeneously enhancing lesion of the right nasopharynx. **Pathological findings:** Biopsy of the right cervical lymph nodes showed a sinusoidal pattern of malignant epithelial cells arranged in syncytial and intermingled with small mature lymphocytes. The cells have oval to spindle vesicular nuclei with conspicuous nucleoli, scant eosinophilic cytoplasm with indistinct border. Mitotic figures were apparent including the aberrant forms. There was a cyst with papillary fronds at the centre of the lymph node, aggregates of neutrophils forming microabscess and scattered eosinophils. The cells were non-immunoreactive for hematolymphoid markers, CK7 and CK20. However, the meshwork pattern showed strong positivity for CKAE1/AE3 and p63 that gave the impression of metastatic NPC. Biopsy from the friable tissue of nasopharynx confirmed a diagnosis of non-keratinising NPC, undifferentiated subtype. **Conclusion:** Despite the rarity of cases, painless neck lumps in children should raised the suspicion of NPC. A multidisciplinary approach with clinicopathological-correlation is essential in diagnosis.

P27. Nodule-in-nodule: Noninvasive follicular thyroid neoplasm with papillary-like nuclear features (NIFTP) arising in a follicular adenoma

Ewe Seng Ch'ng, Hasmah Hussin

Advanced Medical and Dental Institute, Universiti Sains Malaysia

Introduction: Noninvasive follicular thyroid neoplasm with papillary-like nuclear features (NIFTP) is a new terminology proposed to replace the previously known entity of encapsulated follicular variant of papillary thyroid carcinoma (PTC). NIFTP is defined by a set of reproducible histological criteria and reflects the highly indolent behaviour of this neoplasm. Herein, a case of unique nodule-in-nodule appearance of NIFTP arising in a follicular adenoma (FA) is described. *Case Report:* A 28-year-old lady presented with anterior neck swelling for 3 months. Ultrasound examination showed a well-defined right solitary thyroid nodule. Fine needle aspiration cytology revealed a benign follicular nodule. Right hemithyroidectomy was subsequently performed. *Pathological findings:* The right hemithyroidectomy specimen shows a large circumscribed, well-encapsulated nodule occupying almost the whole right thyroid lobe. This large nodule harbours another circumscribed solid nodule (23x20x25mm), giving rise to nodule-in-nodule appearance. Microscopic examination reveals a large FA with a complete fibrous capsule without capsular or vascular invasion. Within this FA, the smaller solid nodule is well-demarcated from the surrounding thyroid follicles. It is composed exclusively of small compact follicles without papillary architecture. The follicular cells however display papillary-like nuclear features. As such, the diagnosis of "NIFTP arising in a FA" is rendered. *Conclusion:* It is important to apply strict criteria to follicular lesions with papillary-like nuclear features to accurately identify such cases as NIFTP. This would help to avoid unnecessary aggressive treatment that is usually administered for PTC. The unique nodule-in-nodule arrangement of NIFTP in a FA also reflects the common RAS mutations in such follicular neoplasms.

P28. Pathological characteristics of colorectal carcinoma in the young

Mardiana Abdul Aziz¹, Effat Omar^{1,2}, Sabariah Abdul Rahman¹, Nor Salmah Bakar¹

¹*Anatomic Pathology Unit, Department of Pathology, Faculty of Medicine, Universiti Teknologi MARA, Sg Buloh, Selangor;*

²*Institute for Pathology, Laboratory and Forensic Medicine (I-PPerForM), Faculty of Medicine, Universiti Teknologi MARA, Sg Buloh, Selangor*

Introduction: Colorectal carcinoma (CRC) is one of the most common cancers worldwide. While historically being common in the older age group, its incidence in the younger population is increasing. CRC in the young has also been described as being more aggressive. This study was conducted to identify i) the frequency of CRC in the young diagnosed on colorectal biopsies in Faculty of Medicine, Universiti Teknologi MARA, and ii) the histopathological characteristics of CRC seen in colorectal biopsies in the young. *Materials and Methods:* All CRC cases in patients aged <40 years old diagnosed on colorectal biopsies from January 2014 to July 2018 were included. Demographic data and tumour location were extracted from the clinical notes. The biopsies were reviewed and histopathological characteristics evaluated. *Results:* 10 of 162 colorectal biopsies positive for adenocarcinoma were from patients aged between 30-39 years (6.17%); 6 were female (60%), 8 were Malay, 1 Chinese and 1 of other ethnicity. Most were left-sided tumours (70%). On histopathological examination, one showed mucinous features; one was poorly-differentiated while the rest were moderately-differentiated CRC. *Conclusion:* The incidence of CRC in the 30-39 years age group in our institution was higher than the reported national figure for 2008-2013. Malay ethnicity was the most common, and left-sided tumours predominated, in keeping with local data. There were no specific histopathological features of CRC in colorectal biopsies taken from the young. Focus has to be given to identifying CRC in this population to address the increasing incidence.

P29. Pattern of histopathological changes seen in Methyl Nitrose Urea (MNU) induced breast cancer in female SD rats treated and non-treated with tualang (TH) and manuka honey (MH)

Urmila Banik^{1,2}, Sarfarz Ahamed³, Nor Hayati Othman¹

¹*Department of Pathology, School of Medical Sciences, Universiti Sains Malaysia, 16150 Kubang Kerian, Kelantan Malaysia;*

²*Unit of Pathology, AIMST University, Faculty of Medicine, Semeling, 08100 Bedong, Kedah, Malaysia;* ³*Department of Biochemistry, Bahauddin Zakariya University, Multan, Pakistan*

Introduction: Honey has been shown to have anticancer effects. We present the pattern of histopathological changes seen in MNU induced breast cancer animal model treated with TH and MH. *Materials and Methods:* MNU was injected intraperitoneally to Sprague-Dawley (SD) female rats 80 mg/kg body weight to induce breast cancer. Honey treatment by oral feeding started when first palpable tumour reached 10–12mm in size and continued till day 120th. Fifty nulliparous SD rats were used and grouped as follow: Group 0 (healthy normal control), Group 1 (negative control, untreated rats), Groups 2 and 3: 1g/kg body weight of TH and MH respectively. On day 120th, rats were sacrificed. Each cancer mass was fixed in neutral-buffered formalin, haematoxylin and eosin stained and examined under light microscope. For histological analysis, Russo and Russo guideline was followed and graded using modified Bloom and Richardson grading. *Results:* A total of 36 honey treated (20TH, 16MH) and 36 control (non-honey treated) tissue sections were examined. Morphologically, all cancer masses were of epithelial origin and diagnosed

as adenocarcinoma with single histologic type or combination of patterns. Cloudy swelling and vacuolar degeneration in the neoplastic cells along with microcystic change were seen in honey treated breast cancers compared to those did not receive honey treatment. The histological grades of the cancers were mainly of grade 1 and 2 compared to grade 3 in non-treated cases. *Conclusion:* The findings indicate that crude honey has cytotoxic effect towards the breast cancer cells and will help in histological interpretation of honey treated breast cancer data.

P30. Pericardial angiosarcoma: A rare entity

Poobalan Rama Chandran¹, Siti Shakinah Sobri¹, Pavitratha Puspanathan¹, Tan Yi Shan²

¹Department of Pathology, Hospital Sultanah Bahiyah (HSB); ²Department of Internal Medicine, Hospital Sultanah Bahiyah

Introduction: Primary pericardial angiosarcomas are rare tumour with poor prognosis. We present a post-mortem case with this entity. *Case Report:* A 41-year-old man presented with symptoms of cardiac failure, cardiac tamponade with thromboses of right internal jugular and brachiocephalic veins. Imaging showed thickening of the pericardium suspicious for tuberculous pericarditis. He was started on anti-tuberculosis medication. His symptoms persisted and MRI done showed thickening of the pericardium with a right atrium infiltrating mass, requiring a tumour to be excluded. He was planned to undergo open cardiac surgery to obtain a biopsy. However, he collapsed in the ward with sudden worsening dyspnea and pleuritic chest pain. Chest x-ray showed a massive right pleural effusion but patient passed away before further procedures could be done. A limited thoracic post-mortem was performed. *Pathological findings:* Post-mortem revealed an enlarged heart with diffuse thickening of pericardium. A haemorrhagic fleshy tumour within the pericardium and extending into the atrial myocardium was present. Massive right haemothorax with rupture of the atrial tumour was noted. Histologically, the tumour was composed of malignant spindle cells, positive for CD99, CD34, CD31, SMA and WT-1 (cytoplasmic). *Conclusion:* The cause of death was a massive right haemothorax secondary to ruptured pericardial angiosarcoma. It is a rare condition but may present with symptoms that mimic benign condition making it a challenging diagnosis.

P31. Pleomorphic liposarcoma of left arm: The rarest variant

Norhafizah Abdul Rahim^{1,2}, CT. Effa Faieyza Mohd Fisall¹, Sharifah Emilia Tuan Sharif^{2,3}

¹Department of Pathology, Hospital Raja (P) Zainab II, Kota Bharu, Kelantan, Malaysia; ²Department of Pathology, School of Medical Sciences, Healthy Campus, Universiti Sains Malaysia, Kelantan, Malaysia; ³Department of Pathology, Hospital Universiti Sains Malaysia, Kubang Kerian, Kelantan, Malaysia

Introduction: Pleomorphic Liposarcoma (PLS) is the rarest variant of liposarcoma defined morphologically by the presence of variable number of pleomorphic lipoblasts. It has the highest malignancy grade, with frequent invasion, metastasis, and recurrence. *Case Report:* We report a case of a 44-year-old gentleman presented with painless left arm swelling for 2 months, gradually increasing in size. Intraoperatively, the mass is attached to brachialis and lateral part of triceps muscle measuring 70x80mm. *Pathological findings:* Grossly, there are 2 fairly-circumscribed masses which appear multi-lobated brownish firm to yellowish cut surface measuring 50x19x30mm and 25x21x20mm respectively. Microscopically, the tumour cells exhibit features of high-grade pleomorphic sarcoma. Pleomorphic lipoblasts with extracellular and intracellular eosinophilic hyaline droplets are present. The tumour cells show focal positivity to S100 and negative to SMA, CD34, Desmin, Myogenin, EMA and Melan-A. The medial margin was involved by the tumour. *Conclusion:* PLS is a rare type of liposarcoma but is an aggressive sarcoma with high local recurrence and metastatic rate (30-50%). This patient had local recurrence due to margin involvement. Second operation was performed with histopathological involvement of proximal margin. Currently, there is no standardised treatment approach for PLS, with radical surgical resection is the mainstay treatment. Chemotherapy and radiotherapy treatment strategies remain controversial. Consequently, more studies are required to develop treatment and therapeutic strategies for PLS.

P32. Plexiform fibromyxoma: A rare benign gastric tumour

Connie Kabincong¹, Aznim Hani Ramlan¹, Nik Raihan Nik Mustapha²

¹Histopathology Unit, Department of Pathology, Hospital Umum Sarawak, Kuching, Sarawak, Malaysia; ²Histopathology Unit, Department of Pathology, Hospital Sultanah Bahiyah, Alor Setar, Kedah, Malaysia

Introduction: Plexiform fibromyxoma (PF) is a rare and fairly novel type of mesenchymal tumour with strong predilection for the antropyloric region of the stomach. We present a case with histological and immunohistochemical profiles that support the diagnosis of PF that was originally misdiagnosed as CD117-negative Gastrointestinal Stromal Tumour (GIST). *Case Report:* A 22-year-old lady presented with 1-year history of epigastric pain associated with anaemic symptoms. Oesophagogastrroduodenoscopy (OGDS) revealed a large submucosal mass at the antropyloric region. Laparoscopic wide local excision (WLE) was subsequently performed. *Pathological findings:* A solid whitish nodular mass within the gastric tissue measuring 55x35x43mm was identified. Microscopically, the mass is composed of loose spindled cells exhibiting nodular-plexiform growth pattern. These cells are regular with round to oval nuclei, indistinct cytoplasmic borders and some appear vacuolated. The stroma is loose and partly

myxoid-looking, with arborising capillaries seen throughout. No tumour necrosis or mitosis seen; Ki-67 proliferative index is low. Immunohistochemically, the tumour shows diffuse positivity towards smooth muscle actin (SMA) with patchy positivity for h-caldesmon, CD-10, CKAE1/AE3. The tumour is entirely negative for desmin, CD117, DOG-1, CD34 and S100 protein. Thus, diagnosis of PF is established. *Conclusion:* PF is a benign tumour with favourable prognosis and no recurrent tendencies. Thus, with early detection and lower risk intervention such as WLE can be done and often adequate. CD117, DOG-1, and CD34 negativity is the hallmark in the diagnosis of PF. Misdiagnosis with GIST may lead to inappropriate therapy. Therefore, it is imperative to consider PF in the differential diagnoses of benign gastric tumours with negative CD117 protein.

P33. Primary lung adenocarcinoma in an autistic boy: A rare occurrence

Mohd Fariz A^{1,5}, Suria Hayati MP¹, Hasniah AL², Hing EY³, Dayang Anita AA⁴, Hamidah A²

¹Department of Pathology; ²Department of Paediatric; ³Department of Radiology; ⁴Department of Surgery, Universiti Kebangsaan Malaysia Medical Centre, Kuala Lumpur, Malaysia; ⁵Department of Pathobiology and Medical Diagnostic, Universiti Malaysia Sabah, Malaysia

Introduction: Primary lung malignancy is uncommon in paediatric population. Most cases of primary lung adenocarcinoma developed after treatment of non-pulmonary malignancies. Lung masses in children are more likely to be benign or reactive lesion rather than malignant. *Case Report:* We report a case of primary lung adenocarcinoma in a 13-year-old autistic boy who initially presented with change of posture, right-sided chest pain associated with two-week history of cough and intermittent fever. An incidental finding of right pleural effusion was noted with a subsequent pleural fluid PCR analysis positive for tuberculosis, hence anti-tuberculosis treatment was given. After two weeks of anti-tuberculosis treatment, his right pleural effusion worsened. A CT thorax was then performed and showed right necrotising pneumonia with right empyema thoracis. He later underwent video-assisted thoracoscopic decortication and debridement surgery. Histopathological examination of the tissue surprisingly showed adenocarcinoma of the lung. Chemotherapy was started which resulted in 50% of reduction of tumour after the second cycle of chemotherapy. *Pathological findings:* The microscopic examination showed malignant glands infiltration within fibrocollagenous tissue with immunopositivity to TTF-1, CK7 and Napsin A, consistent with primary lung adenocarcinoma. The malignant cells were negative to ALK, PLAP and CD30. There was neither granuloma nor normal lung tissue present in the specimen. *Conclusion:* Primary lung malignancy is a very rare entity in children. Although unusually seen in childhood, pathologist and clinician should be aware of the possibility of primary lung malignancy as one of the differential diagnosis in a child with respiratory symptoms and unexplained pleural effusion.

P34. Proportion of male genital tract pathology: An observation over a 5-year period in Hospital Universiti Sains Malaysia

Zaleha Kamaludin, Farahlina Baba, Nik Fatin Amirah Nik Min, Azam Hilmi Mohd Zain, Nur Asyilla Che Jalil, Faezhtul Arbaeyah Hussain

Department of Pathology, School of Medical Sciences, Universiti Sains Malaysia Health Campus; Hospital Universiti Sains Malaysia, Kubang Kerian, Kelantan, Malaysia

Introduction: Male genital tract (MGT) pathology has a diverse entity, ranging from non-neoplastic to neoplastic, including benign, borderline and malignant tumours. The age of presentation differs according to the disorders. Prostate cancer is the most common MGT neoplasm according to the 2014 Malaysian National Cancer Registry (MNCR). The objective of the study is to determine the proportion of MGT pathology diagnosed in Hospital Universiti Sains Malaysia (HUSM) over a 5-year period. *Materials and Methods:* All histopathologically diagnosed MGT cases in the Department of Pathology, HUSM were included in the study. The data were retrieved from the department's Laboratory Information System database from January 2013 to July 2018. The cases were categorised into prostate, testis, paratesticular tissue and penis. Parameters included were the histopathological diagnosis, age, and ethnicity. Data was scrutinised to avoid duplicate entries and were analysed using SPSS 24.0. *Results:* 297 cases were identified. Overall neoplastic cases were 29.9% and 70.1% were non-neoplastic cases. The most common neoplastic disease was prostatic adenocarcinoma (24.6%) and non-neoplastic disease was benign prostatic hyperplasia (BPH) (67.3%). Median age group was 69 years old. Ethnicity involved were Malays (85.85%), Chinese (12.46%), Indian (0.34%) and others (1.35%). *Conclusion:* Prostate neoplasm was on the rise in HUSM Kelantan. The rapid rise was seen in the last 5 years, from 2013 (28%) to 2017(32.8%), which was associated with increased age. This data is similar with MNCR that reported an increase of 102 cases of prostate cancer from year 2007 to 2011, diagnosed in above 65 years of age.

P35. Sarcomatoid carcinoma of small intestine: A case report

Nurwahyuna Rosli¹, Nordashima Abd Shukor¹, Izzatul Aini Mohamad Idris², Erica Wong Yee Hing²

¹Department of Pathology, Universiti Kebangsaan Malaysia Medical Centre; ²Department of Radiology, Universiti Kebangsaan Malaysia Medical Centre

Introduction: Sarcomatoid carcinoma of the small intestine is a rare malignant neoplasm possesses both epithelial and mesenchymal differentiation. The tumour usually manifests in the sixth decade of life and carries a poor prognosis. *Case Report:* Here we report a case of a 68-year-old man with sarcomatoid carcinoma of small intestine who presented with anaemia and features of small bowel obstruction. Abdominal CT scan was performed and revealed a circumferential mass involving the ileum. He underwent surgical resection of the mass. *Pathological findings:* Histopathology examination showed a fungating tumour composed of mixed spindle and epithelioid cells with extensive areas of necrosis. It involved the entire wall of the small intestine and directly invaded the adjacent sigmoid colon. The final diagnosis of sarcomatoid carcinoma was concurred based on tumour morphology supported by wide range of immunohistochemical studies showing tumour positivity towards both epithelial and mesenchymal markers. *Conclusion:* The diagnosis of sarcomatoid carcinoma can be challenging and immunohistochemical studies are crucial for a definitive diagnosis. In view of poor response to chemotherapy and radiotherapy, a complete surgical removal with close follow-up is recommended.

**P36. Sporadic malignant peripheral nerve sheath tumour in a 3-year-old girl: A diagnostic challenge**

Nurulhasanah Mustapar¹, Ismaliza Ismail³, Wan Azman Wan Sulaiman³, Wan Faisham Nu'man Wan Ismail², Sharifah Emilia Tuan Sharif¹

¹Department of Pathology; ²Department of Orthopaedic; ³Department of Plastic and Reconstructive Science, Hospital Universiti Sains Malaysia, Health Campus, Kelantan, Malaysia

Introduction: Malignant peripheral nerve sheath tumour (MPNST) is an uncommon malignant neoplasm of childhood with unfavourable prognosis. Only 1.7% of the cases have been reported in children less than five years of age and approximately one-half arise from a benign peripheral nerve sheath tumour especially in background of neurofibromatosis type 1 (NF1). Primary MPNST in children are even rarer. *Case Report:* A 3-year-old Malay girl presented with painful right axillary swelling for 6 months duration, initially treated as axillary lymphadenitis and she defaulted follow up. She came back 4 months later with enlargement of the swelling. The biopsy was reported as Schwannoma which correlates with MRI findings of benign peripheral nerve sheath tumour. Final diagnosis after debulking surgery was consistent with MPNST. She succumbed to death 20 months after her initial diagnosis of advanced MPNST and lung metastasis. *Pathological findings:* Grossly, a huge partly-circumscribed soft tissue mass noted arising from a nerve with solid greyish yellowish myxoid cut surface. Spindle shaped cells arranged in herringbone pattern with marked pleomorphism, brisk mitosis and extensive necrosis are seen microscopically. Immunohistochemistry shows patchy S100 protein staining with loss of expression of H3K27 trimethylation. *Conclusion:* Although MPNST is rare in paediatric age group, diagnosis should be considered in children without NF1 with rapidly evolving and painful mass in the distribution of a peripheral nerve. In this case, the diagnosis was delayed and made after surgery. Due to its morphologic heterogeneity and lack of specific immunohistochemical markers, MPNST remains a diagnostic challenge.

P37. Stromal expression of CD10 in invasive breast carcinoma and its association with tumour stage, grade, ER, PR and HER-2 status

Nurul Akmal Kamarudin¹, Wirda Indah Farouk¹, Noor Azlin Muhammad Hanapi¹, Fazarina Mohammed¹

¹Department of Pathology, Universiti Kebangsaan Malaysia Medical Centre, Universiti Kebangsaan Malaysia, Kuala Lumpur, Malaysia

Introduction: Invasive breast cancer is a heterogeneous disease. Recent updates addressed the role of tumour microenvironment (TME) in cancer development, progression and responses to treatment. Studies have shown CD10 expressed in cancer-associated fibroblasts (CAF) within TME had been associated with aggressive biological behaviour and poor prognosis. The aim of this study is to evaluate stromal CD10 expression in invasive breast cancer and its correlation with tumour stage, grade, Estrogen Receptor (ER), Progesterone Receptor (PR) and HER2-neu status. *Materials and Methods:* A total of 226 invasive breast carcinoma cases from January 2014 to January 2016 were selected and assembled into tissue microarrays (TMAs). The stromal expression of CD10 was immunohistochemically analysed. *Results:* CD10 was positive in 67 (29.6%) cases of invasive breast carcinoma. The frequency of positive stromal staining was significantly higher in the cases with ER negative ($P=0.000$). However, there were no correlations between stromal CD10 expression with tumour grade, stage, PR and HER2-neu status. *Conclusion:* CD10 expression correlates with well-established negative prognostic markers, that is ER, thus constitutes a potential prognostic marker and therapeutic target. However, future studies are necessary to evaluate other stromal markers within the TME immunohistochemically as well as its molecular basis in order to confirm the specific role of CD10.

P38. T-cell Non-Hodgkin Lymphoma: A single centre experience in the east coast of Peninsular MalaysiaNasrun Hasenan^{1,2}, Faezahtul Arbaeyah Hussain^{1,2}¹Department of Pathology, School of Medical Sciences, Universiti Sains Malaysia, Health Campus, Kelantan, Malaysia; ²Hospital Universiti Sains Malaysia, Kubang Kerian, Kelantan, Malaysia

Introduction: T-cell NHL is a heterogeneous group of lymphoma, an uncommon lymphoid malignancy but regarded as more frequent in Asian population. The diagnosis remains a big challenge as their presentations are often atypical and in general, associated with poor clinical outcome. The aim of this study is to ascertain the frequency, distribution pattern and histological type of T-cell NHL among patients diagnosed in Hospital Universiti Sains Malaysia (USM) and to compare our findings with reports in the literature. **Materials and Methods:** This retrospective study was conducted at Department of Pathology, USM, Kubang Kerian, Kelantan. Fifty-two cases of T-cell NHL were retrieved from the Laboratory Information System database over a period of 15 years, from 2001 to 2016. **Results:** Within 52 cases of T-cell NHL, majority were diagnosed as peripheral T-cell lymphoma (n=20,39%); followed by anaplastic large cell lymphoma (n=19,37%), T-lymphoblastic lymphoma (n=5,10%), angioimmunoblastic lymphoma (n=4,8%), subcutaneous panniculitis-like (n=2,4%), intestinal T-cell lymphoma (n=1,0.02%) and extranodal NK/T-cell lymphoma, nasal type (n=1,0.02%). More than half of the patients were males (n=33,63%) as compared to females (n=19,37%). The most common primary sites of presentation were extranodal accounting for 28 cases (53.8%) followed by nodal which comprised 24 cases (46.2%). Soft tissue and bone were the most common sites among the extranodal T-cell lymphoma followed by nasopharynx, gastrointestinal tract and mediastinum. **Conclusion:** Despite the rarity of this disease, the frequency of T-cell NHL diagnosed in Hospital USM is similar with previous nationwide studies particularly in Asian countries.

P39. The use of PDLIM (LMP1 analogue) as a substitute for EBER in diagnosing extranodal NK/T-cell lymphoma nasal typeMaryam Ahmad Sharifuddin^{1,2}, Faezahtul Arbaeyah Hussain^{1,2}¹Department of Pathology, School of Medical Sciences, Universiti Sains Malaysia, Health Campus, Kubang Kerian, Kelantan; ²Hospital Universiti Sains Malaysia, Kubang Kerian, Kelantan, Malaysia

Introduction: Extranodal NK/T-cell lymphoma, nasal type (ENKTL) is an aggressive extranodal lymphoma which is common among Asians. There is a very strong association with Epstein Barr Virus (EBV), requiring EBV markers like EBER or LMP1 for the diagnosis. In cases of CD56 or CD3 negative, ENKTL cannot be excluded when the cytomorphology features inclined towards the diagnosis. Hence, it is important to include EBV marker as one of the diagnostic tools. **Case Report:** A 64-year-old male with one-month history of left facial numbness and left nasal block with discharge. Physical examination revealed an ill-defined induration over left cheek, numbness over cranial nerve Va and b and two painless lymph nodes at Level II and V. An irregular fleshy mass arising from osteomeatal complex was noted on rhinoscope. MRI showed an expansile heterogeneous enhancing mass occupying the whole left maxillary sinus with bony erosion and extension to the surrounding structures. **Pathological Findings:** Macroscopically, two fragments of tissue measuring 6x4x2mm and 3mm. Microscopically, diffuse lymphomatous infiltrates with angiocentric growth pattern composed of pleomorphic medium-sized cells having irregular nuclei with granular chromatin, small nucleoli and moderate amount of pale cytoplasm were seen. These cells were CD3+ (weak), perforin+, EBV PDLIM+, high Ki67 > 50%, CD20-, CD56- and CKAE1&AE3-. **Conclusion:** In a centre where EBER is unavailable due to budget constraint, it is reasonable to have an alternative EBV marker that is useful in cases of highly suspicious of ENKTL. Even though literatures have reported a low sensitivity of these markers compared to EBER, having one is better than none.

P40. The utility of fluorescence in situ hybridisation (FISH) in synovial sarcoma – The pitfallsNoraziah Salehan¹, Sharifah Emilia Tuan Syarif¹, Norasikin Nafi¹, and Aidy Irman Yajid¹.¹Department of Pathology, School of Medical Sciences, University Science Malaysia Health Campus, Kelantan, Malaysia

Introduction: The introduction of molecular and cytogenetic studies have supplemented histology and immunohistochemistry test. Molecular study gives better understanding of biology of Synovial sarcoma (SS). The translocation (X;18)(p11.2;q11.2) is the cytogenetic hallmark of SS. This molecular identity is the useful marker to differentiate SS from its histological mimics. **Materials and Methods:** We conducted a cross sectional study using 27 archived formalin-fixed paraffin embedded tissue blocks of SS cases, which were diagnosed in HUSM, Kelantan from year 1999 to July 2017. Histology assessment was performed to identify SS morphology subtypes. FISH was performed on the paraffin embedded tissue sections using break apart SYT probe, which were hybridised to the target breakpoint gene. Troubleshooting FISH was carried out in obtaining positive t(X;18) signals. **Results:** None of Synovial sarcoma cases performed in HUSM showed signal detection. Cases were carried to a molecular centre in HUKM for troubleshooting. This study found that there are several pitfalls and various factors that lead to failure of signal detection done in HUSM such as inherent technical difficulties, tissue factor (aging tissue), improper tissue fixation, pre-treatment method instability, unsuitable pre-treatment solutions, inadequate training, experience and laboratory facilities. **Conclusion:** FISH is used as a supplementary test and not as a routine test in most of the centres. In order to perform a successful FISH, we have to determine its pitfalls and find the solutions. Although FISH is the gold standard in SS, morphology features and immunohistochemistry profiles of SS, in the hands of an experienced pathologist, is still considered to be the most important aspect when dealing with difficult cases.

P41. Tissue optimisation for molecular testing in lung carcinoma

Nor Salmah Bakar¹, Mardiana Abdul Aziz¹, Ruzi Hamimi², Rose Adzriane², Noor Kaslina Mohd Kornain¹

¹Anatomic Pathology Unit, Department of Pathology, Faculty of Medicine, Universiti Teknologi MARA, Sg Buloh, Selangor;
²Molecular Unit, Department of Pathology, Faculty of Medicine, Universiti Teknologi MARA, Sg Buloh, Selangor

Introduction: Lung carcinoma is the most common type of cancer worldwide and the leading cause of cancer death. The diagnosis of lung carcinoma is confirmed by histopathological examination (HPE) of the tumour biopsy. The same tissue is often subjected to molecular testing, which guides subsequent treatment and prognosis. As amount of tissue is limited, optimisation of the tissue sample is important to ensure its adequacy. This study was conducted to examine the i) adequacy of biopsy diagnostic material for molecular testing and ii) histopathological type of lung carcinoma in relation to the molecular test results. *Materials and Methods:* All lung carcinoma cases in our laboratory that were sent for EGFR molecular testing in 2016 and 2017 were included. HPE diagnosis was confirmed by slide review. Multiple sections of the biopsy were prepared as follows; Level-1 HE, 2-unstained polyL, Level-2 HE, 2-unstained polyL, 6-unstained EGFR, and Level-3 HE. The EGFR results against histopathologic tumour type were analysed. *Results:* 38 cases were included. All were adequate for histology diagnosis. Thirty-seven cases (97%) were adequate for EGFR molecular testing with 14(38%) showing mutation. HPE-EGFR result correlation as follows: adenocarcinoma (n=12) =exon 19 deletion (n=11); exon 21 L858R mutation (n=1), non-small cell lung carcinoma (NSCLC)-favour-adenocarcinoma (n=1) =exon 20 insertion, and NSCLC-NOS (n=1) =exon 21 L858R mutation. The smallest biopsy was 2mm in size. *Conclusion:* Tissue optimisation improves specific diagnosis and ensures adequate tissue for molecular testing. There is specific correlation between histology type and EGFR mutations however comprehensive study of larger sample size is recommended.



SPORADIC MALIGNANT PERIPHERAL NERVE SHEATH TUMOR IN A 3 YEAR OLD GIRL; A DIAGNOSTIC CHALLENGE



Nurulhasanah Mustapar¹, Ismaliza Ismail³, Wan Azman Wan Sulaiman³, Wan Faisham Nu'man Wan Ismail², Sharifah Emilia Tuan Sharif¹

¹Department of Pathology, School of Medical Sciences, Hospital Universiti Sains Malaysia, Kubang Kerian, 16150 Kota Bharu, Kelantan, Malaysia

²Department of Orthopaedic, School of Medical Sciences, Hospital Universiti Sains Malaysia, Kubang Kerian, 16150 Kota Bharu, Kelantan, Malaysia

³Department of Plastic and Reconstructive Science, School of Medical Sciences, Hospital Universiti Sains Malaysia, Kubang Kerian, 16150 Kota Bharu, Kelantan, Malaysia

Introduction

Malignant peripheral nerve sheath tumour (MPNST) is particularly rare with an incidence of 0.001% in the general population. It is a very rare spindle cell sarcoma in children accounting for approximately 5–10% of non-rhabdomyosarcoma soft tissue sarcomas. Depending on its location and amount of nerve involvement, MPNST can present as a painful or painless mass. The tumour is usually found in lower extremities and MPNSTs located in the trunk and extremities are usually high grade and clinically aggressive with poor prognosis. Most MPNSTs are thought to arise by malignant transformation of neurofibromas, occurs in about 2% of NF1 patients which is frequently reported. Primary MPNST in children are even rarer. Malignant transformation of schwannomas; in contrast is an exceedingly rare occurrence, with no hereditary predisposition. In this report we highlighted such cases. Here we report a case of a rare paediatric malignant peripheral nerve sheath tumour in a 3-year-old female patient with no background history of neurofibromatosis type-1. The diagnostic challenges of this rare tumour are discussed.

Clinical case

In this report we present a case of a 3 year-old Malay girl presented with painful right axillary swelling for 6 months duration. Initially treated as axillary lymphadenitis. However she defaulted follow up. She came back 4 months later with enlargement of the swelling. The initial biopsy was reported as Schwannoma which tally with the MRI findings of benign peripheral nerve sheath tumor. Final diagnosis after debulking surgery consistent with MPNST. She succumbed to death 20 months after her initial diagnosis with advanced MPNST and lung metastasis.

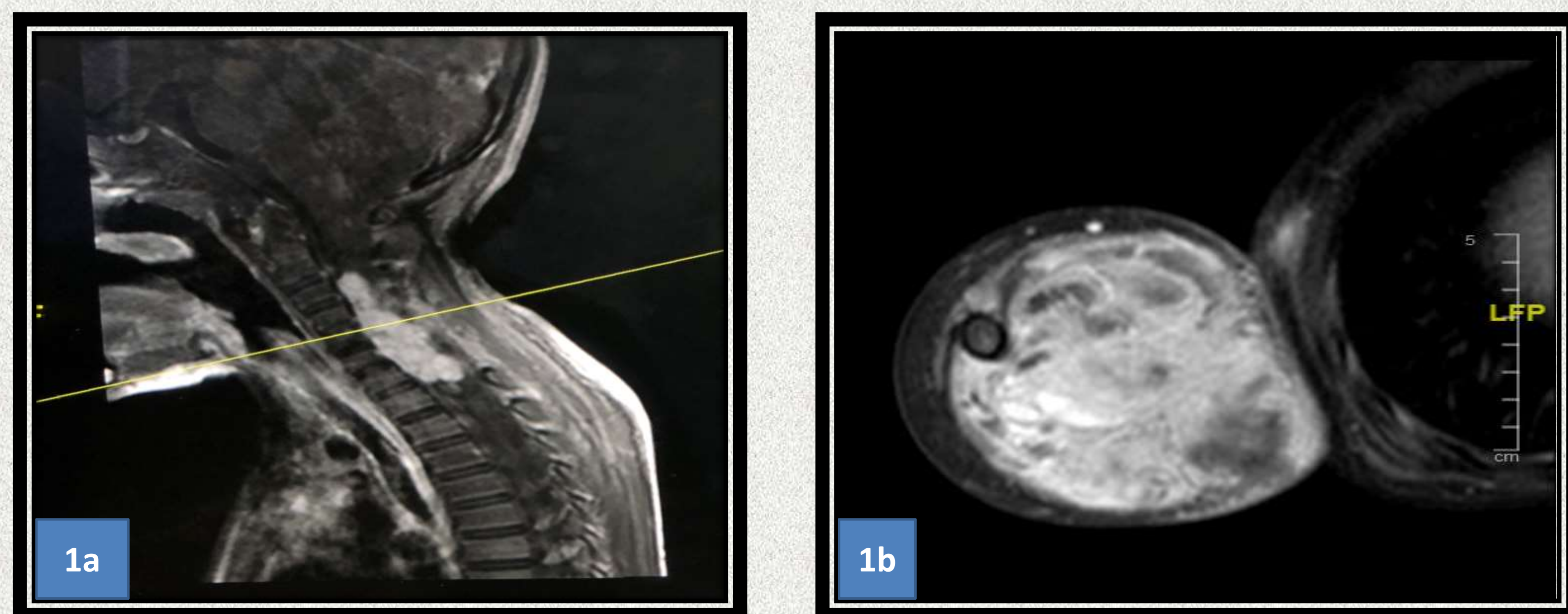


Figure 1a: MRI show intradural extramedullary mass at the right cervical region from the level of C4 to the C8 which appear cystic, heterogeneously hypointense on T1 and hyperintense on T2 and features suggestive of benign peripheral nerve sheath tumor. **Figure 1b:** MRI show a large intermuscular capsulated mass at the right medial side of proximal arm causing splaying and compression of the surrounding muscle and this lesion appear solid with cystic component and reported as malignant schwannoma. (Source: USM PACS, GE Healthcare zero foot-print viewer)

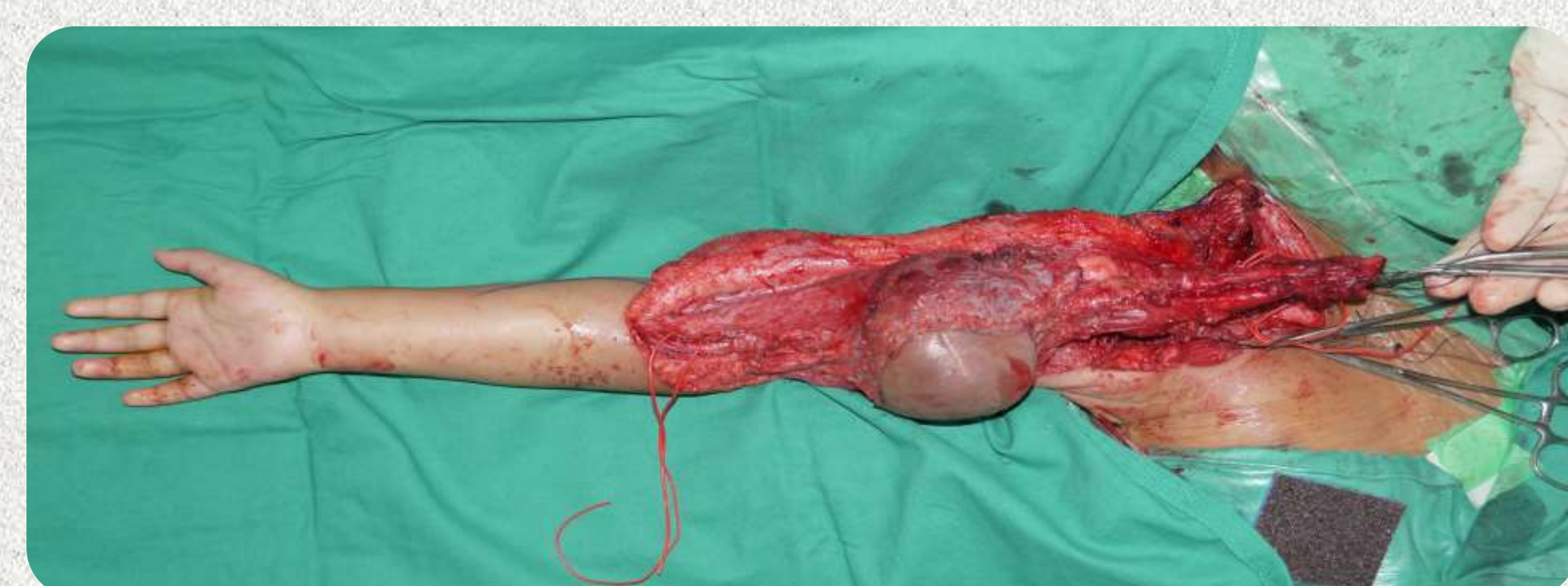


Figure 2: Intraoperative findings of tumour exhibit a right arm mass with surrounding tissue and overlying skin. The mass is seen eccentrically located from the site of nerve.

Pathological findings

Grossly, a huge partly circumscribed soft tissue mass noted arising from the site of a nerve with solid greyish yellowish myxoid cut surfaces. Microscopically displayed spindle shaped cells arranged in hypercellular and hypocellular areas. The hypercellular areas predominantly exhibited fascicular and herring-bone pattern with moderate to severe pleomorphism, brisk mitosis and extensive necrosis. Immunohistochemistry show patchy S-100 protein staining with loss of expression of H3K27 trimethylation.

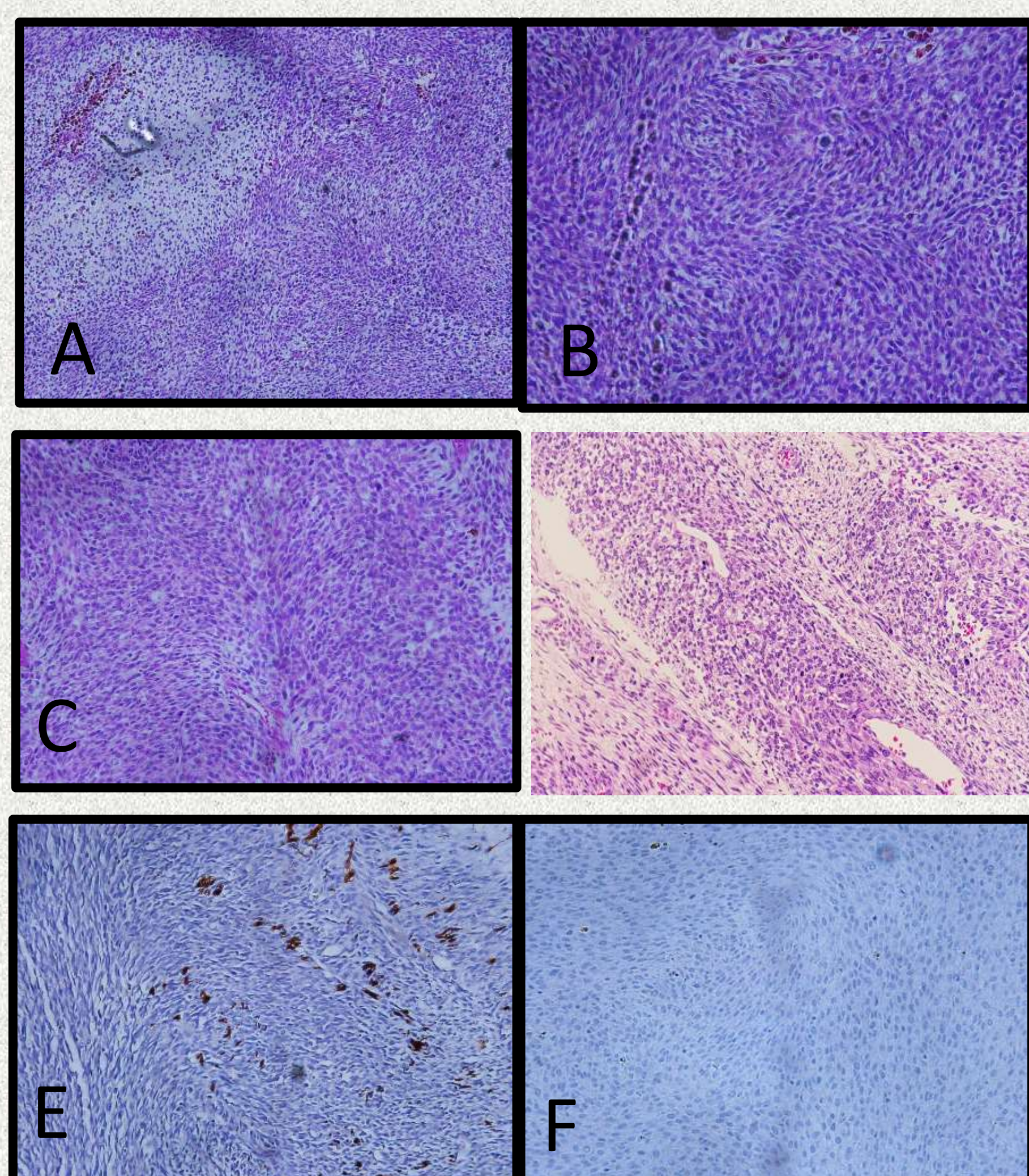


Figure 3: (A) Tumour mass showing malignant spindle shaped cells arranged in hypercellular areas and loose area (H&E 100x). (B) In areas, malignant cells haphazardly arranged in vague storiform pattern (H&E 200x). (C) Herring-bone pattern is also seen (H&E 200x). The cells show moderate to markedly pleomorphism some with conspicuous nucleolus (D) Perivascular accentuation can be identified (H&E 400x). Mitoses are brisk. (E) The tumor cells show only focal immunoreactivity towards S-100 protein (200x). H3K27 trimethylation immunohistochemistry exhibits loss of expression (200x).

Discussion

With its diversity of histologic appearances, overlapping pattern, the rarity of these tumour, and lacking of highly sensitive and specific immunohistochemical antibodies for MPNST, all these may justify to the delay in diagnosis. Diagnosis may be delayed since this type of tumours is either asymptomatic or may cause minimal discomfort. Many patients reported pain and neurological deficits at the time of presentation. Diagnosis of MPNST in this age group took longer compared to adults. This slow enlarging mass exhibits rapid growth and two thirds of the lesions are more than 5cm at the time of diagnosis. Our patient illustrated the potential for these malignancies to present late due to their minimal propensity to produce symptoms and no background history of NF1.

Radiological diagnosis of this tumour is rather challenging. Concerning imaging investigations, our patient was evaluated with MRI scan. Radiographically the MRI findings in comparison with previous study performed 4 months prior to initial biopsy, this lesion at the right upper arm significantly increased in size with more necrotic and haemorrhage within and encasing the vessel. Imaging investigations are important but are not reliable to detect a malignant transformation. Significant differences between malignant peripheral nerve sheath tumors and benign peripheral nerve sheath tumour were noted for the largest dimension of the mass, peripheral enhancement pattern, perilesional edema like zone, and intratumoral cystic lesion e.g. haemorrhage or necrosis [5]. If a tumor has two or more of the four statistically significant features, it can be considered to be highly suspicious of malignancy and should be subjected to a biopsy for early diagnosis. The presence of two or more of the four features suggestive of malignancy indicated malignant peripheral nerve sheath tumor with a sensitivity of 61% and a specificity of 90% [4].

The definitive diagnosis of MPNST is histopathology. But morphologic heterogeneity in MPNST especially in the low grade lesion or ambiguous lesions between benign and low grade lesion and lack of specific immunohistochemistry, histologic diagnosis in this type of lesion would be difficult. H3K27 trimethylation (H3K27me3) marker may have a role in the diagnosis of MPNST. In one study, loss of H3K27me3 was found in 34% of malignant peripheral nerve sheath tumour compared with intact H3K27 tri-methylation in all benign peripheral nerve sheath tumour []. Distinguishing Schwannoma from MPNST is important because schwannoma has a benign course with rare malignant transformation. (Table 1).

	Schwannoma	MPNST
Microscopy findings	Typical Schwannoma has two different cell patterns. Antoni type A: like pattern with spindle cells in a palisade formation, surrounded by an interstitial substance that forms verocay bodies. Antoni type B: like pattern with irregular cells and a myxoid component. The presence of verocay bodies is pathognomic of schwannoma. ** Although Antoni A and B arrangements are commonly described in benign schwannoma, usually problem arises when we are dealing with cellular schwannoma where antoni A is predominant and lacking antoni B and verocay bodies.	The histologic features of MPNSTs show considerable variation. Several features that favours the histological diagnosis includes: <ul style="list-style-type: none"> • perivascular hypercellularity, • Pleomorphic and hyperchromatic wavy nuclei • high mitotic activity, • geographical necrosis. **Cellular schwannoma may mimic MPNST by showing high cell density, elevated mitotic activity, and may have focal necrosis.
Ancillary tests:		
• S-100 protein	Diffuse immunoreactivity for S-100 protein	Focal immunoreactivity is seen in MPNST.
• H3K27 me3	Diffuse strong immunoreactivity towards H3K27 trimethylation	Loss of immunoreactivity towards H3K27 trimethylation

Table 1: Features to distinguish between benign and malignant peripheral nerve sheath tumour.

Most MPNSTs are aggressive, high grade sarcomas with a high likelihood of local recurrence (40% to 65%), and distant metastases (40% to 68%). They frequently metastasize to the lungs followed by bone whereas lymph node metastases are uncommon. Other sites of metastasis include liver, brain, soft tissue, skin, and retroperitoneum. MPNSTs have poor outcome if untreated. These tumours are relatively resistant to chemotherapy and radiation therapy and, therefore, complete surgical excision continues to be the gold standard for treatment. Early radical surgical resection, when feasible, is the treatment of choice. Our case was treated by wide surgical excision or tumour debulking surgery and adjuvant chemotherapy. Unfortunately, Our patient developed lung metastases and succumbed to death 20 months after diagnosis with advanced MPNST.

Conclusion

Although MPNST is rare in the paediatric age group, diagnosis should be considered in children without NF1 with a rapidly evolving and painful mass in the distribution of a peripheral nerve. In this case, the diagnosis was delayed and made after surgery. Due to its morphologic heterogeneity, lack of specific immunohistochemical markers and because of sampling errors, MPNST remains a diagnostic challenge. The role of chemotherapy is unclear. Early diagnosis and referral to multidisciplinary team are important in ensuring the best diagnosis and optimal therapy in this young age.

References

1. Woodruff JM, Selig AM, Crowley K, Allen PW. Schwannoma (neurilemmoma) with malignant transformation—a rare distinctive peripheral nerve tumour. *Am. J. Surg. Pathol.* 1994; **18**: 882–895.
2. Prieto-Granada, C. N., T. Wiesner, J. L. Messina, A. A. Jungbluth, P. Chi and C. R. Antonescu (2016). "Loss of H3K27me3 Expression Is a Highly Sensitive Marker for Sporadic and Radiation-induced MPNST." *Am J Surg Pathol* **40**(4): 479-489.
3. Schaefer, I. M., C. D. Fletcher and J. L. Hornick (2016). "Loss of H3K27 trimethylation distinguishes malignant peripheral nerve sheath tumors from histologic mimics." (1530-0285 (Electronic)).
4. Wasa et al. MRI of Peripheral Nerve Sheath Tumors and Neurofibromas. *AJR*:194, June 2010
5. M.A. SInll et al. : MR appearance of peripheral nerve sheath tumors. *Skeletal Radiol* (1991) 20:9-14.
6. Nayler, S. J., Leiman, G., Omar, T. and Cooper, K. Malignant transformation in a schwannoma. *Histopathology* 1996, **29**, 189–192.



CERTIFICATE OF APPRECIATION

This certificate is awarded to

NURULHASANAH BINTI MUSTAPAR

.....

POSTER PRESENTATION

**5th INTERNATIONAL ACADEMY OF
PATHOLOGY MALAYSIAN DIVISION
(IAPMD)**

ANNUAL SCIENTIFIC MEETING

On 27th -28th October 2018

At Shangri-La's Tanjung Aru Resort & Spa,
Kota Kinabalu, Sabah, Malaysia.

**INTERNATIONAL
ACADEMY OF
PATHOLOGY MALAYSIAN
DIVISION (IAPMD)
ANNUAL SCIENTIFIC
MEETING**

**THEME:
MEDIASTINAL AND
BREAST PATHOLOGY**

Prof. Dr Nor Hayati Othman
President, International Academy
of Pathology Malaysian Division

Dr Ahmad Toha Smasudin
Chairman, 5th International Academy
of Pathology Malaysian Division,
Annual Scientific Meeting