



# RAMBUTAN RELATED OCULAR TRAUMA

Muhd Yusuf A Rahman , Abdul Hadi Rosli, Khairidzan Mohd Kamal  
Department of Ophthalmology, Kulliyah of Medicine, International Islamic University  
Malaysia



## INTRODUCTION

- Rambutan (scientific name = *Nephelium lappaceum* L) is a famous tropical fruit in the Southeast Asia region. It is widely grown in Malaysia and Indonesia [1]. Although the fruit is small, its physical characteristics of wooden stalks and sphinterns make it prone to ocular trauma if it falls on the eyes. Ocular trauma with vegetative material like Rambutan also has a significant association with the development of fungal keratitis [6]. We report a case of deeply embedded cornea wooden-foreign body and fungal keratitis following ocular trauma by rambutan fruit.

## CASE REPORT

A 61-year-old gentleman with underlying hypertension was referred for right eye ocular trauma following being hit by a Rambutan fruit at home. He was looking up while harvesting a sprig of Rambutan fruits under the tree when suddenly, one of the fruits directly fell over his right eye. He did not use any ocular protection equipment during the trauma. Post-trauma, he developed right eye pain with foreign body sensation. He also had reduced vision and tearing over the right eye. During the examination, the patient was alert and conscious. Hemodynamically he was stable. The visual acuity of the right eye was 6/15 and 6/6 in the left eye. There was no evidence of injury over the periorbital region and eyelids. Examination of the right eye showed diffusely injected conjunctiva. However, no entry wound was seen. There was a deeply embedded elongated woody-like cornea foreign body measuring about 0.5mm length, at the paracentral region, 6 o'clock nearing involves the visual axis (Figure 1). It was deep embedded up to the posterior stroma layer and impinging to the Descemet membrane, causing circumferential striae surrounding the inner edge of the foreign body (Figure 2). There were another two smaller foreign bodies at paracentral 5 and 9 o'clock but away from the visual axis. The seidel test was negative. The anterior chamber was well formed with minimal reaction seen. There was no hyphaema, pupillary sphincter tear and lens capsule breach seen. Fundus examination of the right eye showed normal findings. Examination of the anterior and posterior segment of the left eye showed normal findings.

## DISCUSSION

Rambutan (*Nephelium lappaceum* L) is widely found in warm, humid and high rainfall regions such as Malaysia, Indonesia and Thailand [1,2]. It is covered with soft spine with spinterns and usually grows in a group of sprigs, connected by a wooden stalk [1,2]. Even though it is a small fruit, due to its physical characteristics, it may inflict ocular trauma when it accidentally hit the eyes while harvesting from the trees. There was also the presence of endophytic bacteria in the rambutan fruit including *Corynebacterium*, *Bacillus*, *Chryseobacterium*, *Staphylococcus* and *Curtobacterium* [3]. Besides that, farmers are rarely using ocular protection equipment during harvesting the rambutan. This is likely due to the equipment being not readily available and a lack of eye safety awareness. Due to all these factors, rambutan tends to cause serious injuries and infections to the eyes. There was no other rambutan-related ocular trauma case reported in the literature, likely due to underreporting. Treatment of ocular trauma depends on the location and severity of the injury. The location and severity of the ocular injury need to be assessed carefully as it will determine further management [4]. Initial visual acuity and severity of the ocular injury were found to be significantly associated with the visual outcome. Initial visual acuity better than 6/60 was found to have the better visual outcome and open globe injuries showed worse or no improvement in visual outcome [4]. The incidence of fungal keratitis is increasingly in trend in developing countries. This is facilitated by vegetative-related trauma in agricultural activities [5,6]. The incidence of fungal keratitis is about 17-44%. *Fusarium* species are the most causative organisms, followed by *Aspergillus* and *Candida* species [6]. Most of the fungal keratitis is treated with combination therapy such as Topical Amphotericin B and Topical Fluconazole with oral Fluconazole added in severe cases. Other modalities of treatment include intrastromal Amphotericin B which is usually prescribed in severe cases who do not respond to initial treatment [5,6].

## CONCLUSION

Ocular injury awareness campaign needs to be stepped up especially in the remote areas where rambutan trees are widely grown. The uses of goggles or face shields are the most efficient method of ocular protection during harvesting the rambutan.

## REFERENCE

- Chai KF, Adzahan NM, Karim R, Rukayadi Y, Ghazali HM. Selected Physicochemical Properties of Registered Clones and Wild Type Rambutan (*Nephelium lappaceum* L.) Fruits and Their Potential in Food Product. *Sains Malays*. 2018; 47(7): 1483-1490 <http://dx.doi.org/10.17576/jsm-2018-4707-16>
- Rohman A. Physico-chemical Properties and Biological Activities of Rambutan (*Nephelium lappaceum* L.) Fruit. *Res. J. of Phytochem*. 2017; 11(2): 66-73 DOI: 10.3923/rjphyto.2017.66.73
- Suhandono S, Kusumawardhani MK, Aditiawati P. Isolation and Molecular Identification of Endophytic Bacteria From Rambutan Fruits (*Nephelium lappaceum* L.) Cultivar Binjai. *HAYATI J Biosci*. 2016; 1-6 <http://dx.doi.org/10.1016/j.hjb.2016.01.005>
- Thevi T, Reddy SC. Review of Ocular Injuries in Malaysia. *Malaysian J. Public Health Med*. 2017; Vol 17 (1): 69-77
- Chitamparam S, Lim TH, Tai E, Ibrahim M. Mycotic Keratitis in a Tertiary Hospital in Northeastern Malaysia. *Turk J Ophthalmol*. 2020; 50: 332-338 DOI: 10.4274/tjo.galenos.2020.57609
- Tabatabaee A, Mohajernezhadfar Z, Daneshgar F, Mansouri M. Keratomycosis After Incidental Spillage of Vegetative Material Into the Eye: Report of two cases. *Oman J Ophthalmol*. 2013; 6(2): 122-126 DOI: 10.4103/0974-620X.116659

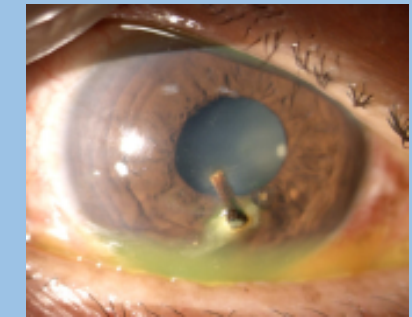


Figure 1: Picture showing deeply embedded cornea foreign body

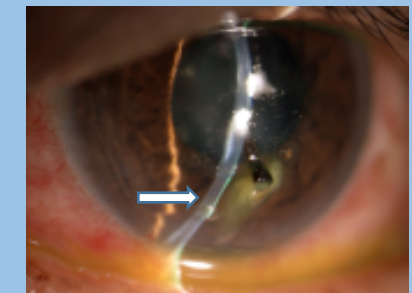


Figure 2: Picture showing the foreign body impinge to the Descemet membrane cause circumferential striation (arrow)

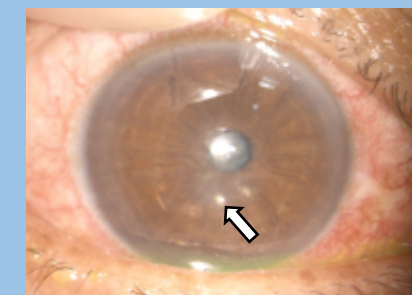


Figure 3: Picture showing cornea infiltrates at 6 and 5 clock hours (arrow)

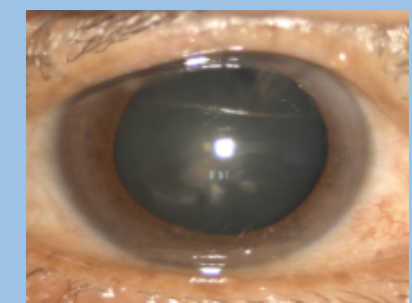


Figure 4: Picture showing complete resolution of cornea infiltrates with scarring