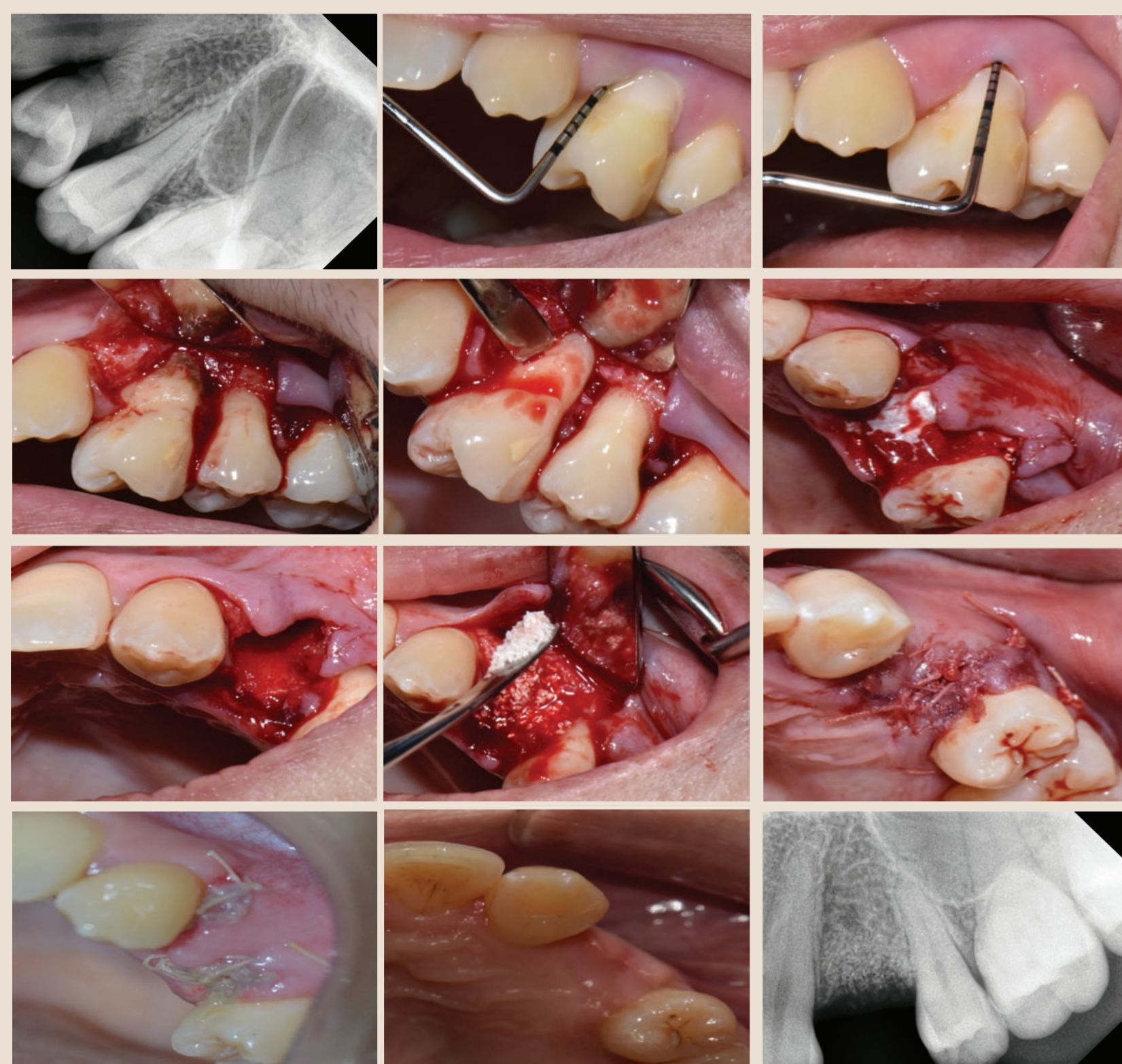

SOCKET PRESERVATION, A RIDGE PRESERVATION TECHNIQUE AS ONE OF THE MANAGEMENT OF IMPLANT SUPPORTED PROSTHESIS: A CASE SERIES

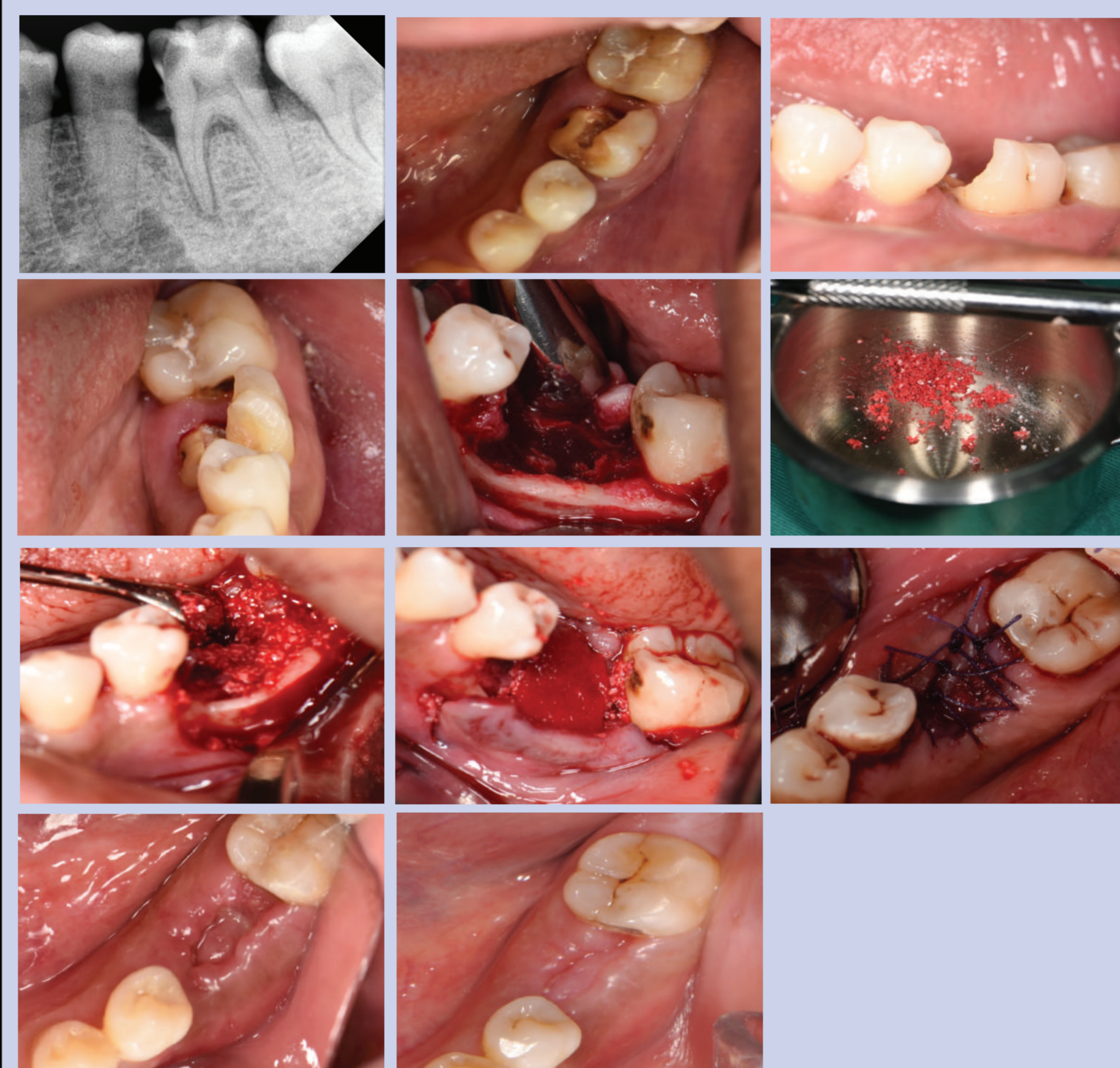
N.Q Salehuddin¹, N.A Mohamed Yusof¹, N.Z Mohd Noh¹ & E Noor¹
¹Faculty of Dentistry, University Teknologi MARA (UiTM),
 Sungai Buloh, Selangor, Malaysia

CASE 1: COMPLICATED CROWN ROOT FRACTURE



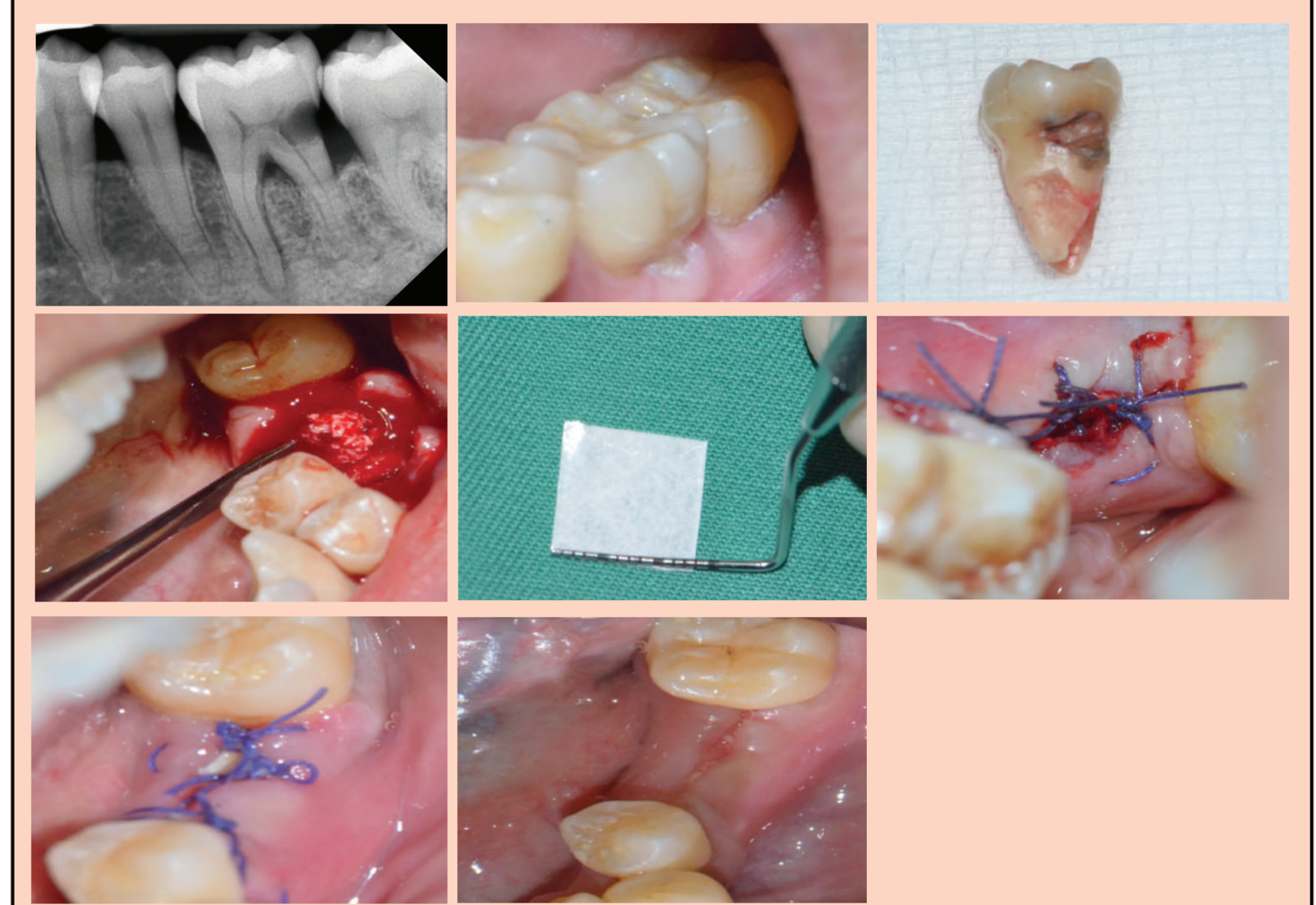
- A 36 years old lady presented with localized mesiobuccal probing pocket depth of 8mm on tooth 24.
- It was decided then to proceed with exploration surgery.
- Therefore, an intrasulcular incision was made on the buccal and palatal aspect with vertical releasing incision on the buccal aspect.
- A full thickness flap was raised and curettage was done on the inner surface of the flap to remove the chronic inflammatory tissues.
- Vertical crack line was noted with presence of calculus on the middle third of the buccal root surface of 24.
- Briefly, atraumatic extraction was done by using periosteal elevator and extraction forceps on 24.
- Socket was curettaged and debrided.
- Bone particles was placed at extraction socket.
- Lastly, resorbable membrane was packed and flap was fully closed and sutured with Laurel technique.
- The results after 8months shown bone filled at extraction socket.

CASE 2: UNRESTORABLE CARIES



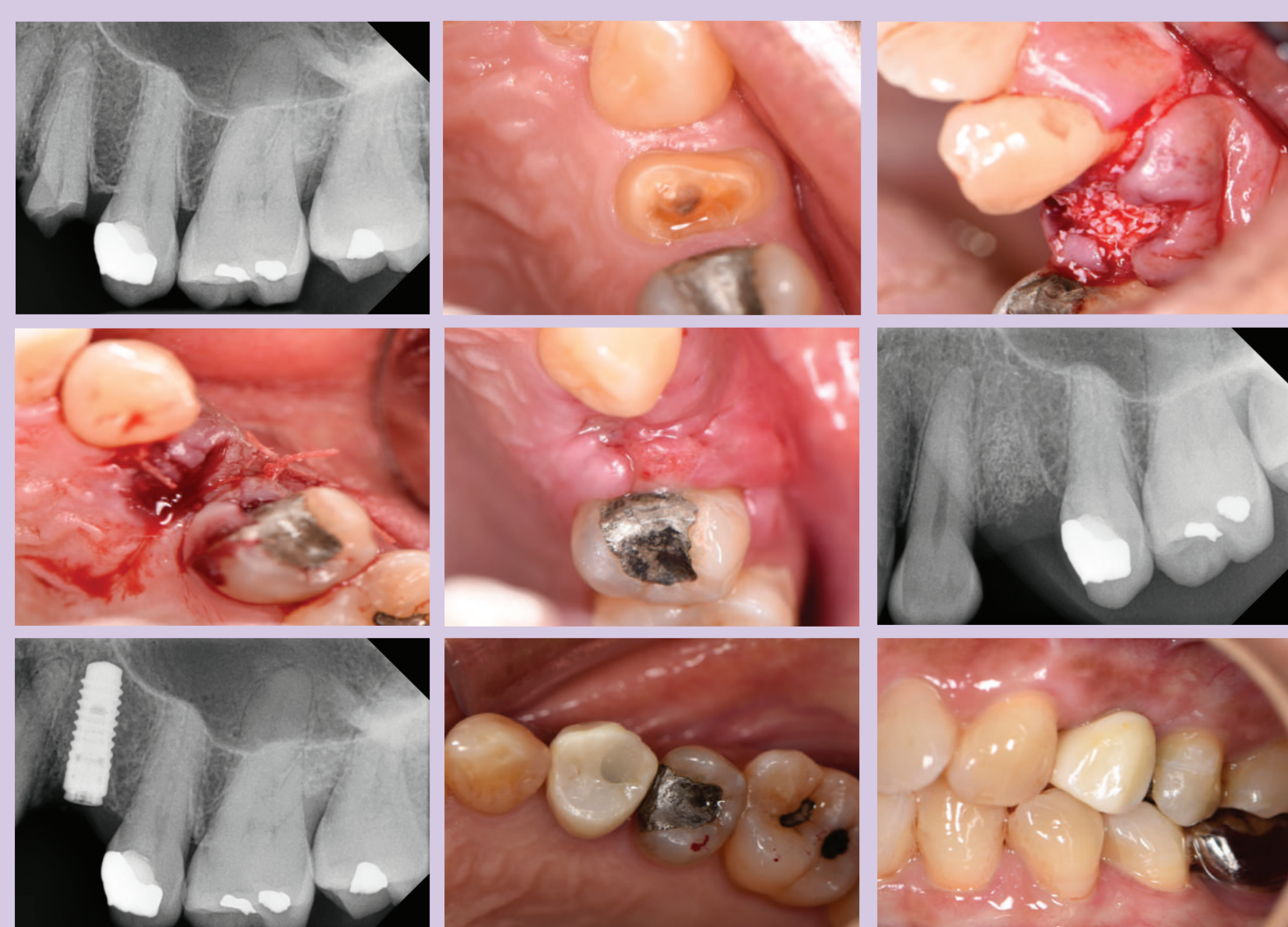- A 50 years old lady came with complaint on fractured tooth on the lower left posterior region.
- Upon examination, a deep and wide dentinal caries involving the distal upperthird of the root of tooth 36 was noted.
- Treatment options were given to patient and patient decided for extraction followed by placement of implant supported crown procedure.
- Therefore, an intrasulcular incision was made on the buccal and lingual aspect with vertical releasing incision on the buccal.
- A flap was raised in full thickness.
- Atraumatic extraction was done by using periosteal elevator and extraction forceps of 36.
- Socket was curettaged and debrided.
- Later, xenogenic bone particles was placed at extraction socket.
- And lastly, membrane was packed and flap was fully closed and sutured.
- The results after 2 weeks shown that the wound was fully closed.
- One month later, surgical site was reviewed again and the wound undergone healing with no sign and symptoms.

CASE 3: ROOT CARIES



- A 39 years old lady came with complaint of tooth sensitivity on the lower left posterior region.
- Upon examination, the tooth presented with buccal recession with sensitive to air blown and slight tender to percussion but no swelling and pus discharge seen.
- Periapical radiograph shown there's a presence of radiolucency on the distal root surfaces extending to the pulp and bifurcation area.
- The tooth then planned for atraumatic extraction followed by implant supported crown due to the presence of root caries.
- Therefore, an intrasulcular incision was made on the buccal and lingual aspect with vertical releasing incision on the buccal.
- A flap was raised in full thickness.
- Atraumatic extraction was done by using periosteal elevator and extraction forceps of 36.
- Socket was then curettaged and debrided.
- Xenogenic bone particles was placed at extraction socket.
- And lastly, resorbable membrane was packed and flap was fully closed and sutured.
- The results after 2 weeks shown that the wound was fully closed.

CASE 3: INADEQUATE CROWN ROOT RATIO



- A 60 years old lady came with complaint of fractured tooth and history of dull pain on the upper left first premolar.
- Upon examination, the crown to root ratio of tooth 24 is inadequate with 0.5:2.0.
- It was then decided to proceed with socket preservation procedure followed by implant placement.
- Therefore, an intrasulcular incision was made on the buccal and lingual aspect with vertical releasing incision on the buccal

- A full thickness flap was raised.
- Atraumatic extraction was done by using periosteal elevator and extraction forceps of tooth 24.
- Socket was curettaged and debrided.
- Later, xenogenic bone particles was placed at extraction socket. with placement of resorbable membrane.
- After 4 months of healing, implant was placed and loaded 3 months later.

CONCLUSION

- In order to achieve the functionality and aesthetics of an implant supported prosthesis, sufficient alveolar bone volume and favourable architecture of the alveolar ridge was agreed by the professionals as one of the crucial factors to consider.
- Socket preservation technique has been one of the technique in preserving and reconstructing an extraction socket by following the principles of guided bone regeneration.
- In conclusion, this technique, enhances our ability to deliver the best restorations with regards to function and aesthetic.

References:

- Marcus SE, Drury TF, Brown LJ, Zion GR. Tooth retention and tooth loss in the permanent dentition of adults: United States, 1988-1991. J Dent Res Feb 99; 75(2): Suppl: 684-695
- Irinakis T. Rationale for socket preservation after extraction of a single-rooted tooth when planning for future implant placement: J Can Dent Assoc. 2006 Dec;72(10):917-22.
- Darby J, Chen ST, Buser D. Ridge preservation techniques for implant therapy. Int J Oral Maxillofac Implants. 2009;24 Suppl:260-71.