

2022

Normative data on the foveal avascular zone in a young healthy Irish population using optical coherence tomography angiography

Susan M. O'Shea

Veronica O'Dwyer

Grainne Scanlon

Follow this and additional works at: <https://arrow.tudublin.ie/ceyerart>



Part of the [Optics Commons](#), and the [Optometry Commons](#)

This Article is brought to you for free and open access by the Centre for Eye Research Ireland at ARROW@TU Dublin. It has been accepted for inclusion in Articles by an authorized administrator of ARROW@TU Dublin. For more information, please contact arrow.admin@tudublin.ie, aisling.coyne@tudublin.ie, gerard.connolly@tudublin.ie.



This work is licensed under a [Creative Commons Attribution-Noncommercial-Share Alike 4.0 License](#)

Normative data on the foveal avascular zone in a young healthy Irish population using optical coherence tomography angiography

Susan M. O'Shea¹ , Veronica M. O'Dwyer¹
and Grainne Scanlon^{1,2} 

European Journal of Ophthalmology
1–9

© The Author(s) 2022

Article reuse guidelines:

sagepub.com/journals-permissions

DOI: 10.1177/11206721211073446

journals.sagepub.com/home/ejo



Abstract

Purpose: To establish normative data on the size, shape and vascular profile of the foveal avascular zone (FAZ) in a young, healthy, Irish population, using the Cirrus 5000 HD-OCT. Certain diseases may alter FAZ appearance. Normative databases provide normal baseline values for comparison, thus improving diagnostic ability.

Methods: One hundred and fifty-four subjects aged 18–35 years old were recruited. Superficial FAZ area, diameter, circularity, ganglion cell layer, central macular thickness (CMT), vascular perfusion and density were measured using the Cirrus 5000. Axial length was measured with the IOL Master and blood pressure was measured using the Omron sphygmomanometer.

Results: Mean FAZ area was $0.22 \pm 0.07 \text{ mm}^2$, mean CMT was $263.08 \pm 18.73 \mu\text{m}$. Both were larger in females than males ($p = 0.022$, $p = 0.000$). Mean vessel density and perfusion central were $14.11 \pm 2.77 \text{ mm/mm}^2$ and $24.70 \pm 4.96\%$ respectively. Both were lower in females ($p = 0.010$, $p = 0.019$). Vessel density and perfusion inner correlated positively with minimum ganglion cell layer plus inner plexiform layer (GCL + IPL) thickness ($p = 0.001$, $p = 0.019$). CMT correlated positively with vessel density and perfusion central ($p = 0.000$ for both) and negatively with FAZ area ($p = 0.000$).

Conclusions: This study provides normative data for FAZ appearance and vascularity for the first time in a young, healthy, Irish population, using the Cirrus 5000 HD-OCT. Establishing machine and population specific normative data, particularly in relation to vessel density and perfusion is paramount to the early identification of ocular disease using Optical Coherence Tomography Angiography.

Keywords

Diagnostic techniques < GLAUCOMA, optics/refraction/instruments < OPTICS / REFRACTION / INSTRUMENTS, techniques of retinal examination < RETINA, diabetic retinopathy < RETINA, neuro maging < NEURO OPHTHALMOLOGY, age-related macular degeneration < RETINA

Date received: 7 July 2021; accepted: 12 December 2021

Introduction

The foveal avascular zone (FAZ) is a region in the fovea devoid of blood vessels. Absence of vessels in this area reduces light scatter, allowing light to pass to photoreceptors unimpeded, thereby providing precise vision from this region of the macula.¹ While the FAZ is surrounded by a capillary ring, nutrients are provided to this region by the choriocapillaris.² The FAZ can be visualised using fluorescein angiography (FA),³ however, with optical coherence

¹School of Physics, Clinical & Optometric Sciences. Technological University Dublin, Dublin, Ireland

²Centre for Eye Research Ireland, GW205-207 Greenway Hub, Environmental Sustainability and Health Institute, TU Dublin, Dublin, Ireland

Corresponding author:

Susan O'Shea, School of Physics, Clinical & Optometric Sciences, Central Quad, TU Dublin, Grangegorman Lower, Dublin 7, D07ADY7, Ireland.
Email: C06466176@mytudublin.ie



tomography angiography (OCTA), this area can now be examined in greater detail, non-invasively.

The current study used the Cirrus 5000 HD-OCT (ZEISS, California), which identifies the movement of red blood cells by scanning the retina approximately 68,000 times per second.³ An algorithm provides analysis, detecting movement as blood flow and producing three-dimensional angiographic images.³ The software is the Angioplex metrix which measures FAZ area, circularity, perimeter, diameter, vessel density and vessel perfusion. Circularity index is a scale from 0 to 1 of how circular an object is, 1 being a perfect circle.⁴ Angioplex measures vessel density as the total length of perfused blood vessels per unit area, represented as mm/mm². Vessel perfusion is a percentage of the total area of perfused vasculature per unit area in the same region.⁵ As there is no standardised method of representing this information, comparisons cannot be made between different OCTA machines. Therefore, normative data is required for each commercially available instrument. Vessel density and perfusion are subdivided into sections according to the Early Treatment of Diabetic Retinopathy Study (ETDRS) in circles of 1 mm, 3 mm and 6 mm diameter.⁵ An example is shown in Figure 1A. Vessel density and perfusion density are measured within central, inner and full zones which are shown in Figure 1B.

FAZ size appears to increase with age while vessel density decreases.^{6,7} FAZ size is generally larger in females than in males.^{6,8} Central macular thickness (CMT) has been found to be smaller in females.⁸ Larger FAZ area has been associated with decreased CMT,^{8,9} suggesting that a thinner retina requires less blood supply and, therefore, will have a larger FAZ. Additionally, longer axial length has been associated with larger FAZ area and decreased vessel density.¹⁰

Normative data for FAZ parameters are valuable in understanding the possible relationship they may have with disease process. This is particularly relevant to diseases characterised by blood flow and perfusion such as diabetes, multiple sclerosis and glaucoma.^{11–13} Increased FAZ size and irregular shape may have diagnostic importance in diabetes.¹¹ Di et al. found greater variability in FAZ appearance between subjects without diabetic retinopathy compared to those with it, indicating that FAZ changes could possibly predict disease.¹⁴ The invasive nature of FA means, however, that it is not routinely used on subjects with mild diabetic retinopathy or prediabetes.¹⁴ Therefore, with OCTA, FAZ changes in these subjects can now be investigated.¹⁴

The purpose of the current study is to establish normative data relating to FAZ size, shape and vascular profile in a young, healthy Irish population. There is a need for machine-specific normative data to make valid comparisons when using OCTA.¹⁵

Methods

Approval was obtained from the Technological University Dublin (TU Dublin) ethics committee. Subjects were recruited mainly from the TU Dublin student cohort in accordance with the principles of the Declaration of Helsinki.

Subjects

Healthy subjects aged 18–35 years old with visual acuity \geq 6/12 were included. Exclusion criteria was refractive error \geq \pm 8.00DS spherical equivalent. Because interocular symmetry of the FAZ area has been demonstrated, one eye of each participant was examined.¹⁶

Ocular and clinical examinations

Spectacle prescription, if worn, was measured on a manual focimeter, otherwise the dry refractive error was measured using an autorefractor (Dong Yang ReKto ORK-11 Auto Ref-Keratometer, Everview, Korea). Visual acuity was measured with appropriate correction in place and the eye with the best acuity was used. In case of equal acuity, the dominant eye was selected, using the Miles test.¹⁷ Axial length was measured using the IOL Master (ZEISS, Germany). Blood pressure was measured using an M3 Digital Sphygmomanometer (Omron, Netherlands).

Optical coherence tomography angiography

OCTA was performed using the Cirrus 5000 HD-OCT.¹⁸ A 200 \times 200 mm macular cube was imaged by a single skilled examiner, followed by a 3 \times 3 mm OCTA scan. Scans with a signal strength of 8 or higher were accepted. Macular health was confirmed by viewing a photograph from the macular cube scan and by self-reported medical history. CMT and ganglion cell thickness were obtained from the macular cube. The Angioplex metrix identified FAZ area, perimeter, circularity, vessel density and perfusion in the superficial FAZ, which Angioplex defines as the layer from the inner limiting membrane to the inner plexiform layer.¹⁸ In cases where the FAZ was incorrectly or not identified, this was performed manually. The machine's internal callipers measured the horizontal, vertical and longest diameters of the FAZ.

Statistical analysis

Statistical analysis was carried out using the Statistical Package for Social Sciences (SPSS) version 26.0 (IBM Corp, Armonk, NY, USA). Normality of the data was assessed using the Kolmogorov-Smirnov test. An independent samples t-test was used to test for differences in normally distributed study parameters, whereas the Kruskal-Wallis H test

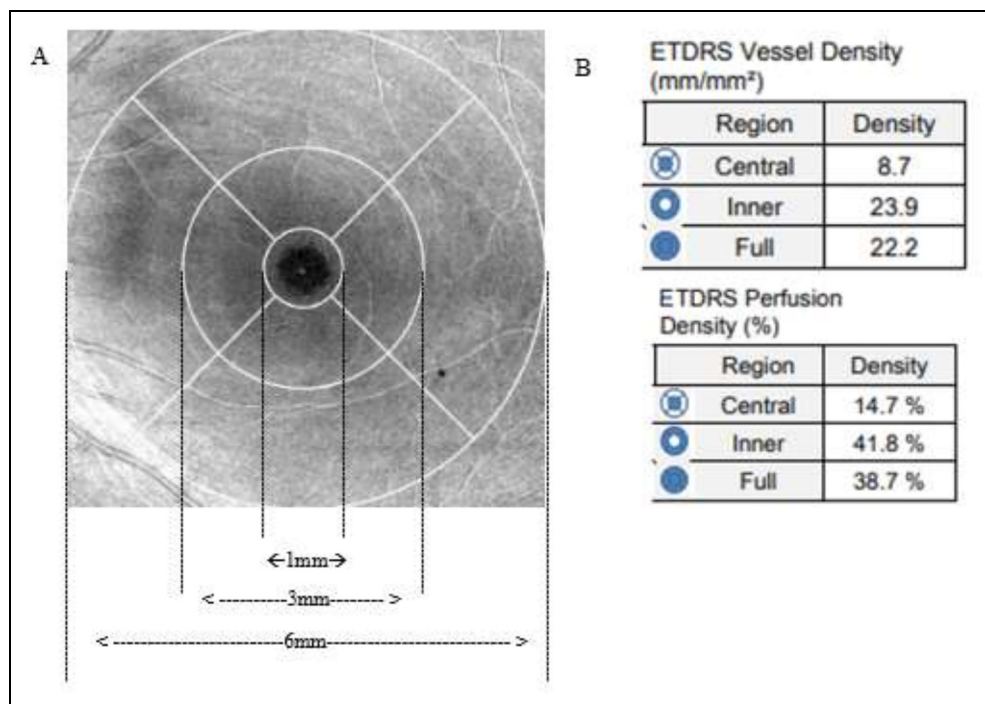


Figure 1. A. ETDRS grid centred on the macula. B. Cirrus Metrix showing central, inner and full ETDRS measurement zones. The central zone corresponds to a circle of 1 mm diameter, the inner zone is the inner 1 mm radius ring and the full zone is a disc of 3 mm diameter comprising both. The outer 1.5 mm diameter ring as shown in Figure 1A is not used in a 3 mm scan.

was used for non-normally distributed data. Pearson's product-moment and Spearman's Rho were used to assess the relationship between FAZ area and other study variables where appropriate. Partial correlations were carried out to control for gender. All values were expressed as mean \pm standard deviation throughout. A P -value of < 0.05 was considered significant.

Table 1. Demographic characteristics of the study group (n = 142).

Characteristic	n	%
Sex		
Male	45	31.7
Female	97	68.3
Race		
White	115	81
Mixed	7	4.9
Asian	8	5.6
Pakistani	3	2.1
African American	6	4.2
Hispanic	1	0.7
Indian	2	1.4
Blood Pressure		
Non-hypertensive	133	93.7
Hypertensive	9	12.6

Hypertension: Systolic blood pressure > 140 mmHg and/or diastolic blood pressure > 90 mmHg.

Results

Demographic data

Of the 154 subjects recruited, 12 were excluded due to underlying systemic health conditions. Ninety-seven of the remaining subjects were female and 45 were male. The mean age for the total group was 23.75 ± 4.89 (range 18–34). Demographic data are shown in Table 1.

Analysis

Data was analysed for both the full group (n = 142) and whites only (n = 115). While there were no significant differences in P values for the main findings between the two groups, the subsequent analysis is reported for the whites only group (n = 115).

FAZ characteristics

FAZ characteristics and differences between males and females are shown in Table 2. Mean and standard deviation for the FAZ area were 0.22 ± 0.07 mm². Females had significantly larger FAZ area (0.23 ± 0.07 mm²) than males (0.19 ± 0.08 mm²), ($P < 0.01$). FAZ perimeter and diameters were all significantly larger in females ($P < 0.01$ for all). Median FAZ circularity was 0.71 with no significant difference between the sexes ($P = 0.05$).

Table 2. Demographic and structural characteristics by gender (n = 115).

	Total	Male	Female	p value
Age	22 (18–34)	26 (18–34)	21.5 (18–33)	0.01* †
FAZ area (mm ²)	0.22 ± 0.07	0.19 ± 0.08	0.23 ± 0.07	0.02*
Circularity	0.71 (0.48–0.86)	0.69 (0.48–0.82)	0.72 (0.49–0.86)	0.18†
Perimeter (mm)	1.94 ± 0.07	1.84 ± 0.38	1.99 ± 0.32	0.03*
Horizontal diameter(μm)	565 (265–829)	522 (272–829)	586 (256–750)	0.03* †
Vertical diameter (μm)	508.26 ± 102.68	471.86 ± 113.57	525.53 ± 92.95	0.00*
Longest Diameter (μm)	614.71 ± 103.88	579.11 ± 111.50	631.60 ± 96.26	0.01*
Vessel Density central (mm/mm ²)	14.11 ± 2.77	15.06 ± 3.02	13.66 ± 2.55	0.01*
Vessel Density Inner (mm/mm ²)	23.22 ± 1.01	23.25 ± 0.86	23.21 ± 0.98	0.81
Vessel Density Full (mm/mm ²)	22.20 ± 1.01	22.32 ± 0.99	22.14 ± 1.03	0.37
Vessel Perfusion central (%)	24.70 ± 4.96	26.26 ± 5.35	23.96 ± 4.92	0.02*
Vessel Perfusion inner	41.55 ± 1.47	41.59 ± 1.35	41.53 ± 1.52	0.82
Vessel Perfusion full	39.65 ± 1.65	39.87 ± 1.56	39.54 ± 1.70	0.33
CMT (μm)	263.08 ± 18.73	274.70 ± 19.56	257.56 ± 15.65	0.00*
Average GCL + IPL thickness (μm)	83.19 ± 5.35	83.93 ± 6.04	82.85 ± 4.99	0.32
Minimum GCL + IPL thickness (μm)	81.93 ± 5.49	82.81 ± 6.32	81.51 ± 5.03	0.24
Axial length	23.88 ± 1.16	23.91 ± 1.25	23.87 ± 1.12	0.89
Systolic BP	118.89 ± 11.80	126.97 ± 10.19	115.06 ± 10.54	0.00*
Diastolic BP	78.31 ± 8.09	81.40 ± 6.43	76.84 ± 8.41	0.00*

Independent samples t- test †Independent samples Kruskal-Wallis test of medians. *Difference is significant at the 0.05 level.

Abbreviations: FAZ; foveal avascular zone, CMT; central macular thickness, Avg GCL + IPL thickness; average ganglion cell layer and inner plexiform layer thickness, Min GCL + IPL thickness; minimum ganglion cell layer and inner plexiform layer thickness.

Vessel density and perfusion

Normative data for vessel density and perfusion in males and females are shown in Table 2. The mean and standard deviation for vessel density and perfusion central were 14.11 ± 2.77 mm/mm² and 24.70 ± 4.96% respectively. Both were significantly smaller in females (13.66 ± 2.55 mm/mm² and 23.96 ± 4.92%) than in males (15.06 ± 3.02 mm/mm² and 26.26 ± 5.35%) ($P < 0.05$ for all). Blood pressure was also lower in females than in males ($P < 0.05$).

Structural parameters

The mean axial length for the whole group was 23.88 ± 1.16 mm (range 20.6–27.16). There was no statistically significant difference in axial length based on gender ($P > 0.05$), as shown in Table 2. The mean CMT was 263.08 ± 18.73 μm and this was lower in females than in males ($P < 0.05$).

FAZ measurements and vessel density and perfusion

Correlations between FAZ size, vessel density and perfusion are shown in Table 3. As expected, vessel density central and full correlated negatively with FAZ area (Pearson's $r = -0.707$, -0.350 , $P < 0.01$) and perimeter (Pearson's $r = -0.664$, -0.326 , $P < 0.01$). Vessel perfusion central and full correlated negatively with FAZ area (Pearson's $r = -0.684$, -0.323 , $P < 0.01$) respectively and perimeter (Pearson's $r = -0.636$, -0.305 , $P < 0.01$) respectively.

CMT, vessel density, perfusion, and GCL + IPL thickness

CMT correlated negatively with FAZ area, (Pearson's $r = -0.594$, $P < 0.01$), perimeter (Pearson's $r = -0.566$, $P < 0.01$), and diameters as shown in Figure 2 (A), (B), (C) and (D). CMT showed significant positive correlations with vessel density and perfusion central and full (Pearson's $r = 0.644$, 0.320 , 0.637 , and 0.342 , $P < 0.01$ for all). No significant correlation was found between CMT and axial length ($P > 0.05$). Average GCL + IPL thickness showed a positive correlation with vessel density inner, (Pearson's $r = 0.292$, $P < 0.01$). Minimum GCL + IPL thickness showed positive correlations with both vessel density inner and full (Pearson's $r = 0.309$, $P < 0.01$, 0.235 , $P < 0.05$) and vessel perfusion inner, (Pearson's $r = 0.220$, $P < 0.05$). These correlations are shown in Table 4.

Discussion

OCTA is a non-invasive, simple test with great diagnostic potential, given that FAZ area and vascular changes have been associated with various diseases.^{11–14} While several studies have examined FAZ area and vascular profile in various ethnicities, relatively few studies report on a predominantly white, young, healthy population. A considerable amount of normative data exists for the AngioVue machine, (Optovue, USA),^{8,19–21} and the Topcon DRI-OCT.^{6,7,9,22} While some normative data exists for the Cirrus 5000,^{23–25} there is currently limited data

Table 3. Correlations between FAZ measurements and vessel density and perfusion and blood pressure controlling for gender (n = 115).

	FAZ Area	Circularity	Perimeter	Horizontal Diameter	Vertical Diameter	Longest Diameter
Vessel Density Central	-0.707†**	-0.173‡	-0.664†**	-0.694‡**	-0.612†**	-0.692†**
Vessel Density Inner	-0.160†	-0.044‡	-0.148†	-0.127‡	-0.176†	-0.125†
Vessel Density Full	-0.350†**	-0.098‡	-0.326†**	-0.306‡**	-0.333†**	-0.314†**
Vessel Perfusion Central	-0.684†**	-0.186‡*	-0.636†**	-0.672‡**	-0.588†**	-0.663†**
Vessel Perfusion Inner	-0.122†	-0.039‡	-0.118†	-0.088‡	-0.130†	-0.103†
Vessel Perfusion Full	-0.323†**	-0.089‡	-0.305†**	-0.275‡**	-0.301†**	-0.300†**
Mean Systolic BP	0.252†**	0.016‡	0.241†**	0.192‡*	0.206†*	0.227†*
Mean Diastolic BP	0.163†	-0.052‡	0.173†	0.210‡*	0.170†	0.117†

Pearson Correlation test†; Spearman's Rho test‡; Correlation is significant at 0.05 level*; Correlation is significant at 0.01 level**. Significant correlations are shown in bold.

Abbreviations: FAZ; foveal avascular zone, BP; blood pressure.

available on white subjects, on vascular profile, and to the author's knowledge, none on an Irish population. Establishing normative data is paramount if FAZ changes associated with systemic or ocular disease are to be detected and monitored.

FAZ area, perimeter and diameter

Differences in FAZ area and size have been found, possibly due to the various ethnicities, age and gender profiles being studied, along with different types of commercial instruments used.^{7,8,24,25} In the current study, FAZ area was significantly larger in females (0.23 mm²) compared with males (0.19 mm²), ($P < 0.01$) and this is supported by the literature.^{7,8} The mean FAZ area for the current population was 0.22 ± 0.07 mm², which was smaller than that found in an Asian population (0.37 ± 0.11 mm²),²³ which also used the Cirrus 5000. A recent study found that FAZ area was significantly larger in a Chinese population (0.33 ± 0.012 mm²) compared with Polish subjects (0.28 ± 0.014 mm²), also using this machine.²⁵ The mean age of this study group was 68.23 ± 1.42 and 65.31 ± 1.10 years respectively, and subjects under the age of 54 years were excluded. Coscas et al. found the mean superficial FAZ area was 0.28 mm², when using the AngioVue OCTA (Optovue Inc, USA), in a white population, aged 20–79 years old, and noted that vessel density decreased with age.²¹ Fujiwara et al. found that age only became a factor affecting FAZ area in those aged 40 years and over, in a large group of Japanese subjects.⁹ Of interest, Dai et al. found that the Cirrus 5000 consistently measured smaller FAZ area and vessel density when compared with the AngioVue machine.²⁶ While the current study found that the average FAZ area was smaller in whites compared with other populations, due to limited data (white n = 115 versus other ethnicities n = 27), it was not possible to compare with other ethnicities. Furthermore, no association was found between FAZ area and age in this group of young adults, aged 18–35 years old, mean age $24.06 \pm$

4.95 years. The variability in measurements between different groups highlight the importance of taking ethnicity, age and gender into account when making comparisons. These findings further highlight the need for machine and population-specific normative data on FAZ size and area in a young, healthy, white population, for disease detection and monitoring using OCTA.

Vessel density and perfusion

Vessel density and perfusion central were found to be significantly lower in females than males ($P < 0.01$, $P < 0.05$ respectively). This may be because females have a smaller number of vessels spread throughout a larger area of the choriocapillaris plexus, as females are known to have a larger FAZ area than males. Mean vessel density central, inner and full were 14.11 ± 2.77 mm/mm², 23.22 ± 1.01 mm/mm² and 22.20 ± 1.01 mm/mm², on the Cirrus 5000, while mean vessel perfusion central inner and full were, $24.70 \pm 4.96\%$, $41.55 \pm 1.47\%$ and $39.65 \pm 1.65\%$ respectively in this young Irish population. Findings in the literature relating to vessel density and gender, are, however, mixed. Yilmaz et al. found no significant relationship while the findings of Wang et al. support the current study.^{19,27} A recent study on an older population using the Cirrus 5000 found that vessel density full was significantly higher in Chinese subjects (17.05 ± 0.24 mm/mm²) when compared with Polish subjects (16.08 ± 0.43 mm/mm²).²⁵ The smaller vessel density full found in Polish subjects compared to the white subjects in the current study may be due to different EDTRS segmentation used by the software of each machine. Differences in software between the various instruments mean that it is not possible to make direct comparisons on vessel density and perfusion, even on the same machine which further highlights the importance of establishing normative data for each instrument depending on the software used. The current study found that blood pressure was statistically significantly lower in females

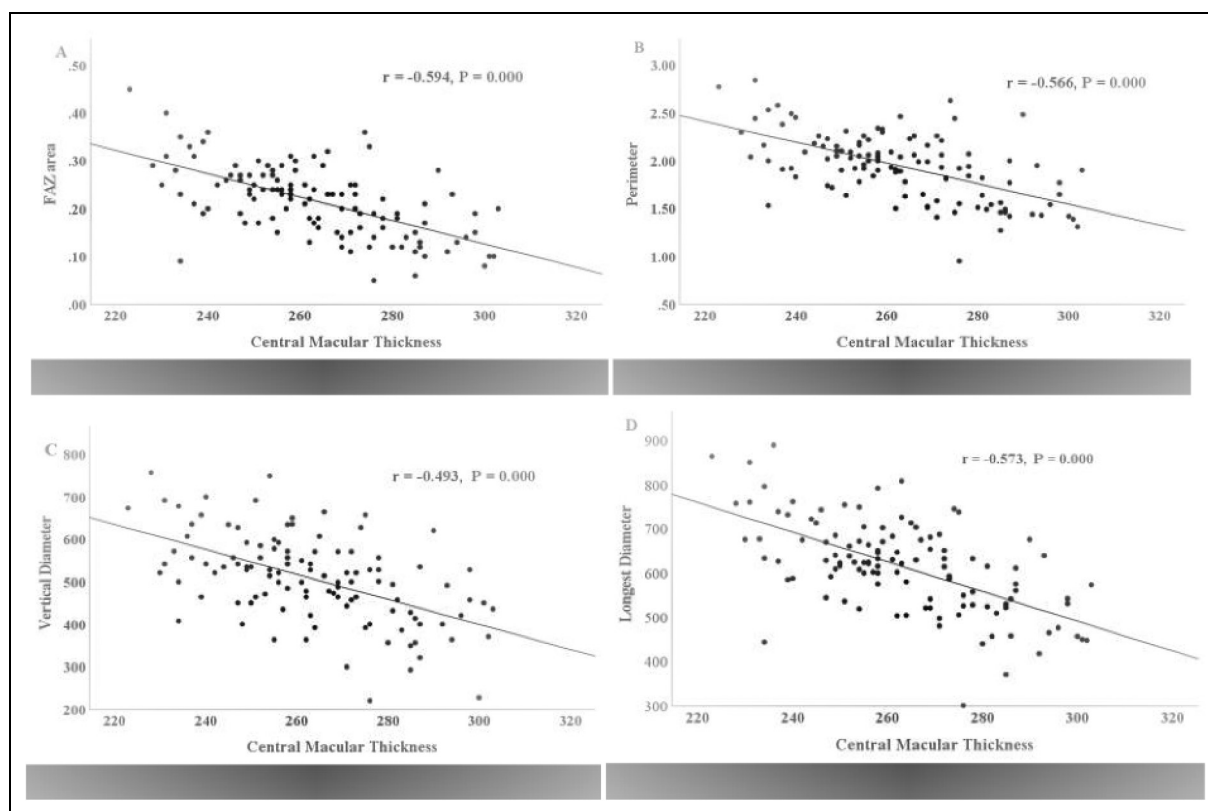


Figure 2. Significant negative partial correlations between CMT and (A) FAZ area; (B) perimeter; (C) vertical diameter and (D) longest diameter. These findings indicate that a larger FAZ area is associated with lower CMT. Abbreviations: CMT, central macular thickness; FAZ, foveal avascular zone.

Table 4. Correlation of vessel density and perfusion and structural parameters controlling for gender (n = 115).

	Vessel Density Central	Vessel Density Inner	Vessel Density Full	Vessel Perfusion Central	Vessel Perfusion Inner	Vessel Perfusion Full
Axial Length	0.154	0.091	0.124	0.074	-0.081	-0.040
Avg GCL + IPL Thickness	-0.052	0.292**	0.221	-0.034	0.244	0.182
Min GCL + IPL Thickness	-0.056	0.309**	0.235*	-0.051	0.220*	0.160
CMT	0.644**	0.145	0.320**	0.637**	0.153	0.342**

Pearson Correlation test; Correlation is significant at 0.05 level*; Correlation is significant at 0.01 level **. Significant correlations are shown in bold.

Abbreviations: CMT; central macular thickness, Avg GCL + IPL thickness; average ganglion cell layer and inner plexiform layer thickness, Min GCL + IPL thickness; minimum ganglion cell layer and inner plexiform layer thickness.

compared with males ($P < 0.01$) which is not surprising, as blood pressure tends to be lower in premenopausal women than age-matched males.²⁸ There was, however, no significant correlation between blood pressure and vessel density or perfusion while controlling for gender, in the current study. While this finding was unexpected, the small number of hypertensive subjects may explain this observation. A 2018 study suggested, however, that changes in the choriocapillaris vasculature could be indicative of hypertension, indicating that hypertension may

affect the microvasculature of the eye.²⁹ Further research on participants with hypertension versus normotension is warranted to establish cut-off points where hypertension can show an effect on vessel density and perfusion within the retina.

Central macular thickness, GCL + IPL thickness

CMT was found to be lower in females than in males in the current study, which aligns with previous reported findings

using various machines.^{8,9,30} The mean CMT for the white group was $263.08 \pm 18.73 \mu\text{m}$. CMT correlated negatively with FAZ area, a finding which has appeared elsewhere,^{7,8,20} Samara et al. infer that a thicker retina may have a smaller FAZ due to increased metabolic requirements.²⁰ The current study supports these findings, as CMT was positively and FAZ area was negatively correlated with vessel density and perfusion, central and full. This suggests that a greater macular thickness requires a larger amount of blood vessels and perfusion and therefore, a smaller avascular zone. While the results are not directly comparable; a recent study also found a positive correlation between vessel density and foveal thickness using the Triton OCT (Topcon, Japan).²² Although no correlation was found between CMT and blood pressure in the current study in this young, healthy, population; Lee et al. found that CMT was thinnest in a group of subjects with hypertensive retinopathy or previous retinopathy when compared with healthy controls.³¹ Future research on subjects with hypertension could further investigate these findings.

Vessel density inner showed positive correlations with both average and minimum GCL + IPL thickness in the current study, while vessel density full and perfusion inner also correlated positively with minimum GCL + IPL thickness. This association may indicate that thicker ganglion cell and inner plexiform layers require more vascular perfusion to function normally, as would be expected. The average and minimum GCL + IPL thicknesses were found to be $83.19 \pm 5.35 \mu\text{m}$ and $81.93 \pm 5.49 \mu\text{m}$ in the current study. Again, similar normative data on the Cirrus 5000 for comparison is lacking, to the author's knowledge to date, one small study ($n = 10$) reports similar normative data on average ($82.1 \pm 3.6 \mu\text{m}$) and minimum ($79.6 \pm 4.1 \mu\text{m}$) GCL + IPL thickness in a Spanish population.⁵ Reduction in ganglion cell layer thickness has been associated with glaucoma diagnosis.³² Further study of correlations with these thickness values in a larger population sample would be interesting to investigate the potential use of minimum GCL + IPL thickness as a prognostic indicator for possible glaucomatous change in otherwise healthy subjects with glaucoma risk factors, such as family history or raised IOP.

Differences between manufacturers

The Angioplex software represents vessel density as mm/mm^2 while the XR Avanti uses a percentage. Shiihara et al. found that the measurement of FAZ area was comparable between the DRI-OCT Triton, the RS-3000 Advance (Nidek, Japan) and the Cirrus 5000, however, these authors used only manual measurements for the Cirrus machine as the study predated the Angioplex automatic software.²⁴ The variability in how FAZ data has been presented in

the literature makes it difficult to draw comparisons, even using the same machine.

Study strengths and limitations

To the author's knowledge, this study is the first to establish normative data on FAZ area and vascular profile, in a young, healthy, Irish, white population for the Cirrus 5000 HD-OCT. The large study size was an important strength, which represented a young healthy population. There were, however, some limitations which should also be acknowledged. Ocular health was based on self-reported case history and by examination of a greyscale photograph rather than by direct observation. The study population had a higher percentage of females than males which may have influenced some of our findings and, therefore, should be interpreted with caution. The current study did not include measurement of intraocular pressure which would have further contributed to our understanding of factors affecting the FAZ. Shoji et al. found that FAZ area decreased after IOP lowering surgery in subjects with POAG while Zhou et al. found no association between IOP and FAZ area in young, healthy subjects.^{8,33}

Conclusion

This study proposes normative data, for the first time, on FAZ size, shape and vascular profile in a young, healthy, Irish population, using the Cirrus 5000 HD-OCT. The mean FAZ area for the current population was smaller than other ethnicities, which also used the Cirrus 5000. Vessel density and perfusion central were found to be lower in females compared with males ($P < 0.01$, $P < 0.05$ respectively). No significant correlation, however, was found between blood pressure and vessel density or perfusion, in participants under the age of 35, while controlling for gender. Vessel density central and full correlated positively with CMT and negatively with FAZ area. These findings suggest that a greater macular thickness requires a larger amount of blood vessels and blood perfusion and, therefore, a smaller avascular zone. Vessel density inner showed a positive correlations with average and minimum GCL + IPL thickness in the current study, vessel density full and perfusion inner also correlated positively with minimum GCL + IPL thickness only which is an interesting finding. Thinning ganglion cell layer is considered to be a potential indicator for glaucoma.³² Our findings suggest that minimum GCL + IPL thickness is a more useful predictor than using average thickness.

OCTA has potential for the investigation of the FAZ area and retinal vasculature for diagnostic purposes, however, there is a need for normative data for individual instruments. The variability of reporting on vascularity between the various machines means that no comparisons can be made between our results and the existing literature.


Declaration of conflicting interests


The author(s) declared no potential conflicts of interest with respect to the research, authorship, and/or publication of this article.

Funding

The authors received no financial support for the research, authorship or publication of this article.

ORCID iDs

Susan M. O'Shea  <https://orcid.org/0000-0002-2965-9699>

Grainne Scanlon  <https://orcid.org/0000-0001-6956-5980>

References

- Zeffren BS, Applegate RA, Bradley A, et al. Retinal fixation point location in the foveal avascular zone. *Invest Ophthalmol Vis Sci* 1990; 31: 2099–2105.
- Zouache MA, Eames I, Klettner CA, et al. Form, shape and function: segmented blood flow in the choriocapillaris. *Sci Rep* 2016; 6: 1–13.
- Rosenfeld PJ, Durbin MK, Roisman L, et al. ZEISS AngioPlex™ spectral domain optical coherence tomography angiography: technical aspects. *Dev Ophthalmol* 2016; 56: 18–29.
- Choi J, Kwon J, Shin JW, et al. Quantitative optical coherence tomography angiography of macular vascular structure and foveal avascular zone in glaucoma. *PLoS ONE* 2017; 12: 1–19.
- Rebolleda G, Diéz-Álvarez L, García Marín Y, et al. Reduction of peripapillary vessel density by optical coherence tomography angiography from the acute to the atrophic stage in non-arteritic anterior ischaemic optic neuropathy. *Ophthalmologica* 2018; 240: 191–199.
- Gómez-Ulla F, Cutrin P, Santos P, et al. Age and gender influence on foveal avascular zone in healthy eyes. *Exp Eye Res* 2019; 189: 107856.
- Sato R, Kunikata H, Asano T, et al. Quantitative analysis of the macula with optical coherence tomography angiography in normal Japanese subjects: the taiwa study. *Sci Rep* 2019; 9: 1–11.
- Zhou Y, Zhou M, Gao M, et al. Factors affecting the foveal avascular zone area in healthy eyes among young Chinese adults. *BioMed Res Int* 2020; 2020: 1–8.
- Fujiwara A, Morizane Y, Hosokawa M, et al. Factors affecting foveal avascular zone in healthy eyes: an examination using swept-source optical coherence tomography angiography. *PLoS ONE* 2017; 12: 1–12.
- Shihara H, Terasaki H, Sonoda S, et al. Objective evaluation of size and shape of superficial foveal avascular zone in normal subjects by optical coherence tomography angiography. *Sci Rep* 2018; 8: 1–9.
- Krawitz BD, Mo S, Geyman LS, et al. Acircularity index and axis ratio of the foveal avascular zone in diabetic eyes and healthy controls measured by optical coherence tomography angiography. *Vision Res* 2017; 139: 177–186.
- Yilmaz H, Ersoy A and Icel E. Assessments of vessel density and foveal avascular zone metrics in multiple sclerosis: an optical coherence tomography angiography study. *Eye (Basingstoke)* 2020; 34: 771–778.
- Kwon J, Choi J, Shin JW, et al. Glaucoma diagnostic capabilities of foveal avascular zone parameters using optical coherence tomography angiography according to visual field defect location. *J Glaucoma* 2017; 26: 1120–1129.
- Di G, Weihong Y, Xiao Z, et al. A morphological study of the foveal avascular zone in patients with diabetes mellitus using optical coherence tomography angiography. *Graefe's Arch Clin Exp Ophthalmol* 2016; 254: 873–879.
- Kashani AH, Chen C-L, Gahm JK, et al. Optical coherence tomography angiography: a comprehensive review of current methods and clinical applications. *Graefe's Arch Clin Exp Ophthalmol* 2018; 256: 237–245.
- Liu M, Fujiwara A, Morizane Y, et al. Interocular symmetry of the foveal avascular zone area in healthy eyes: a swept-source optical coherence tomography angiography study. *Jpn J Ophthalmol* 2020; 64: 171–179.
- Miles WR. Ocular dominance in human adults. *J Gen Psychol* 1930; 3: 412–430.
- Carl Zeiss Meditec. *Cirrus HD-OCT User Manual*. Jena, Germany: Carl Zeiss Meditec, 2017.
- Wang Q, Chan S, Yang JY, et al. Vascular density in retina and choriocapillaris as measured by optical coherence tomography angiography. *Am J Ophthalmol* 2016; 168: 95–109.
- Samara WA, Say EAT, Khoo CTL, et al. Correlation of foveal avascular zone size with foveal morphology in normal eyes using optical coherence tomography angiography. *Retina* 2015; 35: 2188–2195.
- Coscas F, Sellam A, Glacet-Bernard A, et al. Normative data for vascular density in superficial and deep capillary plexuses of healthy adults assessed by optical coherence tomography angiography. *Invest Ophthalmol Vis Sci* 2016; 57: OCT211–OCT223.
- Fernández-Vigo JI, Kudsieh B, Shi H, et al. Normative database and determinants of macular vessel density measured by optical coherence tomography angiography. *Clin Exp Ophthalmol* 2020; 48: 44–52.
- Guo J, She X, Liu X, et al. Repeatability and reproducibility of foveal avascular zone area measurements using AngioPlex spectral domain optical coherence tomography angiography in healthy subjects. *Ophthalmologica* 2017; 237: 21–28.
- Shihara H, Sakamoto T, Yamashita T, et al. Reproducibility and differences in area of foveal avascular zone measured by three different optical coherence tomographic angiography instruments. *Sci Rep* 2017; 7: 1–8.
- Wylegała A, Wang L, Zhang S, et al. Comparison of foveal avascular zone and retinal vascular density in healthy Chinese and caucasian adults. *Acta Ophthalmol* 2020; 98: e464–e469.
- Dai W, Chee ML, Majithia S, et al. Agreement in measures of macular perfusion between optical coherence tomography angiography machines. *Sci Rep* 2020; 10: 1–6.
- Yilmaz H, Karakurt Y, Icel E, et al. Normative data assessment of vessel density and foveal avascular zone metrics using AngioScan software. *Curr Eye Res* 2019; 44: 1345–1352.
- Yanes LL and Reckelhoff JF. Postmenopausal hypertension. *Am J Hypertens* 2011; 24: 740–749.

29. Takayama K, Kaneko H, Ito Y, et al. Novel classification of early-stage systemic hypertensive changes in human retina based on OCTA measurement of choriocapillaris. *Sci Rep* 2018; 8: 1–13.
30. Tan CS, Lim LW, Chow VS, et al. Optical coherence tomography angiography evaluation of the parafoveal vasculature and its relationship with ocular factors. *Invest Ophthalmol Vis Sci* 2016; 57: OCT224–OCT234.
31. Lee SH, Lee WH, Lim Hb, et al. Thicknesses of central macular, retinal nerve fiber, and ganglion cell inner plexiform layers in patients with hypertension. *Retina* 2019; 39: 1810–1818.
32. Scuderi G, Fragiotta S, Scuderi L, et al. Ganglion cell complex analysis in glaucoma patients: what can it tell us? *Eye Brain* 2020; 12: 33–44.
33. Shoji T, Kanno J, Weinreb RN, et al. OCT Angiography measured changes in the foveal avascular zone area after glaucoma surgery. *Br J Ophthalmol* 2020: 1–7.