

Hutchinson-Gilford Progeria Syndrome

*Jhon Camacho-Cruz¹, Luz Dary Gutiérrez-Castañeda², Daniela Pulido³, Catalina Echeverri³, Betty Bernal³, Luisa Bautista³, Lizeth Angarita³, Andrés Villamil³, Laura Guarín³, Vanessa Benavides³, Natalia Lancheros³, Juan Pardo³, Mónica Bautista³

¹MD Pediatrician, Associate Instructor Department of Pediatrics, Fundación Universitaria de Ciencias de la Salud (FUCS), Bogotá, D.C. Colombia. Grupo de Investigación Materno – Infantil. Línea Pediatría.

²MSc. in Human Genetics, Biotechnology Doctor (c), Assistant Professor, Department of Genetics, Fundación Universitaria de Ciencias de la Salud (FUCS), Bogotá, D.C. Colombia. Grupo de Investigación Ciencias Básicas en Salud.

³Medical Student, Grupo de Investigación Ciencias Básicas en Salud y Grupo de Investigación Materno – Infantil. Línea Pediatría. Fundación Universitaria de Ciencias de la Salud (FUCS), Bogotá, D.C. Colombia.

Abstract

The Hutchinson-Gilford syndrome or progeria is a laminopathy generated by mutations that affect LMNA gene. This produces an abnormal protein named progerine which alters the formation of the cellular membrane inducing premature aging of all cells. In the present review aspects related to the pathophysiology and clinical characteristics of this syndrome are shown.

Key Words: Hutchinson-Gilford, Aging, Lamins Progeria, Pediatrics.

*Please cite this article as: Camacho-Cruz J, Dary Gutiérrez-Castañeda L, Pulido D, Echeverri C, Bernal B, Bautista L, et al. Hutchinson-Gilford Progeria Syndrome. Int J Pediatr 2019; 7(10): 10283-289. DOI: **10.22038/ijp.2019.42913.3592**

*Corresponding Author:

Jhon Camacho MD Pediatrician, Hospital de San José (Bogotá, Colombia), Department of Pediatrics, Grupo de Investigación Materno – Infantil. Línea Pediatría. Address Cra 19 No. 8A - 32, Bogotá D.C. Colombia.

Email: jhcamacho@fucsalud.edu.co

Received date: Mar.15, 2019 ; Accepted date: Aug.22, 2019

1- Introduction

Hutchinson-Gilford Progeria syndrome (HGPS) is a monogenic disorder that alters the components of the nuclear membrane, classifying it as a laminopathy. The affected gene is LMNA which encodes glycoprotein laminin A. It is a low frequency disease that is correlated to severe morbidity and high mortality, as a consequence of accelerated irreversible atherosclerosis of the coronary and cerebral arteries (1). This leads to premature death during the first and second decade of life. Furthermore, these patients present stunted growth, muscular atrophy, and skin atrophy, loss of subcutaneous fat, osteoporosis, arthritis, alopecia, cataracts, diabetes, hyperlipidemia, and occasionally tumors (1-3). Search information was done using the terms "hutchinson gilford progeria" in ScienceDirect and PubMed search engine. Published studies were included, with no time limit, restricted by age to children under 18 years of age. The results are presented in a narrative manner. The initial phase began with the terms "hutchinson gilford progeria", "pediatrics" and "genetics" in English and Spanish obtaining 1059 results. The selection was made by type of article (review articles), which were selected according to the abstract, relevance and free access. Likewise, two web pages were included. Finally, we used 26 titles referred by the experience of the researchers.

2- Definition

Hutchinson-Gilford syndrome, or progeria, was described for the first time in 1886 by Dr. Jonathan Hutchinson in England. Afterwards, in 1897, Dr. Hastings Gilford described a second case, according to which the syndrome is named in honor of both clinicians (1). It is a member of the progeroid syndromes, a group of diseases which have premature physiological aging in common (2).

3- Epidemiology

The reported incidence rate is approximately 1 for each 4 to 8 million inhabitants (3-4). In 2017 *Progeria Research Foundation* found that there are 144 cases in 45 countries, of which 112 children have classic Hutchinson Gilford progeria, and 32 have some progeroid laminopathy (5).

4- Physiopathology

The gene LMNA encodes type A and C lamina (intermediate filamentous proteins). The name is due to proteins which have a diameter of 10 nm, less than microtubules, but more than actin filaments, which are located above the internal nuclear membrane. LMNA encodes 4 types of laminar proteins, through alternative cutting and splicing (A, C, C alpha, C2), and lamina A and C are similar up to residue position 574. Lamin A has precursor prelamin A, subsequent to post-translational processing, and generating the mature protein (6). This protein's functions range from constructing part of the nuclear cellular architecture, to regulating multiple nuclear functions (6, 7).

5- Nuclear lamina

The major structural proteins of the lamina are intermediate type V filaments: the nuclear lamina. According to their sequence and structural properties lamina are classified in type-A (LA and LC), and in type-B (LB1 and LB2) lamina (8). Type A and C lamina are expressed mainly as differentiated cells. These filaments are translocated from the cytoplasm inside the nucleus and are assembled before incorporation into the protein network, or nucleoplasmic veil. The lamina structures that compose the veil are bonded to chromatin, and through changes in said structure, modulate the transcription of genes (7, 9). The nuclear lamina presents multiple functions such as: mechanical support of the nucleus, organization of

chromatin, gene regulation, DNA repair and mechanotransduction (9-10).

6- Laminopathy

There is a greatly varied presentation of laminopathies given the presentation of allelic heterogeneity, variable expressivity, and complete and incomplete penetrance. One mutation in the gene LMNA that causes HGPS consists of the de novo substitution of exon 11 of LMNA (c.1824C>T), which produces activation of a cryptic splice site. It alters the reading frame, given the generation of the deletion of 50 amino acids in the extreme C-terminal of prelamin A (**Figure.1**). The formal abnormal protein produced, known as 'progerin', retains the CAAX motif,

becoming farnesylated and carboxymethylated. These post-translational modifications should be removed in the mature protein, moreover, progerine lacks the second site of endoproteolytic cleavage, through which farnesylation and carboxymethylation occur permanently. This mutant form of lamin A serves mainly to cause an entire spectrum of abnormalities in nuclear processes. Even though c.1824C>T is the most frequent mutation in patients with HGPS, other mutations reported for gene LMNA have resulted in greater use of this cryptic splicing site. Some of these mutations determine a more severe phenotype than in classic HGPS (11, 13).

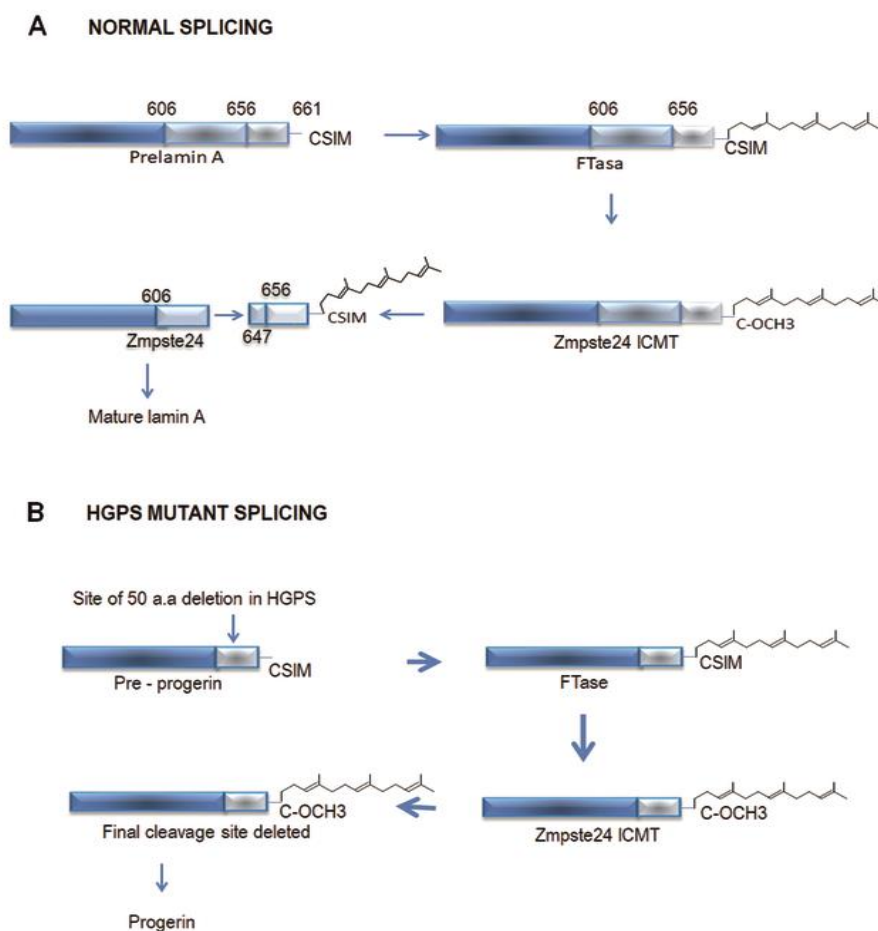


Fig.1: Production of Lamin A and Progerin.

Progerin accumulates in the nuclear membrane, and these changes in the laminar dynamic alter mechanical properties and signaling mechanics, which affect signaling pathways and genetic expression. In this manner, progerin contributes to differentiation and self-renewal defects in adult stem cells, which produce a defective extracellular matrix

and generate cellular senescence (13, 14). The progressive accumulation of progerin in the internal nuclear membrane leads to immobility of lamin A, thickening, and altering of lamin stiffness, generating lobules or folds in the nuclear envelope. These damages lead to a vulnerable nucleus that is prone to physical stress (11, 13-16) (**Figure.2**).

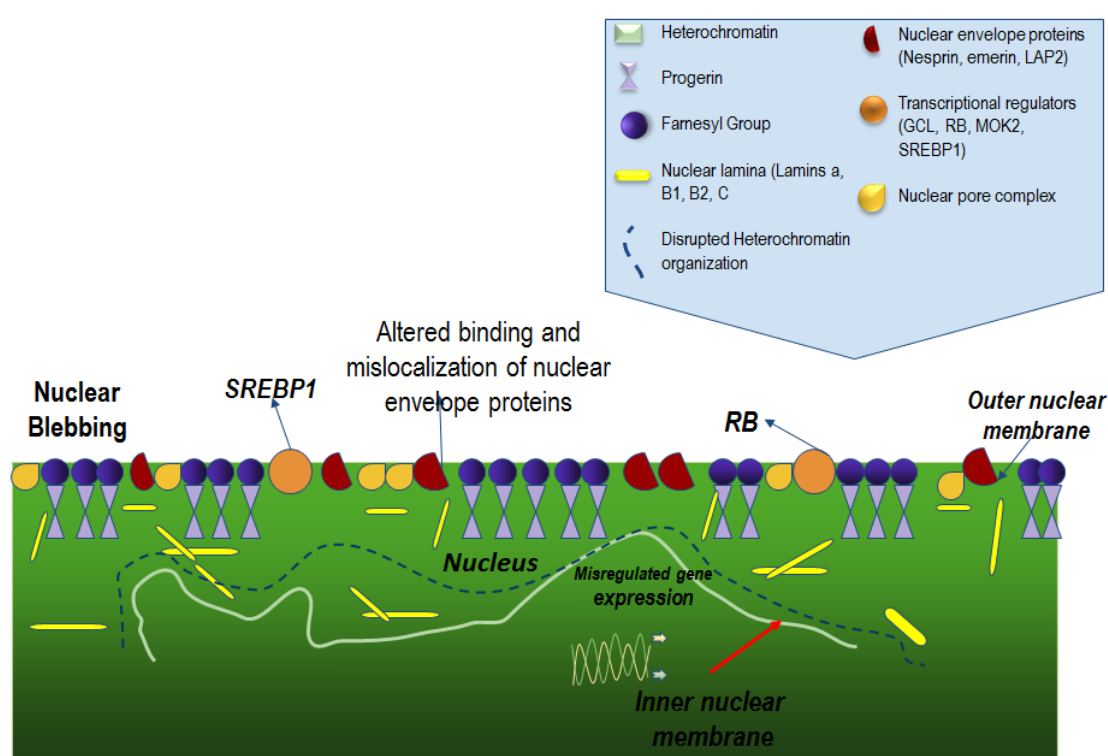


Fig.2: Alterations in nuclear lamina.

Type-A lamin may directly interact with DNA, histones, and chromatin proteins bonded to lamina A. It has also been implicated in the organization of higher-order chromatin, the formation of heterochromatin and epigenetic regulation (2). Type-A lamina contributes to the bonding of heterochromatin genomic regions, denominated as lamina-associated domains (LAD's) of nuclear lamina. It also interacts with promoter regions, and in this way modulates genetic expression during cellular differentiation. Therefore, the HGPS nuclei loss of the peripheral heterochromatin, lessening of the repressor histone marks H3K9me3 y H3K27me3,

and an increase in H4K20me3 (2). Changes in the modification of histone, DNA methylation, chromatin architecture and modification of cells expressing progerin have all been reported. In HGPS there is a loss of the peripheral heterochromatin and diminished levels of modification in repressor histones (H3K9me3, H3K27me3). Additionally, there is an increase in the transcription of sequences that contain pericentromeric repeats. All these changes are reported for individuals of advanced age, and for this reason progerin has been related to premature aging (2).

7- Clinical Manifestations

The first signs to appear in patients affected by progeria are mainly cutaneous, with variable severity. Among these signs we find: regions of hyperpigmentation, mottled skin, tenseness in certain areas which reduce movement, and cutaneous masses that are usually small and soft (1 to 2 cm) in the torso or the lower limbs. Alopecia is one of the most common symptoms. Children are born with normal hair on the head, and demonstrate hair growth, usually without alteration. However, in the first years of life the hair begins to fall out and is substituted by immature sparse hair growth. There is also usually complete loss of the eyebrows and the eye lashes. The skin is usually very thin, and it becomes possible to see through it and see the blood vessels (17).

Another of the main reasons for screening in the first year of life is growth delay. Children with HGPS present normal fetal and early post-natal development. In the first year of life, alterations of growth, body structure, and weight are detected. Additionally, general lipotrophy and atrophy of the limbs, cyanosis, and prominent veins in the torso, neck, and scalp are present. In general, children with progeria achieve a final average height of 1 meter, an average final weight of 14 kg, and normal cephalic perimeter. The loss of subcutaneous fat produces hypothermia (17). Other characteristics are: xerophthalmia, difficulty in fully closing the eye lids, and exposure keratopathy and/or corneal ulcers affecting vision (17-18). Dental alterations are frequent, and there is a delay in dentition and dental crowding, with micrognathia (17-19). In terms of bone development, in patients affected by skeletal dysplasia there is acro-osteolysis in the distal phalanges, and bone reabsorption (clavicles and ribs) by which pyriform thorax is produced. In the lower limbs there is a remodeling of the long

bones, above the femur due to knee flexion contracture (17).

Primary vasculopathy characterized by accelerated global arterial stiffness is found, posterior to which there is occlusive disease of the arteries through early formation of atherosclerotic plaque. In patients with HGPS, in the terminal stages of cardiovascular disease, hypertension, valvulopathies, ischemic disease, cardiomegaly, metabolic syndrome, and heart failure are observed. Vascular disease is also seen in cerebral blood vessels responsible for strokes in patients. This represents the second cause of death from the disease, after acute myocardial infarction (17-20).

8- Diagnosis

The diagnosis for HGPS is clinical, performed with the subsequent screening of gene mutation LMNA. Presently, there are no laboratory tests in serum that suggest HGPS. Nevertheless, the most frequent sign in patients has been the increase of excretion of hyaluronic acid in urine. Some studies have found urinary excretion 10-20 times greater for hyaluronic acid, in patients with HGPS with respect to controls. Hyaluronic acid is a non-sulfated glycosaminoglycan maintaining skeletal, muscular, cutaneous, and vascular integrity and texture. These hyaluronic acid abnormalities may account for hardened collagen, calcification of the arterial walls, and changes in the skin which look very much like scleroderma (20-21). On a genetic level, the screening of correlated mutations is performed by sequencing of gene LMNA (6-9).

9- Treatment

Presently, HGPS has no cure, and there has been no success in finding a specific treatment. However, some options exist that attempt to increase the quality of life in patients, their prognosis, and comorbidities that affect and are finally responsible for premature death. It is

important to remember, that in spite of available therapeutic options these do not change the course of the disease (22-24). In 2007, the first clinical trial to treat progeria consisted of administering medication, Lonafarnib ®, a farnesylation inhibitor of progerin, to 26 children aged between 3 and 15 years. An improvement in the stiffness of the vascular wall was demonstrated, leading to an increase of the flexibility of the blood vessels. An improvement in weight gain, hearing, and bone structure was also described. However, these effects did not occur in all patients (22). In April 2016 another clinical trial was initiated using Everolimus®, an analogue of rapamycin. The results demonstrated the safety of Everolimus®, and clarified the elimination of progerin, as it may reestablish the abnormal form of the cell nucleus, and thus, extend the cells' half-life (23). Other options for treatment include statins, bisphosphonate, pravastatin® and zoledronate®. They are on course to demonstrate the morphology of the cell membrane, reducing levels of cholesterol, and increasing weight and bone density. Furthermore, it is important to ensure adequate feeding, a low-fat diet to reduce the risk of cardiovascular events, and integral psychological support (24).

10- Prognosis

The main factor which affects mortality in patients with HGPS is cardiovascular disease. Acute myocardial infarction and congestive heart failure represent 75% of cases of death in these patients. In the first 5 years of life cardiovascular affectation is minimum but starting at the age of 6 years the respiratory symptoms are observed. In autopsies, the most common sign is disseminated atherosclerosis (25-26). Also, the cerebrovascular arteriopathy and strokes have been linked to high mortality in these patients. Additionally, in 60% of individuals, silent stroke was registered as being characteristic of progeria, and thus,

is also one of the main causes of premature death in patients (27).

11- Conclusion

HGPS has been correlated to premature death during the first and second decade of life, due to accelerated atherosclerosis of the coronary and cerebral arteries (1-2, 6). This is a complex pathology which requires complete engagement with the patient and patient's family. Genetic and functional studies must continue, allowing for available therapeutic options for this disease. Current studies have shown an improvement in the morbidity and mortality of this population group.

12- CONFLICT OF INTEREST: None.

13- REFERENCES

1. Brune T, Bonne G, Denecke J, Elcioglu N, Hennekam RC, Marquardt T, et al. Progeria: a new kind of Laminopathy--report of the First European Symposium on Progeria and creation of EURO-Progeria, a European Consortium on Progeria and related disorders. *Pediatric endocrinology reviews: PER*. 2004; 2(1):39-45.
2. Arancio W, Pizzolanti G, Genovese SI, Pitrone M, Giordano C. Epigenetic involvement in Hutchinson-Gilford progeria syndrome: a mini-review. *Gerontology*. 2014; 60(3):197-203.
3. Pollex RL, Hegele RA. Hutchinson-Gilford progeria syndrome. *Clinical genetics*. 2004; 66(5):375-81.
4. Viégas J, Souza PL, Salzano FM. Progeria in twins. *J Med Genet*. 1974; 11(4):384-6. 11.
5. GraVoc. Progeria Research Foundation [Internet]. Estados Unidos de America: PRF. Disponible en: <https://www.progeriaresearch.org/>.
6. Swahari V, Nakamura A. Speeding up the clock: The past, present and future of progeria. *Development, growth & differentiation*. 2016; 58(1):116-30.
7. Lattanzi G, Marmioli S, Facchini A, Maraldi NM. Nuclear damages and oxidative stress: new perspectives for laminopathies. *Eur*

- J Histochem. 2012; 56(4):e45. doi: 10.4081/ejh.2012.e45.
8. Shimi T, Kittisopikul M, Tran J, Goldman AE, Adam SA, Zheng Y, Jaqaman K, Goldman RD. Structural organization of nuclear lamins A, C, B1, and B2 revealed by superresolution microscopy. *Molecular biology of the cell*. 2015; 26(22):4075-86.
9. Booth-Gauthier EA, Du V, Ghibaud M, Rape AD, Dahl KN, Ladoux B. Hutchinson-Gilford progeria syndrome alters nuclear shape and reduces cell motility in three dimensional model substrates. *Integrative Biology*. 2013; 5(3):569-77.
10. González Morán MG. Síndrome de Progeria de Hutchinson-Gilford. Causas, investigación y tratamientos farmacológicos. *Educación química*. 2014; 25(4):432-9.
11. Andriani GA, Vijg J, Montagna C. Mechanisms and consequences of aneuploidy and chromosome instability in the aging brain. *Mechanisms of ageing and development*. 2017; 161: 19-36.
12. Vidak S, Kubben N, Dechat T, Foisner R. Proliferation of progeria cells is enhanced by lamina-associated polypeptide 2 α (LAP2 α) through expression of extracellular matrix proteins. *Genes & development*. 2015; 29(19):2022-36.
13. Coutinho HD, Falcão-Silva VS, Gonçalves GF, da Nóbrega RB. Molecular ageing in progeroid syndromes: Hutchinson-Gilford progeria syndrome as a model. *Immunity & Ageing*. 2009; 6(1):4.
14. Wang K, Das A, Xiong ZM, Cao K, Hannenhalli S. Phenotype-dependent coexpression gene clusters: Application to normal and premature ageing. *IEEE/ACM transactions on computational biology and bioinformatics*. 2014; 12(1):30-9.
15. Vidak S, Foisner R. Molecular insights into the premature aging disease progeria. *Histochemistry and cell biology*. 2016; 145(4):401-17.
16. Finley J. Alteration of splice site selection in the LMNA gene and inhibition of progerin production via AMPK activation. *Medical hypotheses*. 2014; 83(5):580-7.
17. Gordon L. Síndrome de progeria de Hutchinson-Gilford in: Kliegman R. Stanton B. St. Geme J. et al. *Nelson Tratado de pediatría*. 20.^a Edición. España: Elsevier: 2016.
18. Gordon LB, Brown WT, Collins FS. Hutchinson-Gilford progeria syndrome. InGeneReviews® [Internet] 2019 Jan 17. University of Washington, Seattle.
19. Saigal S., Bhargava A. Progeria: pathogenesis and oral manifestation--a review. *Kathmandu Univ Med J (KUMJ)*. 2012; 10(37):72-6.
20. Gerhard-Herman M., Smoot L.N., Wake N et al. Mechanisms of premature vascular aging in children with Hutchinson-Gilford progeria syndrome. *Hypertension*. 2012; 59(1):92-7.
21. Pardo RA, Castillo S. Progeria. *Revista chilena de pediatría*, 2002; 73(1), 5-8.
22. Gordon LB, Kleinman ME, Miller DT, Neuberg DS, Giobbie-Hurder A, Gerhard-Herman M, Smoot LB, Gordon CM, Cleveland R, Snyder BD, Fligor B. Clinical trial of a farnesyltransferase inhibitor in children with Hutchinson-Gilford progeria syndrome. *Proceedings of the National Academy of Sciences*. 2012; 109(41):16666-71.
23. Cao K, Graziotto JJ, Blair CD, Mazzulli JR, Erdos MR, Krainc D, Collins FS. Rapamycin reverses cellular phenotypes and enhances mutant protein clearance in Hutchinson-Gilford progeria syndrome cells. *Science translational medicine*. 2011; 3(89):89ra58-.
24. Progeriaresearch.org [internet]. Boston: Progeria Research Foundation; 2016 [actualizado 26 Sep 2017; citado 20 Oct 2017]. Disponible en: <https://www.progeriaresearch.org/clinical-trials/>.
25. Qi YC. Xie XH. Hutchinson-gilford progeria syndrome and its relevance to cardiovascular diseases and normal aging. *Biomed Environ Sci*. 2013; 26(5):382-9.
26. Lessel D, Kubisch C. Hereditary Syndromes with Signs of Premature Aging. *Dtsch Arztebl Int*. 2019; 22; 116(29-30):489-96.
27. Silvera VM, Gordon LB, Orbach DB, Campbell SE, Machan JT, Ullrich NJ. Imaging characteristics of cerebrovascular arteriopathy and stroke in Hutchinson-Gilford progeria syndrome. *American Journal of Neuroradiology*. 2013; 34(5):1091-7.