



Arterial Pressure Management in a Reconstructive Microsurgery Patients by Dopamine Infusion in a Nonintensive Care Ward

Linda Martellani, MD
 Chiara Stocco, MD
 Giovanni Papa, MD, PhD
 Nadia Renzi, MD
 Vittorio Ramella, MD
 Zoran Marij Arnež, MD, PhD

BACKGROUND

Free flap perfusion and arterial pressure management have always had a crucial role in free flap reconstruction. Blood pressure values requested can be reached either by using vasoactive agents or fluid replacement or the combination of both.^{1,2}

In contrast to the most frequently tested phenylephrine, norepinephrine, and dobutamine,^{3,4} this work evaluates dopamine efficacy in perioperative blood pressure management.

In our institution, dopamine infusion is the only vasoactive agent authorized in a non-intensive care unit department. This drug stimulates α - and β -adrenergic receptors with positive chronotropic and inotropic effects and reduces peripheral vascular resistance helping in this way to achieve an increase of blood pressure and free flap perfusion.⁵

METHODS

One hundred forty-five patients who underwent free flap reconstruction from 2008 to 2014 were analyzed: 37 did not sign the privacy consent and 18 showed incomplete data. In total, 90 patients (39 breast

reconstruction, 33 head and neck reconstruction, 12 upper and lower limb reconstruction, and 6 sex reassignment) were included retrospectively.

Patients' vital signs (blood pressure, cardiac frequency, temperature, and urinary output) were monitored every hour in the perioperative period. An accurate fluid balance was provided hourly focusing on input and output of fluids, considering hydration, diuresis, blood loss, and perspiration insensibilis.

When mean blood pressure was <75 mm Hg, the cardiac rate was 80–100 BPM and the urinary output, >1 mL/kg/min; despite the infusion therapy, dopamine was infused at 5–10 g/kg/min dose.

The longitudinal linear mixed effect model was used to evaluate mean pressure trend, and the R-Software was used for the statistical analysis. The comparison between the pressure values was assessed with the Tukey test for multiple comparison (post-hoc analysis). A P value <0.05 (two-tailed) was considered statistically significant.

RESULTS

Dopamine has been used to reach the pressure target in 35 out of 90 patients: 9 men and 26 women (Table 1).

From the Department of Plastic and Reconstructive Surgery, Hospital of Cattinara, "A.O.U. Ospedali Riuniti," Trieste, Italy.

Presented at the 64th Annual Meeting of the SICPRE, September 17–19, 2015, Milan, Italy.

Copyright © 2016 The Authors. Published by Wolters Kluwer Health, Inc. on behalf of The American Society of Plastic Surgeons. All rights reserved. This is an open-access article distributed under the terms of the Creative Commons Attribution-Non Commercial-No Derivatives License 4.0 (CCBY-NC-ND), where it is permissible to download and share the work provided it is properly cited. The work cannot be changed in any way or used commercially.

Plast Reconstr Surg Glob Open 2016;4:e656; doi:10.1097/GOX.0000000000000633; Published online 18 March 2016.

Table 1. Study Data Are Analyzed

	Only Fluid Therapy	Dopamine
Mean age	66	54
Mean blood pressure	97	92
Surgical complications	9	3

SICPRE: La SICPRE, Società Italiana di Chirurgia Plastica Ricostruttiva ed Estetica, national meeting, in Milano, Italy on September 17–19, 2015.

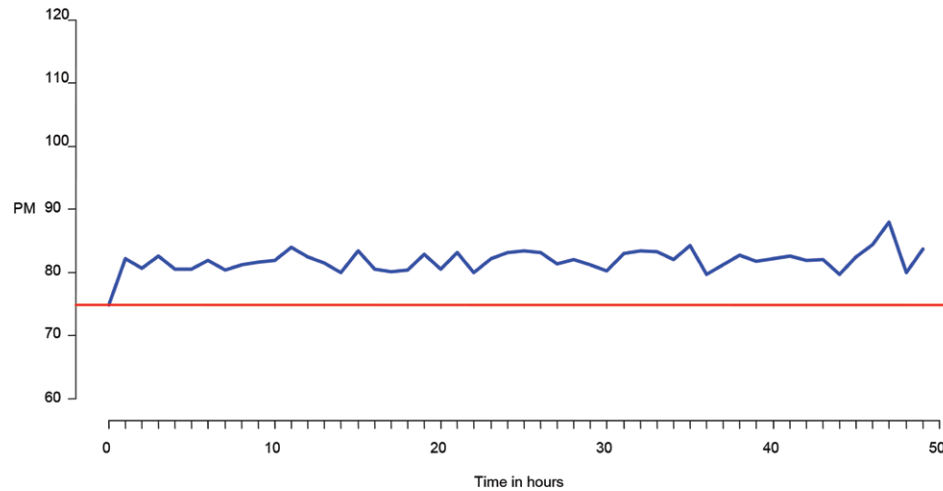


Fig. 1. Mean blood pressure trend is displayed.

The primary outcome of interest was mean blood pressure trend after dopamine infusion. The overall increase of mean pressure after dopamine infusion (T0 = starting infusion) has always been superior to the T0 value, with statistical significance ($P < 0.001$). In particular, a clear mean pressure increment, 1 hour after dopamine administration, was registered ($P < 0.01$) followed by variation superior to the cut off value for the following 50 hours of observation due to the individual response (Fig. 1).

We registered 1 case of tachycardia and 1 case of nausea and headache (the latter due to infusion pump malfunction), managed by interruption of the dopamine infusion. Furthermore, we report 1 case of oxygen desaturation, with mild pulmonary edema due to an aggressive fluid therapy.

The secondary outcome was evaluation of surgical complications (hematoma and microvascular anastomosis problems). Reintervention was performed in 3 dopamine cohort patients versus 9 of the fluid therapy cohort. Comorbidities and drug therapy were not statistically different between the cohorts.

CONCLUSION

In our experience, dopamine infusion represents a good option for arterial pressure manage-

Disclosure: The authors have no financial interest to declare in relation to the content of this article. The Article Processing Charge was supported by a grant of family Pascone, in memory of Professor Michele Pascone, MD.

ment in free flap reconstruction. It can maintain an adequate flap perfusion by blood pressure modulation without major side effects. Despite these promising results, this topic will continue to be a matter of debate until more definitive data are obtained.

Zoran Marij Arnez, MD, PhD

Department of Plastic and Reconstructive Surgery
Ospedale di Cattinara
Azienda Ospedaliero-Universitaria
Ospedali Riuniti di Trieste
Strada di Fiume 447, 34149 Trieste, Italy
E-mail: zoran.arnez@aots.sanita.fvg.it

REFERENCES

1. Kelly DA, Reynolds M, Crantford C, et al. Impact of intraoperative vasopressor use in free tissue transfer for head, neck, and extremity reconstruction. *Ann Plast Surg.* 2014;72:S135–S138.
2. Tocantins LM, Carroll RT, Holburn RH. The clot accelerating effect of dilution on blood and plasma. Relation to the mechanism of coagulation of normal and hemophilic blood. *Blood.* 1951;6:720–739.
3. Eley KA, Young JD, Watt-Smith SR. Epinephrine, norepinephrine, dobutamine, and dopexamine effects on free flap skin blood flow. *Plast Reconstr Surg.* 2012;130:564–570.
4. Eley KA, Young JD, Watt-Smith SR. Power spectral analysis of the effects of epinephrine, norepinephrine, dobutamine and dopexamine on microcirculation following free tissue transfer. *Microsurgery.* 2013;33:275–281.
5. Suominen S, Svartling N, Silvasti M, et al. The effect of intravenous dopamine and dobutamine on blood circulation during a microvascular TRAM flap operation. *Ann Plast Surg.* 2004;53:425–431.