

Journal of

Gastroenterology and Hepatology Research

Online Submissions: <http://www.ghrnet.org/index./joghr/>
doi: 10.17554/j.issn.2224-3992.2016.05.631

Journal of GHR 2016; 5(2): 2038-2040
ISSN 2224-3992 (print) ISSN 2224-6509 (online)

CASE REPORT

Reactivation of Hepatitis B in a Patient with Breast Cancer Treated Using Capecitabine

Marco Fiore, Ivo Maria Crosato, Rossana Bussani, Romina Valentinotti, Marta Mascarello, Roberto Luzzati

Marco Fiore, Ivo Maria Crosato, Romina Valentinotti, Marta Mascarello, Roberto Luzzati, Unit of Infectious Diseases, University Hospital, Trieste, Italy

Rossana Bussani, Department of Pathologic Anatomy, University of Trieste Medical School, Trieste, Italy

Correspondence to: Marco Fiore, MD, Unit of Infectious Diseases, University Hospital, 1 Piazza Ospitale, 34134, Trieste, Italy.

E-mail: marco.fiore@hotmail.it

Telephone: +39 040 399 2655 Fax: +39 040 399 2652

Received: October 29, 2015 Revised: December 10, 2015

Accepted: December 15, 2015

Published online: April 21, 2016

and *Hepatology Research* 2016; 5(2): 2038-2040 Available from:
URL: <http://www.ghrnet.org/index.php/joghr/article/view/1454>

INTRODUCTION

Hepatitis B virus reactivation (HBVr) is increasingly recognized as a clinical problem and has associated significant morbidity and mortality. Conversely, the International Guidelines for HBV screening in patients undergoing immunosuppressive drug therapy (ISDT) are controversial: The *American Association for the Study of Liver Diseases* guidelines recommend both HBsAg and antiHBc testing in patients who are at high risk of HBV infection prior to initiation of ISDT^[1], The European Association for the Study of the Liver guidelines recommend that all candidates to ISDT should be screened for HBsAg and antiHBc prior to initiation of treatment^[2], The Asian Pacific Association for the Study of the Liver recommends that patients who are going to receive biological agent such as anti-CD 20 or anti-tumor necrosis factor should be screened for both HBsAg and antiHBc. In case of antiHBc positivity, HBV-DNA should be closely monitored and treatment with nucleoside/nucleotide analogue (NA) should be started when needed^[3]. Recently, the American Gastroenterological Association guidelines recommend screening for HBV (HBsAg and antiHBc, followed by a sensitive HBV-DNA test in case of positivity for either one or the other test, or both tests) in patients at moderate or high risk who will undergo ISDT, so the HBV screening may be cost-effective in patients with breast cancer slated to receive adjuvant chemotherapy if HBV infection is prevalent^[4].

About 20% of untreated HBsAg-positive patients with breast cancer undergoing chemotherapy develop HBVr, in these studies anthracycline-based therapy was used by all investigators^[5-7] and glucocorticoids were routinely administered in 2 studies. Despite in literature capecitabine does not result in acute hepatitis B reactivation^[8]; we report a case of HBVr leading to *exitus in a female patient with breast cancer treated using capecitabine*.

ABSTRACT

Reactivation of hepatitis B virus (HBV) is a well-recognized complication following immunosuppressive drug therapy in patients with past infection. The International Guidelines for HBV screening before cytotoxic or immunosuppressive therapy are controversial, there is only agreement on the use of biological agent such as anti-CD 20. The literature data do not report HBV reactivation due to capecitabine and therefore the international guidelines do not recommend prophylaxis in that condition. In this paper, we describe the history of HBV reactivation of hepatitis B in a female patient with breast cancer treated using capecitabine observed in a Unit of Infectious Diseases of north-est of Italy.

© 2016 The Authors. Published by ACT Publishing Group Ltd.

Key Words: Hepatitis B virus reactivation (HBVr); Capecitabine; breast cancer; Tenofovir; Immunosuppressive drug therapy (ISDT); Acute liver failure (ALF)

Fiore M, Crosato IM, Bussani R, Valentinotti R, Mascarello M, Luzzati R. Reactivation of Hepatitis B in a Patient with Breast Cancer Treated Using Capecitabine. *Journal of Gastroenterology*

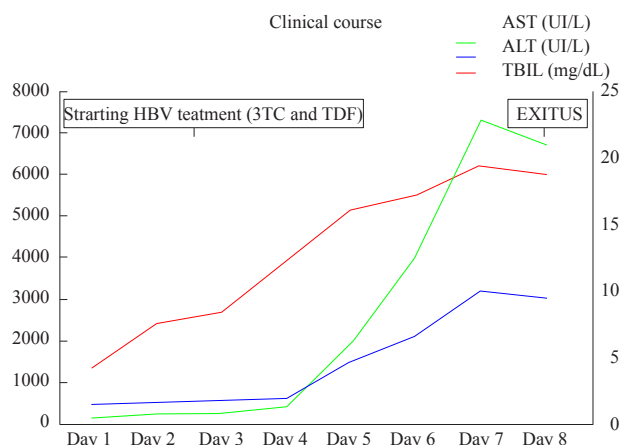


Figure 1 Clinical course characterized by a progressive increase of the indices of hepatic necrosis. AST: Aspartate aminotransferase; ALT: Alanine aminotransferase; TBIL: Total bilirubin; TDF: Tenofovir; 3TC: Lamivudine. Bilirubin values in the image to the right, transaminases to the left.

CASE REPORT

In January 2015, a 68 years old Caucasian female was evaluated at Infectious Disease Unit of University Hospital of Trieste because of worsening asthenia, loss of appetite and difficulty eating. Physical examination relieved jaundice and tenderness abdomen. The laboratory data showed a total bilirubin (TBIL) of 4.34 mg/dL (direct bilirubin 1.57 mg/dL), Alkaline phosphatase 110 IU/L, aspartate aminotransferase (AST) 172 IU/ml and alanine aminotransferase (ALT) 460 IU/ml.

About a year before the diagnosis of breast cancer, the patient suffered from bone pain. She took not specified doses of steroids prescribed by her General Practitioner in that period.

The diagnosis of invasive ductal carcinoma, Grade 2, with evidence of bone metastases was made in the Autumn of 2014.

The patient had radiation therapy for palliation of bone pain in November 2014. She was administered in a repeating cycle of total daily doses of 3500 mg of capecitabine orally in a combination therapy with 8 mg of methylprednisolone orally in December 2014 (day 17th and 30th).

The patient has never shown previously hypertransaminasemia, therefore hepatitis markers were never executed. The clinical course was characterized by a progressive increase of the indices of hepatic necrosis (Figure 1), with onset of hepatic encephalopathy (HE). We had, after 3 days of admission, the acquisition of hepatitis markers: the patient tested positive for hepatitis B surface antigen (HBsAg), HBeAg borderline and anti-hepatitis B core antibodies (HBcAb) IgG, and hepatitis A virus antibodies (HAVAb) IgG. The patient tested negative for hepatitis B surface antibody (HBsAb), HBcAb IgM, anti-human immunodeficiency virus (HIV), HAVAb IgM, anti-hepatitis C virus (HCVAb).

Levels of HBV DNA: 10 e8 IU/ml and quantitative HBsAg: 42687 IU/mL.

After the knowledge of the viral etiological profile we started immediately antiviral therapy with tenofovir (TDF, 300 mg orally once daily) and Lamivudine (3TC, 100 mg orally once daily).

The patient died of liver failure after 8 days of admission (Figure 1).

Hepatic histology was described in the autopsy report, pathologic findings: Imposing phenomena of steatosis and hepatic necrosis (Figure 2) with multiple foci of lymphocyte inflammation (Figure 3).

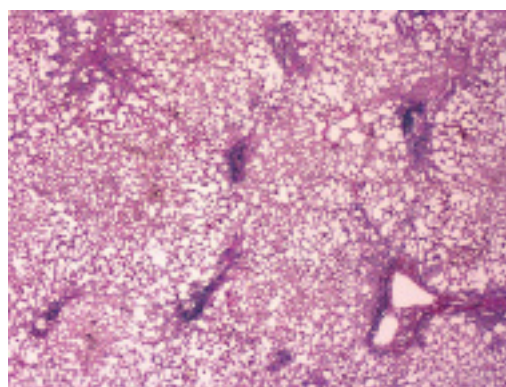


Figure 2 Portal tracts can be identified but the parenchyma has been replaced by inflammatory cells (Needle biopsy, H and E).

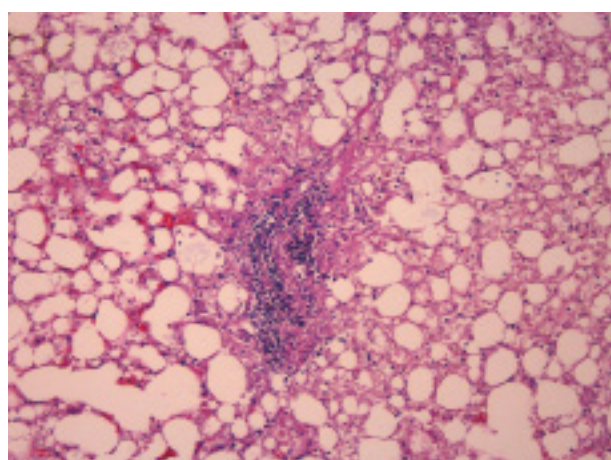


Figure 3 Heavy portal inflammatory infiltrate. Some hepatocytes have a ground-glass appearance (Needle biopsy, H and E).

DISCUSSION

HBVr in patients undergoing ISDT is a life-threatening event described in both HBsAg-positive patients (overt HBV infection)^[9] and HBsAg-negative but anti-HBc-positive patients (past HBV infection). Actually is consider as moderate/high risk of HBVr, in patients with breast cancer, the treatment based on derivatives of anthracyclines such as doxorubicin and epirubicin. No mention is made to the capecitabine^[10].

The first flaw of our report is that we don't know hepatitis markers before the admission because the patient was never tested. The low rate of screening^[11] could be related to the cost of testing, the absence of different therapeutic combinations commonly used^[4], the fact that HBV infection is not considered a major issue in cancer patients. The second flaw is that we did not exactly know the dose of steroids that the patient assumed before chemotherapy. This often happens in clinical practice in old cancer patients with many diseases associated, although 8 mg of methylprednisolone for two day of a chemo-session (17th and 30th of December 2014) represents a risk far from HBVr^[10]. Strengthening the notion that steroids could have a marginal role in HBVr of our patient Salpini *et al*^[12] in a recent large cohort study of HBV-reactivated patients, 51.7% were treated with rituximab, 34.5% with different chemotherapeutics, and 13.8% with corticosteroids. HBVr after discontinuation of ISDT was observed in about half of the patients (48.3%) and was positively correlated with patients' age. Conversely, HBVr after discontinuing immunosuppression was negatively correlated with

use of corticosteroids. Our patient reactivated in January and discontinued therapy in late December. The late onset of HBVr after discontinuation of corticosteroids could be explained by the fact that the HBV genome contains a glucocorticoid responsive element (GRE) whose stimulation enhances the rate of a stable HBV-DNA minichromosome named covalently closed circular DNA (cccDNA) transcription and, in turn, HBV replication^[13].

The incidence of HBVr is a common clinical problem in endemic regions. However, the incidence of reactivation is difficult to evaluate because of the possible absence of HBV markers testing before and during ISDT, lack of standardized nomenclature and definitions of HBVr, and variation of the sensitivity and linearity of HBV DNA assays used across studies.

Patients who received antiviral prophylaxis had less interruption of chemotherapy and lower rates of cancer-related and all-cause mortality. Thus, HBV screening before the start of ISDT is a major factor to avoid HBVr^[14], because it could be prevented by the screening of patients for HBV infection, allowing initiation of prophylactic antiviral therapy: In a recent retrospective study, based on an electronic pharmacy, Wi *et al*^[15] report the extent of HBV screening before chemotherapy and outcomes of screened patients at a tertiary oncology center. Thirteen patients were found to have HBV infection (1% among tested patients), and prophylactic antiviral therapy was used in 8 of these patients. None experienced HBVr. According to the authors, the proportion of patients in whom undiagnosed HBV infection may have been responsible for the flare appeared small. However, results for HBsAg or HBV DNA were not available; thus the real incidence of HBVr is unknown.

CONCLUSION

HBV risk tools will be necessary to reduce the risk of HBVr after chemotherapy. Guidelines for HBV screening before ISDT are controversial. Nevertheless, our case report highlights the need to re-evaluate the current HBV screening guidelines for cancer patients. HBsAg and anti-HBc assays are sensitive, specific, and widely available worldwide at a low cost. Risk-based screening is difficult to implement and can miss infected patients who do not recognize or report risk factors. So in patients whose medical history is unclear, as in our Case Report, screening could be the first life-saving procedure.

CONFLICT OF INTERESTS

There are no conflicts of interest with regard to the present paper.

REFERENCES

1. Lok AS, McMahon BJ. Chronic hepatitis B: update 2009. *Hepatology* 2009; **50**: 661-662.
2. EASL clinical practice guidelines: Management of chronic hepatitis B virus infection, *Journal of Hepatology* 2012; **57**: 167-185.
3. Liaw YF, Kao JH, Piratvisuth T *et al.* Asia-Pacific consensus state-

ment on the management of chronic hepatitis B: a 2012 update. *Hepatology International* 2012; **6**: 531-561.

4. Reddy KR, Beavers KL, Hammond SP, Lim JK, Falck-Ytter YT; American Gastroenterological Association Institute. American Gastroenterological Association Institute guideline on the prevention and treatment of hepatitis B virus reactivation during immunosuppressive drug therapy. *Gastroenterology* 2015; **148**: 215-219
5. Long M, Jia W, Li S *et al.* A single-center, prospective and randomized controlled study: Can the prophylactic use of lamivudine prevent hepatitis B virus reactivation in hepatitis B s-antigen seropositive breast cancer patients during chemotherapy? *Breast Cancer Research and Treatment* 2011; **127**: 705-712.
6. Lee HJ, Kim DY, Keam B *et al.* Lamivudine prophylaxis for hepatitis B virus carrier patients with breast cancer during adjuvant chemotherapy. *Breast Cancer* 2014; **21**: 387-393.
7. Yeo W, Chan PK, Hui P *et al.* Hepatitis B virus reactivation in breast cancer patients receiving cytotoxic chemotherapy: a prospective study. *Journal of Medical Virology* 2003; **70**: 553-561.
8. Ling WH, Soe PP, Pang AS, Lee SC. Hepatitis B virus reactivation risk varies with different chemotherapy regimens commonly used in solid tumours. *British journal of cancer* 2013; **108**: 1931-1935.
9. Sagnelli E, Pisaturo M, Martini S, Filippini P, Sagnelli C, Coppola N. Clinical impact of occult hepatitis B virus infection in immunosuppressed patients. *World Journal of Hepatology* 2014; **6**: 384-393.
10. Perrillo RP, Gish R, Falck-Ytter YT. American Gastroenterological Association Institute technical review on prevention and treatment of hepatitis B virus reactivation during immunosuppressive drug therapy. *Gastroenterology* 2015; **148**: 221-244.
11. Hwang JP1, Fisch MJ, Zhang H, Kallen MA, Routbort MJ, Lal LS, Vierling JM, Suarez-Almazor ME. Low rates of hepatitis B virus screening at the onset of chemotherapy. *Journal of Oncology Practice* 2012; **8**: e32-39.
12. Salpini R, Colagrossi L, Bellocchi MC, Surdo M, Becker C, Alteri C, Aragri M, Ricciardi A, Armenia D, Pollicita M, Di Santo F, Carioti L, Louzoun Y, Mastroianni CM, Lichtner M, Paoloni M, Esposito M, D'Amore C, Marrone A, Marignani M, Sarrecchia C, Sarmati L, Andreoni M, Angelico M, Verheyen J, Perno CF, Svicher V. Hepatitis B surface antigen genetic elements critical for immune escape correlate with hepatitis B virus reactivation upon immunosuppression. *Hepatology* 2015; **61**: 823-833.
13. Chou CK, Wang LH, Lin HM, Chi CW. Glucocorticoid stimulates hepatitis B viral gene expression in cultured human hepatoma cells. *Hepatology* 1992; **16**: 13-18.
14. Roche B, Samuel D. Universal hepatitis B virus screening in patients receiving immunosuppressive therapy: a small step for the oncologists, a major advance for prevention of hepatitis B virus reactivation. *Clinical Gastroenterology and Hepatology* 2015; **13**: 976-978.
15. Wi CI, Loo NM, Larson JJ, Moynihan TJ, Madde NR, Grendahl DC, Alberts SR, Kim WR. Low level of hepatitis B virus screening among patients receiving chemotherapy. *Clinical Gastroenterology and Hepatology* 2015; **13**: 970-975.

Peer reviewers: Changsong Zhang, PhD, Clinical Oncology Laboratory, Soochow University Affiliated Changzhou Tumor Hospital, No.1 Huai De North Rd. Changzhou, China; Myoung-Kuk Jang, Department of Internal Medicine, Kangdong Sacred Heart Hospital, Hallym University Medical Center, 445, Gildong, Kangdonggu, Seoul, Republic of Korea.