

Narrow band imaging in the intra-operative definition of resection margins in oral cavity and oropharyngeal cancer

Giancarlo Tirelli^a, Marco Piovesana^a, Annalisa Gatto^a, Margherita Tofanelli^a, Matteo Biasotto^b,
Francesca Boscolo Nata^{a,*}

^aENT Clinic, Head and Neck Department, University of Trieste, Strada di Fiume 447, 34149 Trieste, Italy

^bDivision of Oral Medicine, Dental Science Department, University of Trieste, Piazza dell'Ospitale 2, 34125 Trieste, Italy

ARTICLE INFO

Accepted 13 July 2015

Keywords:

Narrow-band-imaging
Squamous-cell-carcinoma
Oral-cancer
Oropharynx
Resection-margins
Field-cancerization

SUMMARY

Objectives: In oncological surgery, a three-dimensional resection 1.5–2 cm from the gross tumour edge is currently considered appropriate, and the status of resection margins is the most reliable indicator of radicality. Awareness of “field cancerization” calls for a re-evaluation of the benchmarks of tumour resection; however, its identification is not simple because the dysplastic areas may be far from the main lesion and difficult to recognize macroscopically. New technologies such as narrow band imaging (NBI) could improve the detection of neoplastic and pre-neoplastic areas, ensuring more precise resections. The main purpose of this study was to investigate the value of NBI in detecting pre-cancerous areas and/or cancer around the tumour bulk intra-operatively, to achieve adequate resection of the tumour.

Materials and Methods: The resection margins of 8 oral cavity and 8 oropharyngeal cancers were first drawn by macroscopic evaluation and then re-defined using NBI. Resections were performed following the NBI-drawing if extemporaneous histological examinations of the NBI-defined enlargements were positive for dysplasia or cancer. The number of clear margins was evaluated.

Results: Resections margins were free of tumour or dysplasia at extemporaneous examination; on definitive histology, two patients had a margin positive for cancer and dysplasia, respectively. Among the NBI-defined enlargements, 25% were positive for dysplasia and 75% for cancer. The sensitivity, specificity, positive and negative predictive values were 100%, 88.9%, 100% and 87.5%, respectively.

Conclusion: The method we propose could be useful for obtaining free surgical margins and reducing the potential development of tumour foci resulting from incomplete resection.

Introduction

The main goal of oncologic surgery remains the excision of the tumour, with macroscopically adequate surgical margins [1]. The current surgical standard in the oral cavity and pharynx implies a resection with a macroscopic margin of 1 cm [2–4], 1.5 cm [5] or 2 cm [6–8] in the three dimensions, both superficially and deeply, assuming that the tumour is as wide on the surface as in depth. Obtaining uninvolved margins at final histological examination is therefore currently the gold standard for surgeons, because the presence of dysplasia or carcinoma following resection of carcinoma of the head and neck, has been shown to be associated with a higher incidence of local recurrence events [9]. However, this appears particularly difficult in consideration of the peculiar frequent growth pattern of oral squamous cell carcinomas (OSCC),

defined as the “field cancerization” phenomenon. This concept assumes that multiple, unrelated, precancerous lesions may exist adjacent to the original tumour mass, each one bearing the potential to develop into a new tumour [10–12]. Although in practice the identification of these proves very challenging by routine examination, substantial progress has been made in the last ten years with the development and optimization of innovative imaging techniques allowing improved visualization of the superficial extension of the tumour [13–15].

Among these diagnostic tools, narrow band imaging (NBI) has widely demonstrated its effectiveness in helping to detect superficial mucosal lesions of the oral and pharyngeal mucosa [13,14].

The main purpose of this pilot study was to investigate the value of NBI in detecting intraoperatively pre-cancerous areas (dysplasias) and/or cancer around the clinically visible tumour bulk, in order to achieve adequate resection of the entire local tumour and maximize the number of free resection margins at definitive histological examination.

* Corresponding author. Tel.: +39 040 3994932.

E-mail address: francesca.boscolonata@gmail.com (F. Boscolo Nata).

Materials and methods

This pilot prospective study was conducted at the ENT Department of Cattinara Hospital in Trieste (Italy) in accordance with the Declaration of Helsinki, and approved by the local ethics committee.

NBI is a video endoscopic system with narrow band filters that allows for the passage of only two specific bands of the visible spectrum which correspond to the absorption peak of haemoglobin. The filtered wavelengths enhance the microvascular abnormalities associated with the preneoplastic and neoplastic changes of the mucosal lining of the upper aerodigestive tract [16]. In our study NBI was used for the intra-operative definition of resection margins in patients with oral cavity and oropharyngeal cancer to evaluate whether it could help in detecting pre-cancerous areas (dysplasias) and/or cancer around the tumour bulk intraoperatively.

Among candidates for surgery, established by a multidisciplinary panel, we decided to focus on a subset of patients who met the following inclusion criteria: age between 18 and 90 years, no previous surgery, radiotherapy or chemotherapy for head and neck cancers, no cancers located in the hypopharynx or larynx. During the first 6 months of intraoperative use of NBI, 37 patients with squamous cell carcinoma (SCC) came to our attention; among the 11 patients with a tumour located in the oral cavity, 3 were excluded because of previous surgery; among the 11 patients with oropharyngeal tumour, 3 were excluded because of previous surgery; 15 patients were excluded because the cancer was located in the hypopharynx ($n=6$) or in the larynx ($n=9$). Therefore, 16 patients with SCC of the oral cavity ($n=8$) and oropharynx ($n=8$) were finally included in the study; all of them had a biopsy-proven diagnosis of SCC and clinical staging (cTNM) obtained with computed tomography (CT) and magnetic resonance imaging (MRI), in accordance with the NCCN guidelines (National Comprehensive Cancer Network). The tumour sites and subsites and clinical staging are summarized in Table 1.

A surgeon explained to the patient that during the surgery, NBI, a new type of imaging tool, would be used to define the real extension of the lesion beyond the macroscopic margins defined both visually and by palpation, that the resection would be performed following the NBI-guided drawing if extemporaneous histological examinations of the area between the two tattoos were positive for dysplasia or cancer, and that this procedure carried no additional risks and required no specific preparation. The patients signed a detailed informed consent form, with the privacy policy agreement.

A few days before surgery, two physicians experienced in the use of NBI carried out a preliminary evaluation focusing on the

clinically negative areas around the tumour that had a suspicious appearance on NBI: this step served only the practical purpose of reducing the intraoperative time required for defining the resection margins. NBI was performed using a Visera Elite system (OTV-S190 video processor and CLV-190 light source, OTV-S7Pro-10E HDTV camera; Olympus Medical Systems Corp, Tokyo, Japan) with rigid endoscopes with a viewing angle of 70° for the oropharynx or an angle of 0° for the oral cavity. Patients were examined in a seated position; no specific patient preparation was necessary; local anaesthesia was achieved with lidocaine spray 10 g/100 ml only if necessary. During the examination, particular care was taken to avoid bleeding, which alters the penetration of light into tissue and precludes NBI evaluation. In the event that the preoperative evaluation could not be completed because of poor patient compliance or difficulty reaching the tumour with the endoscope tip, the NBI evaluation was carried out only intraoperatively. All procedures were recorded on video.

In the operating room on the day of surgery, after general anaesthesia and preparation of the surgical field, and before any surgical action involving bleeding which negatively affects NBI evaluation, a first definition of the resection margins was obtained with an electric scalpel, using a ruler to help maintain a distance of 1.5 cm from the macroscopic lesion boundaries defined visually and by palpation. Then, the two NBI experts made an additional assessment and re-defined the resection margins using the same instrument as used preoperatively. The apparently healthy mucosa surrounding the main tumour mass was considered positive at NBI evaluation if it displayed the known alterations of the intrapapillary capillary loop (IPCL), such as dilatation and crossing, elongation and meandering or pattern destruction and angiogenesis, which can underlie histological changes (Fig. 1) [17–19]. This evaluation increased the operating time by an average of 5 min. The different steps were video recorded (Fig. 2).

The two templates were then compared and the distance between them measured; if a difference between them was found, several biopsies were obtained from the area between the white-light (WL) and NBI tattoos which showed the most suspicious vascular changes (Fig. 3), and they were sent to a dedicated pathologist for extemporaneous histological examination. We decided to use a combination of NBI positivity and positive result of frozen sections collected in these areas to guide the resection margins because this was a pilot study and defining the margins on NBI appearance alone would not have been ethical given the

Table 1
Patients and tumours' characteristics.

Id	Site	Subsite	cTNM
1	Oral cavity	Floor of mouth	T2N0M0
2	Oropharynx	Tonsil, base of tongue	T3N2bM0
3	Oropharynx	Tonsil	T2N1M0
4	Oral cavity	Floor of mouth	T2N1M0
5	Oral cavity	Floor of mouth	T2N2cM0
6	Oropharynx	Tonsil, soft palate	T3N1M0
7	Oral cavity	Anterior tongue	T1N0M0
8	Oral cavity	Floor of mouth, anterior tongue	T3N0M0
9	Oropharynx	Tonsil, soft palate	T3N1M0
10	Oral cavity	Floor of mouth, anterior tongue	T4aN2bM0
11	Oropharynx	Tonsil, soft palate	T1NxM0
12	Oral cavity	Floor of mouth	T2N0M0
13	Oropharynx	Tonsil	T4aN2bM0
14	Oropharynx	Retromolar trigone	T3N2aM0
15	Oropharynx	Soft palate	T2N2bM0
16	Oral cavity	Anterior tongue	T3N0M0

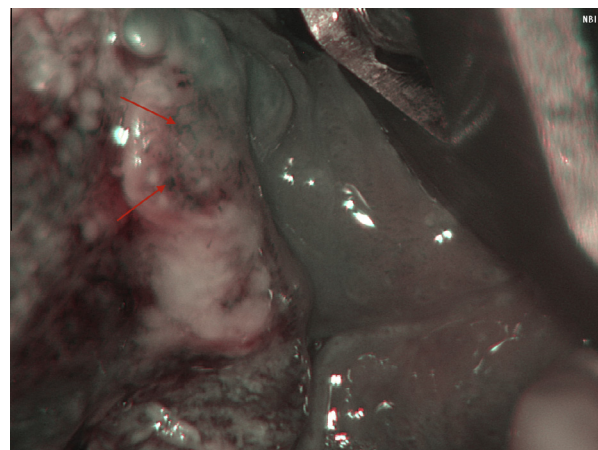


Fig. 1. Vegetating lesion of the posterior left tongue margin: arrows indicate altered intra-papillary capillary loops (IPCL) (capillary meandering) defined as positive at NBI evaluation. The histological examination confirmed the presence of squamous cell carcinoma.

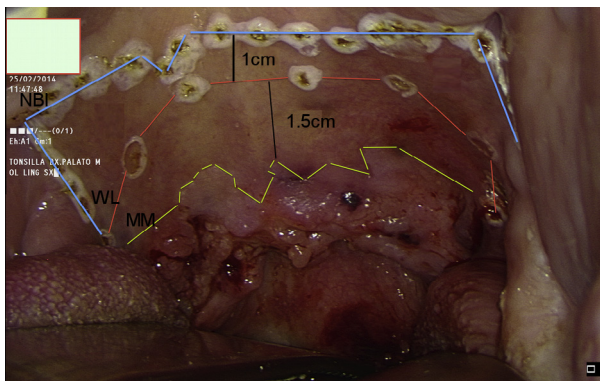


Fig. 2. Squamous cell carcinoma of the right tonsil, soft palate and left tonsil. The green line indicates the gross tumour edge; the red line is the first drawing obtained with white light (WL) by visual inspection and palpation 1.5 cm from the macroscopic margins (MM); the blue line is the narrow-band imaging (NBI)-driven drawing, in this case 1 cm from the WL one. (For interpretation of the references to color in this figure legend, the reader is referred to the web version of this article.)

lack of previous literature reporting on the resection of oral and oropharyngeal cancers guided by NBI alone. If the biopsies were positive for dysplasia or cancer, on the basis of the World Health Organization (WHO) 2005 classification [20], the surgical resection followed the tattoo obtained with NBI. After the resection was performed, the surgical margins (superficial and deep) were subjected to extemporaneous evaluation by a dedicated pathologist (Fig. 3); if they were positive for cancer or dysplasia (mild/moderate/severe) the resection was immediately enlarged, if they were negative, closure of the surgical defect was started. The resected specimen was fixed onto a piece of cork with insulin needles to minimize shrinkage [2,21,22]; sutures of different lengths were placed for correct orientation and to indicate the NBI-guided enlargement; an explanatory drawing with specific notes, was prepared for the pathologist. The specimen was then sent to a dedicated pathologist for histological evaluation.

The pathologist's response was supplied with a drawing to indicate any definitive margin involved by cancer or dysplasia and to signal the presence of dysplastic areas around the main tumour. Our Pathology Department classifies margins as "clear" when >3 mm, "close" when 0.1–3 mm, and "involved" only when clearly infiltrated by neoplastic cells.

In the case of positive margins, a margin-widening operation was planned or, if impossible because of patient factors or particularly difficult anatomical sites, the patient was referred for adjuvant treatments.

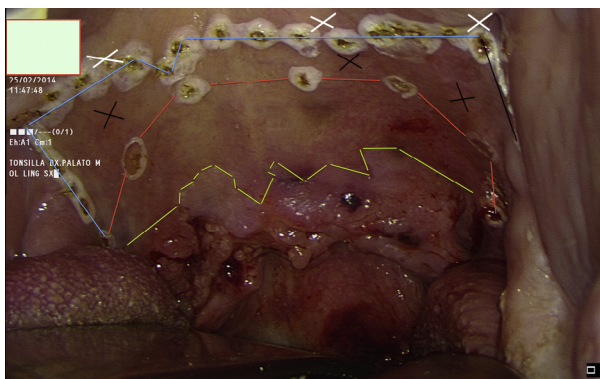


Fig. 3. Comparison between the WL and NBI tattoos. Several biopsies (indicated by the black crosses) are obtained in the area separating the tattoos and sent for extemporaneous evaluation. After the resection is completed, other biopsies (indicated by white crosses) are obtained beyond the surgical margins and sent for extemporaneous examination.

The surgical approach, the type of intervention, the number of positive margins at both extemporaneous and definitive histology, and the extent of NBI enlargement were noted (Table 2).

The true positive (TP), true negative (TN), false positive (FP) and false negative (FN) values were defined as follows: TP, patients with positive areas at NBI illumination and thus included in the NBI resection enlargement with a definitive histological response of dysplasia (mild/moderate/severe) or cancer; TN, patients with negative resection margins at NBI that were confirmed to be "clear" at definitive histological examination; FP, patients with positive areas at NBI illumination and thus included in the NBI resection enlargement with absence of dysplasia or cancer at definitive histological examination; FN, patients with negative resection margins at NBI but with different grades of dysplasia or cancer at definitive histological examination.

The histological response and NBI findings were correlated to calculate sensitivity, specificity, positive predictive value (PPV) and negative predictive value (NPV).

Results

Over the first six months of intraoperative NBI use, 16 patients undergoing surgery for oral cavity ($n = 8$) and oropharyngeal ($n = 8$) carcinoma were selected for the study; 11 male and 5 female patients were present; the mean age was 64.25 years, 87.5% had smoking and/or drinking habits.

Table 2

Surgical approach (SA), type of resection and histological examination of resection margins both at extemporaneous evaluation (FS = frozen sections collected after NBI-guided resection; neg = negative for dysplasia and cancer) and definitive histology (DH). TO = trans-oral, LP = lateral pharyngotomy, TM = trans mandibular, SLND = selective lateral neck dissection, MRND = modified radical neck dissection, ERND = extended radical neck dissection, DBT = distance between templates.

ID	SA	RESECTION	FS	DBT (mm)	DH
1	TO	Anterior pelvectomy, right SLND	Neg	8	Neg
2	LP	Partial right glossectomy, right extended tonsillectomy, right MRND III	Neg	14	Neg
3	TO	Extended left tonsillectomy, left ERND	Neg	7	Neg
4	TO	Anterior hemiglossopelvectomy, bilateral MRND III	Neg	13	Neg
5	TO	Anterior hemiglossopelvectomy, bilateral MRND III	Neg	13	Neg
6	TO	Bilateral extended tonsillectomy, bilateral MRND III	Neg	10	Neg
7	TO	Left partial glossectomy	Neg	8	Neg
8	TO	Left hemiglossectomy, left SLND	Neg	15	Neg
9	TO	Right partial pharyngectomy extended to uvula, right SLND	Neg	10	Neg
10	TO	Right hemiglossopelvectomy, anterior pelvectomy, bilateral MRND III	Neg	14	Neg
11	TO	Right pharyngectomy extended to uvula	Neg	9	Neg
12	TO	Anterior hemiglossopelvectomy, marginal mandibulectomy, bilateral SLND	Neg	9	Neg
13	TM	Right buccopharyngectomy, segmental right mandibulectomy, right SLND	Neg	8	Neg
14	TO	Right hemiglossopelvectomy, partial right pharyngectomy, segmental right mandibulectomy, left SLND, right MRND III	Neg	12	Neg
15	TO	Left hemipharyngectomy extended to left tongue base, MRND I	Neg	11	Cancer
16	TO	Right hemiglossopelvectomy, right SLND	Neg	12	Moderate dysplasia

During surgery, the resection margins were first clinically delimited at 1.5 cm from the macroscopic tumour and then with NBI; areas exhibiting IPCL alterations at NBI were considered positive for dysplasia or cancer and included in the NBI tattoo.

The use of NBI resulted in a resection enlargement of 11 ± 3 mm from the first margin drawn at 1.5 cm, with a consequent distance of 25 ± 4 mm between NBI defined margins and the tumour; several biopsies for extemporaneous histological examination were obtained from the area between the WL and the NBI tattoos showing the most suspicious vascular changes. These biopsies were found to be positive for dysplasia in 6/16 patients (37.5%) and for cancer in 10/16 patients (62.5%); therefore all patients underwent a resection enlargement. Resections were performed along the NBI-guided tattoo and therefore where the mucosa exhibited no vascular changes.

All 16 patients had superficial margins free of dysplasia and/or cancer at extemporaneous histological evaluation. At definitive histology of the surgical specimen, one patient (6.25%) had a superficial margin positive for cancer, and underwent additional resection; one patient (6.25%) had a superficial margin positive for moderate dysplasia and we decided for a close follow-up. The NBI-defined enlargement was positive for moderate dysplasia in 4/16 (25%) patients and for cancer in 12/16 (75%) patients at definitive histology. Deep margin status was not considered since NBI has no role in the detection of deep margins.

The number of cases defined as TP, TN, FP and FN were 16, 14, 0 and 2, respectively, so that the sensitivity, specificity, PPV and NPV were 100%, 88.9%, 100% and 87.5%, respectively.

In spite of the larger resection there was no increase in postoperative morbidity with regard to either swallowing or sound articulation (statistical analysis not performed); no patient experienced major complications such as bleeding, hematoma or salivary fistula either intra- or postoperatively. The mean length of hospitalization was 20.5 ± 7.3 days; no patient was discharged with a feeding tube or tracheostomy.

Discussion

In head and neck SCC, the presence of positive margins after the resection of a tumour has negative implications for local control and survival [9]. The vast majority of studies correlating local recurrence rate with margin status in oral SCC found a strong independent correlation [23,6,24–27], although the absolute number of local recurrences and the criteria used to define positive margins vary significantly among the different studies. Other studies, by contrast, failed to demonstrate any correlation [28,29].

Furthermore, no universal guidelines exist for the pathological classification of margins as “clear” (free of tumour cells), “close” (free of tumour cells but narrow) or “involved” (infiltrated or with tumour cells close to the margin) [30–33].

Setting a safety margin of ≥ 10 mm during surgery is considered to be appropriate for the resection of oral cancers, although a clear basis for this distance is currently lacking [2–4]. Others maintain a distance of 1.5 [5] or 2 cm [6–8] from the macroscopic lesion boundaries.

The intraoperative evaluation of resection margins can be made by using frozen sections (FS) just after resection of the tumour; this method is accepted worldwide but, as underlined by Yahalom et al. [34], the procedure is not standardized. Other problems that have been encountered concern the site where the FS should be collected (surgical bed vs specimen) [30] and the risk of not precisely identifying the area to be enlarged in the event of positive margins [35]. Possible solutions have, however, been proposed [36].

Other methods have been suggested for achieving free resection margins in oral SCC. Staining with Lugol's iodine solution has been

demonstrated to reduce the number of positive margins at definitive histology in different studies [37–39]. More recently, the use of intraoperative touch imprint cytology has been reported as a quick, simple, inexpensive, highly accurate and reliable technique [40]. Optical coherence tomography was used to assess tumour resection margins in 25 patients with early stage oral SCC in a study by Hamdoon et al.: the authors reported the feasibility of its use in differentiating between positive and negative surgical margins [41]. Other studies have proposed a molecular definition of surgical margins, from protein markers to DNA-based techniques, all with their advantages and disadvantages [42–44]. One recent study has also shown the impact of molecular definition on local recurrence [45].

In oncology, the surgeon's main goal is to excise the cancer completely because the presence of residual tumour remains the most important prognostic factor [46]. How wide the resection should be is not clear [2–8] and the surgeon has to find a balance between the need to obtain adequate tumour margins and the desire to retain function and quality of life and limit the cosmetic defect.

Despite the many solutions proposed to solve the problem of positive margins, no definite guidelines exist as yet.

Recent advances in imaging techniques such as NBI could be helpful for defining the superficial resection margins of oral and oropharyngeal carcinoma. The technique uses a filter that alters the light spectrum allowing the passage of only two specific wavelengths of the visible spectrum that enhance the mucosal and sub-mucosal vasculature, allowing the visualization of capillaries and veins. An Italian study [47] showed that, in the oral cavity and oropharynx, NBI provides a diagnostic gain of 25% in detecting oral dysplasia and cancers compared to WL endoscopy.

On the basis of the classification of intra-papillary capillary loops (IPCL) [17–19], it may be possible to distinguish cancerous lesions from dysplastic areas, which are often not macroscopically visible. Identifying apparently normal areas that would not have been resected, with the risk of progression into cancer and a secondary field tumour [48] is of great importance for tumour resection. In our study, the use of NBI enabled us to obtain a resection enlargement of 11 ± 3 mm, leading to negative margins for dysplasia and/or carcinoma at extemporaneous histological examination. At definitive histological examination only two cases were found to be positive, one for cancer and the other for moderate dysplasia, and thus underwent additional resection and close follow-up, respectively. All resections were performed along the NBI-guided tattoo so they did not present vascular alterations; the presence of dysplasia and cancer at definitive histology in two cases results in a loss of sensitivity. On the other hand, the high specificity value obtained indicates that any NBI-positive area should be included in the resection. The NBI-defined enlargement proved positive for moderate dysplasia in 4/16 (25%) patients and for cancer in 12/16 (75%) patients.

To the best of our knowledge, no studies have been carried out with the specific aim of investigating the impact of intraoperative NBI on the incidence of positive superficial surgical margins in the treatment of oral cavity and oropharyngeal carcinoma.

Only one published study has addressed the intraoperative application of NBI to better delineate the superficial resection margins in early glottis cancer; the authors report an increase in the accuracy of the evaluation of superficial spread of the neoplasm, with a consequent reduction in the rate of positive margins [49].

The use of NBI has some organisational consequences: a dedicated team should be created because the presence of a learning curve in the application of NBI has been reported [50] and the surgeon should take this into account before basing surgical resections on NBI appearance; a close relation between the surgeon and a dedicated pathologist should be present; in addition, we

believe a preoperative evaluation is required to have a first idea of tumour extent so as to limit the increase in operating time to only 5 min on average. However, the evaluation of certain areas may sometimes prove difficult because of their location or poor patient compliance; in this case, a more precise evaluation can be performed in the operating room under general anaesthesia before the resection. The presence of blood in the surgical field prevents NBI evaluation so care should be taken to avoid bleeding; to this end, we recommend to perform NBI before any surgical action that can alter mucosal vascularisation.

Moreover, NBI evaluation allows for a better definition of superficial margins only.

Limitations of our study include the small number of patients treated and the short follow-up period. A larger scale study with a longer follow-up period is needed to verify whether negative margins really lead to better locoregional control and whether the wider resection has a negative impact on function in the long term.

Future studies are necessary to compare this group of patients treated with the intraoperative use of NBI with a historical cohort treated without it to quantify the gain in terms of reducing the rate of positive surgical margins at definitive histological examination, the differences in terms of survival and quality of life.

To conclude, we believe this method could help to achieve oncological radicality in oral cavity and oropharyngeal carcinoma in a single step, minimizing the error in relocating the sampling site if there is a need to enlarge the resection after positive extemporaneous examination; it could help to reduce the risk of developing local recurrence or secondary tumours in the cancer field as a result of incomplete resection of the cancer or field, respectively. Obtaining free resection margins at definitive histology is of great importance especially if a free flap is used for reconstruction because this precludes subsequent enlargement of the resection and warrants adjuvant radiotherapy, which negatively impacts quality of life.

In our opinion the advantages of this approach go beyond the oncological benefit of reducing the number of positive margins: first, there is also an economic advantage because positive margins require an additional hospitalization for re-excision, with adjunctive healthcare costs; further, the need for a new surgical procedure may negatively affect the patients' quality of life. Future studies with a complete health technology assessment analysis are required to verify our hypotheses.

Conflict of interest statement

None declared.

Acknowledgements

The authors thank Itala Mary Ann Brancaleone, MA, RSA Dip TEFLA, teacher of Medical English at the University of Trieste, for her support in editing the manuscript.

References

- [1] Hinni ML, Ferlito A, Brandwein-Gensler MS, Takes RP, Silver CE, Westra WH, et al. Surgical margins in head and neck cancer: a contemporary review. *Head Neck* 2013;35(9):1362–70.
- [2] Cheng A, Cox D, Schmidt BL. Oral squamous cell carcinoma margin discrepancy after resection and pathologic processing. *J Oral Maxillofac Surg* 2008;66:523–9.
- [3] Upile T, Fisher C, Jerjes W, El Maaytah M, Searle A, Archer D, et al. The uncertainty of the surgical margin in the treatment of head and neck cancer. *Oral Oncol* 2007;43:321–6.
- [4] Nason RW, Binahmed A, Pathak KA, Abdoh AA, Sándor GK. What is the adequate margin of surgical resection in oral cavity? *Oral Surg Oral Med Oral Pathol Oral Radiol Endod* 2009;107(5):625–9.

- [5] Kovacs AF. Relevance of positive margins in case of adjuvant therapy of oral cancer. *Int J Oral Maxillofac Surg* 2004;33:447–53.
- [6] Yuen PW, Lam KY, Chan AC, Wei WI, Lam LK. Clinicopathological analysis of local spread of carcinoma of the tongue. *Am J Surg* 1998;175:242–4.
- [7] Calabrese L, Giugliano G, Bruschini R, Ansarin M, Navach V, Grosso E, et al. Compartmental surgery in tongue tumours: description of a new surgical technique. *Acta Otorhinolaryngol Ital* 2009;29:259–64.
- [8] Gil Z, Fliss DM. Contemporary management of head and neck cancers. *Isr Med Assoc J* 2009;11:296–300.
- [9] Weijers M, Snow GB, Bezemer PD, Van Der Waal JE, Van Der Waal I. The clinical relevance of epithelial dysplasia in the surgical margins of tongue and floor of mouth squamous cell carcinoma. *J Oral Path Med* 2002;31:11–5.
- [10] Califano J, Leong PL, Koch WM, Eisenberger CF, Sidransky D, Westra WH. Second esophageal tumors in patients with head and neck squamous cell carcinoma: an assessment of clonal relationships. *Clin Cancer Res* 1999;5:1862–7.
- [11] Rennemo E, Zatterstrom U, Boysen M. Impact of second primary tumors on survival in head and neck cancer: an analysis of 2,063 cases. *Laryngoscope* 2008;118:1350–6.
- [12] Weinberg RA. *The biology of cancer*. 2nd ed. New York: Taylor & Francis Group; 2013.
- [13] Piazza C, Cocco D, Del Bon F, Mangili S, Nicolai P, Majorana A, et al. Narrow band imaging and high definition television in evaluation of oral and oropharyngeal squamous cell cancer: a prospective study. *Oral Oncol* 2010;46(4):307–10.
- [14] Muto M, Nakane M, Katada C, Sano Y, Ohtsu A, Esumi H, et al. Squamous cell carcinoma in situ at oropharyngeal and hypopharyngeal mucosal sites. *Cancer* 2004;101(6):1375–81.
- [15] Poh CF, Zhang L, Anderson DW, Durham JS, Williams PM, Priddy RW, et al. Fluorescence visualization detection of field alterations in tumor margins of oral cancer patients. *Clin Cancer Res* 2006;12:6716–22.
- [16] Vu AN, Farah CS. Efficacy of narrow band imaging for detection and surveillance of potentially malignant and malignant lesions in the oral cavity and oropharynx: a systematic review. *Oral Oncol* 2014;50(5):413–20.
- [17] Takano JH, Yakushiji T, Kamiyama I, Nomura T, Katakura A, Takano N, et al. Detecting early oral cancer: narrowband imaging system observation of the oral mucosa microvasculature. *Int J Oral Maxillofac Surg* 2010;39:208–13.
- [18] Yang SW, Lee YS, Chang LC, Hwang CC, Luo CM, Chen TA. Use of endoscopy with narrow-band imaging system in evaluating oral leukoplakia. *Head Neck* 2012;34:1015–22.
- [19] Yang SW, Lee YS, Chang LC, Chien HP, Chen TA. Light sources used in evaluating oral leukoplakia: broadband white light versus narrowband imaging. *Int J Oral Maxillofac Surg* 2013;42(6):693–701.
- [20] Warnakulasuriya S, Reibel J, Bouquot J, Dabelsteen E. Oral epithelial dysplasia classification systems: predictive value, utility, weaknesses and scope for improvement. *J Oral Pathol Med* 2008;37:127–33.
- [21] Mistry RC, Qureshi SS, Kumaran C. Post-resection mucosal margin shrinkage in oral cancer: quantification and significance. *J Surg Oncol* 2005;91(2):131–3.
- [22] Chen CH, Hsu MY, Jiang RS, Wu SH, Chen FJ, Liu SA. Shrinkage of head and neck cancer specimens after formalin fixation. *J Chin Med Assoc* 2012;75:109–13.
- [23] Looser KG, Shah JP, Strong EW. The significance of “positive” margins in surgically resected epidermoid carcinomas. *Head Neck Surg* 1978;1:107–11.
- [24] Woolgar JA, Rogers S, West CR, Errington RD, Brown JS, Vaughan ED. Survival and patterns of recurrence in 200 oral cancer patients treated by radical surgery and neck dissection. *Oral Oncol* 1999;35:257–65.
- [25] Loree TR, Strong EW. Significance of positive margins in oral cavity squamous carcinoma. *Am J Surg* 1990;160(4):410–4.
- [26] Kiritu T, Okabe S, Izumo T, Sugimura M. Risk factors for the postoperative local recurrence of tongue carcinoma. *J Oral Maxillofac Surg* 1994;52:149–54.
- [27] Jerjes W, Upile T, Petrie A, Riskalla A, Hamdoon Z, Vourvachis M, et al. Clinicopathological parameters, recurrence, locoregional and distant metastasis in 115 T1–T2 oral squamous cell carcinoma patients. *Head Neck Oncol* 2010;2:9.
- [28] McMahan J, O'Brien CJ, Pathak I, Hamill R, Mc Neil E, Hammersley N, et al. Influence of condition of surgical margins on local recurrence and disease-specific survival in oral and oropharyngeal cancer. *Br J Oral Maxillofac Surg* 2003;41(4):224–31.
- [29] Brandwein-Gensler M, Teixeira MS, Lewis CM, Lee B, Rolnitzky L, Hille JJ, et al. Oral squamous cell carcinoma: histologic risk assessment, but not margin status, is strongly predictive of local disease-free and overall survival. *Am J Surg Pathol* 2005;29(2):167–78.
- [30] Meier JD, Oliver DA, Varvares MA. Surgical margin determination in head and neck oncology: current clinical practice. The results of an International American Head and Neck Society Member Survey. *Head Neck* 2005;27(11):952–8.
- [31] Woolgar JA, Triantafyllou A. A histopathological appraisal of surgical margins in oral and oropharyngeal cancer resection specimens. *Oral Oncol* 2005;41:1034–43.
- [32] Binahmed A, Nason RW, Abdoh AA. The clinical significance of the positive surgical margin in oral cancer. *Oral Oncol* 2007;43:780–4.
- [33] Chiou WY, Lin HY, Hsu FC, Ho HC, Su YC, Lee CC, et al. Buccal mucosa carcinoma: surgical margin less than 3 mm, not 5 mm, predicts locoregional recurrence. *Radiat Oncol* 2010;5:79.
- [34] Yahalom R, Dobriyan A, Vered M, Talmi YP, Teicher S, Bedrin L. A prospective study of surgical margin status in oral squamous cell carcinoma: a preliminary report. *J Surg Oncol* 2008;98(8):572–8.

- [35] Kerawala CJ, Ong TK. Relocating the site of frozen sections—is there room for improvement? *Head Neck* 2001;23(3):230–2.
- [36] Miyawaki A, Hijioka H, Ishida T, Nozoe E, Nakamura N, Oya R. Intraoperative frozen section histological analysis of resection samples is useful for the control of primary lesions in patients with oral squamous cell carcinoma. *Mol Clin Oncol* 2015;3(1):55–62. Epub 2014 September 4.
- [37] McMahon J, Devine JC, McCaul JA, McLellan DR, Farrow A. Use of Lugol's iodine in the resection of oral and oropharyngeal squamous cell carcinoma. *Br J Oral Maxillofac Surg* 2010;48(2):84–7.
- [38] Umeda M, Shigeta T, Takahashi H, Minamikawa T, Komatsubara H, Oguni A, et al. Clinical evaluation of Lugol's iodine staining in the treatment of stage I–II squamous cell carcinoma of the tongue. *Int J Oral Maxillofac Surg* 2011;40(6):593–6.
- [39] Watanabe A, Taniguchi M, Tsujie H, Hosokawa M, Fujita M, Sasaki S. Clinical impact of iodine staining for diagnosis of carcinoma in situ in the floor of mouth, and decision of adequate surgical margin. *Auris Nasus Larynx* 2012;39(2):193–7.
- [40] Yadav GS, Donoghue M, Tauro DP, Yadav A, Agarwal S. Intraoperative imprint evaluation of surgical margins in oral squamous cell carcinoma. *Acta Cytol* 2013;57(1):75–83.
- [41] Hamdoon Z, Jerjes W, McKenzie G, Jay A, Hopper C. Assessment of tumour resection margins using optical coherence tomography. *Head Neck Oncol* 2010;2(Suppl. 1):O7.
- [42] Brennan JA, Mao L, Hruban RH, Boyle JO, Eby YJ, Koch W, et al. Molecular assessment of histopathological staging in squamous-cell carcinoma of the head and Neck. *N Engl J Med* 1995;332(7):429–35.
- [43] Partridge M, Li SR, Pateromichelakis S, Francis R, Phillips E, Huang XH, et al. Detection of minimal residual cancer to investigate why oral tumors recur despite seemingly adequate treatment. *Clin Cancer Res* 2000;6(7):2718–25.
- [44] Braakhuis BJM, bloemena E, Leemans CR, Brakenhoff R. Molecular analysis of surgical margins in head and neck cancer: more than a marginal issue. *Oral Oncol* 2012;46:485–91.
- [45] Reis PP, Waldron L, Perez-Ordóñez B, Pintilie M, Galloni NN, Xuan Y, et al. A gene signature in histologically normal surgical margins is predictive of oral carcinoma recurrence. *BMC Cancer* 2011;11:437.
- [46] Snow GB. Evaluation and staging of the patient with head and neck cancer. In: Myers EN, Suen JY, editors. *Cancer of the head and neck*. New York: Churchill Livingstone; 1989. p. 17–38.
- [47] Piazza C, Cocco D, Del Bon F, Mangili S, Nicolai P, Peretti G. Narrow band imaging and high definition television in the endoscopic evaluation of upper aero-digestive tract cancer. *Acta Otorhinolaryngol Ital* 2011;31(2):70–5.
- [48] Braakhuis BJ, Tabor MP, Leemans CR, van der Waal I, Snow GB, Brakenhoff RH. Second primary tumors and field cancerization in oral and oropharyngeal cancer: molecular techniques provide new insights and definitions. *Head Neck* 2002;24:198–206. Epub 2014 October 30.
- [49] Garofolo S, Piazza C, Del Bon F, Mangili S, Guastini L, Mora F, et al. Intraoperative narrow band imaging better delineates superficial resection margins during transoral laser microsurgery for early glottis cancer. *Ann Otol Rhinol Laryngol* 2015;124(4):294–8.
- [50] Piazza C, Cocco D, De Benedetto L, Del Bon F, Piero P, Peretti G. Narrow band imaging and high definition television in the assessment of laryngeal cancer: a prospective study on 279 patients. *Eur Arch Oto-Rhino-Laryngol* 2010;267(3):409–14.