



Contents lists available at ScienceDirect

## International Journal of Surgery Case Reports

journal homepage: [www.casereports.com](http://www.casereports.com)

## Perforated appendix with abscess: Immediate or interval appendectomy? Some examples to explain our choice



Edoardo Guida<sup>a,\*</sup>, Federica Pederiva<sup>a</sup>, Massimo Di Grazia<sup>b</sup>, Daniela Codrich<sup>a</sup>,  
Maria Antonietta Lembo<sup>a</sup>, Maria Grazia Scarpa<sup>a</sup>, Waifro Rigamonti<sup>a,b</sup>

<sup>a</sup> Institute for Maternal and Child Health – IRCCS Burlo Garofolo, Trieste, Italy

<sup>b</sup> University of Trieste, Italy

### ARTICLE INFO

#### Article history:

Received 17 February 2015

Received in revised form 4 May 2015

Accepted 4 May 2015

Available online 7 May 2015

#### Keywords:

Interval appendectomy

Appendicolith

Antibiotic therapy

Acute appendicitis

Abscess

### ABSTRACT

**INTRODUCTION:** There are no clear guidelines in the treatment of a perforated appendicitis associated with periappendiceal abscess without generalized peritonitis.

**PRESENTATION OF CASES:** We retrospectively studied six examples of treated children in order to discuss the reasons of our team's therapeutic approach. Some children were treated with a conservative antibiotic therapy to solve acute abdomen pain, planning a routine interval appendectomy after some months. Others, instead, underwent an immediate appendectomy.

**DISCUSSION:** By examining these examples we wanted to highlight how the first approach may be associated with shorter surgery time, fewer overall hospital days, faster refeeding and minor complications. **CONCLUSION:** Our team's therapeutic choice, in the case of a perforated appendicitis with an abscess and coprolith is an initial conservative case management followed by a routine interval appendectomy performed not later than 4 months after discharge.

© 2015 The Authors. Published by Elsevier Ltd. on behalf of Surgical Associates Ltd. This is an open access article under the CC BY-NC-ND license (<http://creativecommons.org/licenses/by-nc-nd/4.0/>).

## 1. Introduction

There are no clear guide lines in the treatment of perforated appendicitis associated with an inflammatory mass or a periappendiceal abscess without generalized peritonitis.

Some surgeons opt for a conservative treatment by means of an intravenous antibiotic therapy to solve acute abdomen [1–4] pain, planning a routinary interval appendectomy (IA) after some months. However, this approach is debatable since some authors suggest an immediate appendectomy regardless [3,4].

The ultrasonographic (US) evidence of appendicolith, associated with an increased risk of recurrent appendicitis [1–4], is, for some surgeons, the reason to suggest an immediate appendectomy. In contrast, others do not perform an IA even after an antibiotic therapy and do so only in case of recurrence [2–4].

The aim of this study is to offer some examples for the conservative treatment followed by IA and some for the immediate appendectomy in children with an associated periappendiceal abscess and to discuss our team's choice.

**Abbreviations:** CT, computed tomography; CVC, central catheter venous; IA, interval appendectomy; NT, naso-gastric tube; US, ultrasonography; VC, vesical catheter.

\* Corresponding author at: Institute for Maternal and Child Health – IRCCS Burlo Garofolo, Via dell'Istria, 65/1, 34137 Trieste, Italy. Tel.: +39 040 3785 314.

E-mail address: [edoardoguida@libero.it](mailto:edoardoguida@libero.it) (E. Guida).

## 2. Case series

### 2.1. Patient 1: immediate appendectomy

This 5-year old girl showed the following symptoms: 5 days fever, abdominal pain and vomit. Leukocytes and PCR was  $18 \times 10^3$  and 16 (mg/dl) respectively.

US showed a perforated appendicitis associated with an inflammatory mass.

We decided to perform an immediate video-assisted appendectomy through a subumbilical incision for the laparoscopic operative trocar insertion.

We found a subhepatic necrotic appendix surrounded by an abscess.

To dissect and extract the appendix, it was necessary to enlarge the subumbilical incision and create a second access in the left iliac fossa. Nasogastric tube (NT) and vesical catheter (VC) were placed. Surgery time was 165 min.

Oral feeding started on day 4. Hospital stay was 9 days.

She was treated with a triple antibiotic therapy (ampicillin/sulbactam 50 mg/kg every 8 h, metronidazole 10 mg/kg every 8 h, tobramycin 5 mg/kg in a single dose) for 9 days.

In the postoperative stage, an infection of the subumbilical wound was observed.

<http://dx.doi.org/10.1016/j.ijscr.2015.05.003>

2210-2612/© 2015 The Authors. Published by Elsevier Ltd. on behalf of Surgical Associates Ltd. This is an open access article under the CC BY-NC-ND license (<http://creativecommons.org/licenses/by-nc-nd/4.0/>).

## 2.2. Patient 2: immediate appendectomy

This 4-year old girl reported having abdominal pain and fever for 3 days. Leukocytes and PCR was  $24 \times 10^3$  and 20 mg/dl respectively. US showed a thickening of the appendix with a pericecal effusion without a secure image of abscess.

An immediate video-assisted appendectomy was performed through a single enlarged subumbilical incision.

We found a necrotic appendix with an inflammatory mass involving the right tube and ovary.

The tube wall was very fragile and during the procedure a tubal lesion led to a partial tube removal. NT and VC were placed. Surgery time was 70 min.

Oral feeding started on day 3. Hospital stay was 10 days. Our standard triple antibiotic therapy was continued for 10 days.

In the postoperative stage, a subumbilical wound infection was observed.

## 2.3. Patient 3: immediate appendectomy

This 3-year old boy presented with a 3 day history of abdominal pain, vomit and high fever. Leukocytes and PCR was  $22 \times 10^3$  and 22 mg/dl respectively.

The child had a sodium depletion (128 mEq/L).

US showed a perforated appendicitis associated with an inflammatory mass and pericecal and pelvic effusion.

We performed an immediate video-assisted appendectomy through a subumbilical incision.

We found a gangrenous appendix with an inflammatory mass involving the cecum, the last ileal loop and extending to the bladder.

Another 2 operative accesses (left iliac fossa and sovrapubic) were necessary to dissect and extract the appendix. NT, VC and central catheter venous (CVC) were placed. Surgery time was 100 min.

Oral feeding started on day 5. Hospital stay was 10 days. A preliminary standard triple antibiotic therapy was prescribed adding Vancomycin (10 mg/kg every 6 h) on the 3rd postoperative day to increase inflammatory markers. The antibiotic therapy was continued for a total of 10 days.

After discharge, US control showed a retro-bladder abscess image which required an additional 4 day intravenous antibiotic therapy.

## 2.4. Patient 4: conservative treatment followed by interval appendectomy

This 4-year old boy reported a history of abdominal pain and fever for 4 days.

Leukocytes and PCR was  $8 \times 10^3$  and 16 mg/dl respectively. A thickening of the appendix with an abscess of 5–6 cm was seen at US and a rounded, hyperechoic image into the appendix referable to a coprolith was described (Fig. 1).

We decided for a conservative approach with standard triple intravenous antibiotic therapy for 5 days. At discharge, PCR was 0.68 mg/dl and US normal.

We planned an IA after 3 months. However, after 2 months, a new episode of moderate abdominal pain convinced us to put forward IA.

Video assisted appendectomy was done through a small single subumbilical incision and a hyperaemic appendix without abscess or adherence was found. No NT or VC were placed. Surgery time was 40 min.

A single shot intraoperative antibiotic therapy with ampicillin/sulbactam was prescribed. Oral feeding was started on day 1. The patient was discharged after 2 days. No postoperative complications were observed by the 5th month.

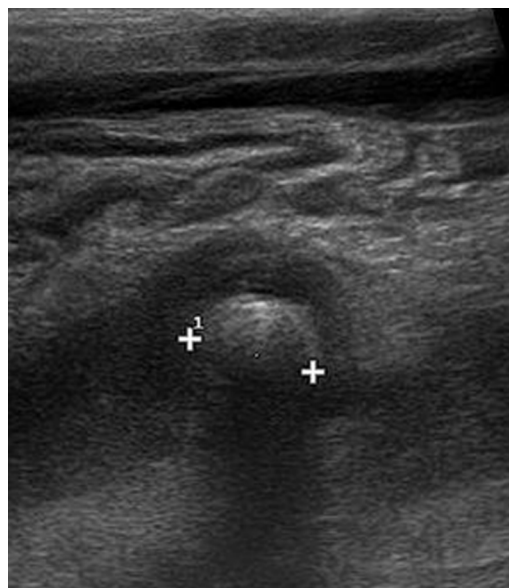


Fig. 1. Ultrasonographic rounded image into the appendix referable to a coprolith.

## 2.5. Patient 5: conservative treatment followed by interval appendectomy

This 7-year old girl presented with a history of abdominal pain, vomit and fever for 2 days.

Leukocytes and PCR was  $15 \times 10^3$  and 19 mg/dl respectively. An abscess of 3 cm including the tip of the appendix and an intraluminal hyperechoic image (coprolith) were seen at US. A conservative approach with standard triple intravenous antibiotic therapy for 6 days was prescribed. At discharge PCR was 1.9 mg/dl and US normal.

We planned IA after 3 months. Video-assisted appendectomy was done with a small single subumbilical incision and an appendix without macroscopic signs of inflammation was removed. No NT or VC was placed. Surgery time was 45 min.

A single shot intraoperative antibiotic therapy was given. Oral feeding was started on day 1. The patient was discharged after 2 days without postoperative complications by the 6th month.

## 2.6. Patient 6: conservative treatment followed by interval appendectomy

This 12 year-old boy had a 2 day history of abdominal pain and fever. Leukocytes and PCR was  $23 \times 10^3$  and 11 mg/dl respectively. At US, an abscess of 6 cm including the tip of the appendix with an hyperechoic image into the appendix referable to appendicolith was observed. A conservative approach with a standard triple intravenous antibiotic therapy for 5 days was given. At discharge, PCR was 1.4 mg/dl and US normal. We planned IA after 4 months. Video-assisted appendectomy was done with a small single subumbilical incision. An appendix without macroscopic signs of inflammation was found. No NT or VC were placed. Surgery time was 45 min. A single shot intraoperative antibiotic therapy was prescribed. Oral feeding started on day 1. The child went home after 2 days. No postoperative complications were observed by the 2nd month Table 1.

## 3. Discussion

Two common surgical dilemmas exist in the treatment of complicated appendicitis.

The first question is whether to proceed with an immediate appendectomy or to treat the patient with an initial intravenous antibiotic therapy followed by IA [1–5].

**Table 1**

3 cases of immediate appendectomy versus 3 cases of interval appendectomy highlighting: the patient's age, number of trocars, surgery time, presence or absence of nasogastric tube (NT) and vesical catheter (VC), time of postoperative oral feeding and overall hospital stay (in the case of IA we considered first and second admission).

	Immediate appendectomy				Interval appendectomy			
	Case 1	Case 2	Case 3	Average	Case 4	Case 5	Case 6	Average
Age (years)	5	4	3	4	4	7	12	7.6
Trocars (number)	2	1	3	2	1	1	1	1
Surgery time (minutes)	165	70	100	111.6	40	45	45	43.3
NT and VC	Yes	Yes	Yes	–	No	No	No	–
Oral feeding (postoperative days)	4	3	5	4	1	1	1	1
Overall hospital stay (days)	9	10	10	9.6	5+2	6+2	5+2	7.3

Our choice was for the preliminary use of triple intravenous antibiotics (ampicillin/sulbactam, metronidazole and tobramycin) until the periappendiceal abscess disappeared at US, the C-reactive protein was almost normal (not more than 2 mg/dl) and the patient had no fever.

A blood test screening and US follow up are recommended 7 days after discharge. An oral antibiotic therapy (amoxicillin/clavulanic acid 25 mg/kg every 8 h) is suggested till the follow-up.

The reasons for our conservative management are the following:

(1) In line with the literature, we believe that preliminary conservative management is associated with fewer perioperative complications such as intraoperative visceral damage (ileal, cecal and tubal damage), postoperative abdominal and pelvic abscesses, wound infections which sometimes require a re-intervention [4].

(2) A preliminary antibiotic therapy allowed a shorter operative time than an immediate appendectomy when IA was performed, removing an hyperemic or normal appendix without adherence.

(3) A preliminary conservative approach followed by IA still reduces the overall hospitalization time [5–6]. While a total of 7.3 days were necessary to solve the problem (including antibiotic therapy + IA), longer hospitalization was required in case of an immediate appendectomy.

The second question is whether the routine IA is always necessary after a conservative case management.

We performed IA after all cases of perforated appendicitis.

The reasons for our choice are the following:

(1) In terms of follow-up, in line with the literature, we believe that the presence of a coprolith is a significant risk factor for recurrent appendicitis [1,2]. Some authors suggest to perform IA only in case of persistence presence of an appendicolith [2]. However, in our opinion it is not always easy to perform an accurate US follow-up to detect the presence or absence of an appendicolith. It is generally accepted that an ultrasonography is operator-dependant and sometimes the appendix cannot be displayed for the retrocecal or retroileal position of the appendix [7]. More, we believe that the presence of an appendicolith may not always be seen at the US and the use of computed tomography (CT) is radiologically too invasive.

(2) In terms of patient safety and comfort, we believe that even a slightest risk of recurrent perforated appendicitis with abscess is still a risk for the children, exposing them to perioperative complications as described above [4]. Moreover, the discomfort for the patients and their parents would be greater in the case of a first hospitalization for the conservative treatment and a second one, similar to an immediate appendectomy, in a perforated appendicitis. In contrast, an IA postoperative course is comparable to a one day-surgery procedure while the appendix extraction could be normally done through a small single incision.

(3) In terms of stress, not performing the routine IA after conservative management means, in our opinion, alerting the family and the patient on the potential risk of another acute appendicitis episode, mostly in case of appendicolith. The fear and anxiety of some parents may cause distress and excessive surveillance at

home: any fever, abdominal discomfort or other symptoms are interpreted as acute appendicitis! [8,9].

(4) In terms of costs, long overall hospitalization (in case of an appendectomy performed for a recurrent perforated appendicitis) and a diagnostic procedure to confirm or disprove the recurrent appendicitis, certainly result in a higher cost for the hospital.

In conclusion, in the light of the cases provided, our team's therapeutic choice in cases of perforated appendicitis with an abscess, also with presence of coprolith, is the initial conservative case management followed by a routine IA performed not later than 4 months after discharge.

**Conflict of interest**

There is no statement of any potential conflict of interest, real or perceived.

**Funding**

No honorarium, grant, or any other form of payment was issued to Edoardo Guida and the other authors to produce the manuscript.

**Ethical approval**

This study did not need of any Ethical Approval, not being a research study.

**Consent**

“Written informed consent was obtained from the patient. A copy of the written consent is available for review by the Editor-in-Chief of this journal on request”.

**Author contribution**

Edoardo Guida and Federica Pederiva wrote the first draft of the manuscript.

Massimo Di Grazia, Daniela Codrich, Maria Antonietta Lembo and Maria Grazia Scarpa contributed to data collection.

Waifro Rigamonti supervised this study.

**Guarantor**

Edoardo Guida, MD.

**References**

[1] S.H. Ein, J.C. Langer, A. Daneman, Nonoperative management of pediatric ruptured appendix with inflammatory mass or abscess: presence of an appendicolith predicts recurrent appendicitis, *J. Pediatr. Surg.* 40 (October (10)) (2005) 1612–1615.  
 [2] H.L. Zhang, Y.Z. Bai, X. Zhou, et al., Nonoperative management of appendiceal phlegmon or abscess with an appendicolith in children, *J. Gastrointest. Surg.* 17 (April (4)) (2013) 766–770.

- [3] D. Puapong, S.L. Lee, P.I. Haigh, et al., Routine interval appendectomy in children is not indicated, *J. Pediatr. Surg.* 42 (September (9)) (2007) 1500–1503.
- [4] T.R. Weber, M.A. Keller, R.J. Bower, et al., Is delayed operative treatment worth the trouble with perforated appendicitis in children? *Am. J. Surg.* 186 (December (6)) (2003) 685–688, discussion 688–9.
- [5] K.A. Kogut, M.L. Blakely, K.P. Schropp, et al., The association of elevated percent bands on admission with failure and complications of interval appendectomy, *J. Pediatr. Surg.* 36 (January (1)) (2001) 165–168.
- [6] S.D. St Peter, P. Aguayo, J.D. Fraser, et al., Initial laparoscopic appendectomy versus initial nonoperative management and interval appendectomy for perforated appendicitis with abscess: a prospective, randomized trial, *J. Pediatr. Surg.* 45 (January (1)) (2010) 236–240, <http://dx.doi.org/10.1016/j.jpedsurg.2009.10.039>.
- [7] P. Pacharn, J. Ying, L.E. Linam, et al., Sonography in the evaluation of acute appendicitis: are negative sonographic findings good enough? *J. Ultrasound Med.* 29 (December (12)) (2010) 1749–1755.
- [8] C.W. Iqbal, E.M. Knott, V.E. Mortellaro, et al., Interval appendectomy after perforated appendicitis: what are the operative risks and luminal patency rates? *J. Surg. Res.* 177 (September (1)) (2012) 127–130, <http://dx.doi.org/10.1016/j.jss.2012.03.009>, Epub 2012 Mar 30.
- [9] J.V. Schurman, C.C. Cushing, C.L. Garey, et al., Quality of life assessment between laparoscopic appendectomy at presentation and interval appendectomy for perforated appendicitis with abscess: analysis of a prospective randomized trial, *J. Pediatr. Surg.* 46 (June (6)) (2011) 1121–1125, <http://dx.doi.org/10.1016/j.jpedsurg.2011.03.038>.

#### Open Access

This article is published Open Access at [sciencedirect.com](http://www.sciencedirect.com). It is distributed under the [IJSCR Supplemental terms and conditions](#), which permits unrestricted non commercial use, distribution, and reproduction in any medium, provided the original authors and source are credited.