

Contents lists available at [SciVerse ScienceDirect](http://SciVerse.ScienceDirect.com)

European Journal of Vascular and Endovascular Surgery

journal homepage: www.ejves.com

Short Report

The Wonders of a Newly Available Post-analysis CT Software in the Hands of Vascular Surgeons

F. Setacci*, P. Sirignano, A. Cappelli, C. Setacci

Department of Vascular Surgery, Vascular and Endovascular Surgery Unit, University of Siena, Siena, Italy

ARTICLE INFO

Article history:

Received 18 May 2011

Accepted 30 November 2011

Available online 5 January 2012

Keywords:

EVAR

Follow-up

CT-angio

ABSTRACT

Introduction: Endovascular treatment of abdominal aortic aneurysms has become a widespread and accepted practice in most Vascular Surgery centres. The optimal method to identify and characterise complications still awaits assessment.

Case report: An 83-year-old woman was admitted to our Institution for volumetric expansion of the aneurysm sac due to a suspected type II endoleak. Post-analysis, using OsiriX, revealed the presence of a hole at the distal portion of the main body in the docking zone near the flow divider.

Conclusion: OsiriX is an image processing software and an attractive alternative to dedicated workstations and allows rendering and analysis of numerous medical imaging modalities.

© 2011 European Society for Vascular Surgery. Published by Elsevier Ltd. All rights reserved.

Endovascular treatment of abdominal aortic aneurysms (AAAs) has become a widespread and accepted practice in most Vascular Surgery centres.

Currently, the methods of follow-up are a source of intense debate. The fixed point is to find the optimal method to identify and characterise complications.¹

Endoleak is the most frequent and potentially catastrophic complication after endovascular aneurysm repair (EVAR). The vascular surgeon must identify the endoleak and understand its nature to schedule possible surgical or endovascular repair.² Unfortunately, in most cases there are no dedicated workstations or vascular radiology services available 24 h a day. The goal of this article was to seek a simple but equally reliable means of image analysis.

Case Report

An 83-year-old woman was admitted to our institution for volumetric expansion of the aneurysm sac due to a suspected type II endoleak detected during regular computed tomography (CT)-angiography follow-up at 16 months follow-up. The patient underwent endovascular aneurysm repair (EVAR) for 5.4 cm AAA using the E-Vita stent graft from Jotec Inc, Hechingen, Germany (30 × 18 × 150 mm + 16 × 18 × 70 mm), a nitinol stent graft, with supra-renal fixation. During follow-up the patient remained

asymptomatic and the CT-angiography at 6 months from the index procedure showed complete exclusion of AAA associated with a diameter decrease of 1.1 cm. The last CT-angiography revealed a 2-cm sac enlargement (maximum diameter 6.4 cm) due to a suspected type II endoleak.

CT-angiography was performed using a 64 slices LightSpeed VCT (GE Medical Systems, Salt Lake City, UT, USA) with and without contrast medium during arterial and venous phases; the thickness was 2.5 mm. At 2D view the endoleak was clearly evident in the arterial phase, and persisted in the venous phase, without identifying the origin of the leak.

Post-analysis included a 3D volume rendering and multiplanar reconstruction using OsiriX (vs 3.8.1 32-bit).³ Post-analysis images showed the presence of a hole at the distal portion of the main body in the docking zone near the flow divider (Figs. 1 and 2), leading to a complementary endovascular treatment.

The patient was treated in an operating theatre equipped with a portable C-arm (GE-OEC9800; GE Medical Systems, Salt Lake City, UT, USA) under local anaesthesia. A preoperative angiogram confirmed the diagnosis. Endurant stent graft limbs (20 × 20 × 80 mm, Medtronic-Cardiovascular, Santa Rosa, CA, USA) were placed to cover the graft's hole with satisfactory angiographic and clinical results.

Discussion

The rapid evolution of digital imaging techniques and the increasing number of multidimensional and multimodality studies

* Corresponding author. Tel.: +39 0577 233443; fax: +39 0577 233426.

E-mail address: setacci2@unisi.it (F. Setacci).

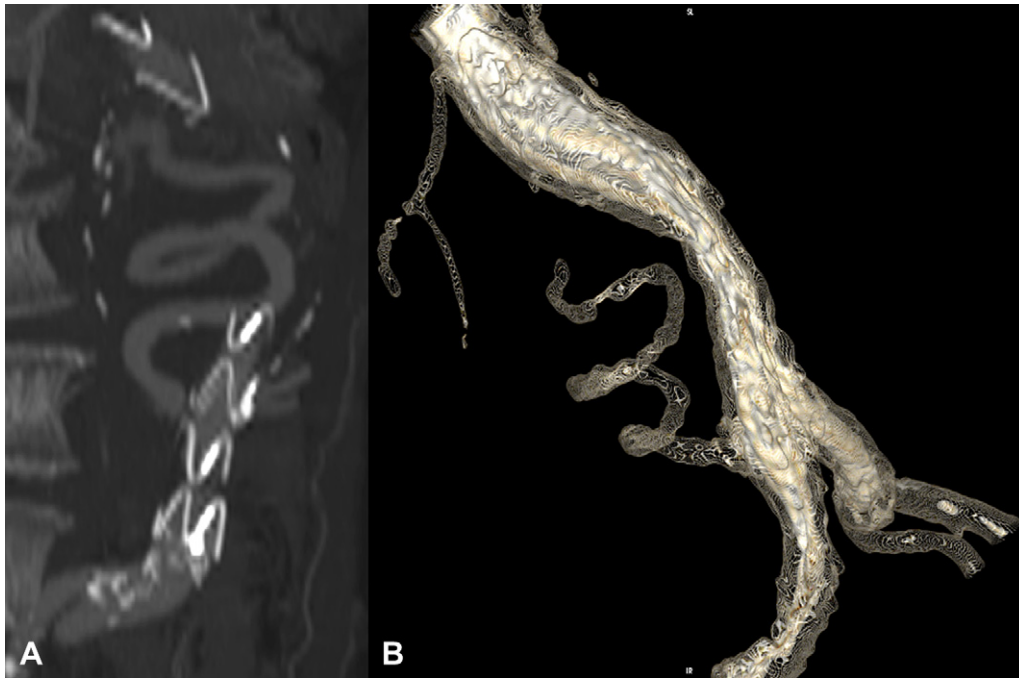


Figure 1. A: Multiplanar reconstruction confirms the presence of the hole in the prosthesis with a spiral leak into the aneurysm sac; B: A more elaborate 3-D reconstruction that allows a perfect spatial definition of the leak.

constitute a challenge for Picture Archiving and Communication Systems (PACS) workstations and image display programs. Traditional 2D image viewers and image display programs are becoming inadequate for interpretation of large sets of images.

Two-dimensional acquisition techniques of cross-sectional slices are evolving into 3D volume acquisitions with isotropic

voxel sizes resulting in very large data sets. The conventional reviewing of images slice by slice is too cumbersome for interpreting the 800–1000 slices that can be acquired with multi-detector CT scanners. These large sets of images require additional image processing and reformatting to make them suitable for efficient and rapid image navigation and interpretation. In most cases, this can be achieved only on high-end dedicated 3D workstations that provide thick-slab maximum intensity projections, orthogonal and oblique multiplanar reconstruction and 3D volume and surface rendering.⁴ Unfortunately, access to these techniques is usually limited to high-end users in a radiology department, preventing referring physicians, surgeons and care providers from benefitting from the extraordinary value of the multidimensional imaging techniques for decision making and patient management.

Today, many attractive alternatives to dedicated workstations are available. The most popular and easy to use is the software OsiriX, developed 8 years ago by Ratib and Rosset at the Department of Medical Imaging and Information Science at the University Hospital of Geneva, Switzerland. This software is distributed free of charge and the source code is available under the GNU General Public License open-source licensing agreement allowing other institutions to enhance and improve the existing version. It runs on a regular laptop or desktop Mac OS X computer^{5,6} and allows accurate rendering and measuring of the aorta and its branches. This software allows vascular surgeons to achieve accurate analysis of the CT images and organise eventual surgical or endovascular adjunctive procedures.⁷

The purpose of this report is that a simple analysis of axial images can lead to misinterpretation, also very important. A more detailed analysis (with 3D reconstructions) is essential for an accurate diagnosis.

However, we should not forget that software such as OsiriX cannot simply replace dedicated workstations or the experience of radiologists.

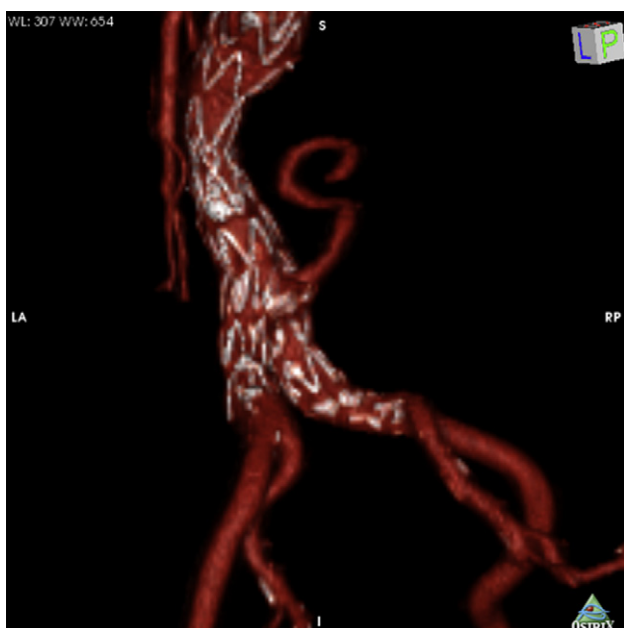


Figure 2. 3-D reconstruction with red vessels algorithm that show clearly the leak and his origin from the prosthesis.

Conflict of Interest/Funding

None.

References

- 1 Hobo R, Buth J, Eurostar collaborators. Secondary interventions following endovascular abdominal aortic aneurysm repair using current endografts. A EUROSTAR report. *J Vasc Surg* 2006;**43**:896–902.
- 2 Cao P, De Rango P, Verzini F, Parlani G. Endoleak after endovascular aortic repair: classification, diagnosis and management following endovascular thoracic and abdominal aortic repair. *J Cardiovasc Surg* 2010 Feb;**51**(1):53–69.
- 3 Ratib O, Rosset A. Open-source software in medical imaging: development of OsiriX. *Int J CARS* 2006;**1**:187–96.
- 4 Salgado R, Mulkens T, Bellinck P, Termote JL. Volume rendering in clinical practice, a pictorial review. *JBR-BTR* 2003;**86**(4):215–20.
- 5 Kirchgeorg MA, Prokop M. Increasing spiral CT benefits with postprocessing applications. *Review Eur J Radiol* 1998;**28**:39–54.
- 6 The Visualization Toolkit (VTK), <http://public.kitware.com/VTK/> Accessed February 20, 2004
- 7 Melissano G, Bertoglio L, Civelli V, Amato AC, Coppi G, Civilini E, et al. Demonstration of the Adamkiewicz artery by multidetector computed tomography angiography analysed with the open-source software OsiriX. *Eur J Vasc Endovasc Surg* 2009 Apr;**37**(4):395–400.