

ORIGINAL ARTICLE

E. Bardellini
I. Tonni
R. Micheli
A. Molinaro
F. Amadori
P. Flocchini
G. Piana
A. Majorana

Occlusal traits in children with neurofibromatosis type 1

Authors' affiliations:

E. Bardellini, I. Tonni, F. Amadori, P. Flocchini, A. Majorana, Department of Paediatric Dentistry, Dental School, University of Brescia, Brescia, Italy
R. Micheli, A. Molinaro, Unit of Child Neurology and Psychiatry, Spedali Civili, Brescia, Italy
G. Piana, Department of Paediatric Dentistry, Dental School, University of Bologna, Alma Mater Studiorum, Bologna, Italy

Correspondence to:

E. Bardellini
Dental Clinic
P.le Spedali Civili 1, 25133 Brescia
Italy
E-mail: bardelena@libero.it

Bardellini E., Tonni I., Micheli R., Molinaro A., Amadori F., Flocchini P., Piana G., Majorana A. Occlusal traits in children with neurofibromatosis type 1

Orthod Craniofac Res 2015. © 2015 John Wiley & Sons A/S. Published by John Wiley & Sons Ltd

Structured Abstract

Objectives – Literature is poor of data about the occlusion in children affected by neurofibromatosis type 1 (NF1). This case–control study investigated the occlusal traits in a group of children with NF1.

Setting and sample population – A hundred and fifteen children with NF1 were enrolled; non-NF1 controls were sequentially selected among subjects referred to the Pediatric Dentistry Department.

Material and methods – All patients underwent a clinical dental examination and a panoramic radiography. The following orthodontic variables were considered: molar relationship, overjet, overbite, cross-bite, scissor bite, and crowding/spacing.

Results – Class III molar relationship resulted significantly ($p = 0.01$) more common in children with NF1 than in the control group as well as the unilateral posterior cross-bite ($p = 0.0017$). Forty-three children with NF1 (37.3%) showed radiographic abnormalities; in one case, a plexiform neurofibroma was detected.

Conclusions – An early orthodontic evaluation might be planned in the management of children with NF1 to prevent or decrease the need for extensive orthodontic interventions.

Key words: child; dental occlusion; neurofibromatoses

Date:

Accepted 4 September 2015

DOI: 10.1111/ocr.12108

© 2015 John Wiley & Sons A/S.
Published by John Wiley & Sons Ltd

Introduction

Neurofibromatosis type 1 (NF1) is a common multisystemic Mendelian disorder, seen in 1:3000 individuals (phenotype MIM number 162200, gene number 613113). NF1 is an autosomal-dominant disease and the gene located on chromosome 17q11.2 also has a high spontaneous mutation rate (1). NF1 was well described as a clinical entity by von Recklinghausen in 1882, but diagnostic criteria were not established until 1988 (2). Oral manifestations can be found in almost 72% of NF1 patients. The oral manifestations of NF1 include dental abnormalities such as impacted, displaced, supernumerary, or missing teeth; bone abnormalities such as intrabony neurofibromas, hypoplasia and deformity of the jaw, enlarged mandibular foramen, flat gonial angle, coronoid notch deformity, pseudo elongation of condylar process; and soft tissue abnormalities such as oral neurofibromas. The typical clinical features of NF1 are usually apparent in childhood or early adolescence (3–6).

Literature is poor of data regarding the occlusal pattern in children with NF1. The aim of this study was to investigate the occlusal traits in a group of children with NF1 compared with a group of healthy children.

Material and methods

Sample selection

This study was designed as a case–control study. Cases were identified as patients affected by NF1 diagnosed at the Neuropsychiatric Department of the Pediatric Clinic and consecutively visited in the period from October 2011 to December 2012. NF1 was diagnosed according to the criteria outlined by the National Institutes of Health Consensus Development Conference (1988) by the neuropediatrician of the NF1 Centre and confirmed by the clinical geneticist (2).

One hundred and twenty-one children affected by NF1 (65 male and 56 female, age range 6–14 years, mean age 9.4, and SD 2.3 years,) were enrolled in the study. The control group

was composed of healthy children sequentially selected among patients referred to the Pediatric Dentistry Department and seeking dental treatment. Subjects with craniofacial anomalies (i.e., clefts lip and palate, syndromes) were excluded.

All children's parents gave informed consent according to the recommendations of the Declaration of Helsinki. Ethical approval for the research was granted by the Dental School Research Ethics Committee (DSREC).

Considered variables

All evaluations were carried out by the same two orthodontists who had previously undergone calibration to standardize their procedures. The assessment of dental occlusion was carried out in a clinical evaluation using dental mouth mirrors and millimetric rulers. Bone anomalies were estimated from presence/absence in panoramic radiographies. The following variables were considered:

Sagittal dimension. Molar relationship was determined according to Angle's classification. The incisor classification (7) and/or the canine relationship were considered for inclusion of patients with subdivision malocclusions (8) (e.g., class III molar relation on the right side and class I on the left side) in the class II or class III groups.

Overjet (OJ) was defined as the distance, parallel to the occlusal plane, from the most labial point of the incisal edge of the maxillary incisors to the most labial surface of the corresponding mandibular incisor and measured to the nearest half millimeter. The normal range of OJ was determined at 2 ± 1.5 . A negative OJ was registered when the lower incisors were in front of the upper incisors. Subjects with a negative OJ were also included in the group of patients with cross-bite (centrals and canines).

Vertical dimension. Overbite (OB) was considered as the vertical overlap of the incisors when the posterior teeth were in contact. The normal range was determined at one-third coverage of the lower incisors by the upper incisors. An edge-to-edge incisor relationship was recorded

when the maxillary and mandibular incisors occluded on their incisal edges. An open bite was registered when there was no vertical overlap between upper and lower incisors.

Transverse dimension. A posterior cross-bite was diagnosed when there was a crossover of at least one tooth in the buccal segment of the dental arches. A posterior cross-bite could be unilateral (right or left) or bilateral. A scissor bite was recorded when the palatal cusps of the upper posterior teeth were positioned buccal in relation to the buccal cusps of the lower posterior teeth.

Alignment anomalies. The difference between the sums of the mesio-distal tooth widths and available arch space was calculated for the upper and lower arches. Different components of the Index of Complexity, Outcome, and Need were used for measuring crowding/spacing in specific conditions (9). According to the orthodontic literature, crowding/spacing was also categorized as follows: no crowding or spacing, mild crowding (≤ 2 mm), moderate crowding (2.1–5 mm), and severe crowding (≥ 5.1 mm). Slightly irregular arches and crowding or spacing up to 0.5 mm in the upper or lower arch were included within normal limits. A midline diastema was diagnosed when there was a space of at least 2 mm between the maxillary central incisors.

The criteria for defining a normal occlusion were a class I canine and molar relationship, a positive OJ up to 3.5 mm, OB up to one-third coverage and well-aligned arches.

Bone anomalies. The presence/absence of NF specific radiographic alterations such as neurofibromas, hypoplasia and deformity of the jaw, coronoid or condylar process deformities was evaluated in a panoramic radiography.

Statistical analysis

Unpaired Student's *t*-test between the two groups was calculated for Gaussian distributed variables; chi-square test for the comparison of the two groups and Fisher's test for non-Gaussian distributed binomial variables were used. Any values less than $p < 0.05$ were interpreted as

statistically significant. To assess examiner reliability, 5% repeated examinations were undertaken throughout the period of data collection. The interclass correlation (ICC) was used for the clinical variables and the Cohen's kappa coefficient for the presence/absence of bone anomalies in the panoramic radiographies.

Results

Of 121 children affected by NF1, 6 were excluded from the study, 4 because it was impossible to perform the visit as they were uncooperative and 2 because the parents refused the panoramic radiography. The study group was composed by 115 children (61 male and 54 female, age range 6–14 years, mean age 9.2, and SD 2.6). A total of 115 healthy children (52 male and 63 female, age range 6–14 years, mean age 8.9, and SD 2.5 years) matched to cases for age, race, and area of residence were enrolled.

The ICC for the intrarater and inter-rater agreement on the clinical variables was 0.73 and 0.77, respectively, indicating a strong agreement for repeated measurements and for measurements realized by the two orthodontists. *K* value was 0.69 and 0.72, respectively, indicating good agreement for repeated measurements and between the 2 orthodontists in detecting bone abnormalities on the panoramic radiographies.

The prevalence of normal occlusion, class I, class II, class III molar relationships in the NF1 group and in the control group is reported in Table 1. Class III was significantly more frequent in children with NF1 than in the control group. The distribution of OJ, OB, cross-bite, and scissor bite in the NF1-group and in the control group is reported in Table 2. Posterior unilateral cross-bite was significantly more common in children with NF1. The maxillary and mandibular arch crowding/spacing are reported in Table 3; no statistically significant differences regarding these variables were observed between the two groups.

Forty-three NF1 patients (37.3%) showed radiographic bone abnormalities. Increase in dimension of the coronoid notch and deformity

Table 1. Distribution of the molar relationships (according to Angle classification) in the NF1 group and in the control group (χ^2 test)

Malocclusion type	NF	Control group	Significance
Normal occlusion	17 (14.7%)	24 (20.8%)	$p = 0.22$ OR = 0.66
Class I	46 (40%)	48 (41.7%)	$p = 0.07$ OR = 0.93
Class II	34 (29.56%)	36 (31, 3%)	$p = 0.08$ OR = 0.92
Class III	18 (15.6%)	7 (6.08%)	$p = 0.01^*$ OR = 2.86
Total (n)	115	115	

NS, not significant; *, significant value; and OR, odds ratio.

Table 2. Distribution of overjet, overbite, cross-bite, anterior open bite, and scissor bite in the NF1 group and in the control group (χ^2 test)

	NF1	Control group	Significance
<i>Overjet</i>			
>9 mm	1 (0.9%)	2 (1.7%)	$p = 0.56$ OR = 0.50
6 < to \leq 9 mm	3 (2.6%)	2 (1.7%)	$p = 0.65$ OR = 1.51
3.5 < to \leq 6 mm	28 (24.3%)	38 (33%)	$p = 0.14$ OR = 0.65
0 \leq to \leq 3.5 mm	72 (62.6%)	68 (59.1%)	$p = 0.58$ OR = 1.16
-1 \leq to < 0 mm	9 (7.8%)	4 (3.5%)	$p = 0.15$ OR = 2.36
-3.5 \leq to < -1 mm	2 (1.7%)	1 (0.9%)	$p = 0.56$ OR = 2.02
Reverse OJ overall	11 (9.5%)	5 (4.3%)	$p = 0.11$ OR = 2.33
<i>Overbite</i>			
\leq 1/3 coverage	72 (62.6%)	68 (59.1%)	$p = 0.58$ OR = 1.16
1/3 < to \leq 2/3 coverage	23 (20%)	28 (24.3%)	$p = 0.42$ OR = 0.78
2/3 < to \leq full coverage	15 (13%)	15 (13%)	$p = 1$ OR = 1
Deep overbite, full coverage	0	1 (0.8%)	$p = 0.31$ OR = 0
Edge-to-edge	5 (4.3%)	2 (1.73%)	$p = 0.24$ OR = 2.57
<i>Anterior open bite</i>			
\leq 1 mm	4 (3.47%)	2 (1.73%)	$p = 0.4$ OR = 2.04
1.1–2 mm	3 (2.6%)	0	$p = 0.08$ OR = 0
2.1–4 mm	1 (0.86%)	0	$p = 0.31$ OR = 0
>4 mm	0	0	–
Anterior open bite overall	8 (6.9%)	2 (1.73%)	$p = 0.06$ OR = 4.22
<i>Cross-bite</i>			
Unilateral posterior	18 (15.6%)	4 (3.47%)	$p = 0.0017^*$ OR = 5.15
Bilateral posterior	6 (5.21%)	3 (2.6%)	$p = 0.3$ OR = 2.06
<i>Scissor bite</i>			
	0	0	–

NS, not significant; *, significant value.

of the condylar head was observed in 41 children (35.6%), an increase in bone density and an enlarged mandible foramen was detected in 21 children (18.2%), and a decreased mandibular angle was observed in 5 children (4.3%). In one

case (8 years old, female), a plexiform neurofibroma was detected. The young girl presented with a swelling of the right cheek and a ptosis of the right eye. The intra-oral examination pointed out the absence of the upper and lower right

Table 3. Maxillary and mandibular arch crowding/spacing in the NF1 group and in the control group (χ^2 test)

	NF1	Control group	Significance
<i>Maxillary arch</i>			
Spacing	20	19	$p = 0.03$ OR = 1.06
Crowding			
No crowding or spacing	8	7	$p = 0.07$ OR = 1.15
Mild (≤ 2 mm)	44	39	$p = 0.47$ OR = 1.21
Moderate (2.1–5 mm)	28	32	$p = 0.36$ OR = 0.83
Severe (≥ 5.1 mm)	15	18	$p = 0.32$ OR = 0.81
<i>Mandibular arch</i>			
Spacing	22	16	$p = 0.28$ OR = 1.46
Crowding			
No crowding or spacing	8	5	$p = 0.73$ OR = 1.64
Mild (≤ 2 mm)	46	41	$p = 0.46$ OR = 1.20
Moderate (2.1–5 mm)	29	39	$p = 0.14$ OR = 0.66
Severe (≥ 5.1 mm)	10	14	$p = 0.38$ OR = 0.69

NS, not significant.

molars, overlaid by a tissue of soft consistency. The panoramic radiography showed a large radiolucent area in the right mandible causing a deformity of the condylar head and a displacement of the first molars, which resulted impacted (Figs 1 and 2).

In the control group, no radiographic bone abnormalities were found.

Discussion

While epidemiological data about orthodontic features in healthy children are widely available, there is a lack of reports about the prevalence of malocclusions in children with NF1. As the prevalence of malocclusion in different studies varies according to methods of assessment, racial differences and chronological age of the sample, the findings should be compared with caution (10).

In our study, both the NF1 group and the control group belonged to the same ethnic population, age, and gender group. The following

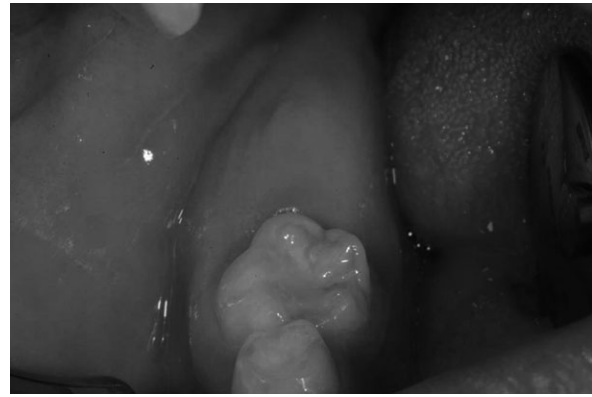


Fig. 1. Intra-oral view. Absence of the lower right molar.

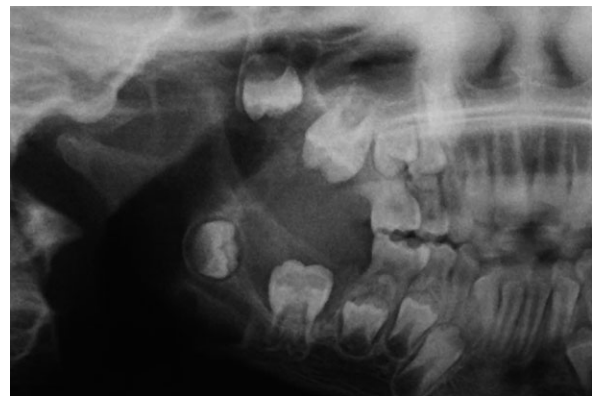

Fig. 2. Panoramic radiography details. Large radiolucent area in the right mandible, deformity of the condylar head, and displacement of the first molars.

orthodontic variables were evaluated: molar relationship, OJ, OB, cross-bite, scissor bite, and arch length discrepancies. According to our results, a significant difference ($p = 0.01$) between the prevalence of class III molar relationship in healthy children (6.08%) and in children with NF1 (15.6%) was observed. As regards the OJ, no statistically significant difference between the two groups was found, but the results show that the number of patients with a reverse OJ was more than double in the NF1 group than in the control group.

The percentages of class I, II, and III molar relationship and reverse overjet in the control group reflected those in the European population (11–17) indicating that our control group may be considered representative. The unilateral cross-bite resulted significantly ($p = 0.0017$ OR = 5.15) more frequent in the NF1 group (15.6%) than in the control group (3.47%) and

also the percentage of bilateral cross-bite, even if not statistically relevant, was double in the NF1 group (5.21%) if compared with the control group (2.6%). Posterior cross-bite in one of the most frequently occurring malocclusions in the deciduous and mixed dentitions, with a reported prevalence from 3% to 23% (18–23). Although a difference between the percentages of cross-bite in the NF1 group and in the control group was found, both these values fall within the normal ranges reported in literature.

However, the prevalence of cross-bite in the NF1 group (20.8%) is higher if compared with the prevalence of cross-bite of Italian schoolchildren (14.2%). It cannot be stated whether the higher percentage of class III molar relationship and reverse overjet in NF1 patients was supported by skeletal malocclusions because no lateral cephalograms were made *a priori* as not all patients would undergo an orthodontic treatment.

The main cause of craniofacial alterations in patients with NF1 is still controversial; genetic factors and local tumor growth can be involved in this deviated development. According to Friedrich et al., (6) the pattern of craniofacial malformation in NF1 could be caused by tumor invasion and local destruction. On the other hand, some studies found that the NF1 gene may regulate the growth of craniofacial structures and the development of bone deformity (24, 25). Dysplasia of the skeleton is an accepted manifestation of NF1 (26–30). Scaloping and resorption of the tibia with consecutive pseudarthrosis and sphenoid wing dysplasia are just two characteristic examples of bone malformations not necessarily associated with an adjacent neurofibroma (6, 26–30). Furthermore, scoliosis of the vertebral column is a frequent sign of NF1 and can be present with and without a neurofibroma (6). Many authors reported pathognomonic skeletal lesions, especially of the long bones (26). In particular, Lorson et al. (29) felt that the change of the shape of the coronoid notch was a pathognomonic feature and was as important as the characteristic sphenoid and orbital dysplasia in NF1 patients.

In our study, of 115 children with NF1, 43 patients showed radiographic features of NF1, that is, increase in dimension of the coronoid notch and deformity of the condylar head (35.6%), increase in bone density and enlarged mandible foramen (18.2%), and decreased mandibular angle (4.3%). These results are difficult to compare because there are few studies about radiographic features of the jaw bone in children with NF1, a part those about malformations associated with plexiform neurofibroma (6, 31, 32). These tumors frequently originate from the branches of the trigeminal nerve and invade both the cheek and oral cavity. Several studies reported hemifacial disfigurement caused by plexiform neurofibroma (7, 26–30). The frequency of these tumors is considered to be about 21% of NF1 patients; the trunk and the head and neck area are frequently affected (5, 6, 33, 34).

In our study, only in one patient (8 years old, female), the panoramic X-ray evidenced a plexiform neurofibroma. The MRI pointed out a plexiform neurofibroma along the right lateral orbit and the adjacent right upper eyelid, affecting not only the subcutaneous tissue but also the underlying muscle structures. The front part of the lateral orbit was thickened due to a bone dysplasia associated with the overlying plexiform neurofibroma.

The mandibular features observed in our study could represent the manifestation of a mesodermal dysplasia, in the sense of ‘altered growth’, without direct association with neurofibromatosis tissue. A role of these osseous abnormalities in inducing a protrusion of the mandible, causing the occlusal traits found in the NF1 children, could be speculated. Similarly, the posterior unilateral cross-bite, that resulted more common in children with NF1, could be ascribed to abnormalities in growth, as it was not associated with neurofibroma. Dysplastic bony lesions of the maxilla or mandible could induce a functional shift of the mandible toward the cross-bite side. The role of the orthodontist is to detect these anomalies in NF1 patients and to correct the malocclusion without presuming to change the pattern of growth of these patients.

NF1 is an extraordinarily variable and progressive condition. Neurofibroma tends to appear in teenage or young adult years. Malignancy, pheochromocytomas, and paraspinal plexiform neurofibroma are mostly problems of adults. This study shows for the first time the presence of occlusal disorders in children with NF, possibly due to a dysplasia of bony structures. A limit of this study is the lack of cephalometric data; however, the aim was to investigate solely the occlusal traits. In a next step, it may be interesting to analyze cephalograms in the potential candidates for orthodontic treatment in order to identify skeletal malocclusion.

Conclusion

The assessment of the occlusal traits in children with NF1 highlighted a significantly higher percentage of class III molar relationship and reverse overjet compared with healthy children.

A multidisciplinary approach for the comprehensive care of children with NF1 is desirable. In particular, an early orthodontic evaluation

might be planned in the pediatric management of these patients, in order to intercept the occlusal disturbances and to prevent or decrease the need for extensive orthodontic interventions.

Clinical relevance

Our study describes the occlusal traits in children with NF1. To the best of our knowledge, this is the first study reporting occlusal abnormalities in these patients. Here, we found that children with NF1 show significantly higher prevalence of class III molar relationship than healthy children. A role of the bone abnormalities, pathognomonic of NF1, in inducing a functional protrusion of the mandible, could be speculated. The clinical relevance of this study is that an early orthodontic evaluation might be planned in the pediatric management of these patients.

Acknowledgements: The authors are grateful to Lorena Kondo for helping with database. The authors received no financial support and declare no potential conflicts of interest with respect to the authorship and/or publication of this article.

References

1. Micheli R. Diagnostic and follow-up protocols for neurofibromatosis types 1 and 2. In: Curatolo P, Riva D, editors. *Neurocutaneous Syndrome in Children*. Montrouge, France: John Libbey Eurotext; 2006. pp. 229–38.
2. National Institutes of Health Consensus Development Conference. Neurofibromatosis conference statement. *Arch Neurol* 1988;45: 575–80.
3. Geist JR, Gander DL, Stefanac SJ. Oral manifestations of neurofibromatosis types I and II. *Oral Surg Oral Med Oral Pathol* 1992;73: 376–82.
4. Neville BW, Damm DD, Allen CM. *Oral and Maxillofacial Pathology*. Philadelphia: WB Saunders Company; 1995. pp. 381–3.
5. D'Ambrosio JA, Langlais RP, Young RS. Jaw and skull changes in neurofibromatosis. *Oral Surg Oral Med Oral Pathol* 1988;66:391–6.
6. Friedrich RE, Giese M, Schmelzle R, Mautner VF, Scheuer HA. Jaw malformations plus displacement and numerical aberrations of teeth in neurofibromatosis type 1: a descriptive analysis of 48 patients based on panoramic radiographs and oral findings. *J Craniomaxillofac Surg* 2003;31:1–9.
7. British Standards Institutes. *Glossary of Dental Terms (BS 4492)*. London: BSI; 1983.
8. Cassidy SE, Jackson SR, Turpin DL, Ramsay DS, Spiekerman C, Huang GJ. Classification and treatment of Class II subdivision malocclusions. *Am J Orthod Dentofacial Orthop* 2014;145:443–51.
9. Daniels CP, Richmond S. The development of the index of complexity, outcome and the index (ICON). *J Orthod* 2000;27:149–62.
10. Proffit WR, Fields HW. *Contemporary Orthodontics*. Saint Louis: Mosby Company; 1986.
11. Pagnacco A, Miotti F, Zamperetti N, Balestro G, Franchini D. Epidemiological study of the prevalence of caries, periodontal diseases and malocclusion in a school population. *Mondo Ortod* 1991;16:197–207.
12. Lux CJ, Dücker B, Pritsch M, Komposch G, Niekusch U. Occlusal status and prevalence of occlusal malocclusion traits among 9-year-old schoolchildren. *Eur J Orthod* 2009;31:294–9.
13. Helm S. Malocclusion in Danish children with adolescent dentition: an epidemiologic study. *Am J Orthod* 1968;54:352–66.
14. Souames M, Bassigny F, Zenati N, Riordan PJ, Boy-Lefevre ML. Orthodontic treatment need in French schoolchildren: an epidemiological study using the index of

- orthodontic treatment need. *Eur J Orthod* 2006;28:605–9.
15. Thilander B, Myrberg N. The prevalence of malocclusion in Swedish schoolchildren. *Scand J Dent Res* 1973;81:12–20.
 16. Foster TD, Day AJW. A survey of malocclusion and the need for orthodontic treatment in a Shropshire school population. *Br J Orthod* 1974;1:73–178.
 17. Perillo L, Masucci C, Ferro F, Apicella D, Baccetti T. Prevalence of orthodontic treatment need in southern Italian schoolchildren. *Eur J Orthod* 2010;32:49–53.
 18. Thilander B, Pena L, Infante C, Parada SS, de Mayorga C. Prevalence of malocclusion and orthodontic treatment need in children and adolescents in Bogota, Colombia. An epidemiological study related to different stages of dental development. *Eur J Orthod* 2001;23:153–67.
 19. Thilander B, Lennartsson B. A study of children with unilateral posterior crossbite, treated and untreated, in the deciduous dentition–occlusal and skeletal characteristics of significance in predicting the long-term outcome. *J Orofac Orthop* 2002;63:371–83.
 20. Brin I, Ben-Bassat Y, Blustein Y, Ehrlich J, Hochman N, Marmary Y. Skeletal and functional effects of treatment for unilateral posterior crossbite. *Am J Orthod Dentofacial Orthop* 1996;109:173–9.
 21. Kutin G, Hawes RR. Posterior crossbites in the deciduous and mixed dentition. *Am J Orthod* 1969;56:491–504.
 22. Kurol J, Bergland L. Longitudinal study and cost-benefit analysis of the effect of early treatment of posterior crossbites in the primary dentition. *Eur J Orthod* 1992;14:173–9.
 23. Sandikcioglu M, Hazar S. Skeletal and dental changes after maxillary expansion in the mixed dentition. *Am J Orthod Dentofacial Orthop* 1997;111:321–7.
 24. Visnapuu V, Peltonen S, Tapio T, Peltonen J, Happonen RP. Radiographic findings in the jaws of patients with neurofibromatosis 1. *J Oral Maxillofac Surg* 2012;70:1351–7.
 25. Alwan S, Armstrong L, Joe H, Birch PH, Szudek J, Friedman JM. Associations of osseous abnormalities in neurofibromatosis 1. *Am J Med Genet A* 2007;143A:1326–33.
 26. Lee L, Yan YH, Pharoah MJ. Radiographic features of the mandible in neurofibromatosis: a report of 10 cases and review of the literature. *Oral Surg Oral Med Oral Pathol Oral Radiol Endod* 1996;81:361–7.
 27. Kaplan I, Calderon S, Kaffe I. Radiological findings in jaws and skull of neurofibromatosis type 1 patients. *Dentomaxillofac Radiol* 1994;23:216–20.
 28. Holtzman L. Radiographic manifestations and treatment considerations in a case of multiple neurofibromatosis. *J Endod* 1998;24:442–3.
 29. Lorson EL, DeLong PE, Osbon DB, Dolan KD. Neurofibromatosis with central neurofibroma of the mandible: review of the literature and report of case. *J Oral Surg* 1977;35:733–8.
 30. Müller H, Slotweg PJ. Maxillofacial deformities in neurofibromatosis. *J Maxillofac Surg* 1981;9:89–95.
 31. Sigillo R, Rivera H, Nikitakis NG, Sauk JJ. Neurofibromatosis type 1: a clinicopathological study of the orofacial manifestations in 6 pediatric patients. *Pediatr Dent* 2002;24:575–80.
 32. Hisatomi M, Asaumi J, Konouchi H, Yanagi Y, Kishi K. Bone deformity showing a deep coronoid notch of the mandible in a patient with neurofibromatosis type 1. *Dentomaxillofac Radiol* 2005;34:380–3.
 33. Waggoner DJ, Towbin J, Gottesman G, Gutmann DH. Clinic-based study of plexiform neurofibromas in neurofibromatosis 1. *Am J Med Genet* 2000;92:132–5.
 34. Depprich R, Singh DD, Reinecke P, Kübler NR, Handschel J. Solitary submucous neurofibroma of the mandible: review of the literature and report of a rare case. *Head Face Med* 2009;13:5–24.