

## Solitary metastasis of the patella as the first manifestation of lung cancer

### A case report

U. E. Pazzaglia, D. Barbieri, and P. Cherubino

Clinica Ortopedica dell'Università di Pavia I.R.C.C.S. Policlinico San Matteo, Via Taramelli, 3, I-27100 Pavia, Italy

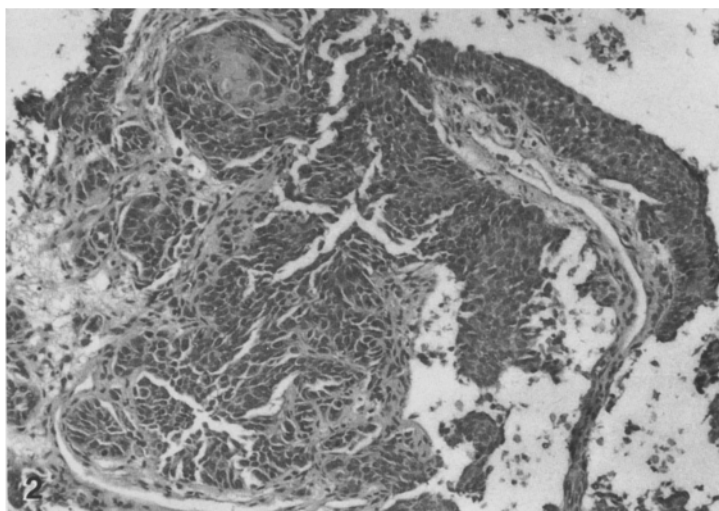
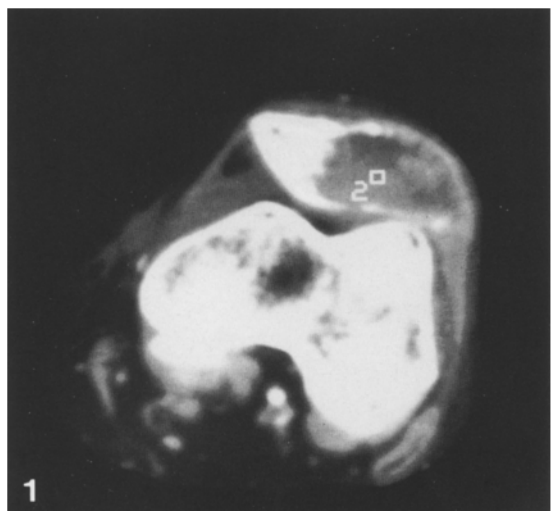
**Summary.** *A man of 71 was seen with a solitary metastasis in the patella as the first presentation of carcinoma of the lung.*

**Résumé.** *Observation d'un homme de 71 ans, porteur d'une métastase isolée au niveau de la rotule, représentant le premier symptôme d'un cancer du poumon.*

A 71 year old man was admitted complaining of pain and swelling of the left knee for three months. He had suffered from angina pectoris for two years and had been a heavy smoker, but had

ceased smoking for the previous two years. His past medical history was otherwise not significant.

Physical examination revealed a painful swelling of the anterior surface of the patella, with limited flexion of the knee and quadriceps wasting. Investigation by radiographs and computerised tomography revealed a lytic lesion destroying half of the patella and extending into the soft tissues (Fig. 1). Skeletal survey and bone scintigraphy confirmed that this was a solitary lesion. The Erythrocyte Sedimentation Rate was elevated and there was a normochromic anaemia. Other investigations, including a chest radiograph, were normal.



**Fig. 1.** Computerized tomography shows destruction of the patella with invasion of soft tissues

**Fig. 2.** (Haematoxylin-eosin, 240x) Histological specimen of the patella. Metastasis of epidermoid carcinoma

Patellectomy and curettage of the soft tissues was performed. Histological examination of the specimen revealed a metastasis of epidermoid carcinoma, suggestive of a lung primary (Fig. 2). Lung tomography showed a mass in the left hilum and bronchoscopy with biopsy confirmed the diagnosis of a primitive bronchial carcinoma.

### Discussion

Tumours of the patella are rare and in most reported cases are osteoclastomas [1–4]. According to our knowledge metastases to the patella have not previously been reported. The diagnosis might

have been suspected in the presence of other bone metastases or of the primary tumour. The occurrence of this solitary bone lesion as a first manifestation of a lung carcinoma makes this case most unusual.

### References

1. Baldini N, Sudanese A (1984) Due casi di TGC della rotula. *Chir Org Mov* 69: 271
2. Cole WH (1925) Primary Tumors of Patella. *J Bone Joint Surg* 7: 637–654
3. Enneking WF (1983) *Musculoskeletal Tumor Surgery*. Churchill Livingstone, New York, pp 626
4. Linscheid RL, Dahlin DC (1966) Unusual Lesion of the Patella. *J Bone Joint Surg [Am]* 48: 1359–1365