

# Deep inferior epigastric artery perforated rectus abdominis free flap for head and neck reconstruction

Johnny Cappiello · Cesare Piazza · Valentina Taglietti · Piero Nicolai

Received: 13 May 2011 / Accepted: 16 August 2011 / Published online: 25 August 2011  
© Springer-Verlag 2011

**Abstract** The deep inferior epigastric artery perforated rectus abdominis (DIEAP-ra) free flap is a modification of the classic myocutaneous DIEA free flap in which only fasciocutaneous tissue is harvested based on the paraumbilical perforators of the medial row. The aim of this retrospective study is to describe our experience with this reconstructive technique in head and neck surgery. Between 2004 and 2009, 24 patients affected by oncologic maxillofacial, skull base, oral, and oropharyngeal defects were submitted to reconstruction with DIEAP-ra. After harvesting the DIEAP-ra, the longitudinally split muscular belly was sutured and the anterior rectus sheath closed with a nonabsorbable mattress suture without inlay mesh interposition. Surgical defects encompassed half of the hard palate in ten patients, orbit and part of the cranial vault in one, radical extended parotidectomy in four, subtotal glossectomy in seven, and total glossectomy in two cases. The only complete flap necrosis (4%) developed as a consequence of an orocutaneous fistula and required a second latissimus dorsi free flap. Another case (4%) developed a partial necrosis for oropharyngeal fistula after total glossectomy that healed after transposition of a pedicled myofascial pectoralis major. Two patients (8%) presented a minor salivary fistula that healed by medication alone. No major complication of the donor site was observed. DIEAP-ra is a valid alternative to the DIEA free flap when applied to complex maxillofacial or tongue major defects. Its greatest advantages are the reduced donor site morbidity and a more adjustable thickness of the skin paddle, particularly in females and obese patients.

**Keywords** Rectus abdominis · Free flap · Perforated flap · Head and neck reconstruction · Skull base · Glossectomy

## Introduction

In the continuing quest for better results in reconstructive techniques, microvascular surgeons have used a variety of flaps to achieve excellence in form and function, and reduce morbidity at the donor site. In this light, fasciocutaneous perforator flaps represent a gradual sophistication in microsurgery and should be viewed as a further refinement in the ability to transfer vascularized tissues. By selectively harvesting the skin above the underlying muscle, capturing the vascularization from musculo-, septomusculo-cutaneous, or septocutaneous perforators, a reduction in donor site morbidity has been demonstrated [1]. Moreover, defatting and thinning the flap from its deep portion toward more superficial layer, allows the possibility to obtain pliable skin paddles even from thick areas such as the abdomen and thigh.

The perforated rectus abdominis or deep inferior epigastric artery perforated rectus abdominis (DIEAP-ra) free flap [2] is a relatively new procedure developed as a modification of the transverse rectus abdominis muscle (TRAM) flap, predominantly used in breast reconstruction [3]. It provides a large amount of skin and subcutaneous tissue, without the donor site morbidity associated with TRAM flap [4]. Since June 2004, we have applied the DIEP-ra in head and neck reconstruction of selected patients, an application that has so far received only minor attention in the recent literature [5–7]. We herein describe our experience with this reconstructive technique, focusing on its indications, surgical details, complications, and results.

J. Cappiello · C. Piazza (✉) · V. Taglietti · P. Nicolai  
Department of Otorhinolaryngology-Head and Neck Surgery,  
University of Brescia, Spedali Civili of Brescia,  
Piazza Spedali Civili 1, 25123 Brescia, Italy  
e-mail: ceceplaza@libero.it

## Materials and methods

From June 2004 to February 2009, 24 patients (15 males, 9 females, age range 15–80 years, mean 58) affected by maxillofacial, skull base, oral, or oropharyngeal surgical defects following oncologic procedures were submitted to microvascular reconstruction with DIEAP-ra free flap at the Department of Otorhinolaryngology, Head and Neck Surgery, University of Brescia, Italy (Tables 1 and 2). This flap represents 15% of the total number of microvascular flaps and 75% of the DIEA free flaps harvested during the same period at our Institution.

Potential paraumbilical perforators were preoperatively identified using a 10 MHz Doppler ultrasound probe (Park Medical®, Aloha, Oregon, USA) and marked on the skin with a pencil by one of two microvascular surgeons (J.C. and C.P.). Scarring due to previous abdominal surgery, extreme obesity, and bilateral absence of any suitable perforator were considered the only strict exclusion criteria. In contrast, an extremely thin body habitus (abdominal subcutaneous

thickness <1 cm) was considered an indication for harvesting a classic DIEA free flap. In case of DIEAP-ra flap, the skin paddle was outlined along a vertical axis to include the larger perforators among those located medially at the level of the paraumbilical area (zones 1 and 2). All flaps were harvested at the time of tumor ablation and raised in a vertical direction (from cranial to caudal) on one side of the midline.

The subcutaneous portion of the flap was dissected free from the anterior rectus sheath by visualizing and preserving each sizeable myocutaneous perforator (Fig. 1). The choice of the most appropriate perforators to be used for vascularization of the skin paddle was then made comparing their size, appearance, and position in relation to the outlined flap. In our series, DIEAP-ra was elevated on 1, 2, or 3 perforators in 2, 20, and 2 patients, respectively, depending on the perforator(s) size and their anatomical location. The anterior rectus sheath was then incised along a vertically oriented ellipse encircling the perforators. Accordingly, a strip of sheath 1 cm wide and

**Table 1** Maxillo-facial and skull base surgical defects in 15 patients

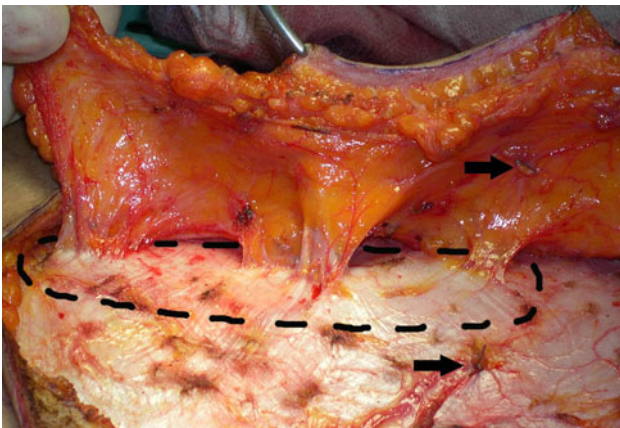
Pt. no.	Gender, age	Surgical defect	Previous treatment	Recipient vessels	Flap-related complications
1	F, 33	Extended radical maxillectomy, OE	CHT	STA, STV	–
2	F, 72	Extended radical ethmoido-maxillectomy, OE, anterior skull base dura resection	Surgery, RT	STA, STV	–
3	M, 53	Extended radical maxillectomy, PPF, ITF, and clivus resection	–	FA, FV	–
4	F, 62	Extended radical maxillectomy, PPF, ITF resection, infraorbital skin excision, OE	CHT	FA, FV	–
5	F, 67	Extended radical maxillectomy, OE	–	STA, STV	–
6	M, 80	Extended radical maxillectomy, skin excision, OE and anterior skull base dura resection	–	STA, STV	–
7	M, 65	Extended radical maxillectomy, OE and anterior skull base resection	CHT	STA, STV	–
8	M, 65	Extended radical maxillectomy, OE	–	FA, FV	Minor donor site skin dehiscence requiring medical therapy
9	F, 69	Ethmoido-maxillectomy, OE	–	STA, STV	–
10	M, 52	Anterior cranio-facial resection with partial frontal bone and dural excision, OE	Surgery, CHT-RT	STA, STV	–
11	M, 75	Total parotidectomy extended to the MS, PFS, and oropharynx	–	FA, FV	–
12	F, 59	Auricolectomy, total parotidectomy extended to the skin, subtotal petrosectomy with dural resection	–	FA, IJV (T–L)	–
13	F, 53	Total parotidectomy extended to the skin, MS and PFS	Surgery RT	TCA, TCV	Total necrosis requiring second free flap (latissimus dorsi)
14	F, 38	Total parotidectomy extended to MS, PFS	–	FA, TFL	–
15	M, 52	Extended radical maxillectomy, OE	Surgery	FA, IJV (T–L)	Fistula requiring medical treatment

*F* female, *M* male, *OE* orbital exenteration, *PPF* pterygo-palatine fossa, *ITF* infratemporal fossa, *MS* masticatory space, *PFS* parapharyngeal space, *CHT* chemotherapy, *RT* radiotherapy, *STA* and *STV* superficial temporary artery and vein, *FA* and *FV* facial artery and vein, *IJV (T–L)* internal jugular vein (termino-lateral anastomosis), *TCA* and *TCV* transverse cervical artery and vein, *TFL* thyro-facial-lingual trunk

**Table 2** Oral and oropharyngeal surgical defects in nine patients

Pt. no.	Gender, age	Surgical defect	Previous treatment	Recipient vessels	Flap-related complications
16	M, 54	Total glossectomy	CHT-RT	FA, FV	–
17	M, 63	Anterior pelvectomy and subtotal glossectomy	–	FA, FV	–
18	M, 77	Hemiglossectomy extended to the lateral wall of the oropharynx and part of the soft palate	–	FA, IJV (T–L)	–
19	M, 75	Lateral wall of the oropharynx and rhinopharynx, part of the soft and hard palate	–	FA, IJV (T–L)	–
20	F, 15	Anterior pelvectomy and subtotal glossectomy	–	FA, FV	Minor salivary fistula requiring medical therapy
21	M, 64	Total glossectomy	CHT-RT	FA, IJV (T–L)	Major salivary fistula requiring revision with pedicled myofascial pectoralis major flap
22	M, 44	Anterior pelvectomy and subtotal glossectomy	–	FA, IJV (T–L)	–
23	M, 51	Subtotal glossectomy	–	FA, TFL	–
24	M, 62	Anterior pelvectomy and subtotal glossectomy	–	LA, TFL	–

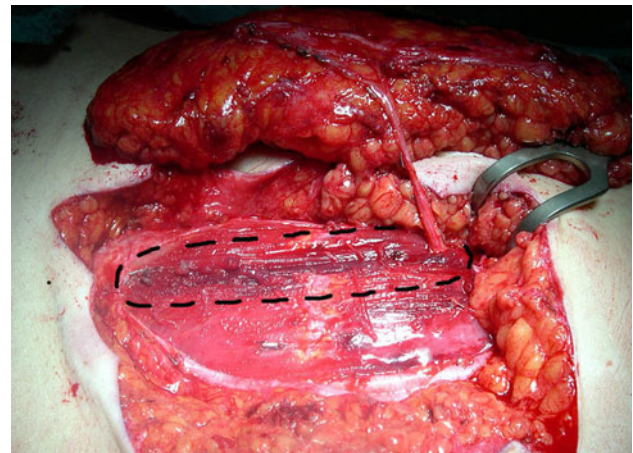
*F* female, *M* male, *CHT* chemotherapy, *RT* radiotherapy, *LA* lingual artery, *FA* and *FV* facial artery and vein, *IJV (T–L)* internal jugular vein (termino–lateral anastomosis), *TFL* thyro-facial-lingual trunk



**Fig. 1** Right-sided DIEAP-ra flap-based on three paraumbilical musculo-cutaneous perforators of the medial row. The dotted line indicates the small portion of anterior rectus sheath to be removed together with the skin paddle. Arrows indicate one perforator of the lateral row that was divided during flap harvesting

3–4 cm long was removed from the underlying muscular belly. Subsequently, the remaining part of the incised but mostly preserved anterior rectus sheath was detached from the muscle to carry on the subsequent perforator and pedicle intramuscular dissection (Fig. 2). The rectus muscle was longitudinally split along its fibers making every effort to spare any intervenient intercostal nerves. The skin incision was then extended to the groin for the deep inferior epigastric pedicle dissection, as routinely performed in harvesting a non-perforated DIEA free flap. This resulted in a long pedicle, with large diameter vessels.

The skin paddle obtained was single in 16 patients and double (after de-epithelialization of the interposed bridge of skin) in the remaining 8 cases (Fig. 3a). Flap sizes



**Fig. 2** Right-sided DIEAP-ra flap based on two paraumbilical musculo-cutaneous perforators of the medial row. The dotted line indicates the removed portion of anterior rectus sheath (the rest is rebated medially and laterally). Note the longitudinally divided muscle belly and the long DIE pedicle dissected nearly up to the inguinal region

ranged from 6 × 8 to 12 × 14 cm. The thickness of the skin paddle ranged from 1.4 to 2 cm (partial flap thinning was performed in two cases with subcutaneous thickness exceeding 2.5 cm). After harvesting the DIEAP-ra, the longitudinally split muscular belly was sutured and the anterior rectus sheath closed by using a mattress nonabsorbable suture without inlay mesh interposition (Fig. 3b). A suction drainage was positioned and left in place for at least 5 days. Flap inset was accomplished (Fig. 3c and d) and microanastomosis performed with a suitable artery and vein (Tables 1 and 2). Assisted deambulation was allowed 3–4 days after surgery and an abdominal garment prescribed for at least 6 weeks.

## Results

Surgical defects encompassed half of the hard palate in ten patients (with simultaneous ethmoid, orbital, and anterior cranial base defect in 7 cases), orbit and part of the cranial vault with overlying skin in one, radical extended parotidectomy in four, subtotal glossectomy in seven, and total glossectomy in two.

The only complete flap necrosis (4%) developed as a consequence of an orocutaneous fistula due to parapharyngeal space infection after extended total parotidectomy following the surgery and radiotherapy. It required surgical revision and a second free flap (latissimus dorsi) for defect restoration. Another case (4%) developed a partial necrosis for oropharyngeal fistula after total glossectomy following chemo-radiation failure, with no alteration of flap viability and bulk. The fistula healed after transposition of a pedicled myofascial pectoralis major flap. Two patients (8%) presented a minor salivary fistula due to a small intraoral dehiscence, healed by secondary intention after standard medical therapy. One patient died for myocardial infarction on the third postoperative day.

The only donor site complication was a minor abdominal skin dehiscence healed with medications. No major complications, such as abdominal wound infection and laparocoele, were observed at the donor site up to the last consultation (December 2010).

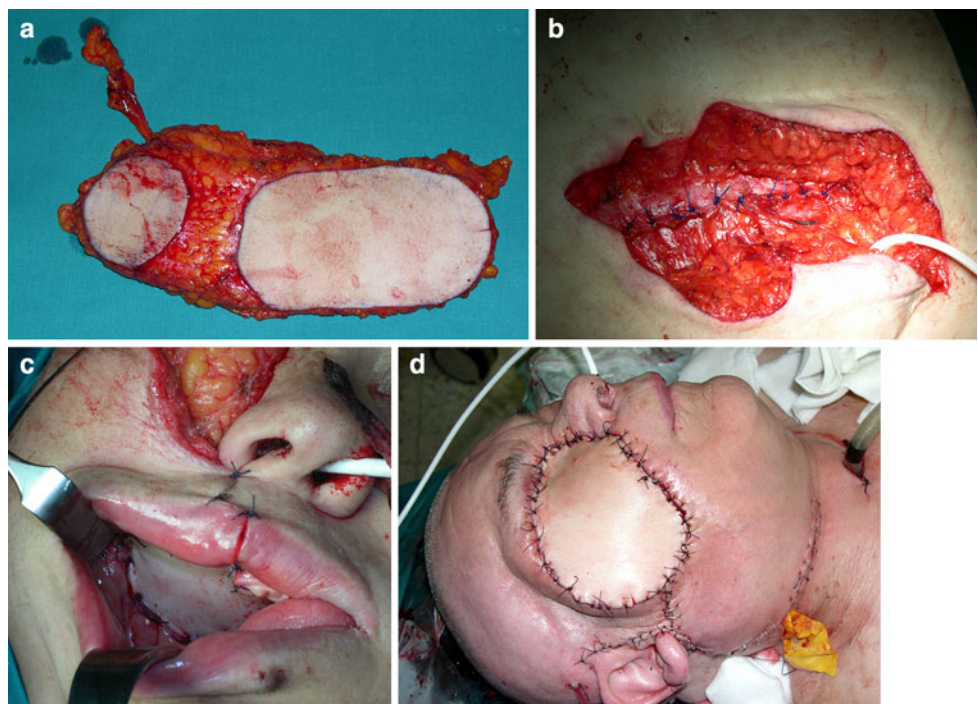
Postoperatively, a normal or soft oral diet was obtained in all patients submitted to subtotal or total glossectomy after a mean of 19 days (range 12–28), without major

limitations in speech intelligibility. No patient remained dependent on a tracheotomy and/or percutaneous gastrostomy feeding-tube.

## Discussion

Since its original description in 1982, the radial forearm free flap has become the workhorse microsurgical flap in head and neck reconstruction, providing pliable replacement tissue with a long pedicle and large-diameter vessels [8]. Drawbacks of this flap, however, are the potential for poor donor site appearance and tendon exposure [9]. In addition, the bulk of tissue available is limited, so that for larger soft tissue defects, the subscapular system (scapular and latissimus dorsi) muscular or myocutaneous flaps have become more popular [10]. The subscapular system provides good tissue bulk; however, it cannot usually be raised at the same time as tumor ablation and frequently requires patient repositioning for flap harvest. Muscle flaps also provide good tissue bulk; however, because they are not innervated, they usually tend to shrink with time, thus making the long-term results somewhat unpredictable. In head and neck reconstruction, another flap that has raised increasing interest is the anterolateral thigh, a perforator-based tissue transfer arising from the lateral circumflex femoral vessels [11]. It represents a reliable flap due to its versatility, even though its application in Western countries can be sometimes limited by unfavorable body habitus. When compared to the above mentioned free flap options, DIEA-based free

**Fig. 3** DIEAP-ra flap harvested for reconstruction of a right extended maxillectomy involving the ethmoid, eye, anterior skull base, and facial skin. The flap was composed of two skin paddles (the smaller for the hard palate, the other for orbital cavity and middle third of the facial skin) joined through an interposed bridge of de-epithelialized subcutaneous tissue (a). Closed rectus abdominis muscle and anterior sheath (b). Flap inset at the level of the surgical defect, with suture of the smaller skin paddle already accomplished (c). Final appearance after complete closure (d)



flaps have distinct advantages: they allow harvesting larger and thicker skin paddles (mandatory when dealing with total/subtotal glossectomy or extensive maxillofacial defects) than a radial forearm free flap; they have a much more constant and reliable vascular anatomy when matched with the anterolateral thigh; they do not require patient's repositioning during surgery as in latissimus dorsi and parascapular free flaps, thus making the two-team approach feasible.

The classic DIEA myocutaneous free flap can give rise to donor site problems, such as abdominal weakness or herniation, particularly if the anterior fascia is extensively harvested together with the skin paddle [12, 13]. Koshima and Soeda [14] first described the DIEAP-ra in 1989 and subsequently popularized the para-umbilical perforator variation [15]. This flap was first applied to breast reconstruction in 1994 by Allen and Treece [3] in an attempt to minimize these donor-site complications.

The DIEAP-ra has several advantages over other available flaps in head and neck reconstruction, especially when tissue bulk is required. Because there is no muscle or fascia harvested, donor-site morbidity is greatly reduced. Mizgala et al. [16] examined 150 patients 5–7.5 years postoperatively to define the long-term consequences of the TRAM flap procedure. Their findings showed decreased abdominal strength and sit-up performance, asymptomatic bulging from the harvest site, abdominal laxity, and increased back pain. Kroll et al. [17] showed that patients who had breast reconstructions with DIEAP-ra flap required significantly less analgesia than a similar cohort of patients reconstructed with TRAM flaps, again indicating that donor site morbidity is reduced when the perforator flap is used as an alternative to the myocutaneous version. Moreover, Ong et al. [18] and Yano et al. [19] underlined the additional value of DIEAP-ra in young females who desire to become pregnant or in physical laborers and athletes.

Although most of previous reports on DIEAP-ra have described a transverse or oblique orientation [20, 21], all flaps in our series were vertically oriented on one side of the midline, centered at the level of the paraumbilical region, thus placing the entire skin paddle in zone 1 and 2 of the DIEA circulation. This orientation restricts the paddle width to some degree; however, because less tissue is generally required in head and neck as compared with breast reconstruction, this was not an issue in the present series.

As previously reported, dissection of the perforator(s) in DIEAP-ra can be tedious [20]. In fact, elevation of perforator flaps always requires meticulous dissection of the myocutaneous perforator(s) through the underlying muscle. Recent anatomical studies on cadavers indicate that use of the medial row of perforators reduce the potential risks of muscle denervation [22]. Motor nerve fibers run from

lateral to medial beneath the muscle belly, so that harvesting DIEAP-ra based on lateral row perforators can expose the patient to muscle denervation and abdominal wall weakness. A major drawback of this technique is that it is somewhat difficult and tedious to spare the entire muscle belly, and is not suitable in those cases without or with inconsistent medial perforators. On the other hand, this was rarely the case in our experience, where medial perforators were generally more abundant and larger in size than the lateral ones.

Kaplan and Allen [23] reported that operating time increases by 2 h for the DIEAP-ra versus TRAM flap procedure. We agree with these authors that operative time is significantly prolonged during the learning curve of dissection. However, with increasing experience the time needed for harvesting can be significantly reduced. In the present series, we did not measure the time needed for harvesting the flap. However, because DIEAP-ra is routinely harvested concomitantly with the oncologic resection, adding this technique did not substantially prolong the overall operative time. In our experience the use of a Doppler probe to identify the main perforator vessels, even while not essential, is reliable to design the skin paddle centered over them, and significantly impacts the time needed to identify and preserve these vessels. Once dissected, the perforator(s) can be followed to the DIE artery and vein, giving good vessels diameter and pedicle length, thus facilitating microanastomosis on both sides of the neck if necessary.

In conclusion, DIEAP-ra is a valid alternative to the classic myocutaneous DIEA free flap in the head and neck area, particularly when applied to complex maxillofacial or major tongue defects (subtotal and total glossectomies). Its greatest advantages, in spite of a more time-consuming and tedious dissection of the perforator vessels, are reduced donor site morbidity and a greater adjustable thickness of the skin paddle, especially in females and obese patients. Even though the classic DIEA flap remains a useful tool in the contemporary reconstructive armamentarium, its perforated version can reliably substitute it in the majority of head and neck cancer patients.

## References

1. Blondeel N, Vanderstraeten GG, Monstrey SJ, Van Landuyt K, Tonnard P, Lysens R, Boeckx WD, Matton G (1997) The donor site morbidity of free DIEP flaps and free TRAM flaps for breast reconstruction. *Br J Plast Surg* 50:322–330
2. Geddes CR, Morris SF, Neligan PC (2003) Perforator flaps: evolution, classification, and applications. *Ann Plast Surg* 50: 90–99
3. Allen RJ, Treece P (1994) Deep inferior epigastric perforator flap for breast reconstruction. *Ann Plast Surg* 32:32–38

4. Futter CM, Webster MH, Hagen S, Mitchell SL (2000) A retrospective comparison of abdominal muscle strength following breast reconstruction with a free TRAM or DIEP flap. *Br J Plast Surg* 53:578–583
5. Beausang ES, McKay D, Brown DH, Irish JC, Gilbert R, Gullane PJ, Lipa JE, Neligan PC (2003) Deep inferior epigastric artery perforator flaps in head and neck reconstruction. *Ann Plast Surg* 51:561–563
6. Woodworth BA, Gillespie MB, Day T, Kline RM (2006) Muscle-sparing abdominal free flaps in head and neck reconstruction. *Head Neck* 28:802–807
7. Zhang B, Li D, Xu Z, Tang P (2009) Deep inferior epigastric artery perforator free flaps in head and neck reconstruction. *Oral Oncol* 45:116–120
8. Song R, Gao Y, Song Y, Yu Y, Song Y (1982) The forearm flap. *Clin Plast Surg* 9:21–26
9. Timmons MJ, Missotten FE, Poole MD, Davies DM (1986) Complications of radial forearm flap donor sites. *Br J Plast Surg* 39:176–178
10. Urken M, Weinberg H, Buchbinder D, Moscoso JF, Lawson W, Catalano PJ, Biller HF (1994) Microvascular free flaps in head and neck reconstruction: report of 200 cases and review of complications. *Arch Otolaryngol Head Neck Surg* 120:633–640
11. Koshima I, Fukuda H, Yamamoto H, Moriguchi T, Soeda S, Ohta S (1993) Free anterolateral thigh flaps for reconstruction of head and neck defects. *Plast Reconstr Surg* 92:421–428
12. Kind GM, Rademaker AW, Mustoe TA (1997) Abdominal-wall recovery following TRAM flap: a functional outcome study. *Plast Reconstr Surg* 99:417–428
13. Suominen S, Asko-Seljavaara S, Kinnunen J, Sainio P, Alaranta H (1997) Abdominal wall competence after free transverse rectus abdominis musculocutaneous flap harvest: a prospective study. *Ann Plast Surg* 39:229–334
14. Koshima I, Soeda S (1989) Inferior epigastric artery skin flaps without rectus abdominis muscle. *Br J Plast Surg* 42:645–648
15. Koshima I, Moriguchi T, Soeda S, Tanaka H, Umeda N (1992) Free thin paraumbilical perforator-based flaps. *Ann Plast Surg* 29:12–17
16. Mizgala CL, Hartrampf CR Jr, Bennett GK (1994) Assessment of the abdominal wall after pedicled TRAM flap surgery: 5 to 7 year follow-up of 150 consecutive patients. *Plast Reconstr Surg* 93:988–1002
17. Kroll SS, Sharma S, Koutz C, Langstein HN, Evans GRD, Robb GL, Chang DW, Reece GP (2001) Postoperative morphine requirements of free TRAM and DIEP flaps. *Plast Reconstr Surg* 107:338–341
18. Ong WC, Lim J, Lim TC (2004) Successful pregnancy after breast reconstruction with the deep inferior epigastric perforator flap. *Plast Reconstr Surg* 114:1968–1970
19. Yano T, Sakuraba M, Asano T, Sarukawa S (2009) Head and neck reconstruction with the deep inferior epigastric perforator flap: a report of two cases. *Microsurgery* 29:287–292
20. Hamdi M, Weiler-Mithoff EM, Webster MH (1999) Deep inferior epigastric perforator flap in breast reconstruction: experience with the first 50 flaps. *Plast Reconstr Surg* 103:86–95
21. Blondeel PN (1999) One hundred free DIEP flap breast reconstructions: a personal experience. *Br J Plast Surg* 52:104–111
22. Rozen WM, Ashton MW, Murray ACA, Taylor GI (2008) Avoiding denervation of rectus abdominis in DIEP flap harvest: the importance of medial row perforators. *Plast Reconstr Surg* 122:710–716
23. Kaplan JL, Allen RJ (2000) Cost-based comparison between perforator flaps and TRAM flaps for breast reconstruction. *Plast Reconstr Surg* 105:943–948