

Contents lists available at [ScienceDirect](http://ScienceDirect.com)

## Journal of Forensic and Legal Medicine

journal homepage: [www.elsevier.com/locate/jflm](http://www.elsevier.com/locate/jflm)

## Case report

## The choking game: A deadly game. Analysis of two cases of “self-strangulation” in young boys and review of the literature

Laura Re<sup>\*</sup>, Jutta M. Birkhoff, Marta Sozzi, Luisa Andrello, Antonio M.M. Osculati

Department of Bio-Technologies and Life Sciences, Section of Forensic Pathology and Forensic Psychiatry, University of Insubria, Varese, Italy

## ARTICLE INFO

## Article history:

Received 22 July 2014

Received in revised form

28 October 2014

Accepted 13 December 2014

Available online 30 December 2014

## Keywords:

Choking game

Jeu du foulard

Self-strangulation

Asphyxial game

## ABSTRACT

The *choking game* is defined as a self-strangulation or strangulation by another person with the hands or a noose to achieve a brief euphoric state caused by cerebral hypoxia. Death may occur, but forensic pathologists often classify them as suicides or accidental deaths, without focusing on the possibility that they may result from a deliberate self-temporary-asphyxiation, turned into a deadly game. Presenting two fatal cases of self-strangulation involving an 11-year-old boy and a teenager of 15 years, the authors identify victims' characteristics and death scene's evidence, which may help to distinguish if a death is from an asphyxial suicide or an asphyxial game.

© 2014 Elsevier Ltd and Faculty of Forensic and Legal Medicine. All rights reserved.

## 1. Introduction

Asphyxial games among children and adolescents are widespread all over the world and, even if played for generations, they are not always considered when a youth dies. In fact, deaths due to a self-asphyxial risk-taking behavior are often classified as suicides or accidental deaths, without considering the possibility that they can be the result of a deliberate self-temporary-asphyxiation in order to take pleasure, which then turns into a deadly game. The following case reports concern two young boys who played a solo asphyxial game and died because of a self-strangulation. Authors want to provide key information that can help to correctly evaluate asphyxial cases in children and adolescents, so to be able to understand, or even to wonder, if it is a suicide, an accident or a choking game.

## 2. The choking game

Before proceeding to the presentation of the two cases, it seems useful to retrace the most significant evidence related to this activity.

The *choking game* or *self-asphyxial risk-taking behavior* (SAB) is defined as a self strangulation or strangulation by another person with the hands or a noose to achieve a brief euphoric state caused by cerebral hypoxia.<sup>1,2</sup> This activity is now known by different

names (Table 1), depending on the country or on the region of the country. The most widely used is *choking game* or, in French-speaking countries, *jeu du foulard*.<sup>2–4</sup> Indeed, the term *choking game* is a misnomer,<sup>5</sup> because the application of an external pressure on the neck is usually called *strangulation*, while *choking* is the term that designates asphyxia by obstruction of the internal airways.<sup>6</sup>

Literature shows that the asphyxial games were even played in primitive Celtic culture, and decades ago, anthropologists observed this activity in Native American and Eskimo children.<sup>7–9</sup> In fact, the choking game likely represents an extension of or variation on games played by previous generations of youth without fatal results.<sup>10</sup>

This *game* provides a dizzy sensation, described as “cool”, which derives from the obstruction of cerebral venous and arterial blood flow, also with an increased carbon dioxide tension.<sup>11–13</sup> This phase of brief euphoria or “high” feeling before loss of consciousness is followed by a “rush” from the surge of blood flow when the constraint is removed.<sup>2,14</sup> Loss of consciousness may occur, with potential injury from subsequent falling, and hypoxic injuries, such as bloodshot eyes, visual impairments, marks on neck, severe headache, altered mental status, recurrent episodes of syncope and changes in behavior.<sup>15–18</sup> Death may also occur; nevertheless, young people do not seem to understand the dangerousness of this activity.<sup>19–22</sup>

The choking game is not sexual in nature.<sup>23–25</sup> However, some authors consider the choking game as the earliest manifestation of the “autoerotic asphyxiation (AEA)”.<sup>7,26</sup>

<sup>\*</sup> Corresponding author. Tel.: +39 0332217510; fax: +39 0332397509.

E-mail address: [laura.re@email.com](mailto:laura.re@email.com) (L. Re).

**Table 1**  
Terms more frequently used to describe a self-asphyxial risk-taking behavior.

English countries	French speaking countries
Choking game	Jeu du foulard
Suffocation roulette	Coma Indien
Space monkey	Rève indien
Breath play	Rève bleu
Funky chicken	Grenouille
Sleeper hold	Jeu des poumons
Black hole	Coma
Fainting lark	Cosmos
Pass out	Jeu de la tomate
Miss trick	Jeu de la serviette
Gasp	Évanouissement
Knockout	
Snuff	
Choke out	
Rush	
Dream game	
Tingling	

The choking game is widespread all over the world, particularly in France, where lots of research were made. According to the “*Association de parents d’enfants accidentés par strangulation*” (APEAS), of all French students between 6 and 15 years, 1 out of 10 has already played to the choking game and almost the half of them lack of the understanding of the risks of participation.<sup>3,17</sup>

This activity can involve both males and females, with a male:female ratio of approximately 2:1.<sup>1</sup> The range of age is 9–19, with a pick at 13 years, but it can also include young adults in college or around college age. During 1997–2007, the CDC’s report (Centers for Disease control and prevention) identified 82 probable choking game deaths among young people aged 6–19; 86.6% of the decedents were male, so boys are much more likely to die from the choking game than girls.<sup>27</sup> The mean age was 13.3 years and nearly all the children who died were playing the game alone. Youth in rural areas were more likely to have joined it than youths in urban areas. A study by Macnab and colleagues indicated that 6.6% of adolescents aged 9–18 had taken part to this game, 94% of them participated while someone else was present, 68% knew this activity and 45% met someone who had joined it.<sup>14</sup> Otherwise, Andrew and Fellon reported that this behavior is largely a solo activity.<sup>10</sup> A study made by using data from the 2009 *Oregon Healthy Teens survey* found out that 22% of eight-graders have heard of someone participating in the choking game, only 1.2% have helped someone to take part of it, while 6.6% have participated themselves.<sup>28</sup> There were no gender differences, black and Pacific Islander students were more involved than white students were. The prevalence (7.6%) was the same in middle class students and high school students.

In the choking game the person usually wants to see who is the toughest or who can go longest without passing out, while others simply think it is funny.<sup>1,19,23</sup>

This game participation is often associated with some health risk categories, such as poor mental health, substance use, exposure to violence, sexual activity and gambling.<sup>28,29</sup> It can also be associated with the willingness to be accepted by peers. Brausch and colleagues, through a health behavior screening made in rural region, discovered that as many as 17% of adolescents had practiced a Self-Asphyxial risk-taking behavior, and that adolescents who reported SAB also reported more suicide ideation and attempts than those who had not.<sup>30</sup> Adolescents who had engaged both SAB and NSSI (non suicidal self-injury) would have a great chance to make other risk behaviors, including suicide. Otherwise, Andrew and Fallon reported that these adolescents usually are athletic and like to *extreme everything* and they think that this activity is safe just

because alcohol or drugs are not involved.<sup>2,10</sup> Therefore, it is also called “good kids game” or even “good kids drug” as it is played by adolescents who avoid the use of drugs, replacing them with this game.<sup>17,31,32</sup>

Although many scientific papers have already described this dangerous activity and some parents have already heard about it, other authors have pointed out that there is still a lack of knowledge about this practice in many doctors and a lack of information among young people. A study made by McClave and colleagues in 2010, revealed that only the 68.1% of the physicians interviewed knew about this dangerous game.<sup>33</sup> Bernacki and Davies, in 2012, interviewed 1227 parents with children between the ages of 2 and 17 years, founding out that three quarters of parents were familiar with the choking game, but only the 20% of them had talked to their children about this activity.<sup>1,34</sup> Parents, teachers and physicians must be aware of the warning signs suggesting that an adolescent may have joined the choking game, as to be able to intervene effectively. These warning signs are: headaches, seizures, unexplained bruising around the neck, bloodshot eyes, facial petechiae, disorientation after being alone, sudden vision loss, behavioral changes, head or musculoskeletal trauma due to falls, wear marks on furniture.<sup>1,17,33</sup>

Deevska and colleagues<sup>35</sup> pointed out that 40% of young people perceived no risk associated with a self-asphyxial risk-taking behavior, therefore the importance of prevention educational programs for adolescents to dispel the common misconception that this is a harmless activity.<sup>2,32</sup> In this context, the age of the young people seems to be very important. The younger children would listen mostly to parents or teachers, while the older kids would listen mostly to people who have practiced this activity with serious consequences, or family members who had lost children as a consequence of an asphyxial practice gone wrong.<sup>1,14</sup> On the other hand, this game should not be sensationalized, because of the risk that young people can emulate this behavior.

### 3. Case report 1

#### 3.1. History

In April 2009, a young boy aged 11 was found by his stepfather hanged from a foulard made into a noose on the bunk bed in his bedroom, his feet barely touching the ground. The scarf made a loop around his neck, while remaining open posteriorly (Fig. 1). He was pronounced dead 1 h later.

Further investigation by police revealed a moderately chaotic social situation. The boy never knew his real father. When he was 2



**Fig. 1.** Case 1: Inspection, detail of the foulard hanged on the bunk bed.

years old he knew his stepfather, and then moved in another city with his family. Because of work, his mother often and for long periods returned to the country of origin, leaving the child in the care of his grandmother and stepfather. The young boy seemed to be well integrated between new peers and classmates, but his stepfather and his teachers told the police that he continuously put in place tests of courage, without considering the risks. He also alternated moments of great sensitivity to moments of arrogance and bullying.

### 3.2. Inspection

An accurate inspection was made. Some objects partially burnt were found on the balcony. The analysis of the young man's computer showed that he had sometimes surfed the net making research about some dangerous activities and in web sites concerning pornography and homosexuality.

### 3.3. Autopsy examination

There was cyanosis of nail beds. At the right side of the neck, there was a red-brownish excoriation of the size of 2.5 cm × 0.8 cm (Fig. 2). A dissection planes was performed without showing anything at the subcutaneous or muscular planes or at vassals and nerves. Areas of hemorrhage were noticed at the aditus laryngis and epiglottis. A neuropathological examination revealed meningeal congestion and cerebral aedema and congestion. Thymic, sub-epicardial and sub-pleural petechiae were quite numerous. In lungs, extensive areas of acute emphysema were evident, also with an important parenchyma's blood congestion (Fig. 3).

Toxicology was negative for alcohol, drugs of abuse or therapeutic drugs.

### 3.4. Cause of death

The diagnosis of death was acute mechanical asphyxia due to an atypical incomplete hanging. There were not detected signs related to the intervention of third parties in the determination of death.

## 4. Case report 2

### 4.1. History

In June 2012, an adolescent boy aged 15 years was found naked with a scarf looped about his neck, suspended on the bunk bed,

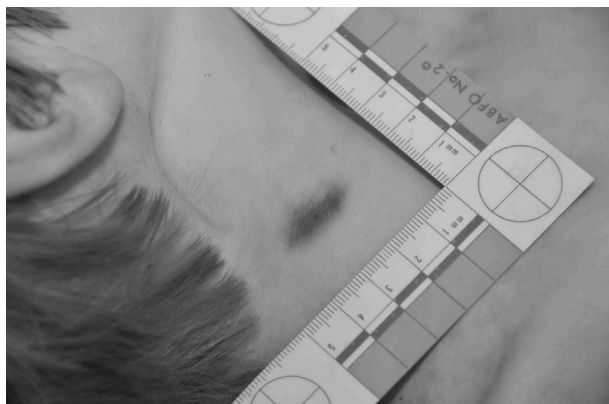

Fig. 2. Case 1: External examination of the body, detail of the excoriation at the neck.



Fig. 3. Case 1: Autopsy examination, sub-epicardial and sub-pleural petechiae, emphysema and blood congestion of lungs.

which was 103 cm (3.4 feet) high. When physicians arrived, the boy was pronounced dead.

No history of behavioral disturbances, school failure or substance abuse was found, contrariwise he had just passed a professional exam and appeared very pleased to relatives. A friend of the adolescent, questioned by the police, claimed to know what the choking game is, but not if the boy had ever practiced this self-asphyxial activity.

### 4.2. Inspection

An accurate inspection was made. The scarf with which the boy had hanged himself was on the floor because his parents had loosened it (Fig. 4).

### 4.3. Autopsy examination

Brownish liquid drained from the respiratory orifices and smeared the face, the neck and the right hemi-thorax. At the frontal region of the neck, there was a 6 cm wide ligature mark, sloping gently upward bilaterally to the occipital notch, where the ligature mark was absent.

A dissection planes showed an extensive hemorrhage of subcutaneous and muscular tissues, particularly of the left sternocleidomastoid muscle and of the right thyrohyoid muscle, without injury of underlying cartilage, hyoid bone or cervical vertebra column (Fig. 5). Cerebral aedema and congestion were found. Sub-epicardial and sub-pleural petechiae were quite numerous. Extensive areas of acute emphysema were observed at lungs, also with

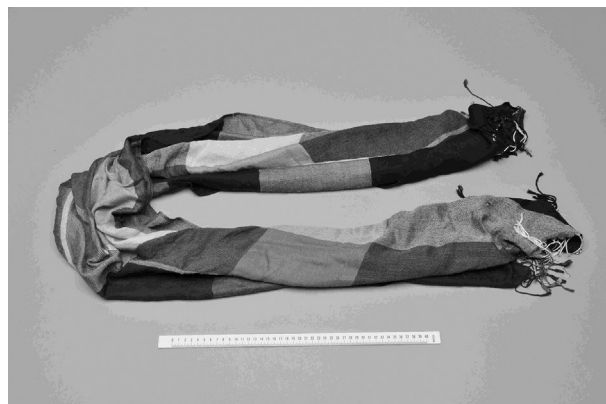


Fig. 4. Case 2: Inspection, the scarf used to play the choking game.

copious whitish foam fluid mixed with blood that overfilled also the bronchi (Fig. 6).

Toxicology was negative for alcohol, drugs of abuse or therapeutic drugs.

#### 4.4. Cause of death

The diagnosis of death was acute mechanical asphyxia due to atypical incomplete hanging. There were not detected signs related to the intervention of third parties in the determination of death.

### 5. Discussion

The two case reports reflect exactly what emerges from the literature. The two boys' age, 11 and 15 years old, fits perfectly into the range of age of the choking game.<sup>1,27</sup> Both of them are male<sup>27</sup> and they were alone during this dangerous activity.<sup>10</sup> Moreover, even if life's experience and children's behavior were very different, some investigative indicators allow the authors certifying them as accidental death related to a choking game instead of suicide.

In the first case, the accurate computer analysis, which revealed that the boy often surfed the net in pornography and homosexuality sites, was crucial. Similarly, the testimony of his stepfather and teachers helped to understand the dynamics of death. In fact, the boy alternated moments of great sensitivity to moments of arrogance and bullying and continuously put in place tests of courage. These traits correspond to those identified by some authors in cases of self-asphyxial risk-taking behaviors, which are actually often associated with some health risk categories.<sup>10,28,29</sup>

Also in the second case, a careful investigation has proved to be essential. The adolescent boy had no history of behavioral disturbances, school failure or substance abuse; contrariwise, he had just passed a professional exam. Nevertheless, a friend of him told the police that they knew about the choking game, claimed to know what this self-asphyxial activity is, but not if the boy had ever practiced it. Therefore, the boy of case number 2, perfectly fits one of the profile that are found in boys who practice the choking game, which is in fact also called “good kids game” or even “good kids drug”, because it can involve adolescents with no apparent medical or psychological problems and not involved in risks categories.<sup>2,17,31,32</sup>

The authors ascribe the two deaths to choking games because evidence allow to perfectly frame these cases in the literature analyzed. Obviously, there is no absolute certainty, because often,

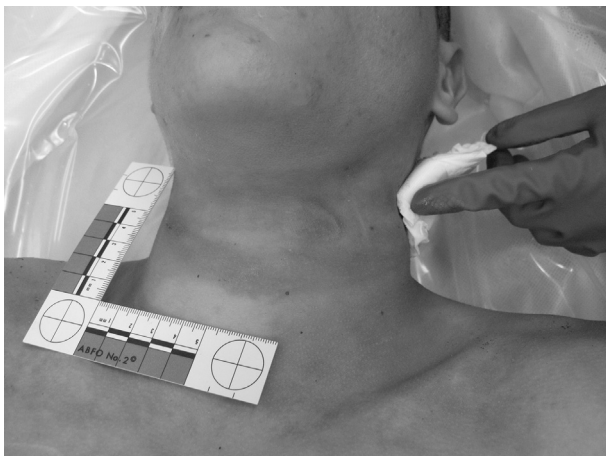


Fig. 5. Case 2: External examination of the body, anterior view of the ligature mark at boy's neck.

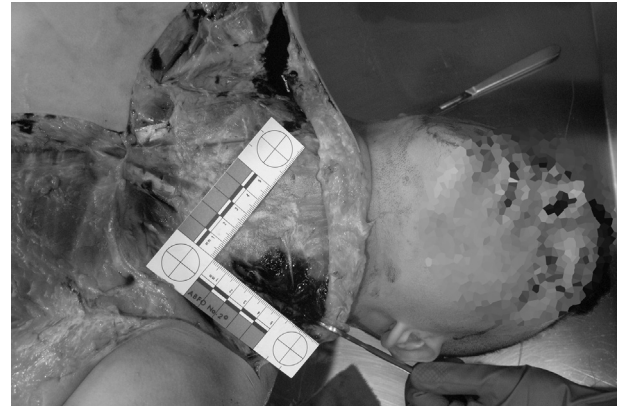


Fig. 6. Case 2: Autopsy examination: hemorrhage of subcutaneous and muscular tissues at planes dissection of the neck.

especially when it is fatal, the choking game is a solitary activity, so it is unlikely to have witnesses and this makes it difficult to determine whether it is a choking game that has become a deadly game, or a suicide. Certainly, even in this latter event, the cases presented are really interesting, due to the different lifestyles and life experiences of the two young victims.

Despite the territorial jurisdiction of the authors is geographically limited, in a short time, only three years, there were 2 cases of choking game. An analysis of autopsy cases of the two decades from 1992 to 2012 in the same jurisdiction has identified only 19 certain cases of suicide in young people aged 10–19 years. The number of suicides is therefore very low, while the presence of two cases of choking game at close range seems to be extremely worrying.

### 6. Conclusion

This two cases show the importance of a careful knowledge of this dangerous *game*, widespread among young people all over the world. It is important that hanging cases are not automatically assumed as suicides. Forensic pathologist should always take in consideration the possibility that the death is a consequence of a *choking game*.

To identify the circumstances and cause of death and for the diagnosis of death due to strangulation during a choking game, seems to be thus essential an accurate analysis of the life-history and the circumstances of death, a depth inspection of places and things and a careful autoptical and toxicological examination. It is also important a combined careful investigation of the social tissue in which the young person lived, also featuring interviews with family, friends, classmates, teachers, etc. That is why further studies are necessary in order to be able to recognize and adequately prevent this deadly game.

Maybe the various and several terms used by call this dangerous practice (Table 1) may have contributed to the lack of knowledge of the phenomenon, as well as to an underestimation of the real dangers of this deadly *game*. Therefore, the authors suggest, as already proposed in the past by others, to adopt a single term, such as “self-strangulation”, to describe this activity, so that it can be used all over the world, favoring the right knowledge of the phenomenon, and also emphasizing the real danger of this practice.

#### Ethical approval

None declared.

#### Funding

None declared.

**Conflict of interest**

There was no financial support for this study.

All authors reported no biomedical financial interests or potential conflicts of interest.

**References**

- Andrew TA, Macnab A, Russel P. Update on “the choking game”. *J Pediatr* 2009;**155**(6):777–80.
- G.A.S.P. Games Adolescents Shouldn't play. [Online]. Available from: <http://gaspinfo.com/en/choking.html> [accessed 09.02.14].
- A.P.E.A.S. Association de Parents d' Enfants Accidentés par Strangulation. [Online]. Available from: [www.jeudufoulard.com](http://www.jeudufoulard.com) [accessed 03.02.14].
- Centers for Disease and Prevention. Unintentional strangulation deaths from the “choking game” among youths aged 6–19 years: United States, 1995–2007. *MMWR Morb Mortal Wkly Rep* 2008;**57**(6):141–4.
- Sauvage A. The choking game. A misnomer [Letter] *Pediatr Emerg Care* 2010;**26**(12):965.
- Katz KA, Toblin RL. Language matters: unintentional strangulation, strangulation activity, and the “choking game”. *Arch Pediatr Adolesc Med* 2009;**163**(1):93–4.
- Cowell DD. Autoerotic asphyxiation: secret pleasure-lethal outcome? *Pediatrics* 2009;**124**(5):1319–24.
- Stearns A. Cases of probable suicide in young persons without obvious motivation. *J Maine Med Assoc* 1953;**44**:16–7.
- Resnik H. Eroticized repetitive hanging: a form of self-destructive behaviour. *Am J Psychoter* 1972;**26**(1):4–21.
- Andrew TA, Fallon KK. Asphyxial games in children and adolescents. *Am J Forensic Med Pathol* 2007;**28**(4):303–7.
- Chow KM. Deadly game among children and adolescents [Letter] *Ann Emerg Med* 2003;**42**(2):310.
- Howard P, Leathart GL, Dornhorst AC, Sharpey-Schafer EP. The “mess trick” and the “fainting lark”. *Br Med J* 1951;**2**(4728):382–4.
- Ullrich NJ, Bergin AM, Goodkin HP. “The choking game”: self-induced hypoxia presenting as recurrent seizurelike events. *Epilepsy Behav* 2008;**12**:486–8.
- Macnab AJ, Deevska M, Gagnon F, Cannon WG, Andrew T. Asphyxial games or “the choking game”: a potential fatal risk behaviour. *Inj Prev* 2009;**15**:45–9.
- Shlamovitz GZ, Assia A, Ben-Sira L, Rachmel A. “Suffocation roulette”: a case of recurrent syncope in an adolescent boy. *Ann Emerg Med* 2002;**41**(2):223–6.
- Gicquel JJ, Bouhamida K, Dighiero P. Complications ophtalmologiques du “jeu du foulard” chez un enfant de 12 ans. *J Fr Ophthalmol* 2004;**27**(10):1153–5.
- Noirhomme-Renard F, Gosset C. Le “jeu du foulard” et autres jeux d'asphyxie: donées épidémiologiques et cliniques. *Rev Med Liège* 2011;**66**(9):485–90.
- Barberia-Marcalain E, Corrons-Perramon J, Suelves JM, Crespo Alonso S, Castellà-García J, Medallo-Muñiz J. El juego de la asfixia: un juego potencialmente mortal. *An Pediatría (Barc)* 2010;**73**(5):264–7.
- Le D, Macnab AJ. Self strangulation by hanging from cloth towel dispensers in Canadian schools. *Inj Prev* 2001;**7**:231–3.
- Thomas SP. A deadly game for boys [from the editor] *Issues Ment Health Nurs* 2009;**30**:287.
- Toblin RL, Paulozzi LJ, Gilchrist J, Russel PJ. Unintentional strangulation from the “choking game” among youths aged 6–19 years – United States, 1995–2007. *J Safety Res* 2008;**39**:445–8.
- Egge MK, Berkowitz CD, Toms C, Sathyavagiswaran L. The choking game. A cause of unintentional strangulation. *Pediatr Emerg Care* 2010;**26**(3):206–8.
- ICD-9-CM Coordination and Maintenance Committee Meeting. Summary of diagnosis presentation; March 5, 2012 [Online]. Available from: [http://www.cdc.gov/nchs/data/icd/2012\\_march\\_summary.pdf](http://www.cdc.gov/nchs/data/icd/2012_march_summary.pdf) [accessed 09.02.14].
- Blanchard R, Hucker SJ. Age, transvestism, bondage, and concurrent paraphilic activities in 11 fatal cases of autoerotic asphyxia. *Br J Psychiatry* 1991;**159**:371–7.
- Sauvageau A, Racette S. Autoerotic deaths in the literature from 1951 to 2004: a review. *J Forensic Sci* 2006;**51**(1):140–6.
- Byard RW, Austin AE, Van den Heuvel C. Characteristics of asphyxia deaths in adolescence. *J Forensic Leg Med* 2011;**18**:107–9.
- Centers for Disease and Prevention (CDC). “Choking game” awareness and participation among 8th graders-Oregon, 2008. *MMWR Morb Mortal Wkly Rep* 2010;**59**(1):1–5.
- Ramowski SK, Nystrom RJ, Rosenberg KD, Gilchrist J, Chaumeton NR. Health risks of Oregon eighth-grade participants in the “choking game”: results from a population-based survey. *Pediatrics* 2012;**129**(5):846–51.
- Dake JA, Price JH, Kolm Valdivia N, Wielinski M. Association of adolescent choking game activity with selected risk behaviors. *Acad Pediatr* 2010;**10**(6):410–6.
- Brausch AM, Decker KM, Hadley AG. Risk of suicidal ideation in adolescents with both self-asphyxial risk-taking behavior and non-suicidal self-injury. *Suicide Life Threat Behav* 2011;**41**(4):424–34.
- Senanayake M, Chandraratne K, de Silva T, Weerasuriya DC. The “choking game”: self-strangulation with a belt and clothes rack. *Ceylon Med J* 2006;**51**(3):120.
- Linkletter M, Gordon K, Dooley J. The choking game and youtube: a dangerous combination. *Clin Pediatr* 2010;**49**(3):274–9.
- McClave JL, Russell PJ, Lyren A, O'Riordan MA, Bass NE. The choking game: physician perspectives. *Pediatrics* 2010;**125**(1):82–7.
- Bernacki JM, Davies WH. Prevention of the choking game: parent perspectives. *J Inj Violence Res* 2012;**4**(2):73–8.
- Deevska M, Gagnon F, Cannon WG, Thamboo A, Macnab AJ. An adolescent risk-taking behavior: “the choking game”. *Paediatr Child Health* 2008;**13**(Suppl. A):52.