

## A NOVEL METHOD TO MEDICATE LOCAL CV FLAPS IN NIPPLE RECONSTRUCTION

### MEME BAŐI REKONSTRÜKSİYONUNDAKİ LOKAL CV FLEPLERİN MEDİKASYONU İÇİN YENİ BİR METOT

Francesca Maggiulli, Mario Cherubino, Stefano Scamoni, Igor Pellegatta, Luigi Valdatta

University of Insubria Varese, Plastic and Reconstructive Surgery, Varese, Italy

#### ABSTRACT

Besides surgical technique related variables, post-operative care after nipple reconstruction with CV flaps is important for an satisfactory final result. We present a novel method to prepare a protective and sealing medication in order to minimize traumas to the new nipple. We found the silicone cap plunger of a 50cc syringe suitable for our purpose. It was applied over a non-adherent dressing and TNT gauze to avoid decubitus and fixed it with a steri-strip before covering with a sticking plaster. Analyzing 118 nipples casistic, reconstructed with a CV flaps technique, between January 2011 and June 2012 and medicated with the presented technique in the last six months considered, we noticed a reduction in partial loss of flap vitality and nipple reabsorption. The main advantages of the dressing technique we propose are the ease and rapidity in the preparation and availability of all materials used in every operation room or outpatient clinic. We believe that our technique of medication may reduce traumas to delicate vascularization of the new nipple, avoiding the partial or total loss of vitality and reabsorption of the flaps.

**Key words:** CV flaps, local, flaps, dressings

#### ÖZET

Cerrahi tekniđe bađlı deđişkenin yanı sıra CV flep ile meme rekonstrüksiyonu sonrası postoperatif bakım, kayda deđer bir nihai sonuç için önemlidir. Yeni meme başına karşı travmaları en aza indirmek amacıyla koruyucu ve kapatıcı bir medikasyon hazırlamak için yeni bir yöntem sunmaktayız. Biz bu amacımız için 50 cc'lik şırınganın silikon piston kabını uygun bulduk. Bu, yapışmaz bir sargı ve bir TNT gazlı bez üzerine dekübitusu önlemek için uygulandı ve hepsi yara bandı ile kaplanmadan önce steril bant ile sabitlendi. Ocak 2011 ve Haziran 2012 arasında CV flep tekniđi ile rekonstrüksiyon yapılmış ve sunulan teknik ile son altı ayda medikasyon uygulanmış 118 meme başı analiz edildiğinde, flep canlılığının kısmi kaybında ve meme başı reabsorpsiyonunda bir azalma fark ettik. Sargı tekniđinde bizim sunduđumuz başlıca avantajlar hazırlama kolaylığı ve çabukluđu ve her operasyon odasında veya ayakta tedavi kliniđinde kullanılan tüm materyallerin bulunabilir olmasıdır. Bizim medikasyon tekniđimizin canlılığın kısmi veya total kaybını ve fleplerin reabsorpsiyonunu önleyerek, yeni meme başının hassas vaskülarizasyonuna karşı travmaları azaltabildiđine inanıyoruz.

**Anahtar sözcükler:** CV flepleri, lokal, flepler, sargılar

**N**ipple-areolar complex reconstruction is the last step for women who face breast reconstruction after radical mastectomy. The nipple is one of the most important factors of an attractive breast. Manifold techniques are proposed to restore the nipple resemblance after surgical procedure (1). Most of them are represented by local flaps and grafts. According to the literature, the local flap technique is the most used in nipple reconstruction (2). The main advantages of this technique are, the minimal site morbidity, use of local anesthesia, simplicity and rapidity of the procedure (3). The greatest worries about CV flap use in nipple reconstruction are the need to preserve the vitality of the flaps and to maintain the native nipple projection. We believe that, in addition to the surgical technique, post-operative care is paramount

for a good result. In this article, we present a protective method to medicate the local CV flap used for nipple reconstruction.

Nowadays, CV flap is the most widespread technique for nipple reconstruction. Starting from the surgical skills of the operator and ending with tissue vascularization of the flaps used, many factors can modify the final results. One of the most important variables in order to avoid complications after surgical procedure is post-operative care. Micro-traumas to the nipple-areolar region could damage the delicate vascularization of the new nipple.

Hence, medication needs to be protective but not bulky and uncomfortable for the patient.

Currently, the nipple, after reconstruction with a CV flap, is medicated with a non-adherent dressing and a pile of gauzes in order to protect the areolar region.

In our opinion, the direct contact between gauzes and the new nipple may represent a micro-trauma that could impair flap vitality.

Thus, a protective, easily manageable, cheap and comfortable dressing could be useful to minimize CV flaps complication in nipple reconstruction.

### Materials and Methods

Our dressing technique was triggered by the need for finding a small case, possibly already present in the operating room, not too difficult to set up, sterile and ready to be used immediately after surgery to close the wounds in a sterile way.

We found the ideal features in the silicone cap plunger of a 50cc syringe, easily removable with a small Klemmer. The peripheral rim, with a central cavity of the case, make it ideal to accommodate and cover flaps of the reconstructed nipple.

In order to avoid the local decubitus, we applied the cap by interposing a non-adherent dressing and a TNT sterile gauze with a central hole.

After the cap had been fixed to the sterile gauze with a wide steri-strip, a secondary dressing was made simply with a sticking plaster (Figure 1).

### Results

From January 2011 to June 2012, we reconstructed 118 nipples with the CV flap technique. In September 2011, we started using the method introduced in this paper to medicate nipples (63 performed surgeries); we noticed that the survival of the flaps of the nipple depended not only on the accuracy of the preoperative plan, width of the vascular pedicle- vitality of the flaps of mastectomy, possible post-mastectomy radiotherapy, but also on post-operative care, which is primarily dependent on the medication.

Comparing the novel technique, performed from September 2011 to June 2012, to the classical medication with non-adherent dressing and TNT gauze and without the protection of the syringe cap

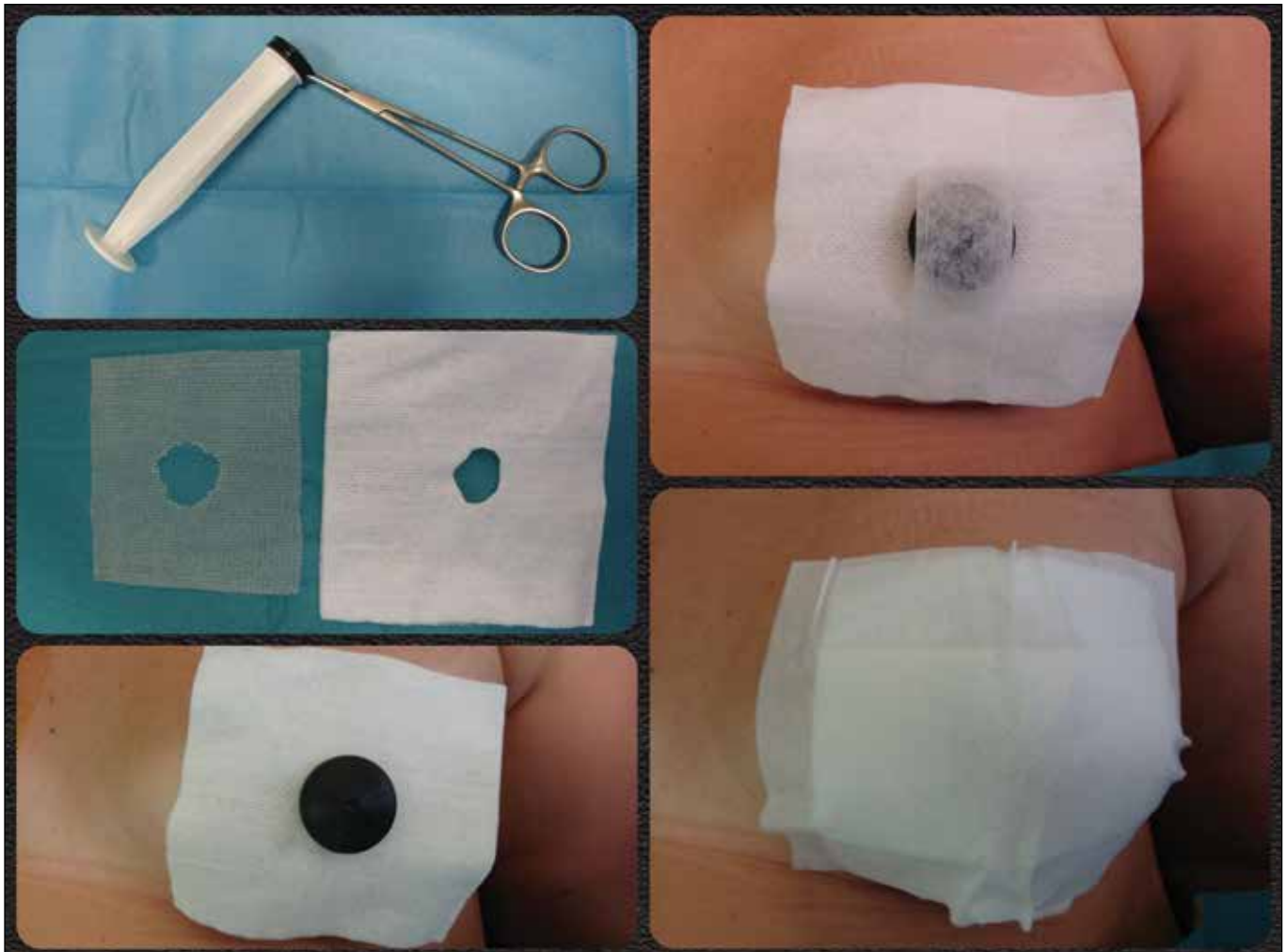


Figure 1. Different steps of the medication process.

plunger (55 patients treated from January 2011 to August 2011), we reported 9.5% fewer complications (partial loss of flaps vitality) and a 16.3% less nipple reabsorption rate in the group where the technique presented was applied.

Partial loss of flap-vitality was clinically assessed during post-operative controls and medication changed considering a partial loss due to the necrosis of half nipple skin.

As far as nipple reabsorption is concerned, we estimated the volume decrease 4 and 20 weeks after surgery acquiring photographically lateral and frontal views of nipples, maintaining the same distance. Dimensional variation of nipple volume was analyzed by means of professional photo editing software (Bersoft Image Measurement v. 8.16).

Notwithstanding the better results obtained on comparing our technique with the control group, the statistically nonsignificant number of our casistic and the manifold independent variables (different performing surgeons, clinical story of the patients) cannot establish the undoubted importance of the dressing technique in avoiding the main CV flaps complications in nipple reconstruction.

### Discussion

Local flaps transposition is the most common method used in breast reconstruction after mastectomy to restore the nipple. In our experience, c-v flaps technique is by far the most used technique (3).

The surgical procedure, under local anesthesia, takes about 20 minutes and it is easily performed also by a reconstructive surgeon with limited experience.

After surgery, the new reconstructed nipple is very bulky and over-corrected because it will face reabsorption over time and is quite exposed to blunt trauma because in almost all cases the area is devoid of sensitivity; hence, it is advisable at least in the first week after surgery to protect the new nipple with a dressing characterized by rigidity in the structure and at the same by flexibility to be atraumatic for the delicate tissue itself.

### References

1. Nahabedian MY. Nipple reconstruction. Clin Plast Surg 2007; 34: 131-7. (PMID: 17307077) [CrossRef]
2. Losken A, Mackay GJ, Bostwick J 3rd. Nipple reconstruction using the C-V flap technique: a long-term evaluation. Plast Reconstr Surg 2001; 108: 361-9. (PMID: 11496176) [CrossRef]

The dressing technique we proposed is easily manageable, and materials used for its preparation are available in every operation room or outpatient's clinic.

Furthermore, the central hole created over the nipple during the dressing arrangement make it possible to verify the flap's vitality at every moment without removing the medication completely.

Treated women appreciated that the dressing was compact and less visible under clothing, allowing an immediate return to normal activities without fear of being observed and without risk of injuries that could put the vitality of the new-nipple at risk.

### Conclusion

In this article we presented a new way to protect CV flaps used for nipple reconstruction.

The most appreciable strong points of this dressing are the ease and rapidity in its preparation, the cheap and broadly available necessary materials.

Despite admitting the major importance of surgeon related variables in flaps transposition, we think that the post-operative care plays a significant role in avoiding complications in nipple reconstruction.

We believe that our technique of medication may reduce traumas to delicate vascularization of the new nipple, avoiding the partial or total loss of vitality and the reabsorption of the flaps.

**Acknowledgments and funding sources:** The authors have no acknowledgments and no funding sources were used during the study.

**Author disclosure and ghost writing:** No competing financial interests exist. The content of this article was expressly written by the author(s) listed. No ghostwriters were used to write this article

### Conflict of interest

No conflict of interest was declared by the authors.

### Correspondence / Yazıřma Adresi

Francesca Maggiulli  
E-mail : francesca.maggiulli@live.it