

Amiodarone-Induced Thyrotoxicosis

Brogioni S^a, Dell'Unto E^a, Cosci C^a, Tomisti L^a, Bartalena L^b, Martino E^a, Bogazzi F^a.

^aDepartment of Endocrinology and Metabolism, University of Pisa, Pisa, Italy; ^bDepartment of Clinical Medicine, University of Insubria, Varese, Italy

Amiodarone, an effective iodine-rich antiarrhythmic drug, frequently causes either changes in thyroid function tests or clinical thyroid dysfunction. Both amiodarone-induced thyrotoxicosis (AIT) and amiodarone-induced hypothyroidism (AIH) have an overall incidence of approximately 14-18%, and AIT being most common in iodine-deficient areas, AIH in iodine-sufficient areas. Both dysfunctions may develop either in apparently normal thyroid glands or in glands with preexisting abnormalities (either nodular goiter or thyroid autoimmune disease). The most important pathogenic mechanisms of AIT include excess iodine-induced thyroid hormone synthesis (type I AIT) and amiodarone (or iodine)-related destructive thyroiditis (type II AIT), but mixed forms involving both pathogenic mechanisms are likely more frequent than previously believed. AIT is a therapeutic challenge, because rapid restoration of euthyroidism is warranted in patients with underlying cardiac disorders. Treatment of choice for type I AIT is represented by the concomitant administration of thionamides and potassium perchlorate, whereas steroids are the most useful tool for type II AIT. Mixed (or, better, undefined) forms of AIT should be treated with a combination of thionamides, potassium perchlorate and glucocorticoids. Radioiodine therapy is usually not feasible owing to low thyroidal radioiodine uptake due to iodine load, while thyroidectomy can be performed in cases resistant to medical therapy or in those patients requiring a rapid control of

thyrotoxicosis after a short course with iopanoic acid to restore normal serum T3 levels. Thyroid ablation is usually required in type I and undefined AIT, also because this allows safe reinstatement of amiodarone treatment, if needed; follow-up without treatment is sufficient in most patients with type II AIT, who usually remain euthyroid or may develop hypothyroidism after reexposure to iodine load.

Key Words: Amiodarone, Amiodarone-induced thyroid dysfunction, Amiodarone-induced thyrotoxicosis.

Introduction

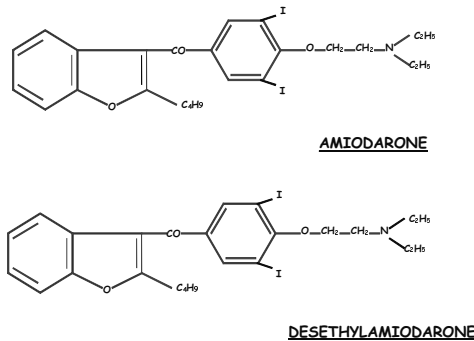
Amiodarone is an iodine-rich drug very effective in the management of tachyarrhythmias¹ (Fig. 1) and, to a lesser extent, of severe congestive heart failure.² However, this drug also has multiple undue effects on several tissues and organs (Table 1); among these, the thyroid is often involved. Effects of amiodarone on the thyroid, range from abnormalities of thyroid function tests not associated with changes in thyroid function to overt thyrotoxicosis (amiodarone-induced thyrotoxicosis, AIT) or hypothyroidism (amiodarone-induced hypothyroidism, AIH).³⁻⁵ While AIH represents neither a difficult therapeutic problem nor a contraindication to continuing amiodarone treatment, AIT is a major therapeutic challenge, owing to its multifaceted features and the iodine load that makes the thyroid gland resistant to conventional antithyroid drug treatment. The aim of this review article is to focus on pathogenic, clinical and therapeutic aspects of AIT.

Correspondence: Enio Martino, Department of Endocrinology and Metabolism, University of Pisa, Ospedale Cisanello, Via Paradisa2, Pisa, Italy
E-mail: e.martino@endoc.med.unipi.it

Table 1. Side effects and complications of amiodarone therapy

	Overall incidence (%)
Corneal microdeposits	100
Gastrointestinal changes (anorexia, nausea)	80
Skin photosensitivity and gray/bluish skin discoloration	55-75
Neurological symptoms (ataxia, tremors, peripheral neuropathy)	48
Abnormalities of liver function tests*	25
Thyroid dysfunction	14-18
Lung dysfunction, interstitial pneumonitis	10-13
Epididymitis	11
Cardiac disorders (heart block, sinus bradycardia)	2-3
Gynecomastia	Exceptional

* toxic hepatitis is rare

**Fig.1. Molecular structure of amiodarone and desethylamiodarone****Pharmacology of amiodarone**

Amiodarone contains approximately 37% iodine by weight.⁵ With a common daily dosage of 200-600 mg and an approximate 10% daily deiodination of the molecule, a huge amount of iodide (7-21 mg) is made available to the body every day, far in excess of necessary requirements (100-150 µg) for a normal thyroid hormone production; this results in a severe iodine load.⁶ Amiodarone is distributed in several tissues, including the thyroid⁷ (Table 2A), from which it is slowly released, with a mean elimination half-life of more than one month for amiodarone and almost two months for its main metabolite, desethyl-

amiodarone (DEA)^{8,9} (Table 2B). Metabolism of amiodarone follows different pathways, the most important being dealkylation which leads to DEA formation.⁸

Table 2a. Pharmacokinetics of amiodarone

Tissue	A (µg/g)	DEA (µg/g)	A/DEA
Adipose	316	72	4.2
Liver	391	2354	0.12
Lung	198	952	0.21
Kidney	57	262	0.22
Heart	40	169	0.24
Muscle	22	51	0.43
Thyroid	14	64	0.22
Brain	8	54	0.15

Table 2b. Pharmacokinetics of amiodarone

Bio – availability	45%	
Serum peak levels	5-6 hours	
Half-life	25-90 days	
Tissue distribution	Adipose	
	Liver	
	Lung	
	Kidney	
	Heart	
	Muscle	
	Thyroid	
	Brain	
Elimination	Liver	70%
	Kidney	25%
	Other	5%

In peripheral tissues, particularly in the liver, amiodarone inhibits type I 5'-deiodinase (5'-D) activity, the enzyme which removes an atom of iodine from the outer

ring of thyroxine (T₄) to generate triiodothyronine (T₃), and from the outer ring of reverse T₃ (rT₃) to produce 3, 3'-diiodothyronine (T₂).¹⁰ In addition, the drug inhibits thyroid hormones entry into peripheral tissues, especially in the liver. Both mechanisms contribute to an increase in serum T₄ concentration; a decrease in serum T₃ levels, and an increase in serum rT₃ concentration in euthyroid subjects given long-term amiodarone therapy. Amiodarone also causes an inhibition of type II 5'-D, mostly operating in the pituitary. This possibly contributes to amiodarone-associated changes in serum thyrotropin (TSH) concentration; serum TSH tends to increase during the initial phases of amiodarone treatment, but then it usually normalizes in patients who remain euthyroid (Table 3).

Table 3. Thyroid function test in euthyroid patients treated with amiodarone

	Short term therapy	Long term therapy
Thyroxine	Increased	Slightly Increased/High
Triiodothyronine	Decreased	Normal Slightly Decreased/Low
Reverse T ₃	Increased	Normal
Thyrotropin	Increased	Increased
T ₃ sulfate	Increased	Normal

Further to inhibition of type I and type II 5'-D activities, amiodarone may induce a hypothyroid-like condition at the tissue level, particularly in the heart, partly related to both a reduction in the number of catecholamine receptors and a decrease in the effect of T₃-

adrenoceptors.¹⁰ The molecular mechanisms underpinning this antagonistic effect of amiodarone on thyroid hormone effects are not completely understood, but they might be related to the fact that DEA (but not amiodarone) acts as a non-competitive inhibitor of T₃ binding to thyroid hormone receptors.¹¹ We have observed that in NIH3T3 cells, DEA (but not amiodarone) behaves as a weak thyroid hormone, and antagonizes the effect of T_α and TR_β agonist using both TR₃ only when present in large excess.¹² The high tissues levels reached by the drug during chronic amiodarone treatment might explain the prevailing antagonist effect and the "hypothyroid-like" situation observed in tissues such as the heart and liver.^{9,10}

Another important action of amiodarone and its metabolites is a direct cytotoxic effect on the thyroid,¹³⁻¹⁵ which may explain the thyroidal destructive phenomena occurring in type II AIT (see below). Effects of amiodarone and its metabolites on thyroid economy are summarized in Table 4.

Although iodine may induce thyroid autoimmune phenomena in humans and animals,¹⁶ most studies suggest that it is unlikely that amiodarone therapy be associated with the appearance of thyroid autoantibodies in patients with negative tests before amiodarone institution.⁵ However, it has been reported that amiodarone administration may cause an increase in some lymphocyte subsets;¹⁷ this might exacerbate preexisting thyroid-specific autoimmune phenomena,¹⁸ a mechanism that might be relevant particularly for AIH.

Table 4. Mechanism of amiodarone action on the thyroid

Mechanism of action	Effects
Inhibition of type I 5'-deiodinase	Increased T ₄ Decreased T ₃ Increased rT ₃
Inhibition of type II 5'- deiodinase	Increased TSH
Inhibition of TH entry into the cells	Decreased peripheral T ₃ production
Thyroid citotoxicity	Leakage of preformed TH Decreased transcription of TH-responsive gene
Interaction with TH receptors	Tissue hypothyroid like condition

Amiodarone Induced Thyroid Dysfunction

Most amiodarone-treated patients remain euthyroid, but, as mentioned above, a relevant proportion of them develop either thyrotoxicosis or hypothyroidism.⁹ The overall incidence of amiodarone-induced thyroid dysfunction varies widely in different series, mostly due to diagnostic criteria, selection of patients and environmental iodine intake, but on average it stands between 14% and 18%.⁵ AIT is relatively more frequent in iodine-deficient areas, whereas AIH is relatively more frequent in iodine-sufficient areas.¹⁸ In a cross-sectional study carried out in Western Tuscany (Italy) (moderately low iodine intake: urinary iodine excretion 68 ± 40 $\mu\text{g/g}$ of creatinine) and Massachusetts (USA) (normal iodine intake: 185 ± 21 $\mu\text{g/g}$), the incidence of AIT was about 10% in Italy and 2% in USA, while that of AIH was 5% in Italy and 22% in USA.¹⁸ In a prospective study of 58 consecutive amiodarone-treated patients from a Dutch region with moderately sufficient iodine intake, AIT occurred in 12% of cases and AIH in 7%.¹⁹ In a prospective study carried out in a moderately iodine-deficient Italian area, AIT occurred in 15% of patients and AIH in 71% of patients who had evidence of preexisting Hashimoto's thyroiditis.^{20,21} AIH may represent a transient phenomenon in patients who do not have an underlying chronic autoimmune thyroiditis.⁵

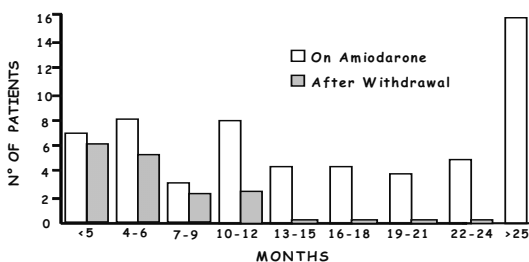


Fig.2. Onset of thyrotoxicosis during and after amiodarone therapy

Amiodarone Induced Thyrotoxicosis

AIT has a relative predominance among men (M:F ratio of 3:1)⁵ and may develop early in the treatment, after many years of therapy, or, owing to the long half-life of amiodarone and its metabolites, even 9-12 months after drug withdrawal (Fig.2). The occurrence of AIT seems to be unrelated to the daily or cumulative dose of amiodarone.¹⁹

Pathogenesis

Pathogenesis of AIT is complex and not completely understood. The disease may develop both in a normal thyroid gland (type II AIT) or in a gland with preexisting abnormalities (type I AIT) (Table 4). Thyroid autoimmune phenomena seems to play little, if any, role in the development of AIT in patients without underlying thyroid disorders or with nodular goiters, while they are important in patients with "latent" Graves' disease prior to amiodarone administration.²²

Type I AIT is a true form of hyperthyroidism (excessive thyroid hormone synthesis) triggered by iodine load. Intrathyroidal iodine content is markedly increased in all AIT patients, but there is no relevant impairment of iodine organification, as indicated by negative perchlorate discharge tests.^{23,24} In patients with preexisting thyroid abnormalities (nodular goiter, "latent" Graves' disease), the 24-h thyroidal radioactive iodine uptake (RAIU) values are, in type I AIT, inappropriately normal or even increased despite the iodine load;²⁵ this phenomenon is rarely observed in iodine sufficient areas, such as USA, where RAIU values are almost always very low or suppressed, as observed in type II AIT (destructive thyroiditis). This suggests that in mildly iodine deficient areas, patients with preexisting thyroid abnormalities may fail to adapt normally to an excessive iodine intake, leading to inappropriately normal or elevated RAIU values. This subgroup of AIT patients usually have normal or slightly elevated serum levels of interleukin-6 (IL-6), a good marker of thyroid-destructive processes,²⁶ implying that in type I AIT patients, thyroid-destructive processes play a minor pathogenic role. The fact that type I AIT (un-

derlying thyroid abnormality, normal/elevated RAIU values, normal/slightly elevated serum IL-6 levels) is indeed related to increased iodine-induced thyroid hormone synthesis is in keeping with the observation that in these cases the observed color flow doppler sonography (CFDS) patterns (pattern I-III) indicate a hyperfunctioning and hypervascularized thyroid gland, similar to spontaneous (amiodarone-unrelated) hyperthyroidism.²⁷

Type II AIT patients have an apparently normal thyroid gland (although in some cases there may be a small, tender goiter), no thyroid autoimmune phenomena, very low/suppressed RAIU values (usually <2-3%),²⁵ markedly increased serum IL-6 concentrations,²⁶ and absence of hypervascularity (CFDS pattern 0).²⁷ These features are similar to other thyroidal destructive processes, such as subacute thyroiditis,²⁸ albeit serum IL-6 determination is not always helpful for type II AIT diagnosis.²⁹ Likewise serum C-reactive protein (CRP), an acute-phase marker, could not correctly differentiate inflammatory and noninflammatory thyroid disorders; in fact, serum CPR levels did not differ significantly in patients with type I and type II AIT.³⁰ The destructive nature of type II AIT is further supported by the histopathologic examination of the thyroid, which demonstrates moderate to severe follicular damage and disruption.³¹ Therefore, thyrotoxicosis in type II AIT is due to discharge of preformed thyroid hormones from damaged follicles. In keeping with this concept, the thyrotoxic phase is sometimes followed by mild hypothyroidism,³² which may be accelerated by reexposure of the patient to iodine load.³³

The relative prevalence of these two main forms of AIT is unknown, but the environmental iodine may be relevant. Indeed, in iodine sufficient areas, where the incidence of multinodular goiters is very low, virtually only destructive-type AIT is observed.³⁴ It must underscored that mixed (or undefined) forms of AIT may occur probably more fre-

quently than previously recognized; in these cases the different pathogenic mechanisms and laboratory features of type I and type II AIT may coexist, i.e., presence of goiter and/or thyroid autoantibodies with markedly increased serum IL-6 levels or low/suppressed RAIU values.²⁵ As indicated by many respondents to a questionnaire on AIT distributed among members of the European Thyroid Association,³⁵ mixed (undefined) AIT cases are believed to be relatively frequent and constitute a difficult therapeutic problem (see below).

Clinical features

Clinical picture of AIT may be extremely variable. Exacerbation of the underlying cardiac disorder, particularly the difficulty in keeping tachyarrhythmias under proper control, may be the main clinical feature heralding the development of AIT in a patient under chronic amiodarone treatment.⁵ Common symptoms of thyrotoxicosis may be absent, particularly in the elderly; goiter may be present or absent, with or without pain in the thyroid region; ophthalmopathy is usually absent, unless AIT develops in a patient with previously unrecognized Graves' disease.⁵ Diagnosis of AIT may be a difficult challenge in patients with severe nonthyroidal illness, because comorbidity, especially in the elderly, may dominate the clinical picture and independently cause an increase in serum FT4, a decreased/suppressed serum TSH, and a reduction in serum total T3 concentration; under these circumstances, measurement of serum FT3 concentration may, however, be useful and decisive in establishing the correct diagnosis of thyrotoxicosis.³⁶ Serum thyroglobulin concentration is often increased in AIT, but this is not a specific and good marker of thyroid destruction in goitrous patients, who often have markedly elevated baseline serum thyroglobulin levels.

Management of AIT

Management of AIT constitutes a major challenge and a difficult task (Table 5). Con-

ventional antithyroid therapy is usually not effective in AIT; the high intrathyroidal iodine content reduces the efficacy of thionamides,⁵ while the often low/suppressed RAIU values preclude the possibility to treat these patients by radioiodine. Identification of the two main different subtypes of AIT, which, as we mentioned, is not always possible, should be pursued to provide a rational basis for the choice of the appropriate medical treatment and improve the therapeutic outcome.

Table 5. Management of amiodarone-induced thyrotoxicosis

	Treatment
Type I AIT	Thionamides+Potassium Perchlorate
Type II AIT	Thyroidectomy Glucocorticoids
Mixed forms	Thionamides+Potassium Perchlorate+ Glucocorticoids

Treatment of type I AIT

In type I AIT treatment should be aimed, on one hand, at blocking organification of iodine, thus inhibiting synthesis of thyroid hormones and, on the other, at decreasing further entry of iodine into the thyroid, thus depleting intrathyroidal iodine stores and making thionamide action more effective.

Thionamides represent a well established therapy for spontaneous hyperthyroidism due to Graves' disease, while they should be considered only a method to control hyperthyroidism prior to ablative therapy by either radioiodine or thyroidectomy for toxic adenoma or toxic multinodular goiter.³⁷ In the uncomplicated thyrotoxic patient, after the first few weeks of therapy with relatively high doses of the drug (e.g., 20-30 mg/day methimazole), low doses are generally sufficient to maintain euthyroidism.³⁷ In AIT, the iodine-repleted thyroid is more resistant to thionamides, making necessary the use of larger than usual daily doses of methimazole (40-60 mg) or propylthiouracil (600-800 mg).⁵ Despite the elevated doses of antithy-

roid drugs, patients often remain hyperthyroid for several months. This situation is obviously dangerous in view of the underlying cardiac conditions, and, in addition, exposes the patient to the risk of thionamide-induced side effects and complications, which are more frequent when high doses of the drug are used.³⁸ In a recent survey among members of the European Thyroid Association, 51% of respondents indicated thionamides as the first-choice treatment for type I AIT, but also suggested in the majority of cases that, should the patient still be hyperthyroid after few weeks of thionamide administration, potassium perchlorate should be added.³⁵ What is the rationale for this association? Potassium perchlorate per se is a weak antithyroid drug, but it has important actions that can be exploited in AIT. In fact, this drug reduces the entry of iodine into the thyroid and ultimately decreases intrathyroidal iodine stores; by these means, the efficacy of thionamides is improved. Management of AIT by concomitant treatment with potassium perchlorate and methimazole was first reported by our group in a study of 23 AIT patients who were treated with either methimazole (40 mg daily) alone, methimazole and potassium perchlorate (1 g daily), or were left untreated.³⁹ Only the combined treatment controlled thyrotoxicosis in all cases, and restored euthyroidism more rapidly than the conventional treatment with methimazole alone.³⁹ The major limitation of potassium perchlorate is represented by its potential side effects, particularly agranulocytosis, aplastic anemia, and renal toxicity.³⁸ However, these are infrequent if daily doses of the drug do not exceed 1 g.⁴⁰ In any case, it seems prudent to withdraw potassium perchlorate once euthyroidism has been restored and, in any case, after 5-6 weeks.⁵ Furthermore, a complete blood count should be made at weekly intervals to detect the potential occurrence of anemia and/or agranulocytosis.

The addition of lithium carbonate (900-1350 mg/day for 4-6 weeks), which decreases

thyroid hormone discharge from the gland, to propylthiouracil has been reported in a small series of AIT patients to shorten substantially the time period necessary to achieve euthyroidism,⁴¹ but these results require confirmation in larger and controlled studies.

Plasmapheresis can transiently reduce plasma amiodarone and DEA concentrations and, therefore, produce an improvement of clinical status for few days in AIT patients;⁴² however, the amount of amiodarone removed from the body is quite low (about 1 mg/plasmapheresis), and this transient improvement is often followed by an exacerbation of AIT.⁴³ Accordingly, plasmapheresis should be considered a desperate therapeutic measure to use when everything else fails.

Thyroidectomy represents a valid option for type I AIT patients resistant to medical treatment, although the underlying cardiac conditions and the thyrotoxic state may increase the surgical risk or even preclude surgery in some patients.⁴⁴ Recently we observed that a prompt restoration of euthyroidism before thyroidectomy can be achieved by a short course of iopanoic acid.⁴⁵ A series of AIT patients, whose thyrotoxicosis was previously uncontrolled and inevitably required amiodarone as a life-saving drug, were submitted to safe and uneventful total thyroidectomy: this approach made continuation of amiodarone therapy possible.⁴⁵ In the recent survey among members of the European Thyroid Association, surgical approach was selected by only 1% of respondents as the first-line treatment for type I AIT, but this proportion increased to 10% when antithyroid drugs proved to be ineffective in controlling thyrotoxicosis.³⁵

Treatment of type II AIT

Type II AIT is not a true form of hyperthyroidism due to increased thyroid hormone synthesis, but rather a destructive thyroiditis caused by amiodarone and/or iodine; accordingly, thionamides and potassium perchlorate are not effective.⁵ Conversely, steroids repre-

sent an effective treatment for type II AIT in view of their membrane-stabilizing and anti-inflammatory effects.⁴⁶ An additional beneficial action of steroids is the inhibition of peripheral T₄ conversion to T₃. Almost half of respondents to the European Thyroid Association survey indicated steroids as the first-line treatment for type II AIT.³⁵ Steroids have been employed in AIT at different doses (15-80 mg prednisone or 3-6 mg dexamethasone daily) and for different time periods (7-12 weeks);⁵ they provided favorable responses, either alone or in combination with antithyroid drugs, in most studies of patients with type II AIT,^{46,47} whereas in type I AIT, in agreement with its pathogenic mechanism, this treatment is poorly effective.⁴⁷ Recurrence of thyrotoxicosis is not exceptional following steroid withdrawal:⁴⁶ this makes reinstitution of steroid treatment necessary.

Oral cholecystographic agents (OCAs) affect peripheral metabolism of the thyroid hormones, mainly by inhibiting peripheral monodeiodination of T₄ to T₃,⁴⁸ and can be used in the treatment of the spontaneous hyperthyroidism.⁴⁹ The use of OCAs was reported in a mixed form of AIT in association with thionamides, KCLO₄ and glucocorticoids, and type II AIT in combination with thionamides.⁵⁰ We recently reported the results of a randomized, controlled study, in which we compared the long-term effects of treatment of type II AIT with either steroids or iopanoic acid.⁵¹ Both treatments were associated with a rapid decrease in serum FT₃ concentrations, but serum FT₄ levels remained markedly elevated for months in patients receiving iopanoic acid therapy,⁵¹ suggesting that iopanoic acid exerts its effects almost exclusively on the peripheral T₃ generation from T₄ but does not affect the thyroidal destructive process as glucocorticoids do. Accordingly, steroids must be considered the first-choice treatment for type II AIT. Iopanoic acid is useful, as in type I AIT, as a short-term treatment, in the preparation to thyroid surgery.⁴⁵

Mixed (or undefined) forms of AIT

A major problem physicians face when dealing with AIT is its correct classification. It seems more evident than in the past, that categorization of AIT in type I and type II is too schematic. In particular both pathogenic mechanisms (true thyroid hormone hyperproduction and destructive phenomena) may be concomitantly present in the same AIT patient. This situation may not be easily detectable despite the aid of diagnostic tools (ECDS, serum IL-6 measurement, thyroidal RAIU determination). This subgroup of AIT can be indicated as mixed or, probably better, undefined forms. Diagnostic uncertainty was underscored by 27% of respondents to the European Thyroid Association questionnaire, who defined the index case (a typical case of type I AIT) as a mixed form.³⁵ These diagnostic problems have a relevant impact on the therapeutic choice: in fact many thyroidologists prefer to treat AIT with a combination of thionamides (with or without potassium perchlorate) and steroids, both in cases of apparently clear-cut type I AIT and, more surprisingly, in patients with evident signs of destructive thyroiditis.³⁵ The answer to whether this multiple and complex pharmacologic approach is justified only in undefined forms of AIT or should be considered as the initial treatment in all cases of AIT, can only come from large, multicenter, randomized and controlled trials.

Open Questions

As outlined by the recent survey among members of the European Thyroid Association,³⁵ there are several areas of uncertainty pertaining to AIT.

Should amiodarone be withdrawn in patients who develop AIT? This is a major question, because amiodarone often represents an important (sometimes a life-saving) antiarrhythmic drug that cannot easily be discontinued or replaced. In addition, the long half-life of amiodarone (and its metabolites) causes the persistence of its effects on the thyroid gland even long after amiodarone

discontinuation.⁹ Remission of thyrotoxicosis while amiodarone was continued has been reported either spontaneously²⁸ or during antithyroid drug treatment.^{52,53,54} However, 90% of respondents to the European Thyroid Association questionnaire proposed amiodarone withdrawal for the index case (type I AIT) and 80% for the case variant (type II AIT).³⁵ Discontinuation of amiodarone might be associated with the removal of the “hypothyroid-like” effect of the drug on the heart and, therefore, an exacerbation of “heart thyrotoxicosis”. Continuation of amiodarone therapy might be more conceivable in type II AIT, which is considered a self-limiting process. It is our opinion, in the absence of controlled trials, that amiodarone therapy should be interrupted, whenever feasible, provided that the underlying cardiac situation allows this measure.

How should the thyroid be treated once euthyroidism has been restored and amiodarone has been withdrawn? The answer to this question largely depends on whether the thyroid gland is abnormal per se and amiodarone is required to control the underlying cardiac abnormalities. Type I AIT occurs in an abnormal thyroid gland affected with either nodular goiter or Graves' disease.⁵ Under these circumstances, in most cases the iodine load simply accelerates the natural course of the pre existing thyroid disorder. Given this premise, we believe that patients with type I AIT should be submitted, once euthyroidism has been restored and iodine contamination removed, to ablative therapy by either radioiodine or thyroidectomy. In the European Thyroid Association survey³⁵ this view was shared only by 34% of respondents, whereas 47% indicated that thyroid ablation should be carried out only if there is a recurrence of thyrotoxicosis. In type II AIT the thyroid gland is basically normal, and no sound information is available on the long-term natural outcome after this destructive process; however, it seems likely that these patients remain euthyroid or may become hypothyroid either spontaneously or after re-

exposure to iodine (and amiodarone?).⁵⁵ Accordingly, we believe that, after recovery from type II AIT, ablative therapy should not be a target; this view was shared by the majority of respondents to the European Thyroid Association survey.³⁵

What should be done if amiodarone therapy needs to be reinstated? While prophylactic radioiodine therapy or thyroidectomy was indicated by 65% of respondents to the European Thyroid Association questionnaire in the index case (type I AIT) and 27% in the case variant (type II AIT), follow-up and strict monitoring were suggested by 29% in the index case and 70% in the case variant.³⁵ In keeping with previous discussion, it is our opinion that thyroid ablation is preferable in type I (and undefined forms) AIT, while close surveillance may represent the best strategy for type II AIT.

What to do if hypothyroidism occurs after reinstatement of amiodarone therapy? As mentioned above and recently discussed in a Clinical Case Seminar,⁵⁵ reinstatement of amiodarone therapy may be associated with

the occurrence of hypothyroidism, although precise figures on this phenomenon are lacking. Under these circumstances, as also indicated by most European Thyroid Association respondents,³⁵ L-T₄ replacement should be given. Since the hypothyroid phase may be transient, a reassessment of the situation few months later following L-T₄ withdrawal, probably represents the best strategy in these cases.

Concluding Remarks

AIT represents a challenging situation, because of the lower effectiveness of conventional antithyroid treatments and the underlying cardiac abnormalities. A better definition of diagnostic criteria and classification is warranted, because this may lead to improvement of the therapeutic strategy and outcome. A strict collaboration between endocrinologists and cardiologists is needed for a better monitoring of amiodarone-treated patients and a prompter therapeutic intervention once AIT occurs.

References

1. Reiffel JA, Estes NA 3rd, Waldo AL, Prystowsky EN, DiBianco R. A consensus report on antiarrhythmic drug use. *Clin Cardiol* 1994; 17: 103-16.
2. Doval HC, Nul DR, Grancelli HO, Perrone SV, Bortman GR, Curiel R. Randomised trial of low-dose amiodarone in severe congestive heart failure. Grupo de Estudio de la Sobrevida en la Insuficiencia Cardiaca en Argentina (GESICA). *Lancet* 1994; 344: 493-8.
3. Harjai KJ, Licata AA. Effects of amiodarone on thyroid function. *Ann Intern Med* 1997; 126: 63-73.
4. Iudica-Souza C, Burch HB. Amiodarone-induced thyroid dysfunction. *The Endocrinologist* 1999; 9: 216-27.
5. Martino E, Bartalena L, Bogazzi F, Braverman LE. The effects of amiodarone on the thyroid. *Endocr Rev* 2001; 22: 240-54.
6. Rao RH, McCready VR, Spathis GS. Iodine kinetic studies during amiodarone treatment. *J Clin Endocrinol Metab.* 1986; 62: 563-8.
7. Holt DW, Tucker GT, Jackson PR, Storey GC. Amiodarone pharmacokinetics. *Am Heart J* 1983; 106: 840-7.
8. Plomp TA, van Rossum JM, Robles de Medina EO, van Lier T, Maes RA. Pharmacokinetics and body distribution of amiodarone in man. *Arzneimittelforschung* 1984; 34: 513-20.
9. Wiersinga WM. Amiodarone and the thyroid. In: Barlow JW, Weetman AP, Grossman A, editors. *Pharmacotherapeutics of the Thyroid Gland*. Newyork: Springer, 1997. p.225-87.
10. Sogol PB, Hershman JM, Reed AW, Dillmann WH. The effects of amiodarone on serum thyroid hormones and hepatic thyroxine 5'-monodeiodination in rats. *Endocrinology* 1983; 113: 1464-9.
11. Bakker O, van Beeren HC, Wiersinga WM. Desethylamiodarone is a noncompetitive inhibitor of the binding of thyroid hormone to the thyroid hormone beta 1-receptor protein. *Endocrinology* 1994; 134: 1665-70.

12. Bogazzi F, Bartalena L, Brogioni S, Burelli A, Raggi F, Ultimieri F, et al. Desethylamiodarone antagonizes the effect of thyroid hormone at the molecular level. *Eur J Endocrinol* 2001; 145: 59-64.
13. Pitsiavas V, Smerdely P, Li M, Boyages SC. Amiodarone induces a different pattern of ultrastructural change in the thyroid to iodine excess alone in both the BB/W rat and the Wistar rat. *Eur J Endocrinol* 1997; 137: 89-98.
14. Chiovato L, Martino E, Tonacchera M, Santini F, Lapi P, Mammoli C, et al. Studies on the in vitro cytotoxic effect of amiodarone. *Endocrinology* 1994; 134: 2277-82.
15. Di Matola T, D'Ascoli F, Fenzi G, Rossi G, Martino E, Bogazzi F, et al. Amiodarone induces cytochrome c release and apoptosis through an iodine-independent mechanism. *J Clin Endocrinol Metab* 2000; 85: 4323-30.
16. McGregor AM, Weetman AP, Ratanachaiyavong S, Owen GM, Ibbertson HK, Hall R. Iodine: an influence on the development of autoimmune thyroid disease. In: Hall R, Kobberling J, editors. *Thyroid disorders associated with iodine deficiency and excess*. New York: Raven Press, 1985. P.209-16.
17. Allen EM, Appel MC, Braverman LE. The effect of iodide ingestion on the development of spontaneous lymphocytic thyroiditis in the diabetes-prone BB/W rat. *Endocrinology*. 1986; 118: 1977-81.
18. Martino E, Safran M, Aghini-Lombardi F, Rajatanavin R, Lenziardi M, Fay M, et al. Environmental iodine intake and thyroid dysfunction during chronic amiodarone therapy. *Ann Intern Med* 1984; 101: 28-34.
19. Trip MD, Wiersinga W, Plomp TA. Incidence, predictability, and pathogenesis of amiodarone-induced thyrotoxicosis and hypothyroidism. *Am J Med* 1991; 91: 507-11.
20. Martino E, Aghini-Lombardi F, Bartalena L, Grasso L, Loviselli A, Velluzzi F, et al. Enhanced susceptibility to amiodarone-induced hypothyroidism in patients with thyroid autoimmune disease. *Arch Intern Med* 1994; 154: 2722-6.
21. Martino E, Aghini-Lombardi F, Mariotti S, Bartalena L, Braverman L, Pinchera A. Amiodarone: a common source of iodine-induced thyrotoxicosis. *Horm Res* 1987; 26: 158-71.
22. Martino E, Macchia E, Aghini-Lombardi F, Antonelli A, Lenziardi M, Concetti R, et al. Is humoral thyroid autoimmunity relevant in amiodarone iodine-induced thyrotoxicosis (AIIT)? *Clin Endocrinol (Oxf)* 1986; 24: 627-33.
23. Wiersinga WM, Touber JL, Trip MD, van Royen EA. Uninhibited thyroidal uptake of radioiodine despite iodine excess in amiodarone-induced hypothyroidism. *J Clin Endocrinol Metab* 1986; 63: 485-91.
24. Martino E, Aghini-Lombardi F, Lippi F, Baschieri L, Safran M, Braverman LE, et al. Twenty-four hour radioactive iodine uptake in 35 patients with amiodarone associated thyrotoxicosis. *J Nucl Med* 1985; 26: 1402-7.
25. Bartalena L, Grasso L, Brogioni S, Aghini-Lombardi F, Braverman LE, Martino E. Serum interleukin-6 in amiodarone-induced thyrotoxicosis. *J Clin Endocrinol Metab* 1994; 78: 423-7.
26. Bartalena L, Brogioni S, Grasso L, Rago T, Vitti P, Pinchera A, et al. Interleukin-6: a marker of thyroid-destructive processes? *J Clin Endocrinol Metab* 1994; 79: 1424-7.
27. Bogazzi F, Bartalena L, Brogioni S, Mazzeo S, Vitti P, Burelli A, et al. Color flow Doppler sonography rapidly differentiates type I and type II amiodarone-induced thyrotoxicosis. *Thyroid* 1997; 7: 541-5.
28. Bartalena L, Brogioni S, Grasso L, Martino E. Increased serum interleukin-6 concentration in patients with subacute thyroiditis: relationship with concomitant changes in serum T4-binding globulin concentration. *J Endocrinol Invest* 1993; 16: 213-8.
29. Eaton SE, Euinton HA, Newman CM, Weetman AP, Bennet WM. Clinical experience of amiodarone-induced thyrotoxicosis over a 3-year period: role of colour-flow Doppler sonography. *Clin Endocrinol (Oxf)* 2002; 56: 33-8.
30. Pearce EN, Bogazzi F, Martino E, Brogioni S, Pardini E, Pellegrini G, et al. The prevalence of elevated serum C-reactive protein levels in inflammatory and noninflammatory thyroid disease. *Thyroid* 2003; 13: 643-8.
31. Brennan MD, Erickson DZ, Carney JA, Bahn RS. Nongoitrous (type I) amiodarone-associated thyrotoxicosis: evidence of follicular disruption in vitro and in vivo. *Thyroid* 1995; 5: 177-83.
32. Roti E, Minelli R, Gardini E, Bianconi L, Braverman LE. Thyrotoxicosis followed by hypothyroidism in patients treated with amiodarone. A possible consequence of a destructive process in the thyroid. *Arch Intern Med* 1993; 153: 886-92.
33. Roti E, Minelli R, Gardini E, Bianconi L, Gavaruzzi G, Ugolotti G, et al. Iodine-induced subclinical hypothyroidism in euthyroid subjects with a previous episode of amiodarone-induced thyrotoxicosis. *J Clin Endocrinol Metab*. 1992; 75: 1273-7.
34. Sato K, Miyakawa M, Eto M, Inaba T, Matsuda N, Shiga T, et al. Clinical characteristics of amiodarone-induced thyrotoxicosis and hypothyroidism in Japan. *Endocr J* 1999; 46: 443-51.
35. Bartalena L, Wiersinga WM, Tanda ML, Bogazzi F, Piantanida E, Lai A, et al. Diagnosis and management of amiodarone-induced thyrotoxicosis in

- Europe: results of an international survey among members of the European Thyroid Association. *Clin Endocrinol (Oxf)* 2004; 61: 494-502.
36. Balzano S, Sau F, Bartalena L, Ruscasio M, Balestrieri A, Cherchi A, et al. Diagnosis of amiodarone-iodine-induced thyrotoxicosis (AIIT) associated with severe nonthyroidal illness. *J Endocrinol Invest*. 1987; 10: 589-91.
 37. Bartalena L, Tanda ML, Bogazzi F, Piantanida E, Lai A, Martino E. An update on the pharmacological management of hyperthyroidism due to Graves' disease. *Expert Opin Pharmacother* 2005; 6: 851-61.
 38. Bartalena L, Bogazzi F, Martino E. Adverse effects of thyroid hormone preparations and antithyroid drugs. *Drug Saf* 1996; 15: 53-63.
 39. Martino E, Aghini-Lombardi F, Mariotti S, Lenziardi M, Baschieri L, Braverman LE, et al. Treatment of amiodarone associated thyrotoxicosis by simultaneous administration of potassium perchlorate and methimazole. *J Endocrinol Invest* 1986; 9: 201-7.
 40. Trotter WR. The relative toxicity of antithyroid drugs. *J New Drugs* 1962; 2: 333-43.
 41. Dickstein G, Shechner C, Adawi F, Kaplan J, Baron E, Ish-Shalom S. Lithium treatment in amiodarone-induced thyrotoxicosis. *Am J Med* 1997; 102: 454-8.
 42. Uzzan B, Pussard E, Leon A, Bekhechi D, Krivitzky A, Modigliani E, et al. The effects of plasmapheresis on thyroid hormone and plasma drug concentrations in amiodarone-induced thyrotoxicosis. *Br J Clin Pharmacol* 1991; 31: 371-2.
 43. Aghini-Lombardi F, Mariotti S, Fosella PV, Grasso L, Pinchera A, Braverman LE, et al. Treatment of amiodarone iodine-induced thyrotoxicosis with plasmapheresis and methimazole. *J Endocrinol Invest* 1993; 16: 823-6.
 44. Farwell AP, Abend SL, Huang SK, Patwardhan NA, Braverman LE. Thyroidectomy for amiodarone-induced thyrotoxicosis. *JAMA* 1990; 263: 1526-8.
 45. Bogazzi F, Aghini-Lombardi F, Cosci C, Lupi I, Santini F, Tanda ML, et al. Lopanoic acid rapidly controls type I amiodarone-induced thyrotoxicosis prior to thyroidectomy. *J Endocrinol Invest* 2002; 25: 176-80.
 46. Bartalena L, Brogioni S, Grasso L, Bogazzi F, Burelli A, Martino E. Treatment of amiodarone-induced thyrotoxicosis, a difficult challenge: results of a prospective study. *J Clin Endocrinol Metab* 1996; 81: 2930-3.
 47. Broussolle C, Ducottet X, Martin C, Barbier Y, Bornet H, Noel G, et al. Rapid effectiveness of prednisone and thionamides combined therapy in severe amiodarone iodine-induced thyrotoxicosis. Comparison of two groups of patients with apparently normal thyroid glands. *J Endocrinol Invest* 1989; 12: 37-42.
 48. Braga M, Cooper DS. Clinical review 129: Oral cholecystographic agents and the thyroid. *J Clin Endocrinol Metab* 2001; 86: 1853-60.
 49. Wu SY, Chopra IJ, Solomon DH, Bennett LR. Changes in circulating iodothyronines in euthyroid and hyperthyroid subjects given ipodate (Oragrafin), an agent for oral cholecystography. *J Clin Endocrinol Metab* 1978; 46: 691-7.
 50. Chopra IJ, Baber K. Use of oral cholecystographic agents in the treatment of amiodarone-induced hyperthyroidism. *J Clin Endocrinol Metab* 2001; 86: 4707-10.
 51. Bogazzi F, Bartalena L, Cosci C, Brogioni S, Dell'Unto E, Grasso L, et al. Treatment of type II amiodarone-induced thyrotoxicosis by either iopanoic acid or glucocorticoids: a prospective, randomized study. *J Clin Endocrinol Metab* 2003; 88: 1999-2002.
 52. Davies PH, Franklyn JA, Sheppard MC. Treatment of amiodarone induced thyrotoxicosis with carbimazole alone and continuation of amiodarone. *BMJ* 1992; 305: 224-5.
 53. Trip MD, Duren DR, Wiersinga WM. Two cases of amiodarone-induced thyrotoxicosis successfully treated with a short course of antithyroid drugs while amiodarone was continued. *Br Heart J* 1994; 72: 266-8.
 54. Newman CM, Price A, Davies DW, Gray TA, Weetman AP. Amiodarone and the thyroid: a practical guide to the management of thyroid dysfunction induced by amiodarone therapy. *Heart* 1998; 79: 121-7.
 55. Ryan LE, Braverman LE, Cooper DS, Ladenson PW, Kloos RT. Can amiodarone be restarted after amiodarone-induced thyrotoxicosis? *Thyroid* 2004; 14: 149-53.