



UNIVERSITÀ
DEGLI STUDI
DI PADOVA

Università degli Studi di Padova

Padua Research Archive - Institutional Repository

Coinfection by *Ureaplasma* spp., *Photobacterium damsela* and an Actinomyces-like microorganism in a bottlenose dolphin (*Tursiops truncatus*) with pleuropneumonia stranded

Original Citation:

Availability:

This version is available at: 11577/3179505 since: 2016-11-02T06:41:05Z

Publisher:

Published version:

DOI: 10.1016/j.rvsc.2016.01.022

Terms of use:

Open Access

This article is made available under terms and conditions applicable to Open Access Guidelines, as described at <http://www.unipd.it/download/file/fid/55401> (Italian only)

(Article begins on next page)

Accepted Manuscript

Coinfection by *Ureaplasma* spp., *Photobacterium damsela*e and an *Actinomyces*-like microorganism in a bottlenose dolphin (*Tursiops truncatus*) with pleuropneumonia stranded along the Adriatic coast of Italy

Gabriella Di Francesco, Cesare Cammà, Valentina Curini, Sandro Mazzariol, Umberto Proietto, Cristina Esmeralda Di Francesco, Nicola Ferri, Andrea Di Provvido, Giovanni Di Guardo

PII: S0034-5288(16)30022-4
DOI: doi: [10.1016/j.rvsc.2016.01.022](https://doi.org/10.1016/j.rvsc.2016.01.022)
Reference: YRVSC 3043

To appear in:

Received date: 27 October 2015
Revised date: 12 January 2016
Accepted date: 29 January 2016

Please cite this article as: Di Francesco, Gabriella, Cammà, Cesare, Curini, Valentina, Mazzariol, Sandro, Proietto, Umberto, Di Francesco, Cristina Esmeralda, Ferri, Nicola, Di Provvido, Andrea, Di Guardo, Giovanni, Coinfection by *Ureaplasma* spp., *Photobacterium damsela*e and an *Actinomyces*-like microorganism in a bottlenose dolphin (*Tursiops truncatus*) with pleuropneumonia stranded along the Adriatic coast of Italy, (2016), doi: [10.1016/j.rvsc.2016.01.022](https://doi.org/10.1016/j.rvsc.2016.01.022)

This is a PDF file of an unedited manuscript that has been accepted for publication. As a service to our customers we are providing this early version of the manuscript. The manuscript will undergo copyediting, typesetting, and review of the resulting proof before it is published in its final form. Please note that during the production process errors may be discovered which could affect the content, and all legal disclaimers that apply to the journal pertain.



Short Communication

(ms. no. RVSC-15-986-Rev. 2)

Coinfection by *Ureaplasma* spp., *Photobacterium damsela*e and an *Actinomyces*-like microorganism in a bottlenose dolphin (*Tursiops truncatus*) with pleuropneumonia stranded along the Adriatic coast of Italy

Gabriella Di Francesco (1), Cesare Cammà (1), Valentina Curini (1), Sandro Mazzariol (2), Umberto Proietto (3), Cristina Esmeralda Di Francesco (4), Nicola Ferri (1), Andrea Di Provvido (1), Giovanni Di Guardo (4)*

(1) Istituto Zooprofilattico Sperimentale dell'Abruzzo e del Molise "G. Caporale", Teramo, Italy;

(2) University of Padua, Department of Comparative Biomedicine and Food Science, Legnaro (Padova), Italy;

(3) Veterinary Practitioner, Giulianova, Teramo, Italy;

(4) University of Teramo, Faculty of Veterinary Medicine, Località Piano d'Accio, Teramo, Italy;

*Corresponding author (E-mail address: gdiuardo@unite.it).

Short running title: *Ureaplasma*, *Photobacterium damsela*e and *Actinomyces*-like coinfection in a dolphin.

Key-words: Bottlenose dolphin, pleuropneumonia, *Ureaplasma* spp., *Photobacterium damsela*e, *Actinomyces*, Adriatic Sea.

Highlights

Ureaplasma, *Photobacterium damsela* subsp. *piscicida* and *Actinomyces*-like coinfection in a dolphin.

Isolation of the three aforementioned pathogens from pleuropneumonia lesions.

Biomolecular characterization of *Ureaplasma* and *Photobacterium damsela* subsp. *piscicida*.

Abstract

A case of pleuropneumonia is reported in an adult male bottlenose dolphin (*Tursiops truncatus*) found stranded in 2014 along the Central Adriatic coast of Italy. A severe pyogranulomatous pneumonia and thoracic lymphadenopathy were present at necropsy. Numerous *Splendore-Hoeppli* bodies were found microscopically scattered throughout the lung. Histochemical evidence of *Actinomyces*-like organisms was obtained from the pulmonary parenchyma, with a strain of *Photobacterium damsela* subsp. *piscicida* and *Ureaplasma* spp. being also isolated from the same tissue. For the latter, a genome fragment of approximately 1,400bp from the 16s rDNA was amplified and sequenced. BLAST analysis revealed 100% identity with an uncultured *Ureaplasma* spp. (JQ193826.1).

In recent years, there has been a growing interest in aquatic mammal health, ecology and conservation. This has enabled, among others, the expansion of our knowledge of infectious diseases in free-living pinnipeds and cetaceans, some of which are also considered emerging public health issues (Van Bressem et al., 2009).

Within this framework, a “*National Cetacean Stranding and Health Surveillance Network*” was created in 2010 in Italy, under the joint supervision of the Ministry for the Environment and of the Ministry of Health, in order to standardize the diagnostic protocols and improve the collection of data obtained from stranded cetaceans.

Aim of the present work is to describe the anatomico-histopathological changes observed in a bottlenose dolphin (*Tursiops truncatus*) stranded along the Central Adriatic coast of Italy, along with the identification and characterization of the microbial pathogens associated with the lung lesions.

An adult male bottlenose dolphin, found stranded lifeless in July 2014 along the Central Adriatic Sea coast (Pineto, Abruzzo Region, Italy), was subjected to a detailed *post mortem* examination at the Istituto Zooprofilattico Sperimentale dell’Abruzzo e del Molise “*G. Caporale*” (Teramo, Italy). The animal’s decomposition code was 3, according to a standardized and widely utilized protocol (Geraci and Lounsbury, 2005). During necropsy, body tissues were both fixed in 10% neutral buffered formalin and frozen at -20°C for microbiological and ecotoxicological investigations. Faecal samples were also collected, while blood clots were obtained from the heart chambers and centrifuged, with the resulting serum being stored at -20°C.

Tissues were routinely processed for histopathological investigations, with periodic acid Schiff (PAS), Grocott and Ziehl-Neelsen staining techniques being additionally applied on selected lung sections and Gram stain on unfixed pulmonary tissue smears. Immunohistochemistry (IHC) against *Ureaplasma* spp. was performed on selected lung tissue sections, utilizing a polyclonal antiserum raised in rabbits, while IHC against *Morbillivirus* was carried out on selected lung, pulmonary lymph node and brain tissue sections with a commercially available, murine monoclonal antibody raised against a highly conserved region of the *Canine Distemper Virus* (CDV) nucleoprotein (N) antigen (VMRD Inc., USA). Suitable positive and negative control tissue specimens were included in each IHC run. Furthermore, biomolecular (PCR, RT-PCR) investigations for *Brucella* spp. and *Morbillivirus* were performed on a range of tissues utilizing two previously published protocols (Frisk et al., 1999; OIE, 2011), while serological investigations for *Morbillivirus*, *Toxoplasma gondii* and *Brucella* spp. were carried out based on reported methods (Di Guardo et al., 2010). Detailed microbiological analyses were additionally performed on all major organs, with the lung

being cultured in supplemented PPLO-selective *media* (Difco™ and BBL™ PPLO broth and PPLO agar, BD Biosciences, NJ, USA).

Furthermore, biomolecular investigations were carried out on DNA extracted from the pulmonary tissue. A portion of the 16s rDNA for *Mycoplasma* spp. (Kumar et al., 2013), along with a fragment of the gene coding for a penicillin-binding protein (PBP) of *Photobacterium damsela* (Serracca et al., 2011), as well as with an approximately 550 bp long sequence of the rRNA internal transcribed spacer region (ITS) for detecting fungi (Schoch et al., 2012), were amplified. The obtained PCR products were then sequenced and submitted for a BLAST search (<http://blast.ncbi.nlm.nih.gov/Blast.cgi>).

Finally, biomolecular (PCR) investigations aimed at detecting *Mycoplasma* spp. were performed from the aforementioned PPLO-selective *media*. Once DNA was extracted from broth-derived pellets, the 16s rDNA was amplified by a modified PCR protocol (Kumar *et al.*, 2013), with PCR products being sequenced and submitted for a BLAST search (<http://blast.ncbi.nlm.nih.gov/Blast.cgi>). Macroscopically, a diffuse and severe, bilateral pleuropneumonia was observed, with the lung being tightly adherent to the costal pleural surface and with pulmonary lesions characterized by multifocal and coalescing necrotic areas (Fig. 1, a-b). Furthermore, a loco-regional lymphadenopathy involving the pulmonary, mediastinal and tracheo-bronchial lymph nodes was apparent, with mesenteric lymph nodes also exhibiting a marked enlargement.

Histologically, variably sized, multifocal and coalescing pyogranulomatous lesions were seen scattered throughout the lung tissue. The aforementioned pyogranulomas showed central necrosis, while several aggregates of an intensely eosinophilic and amorphous material consistent with *Splendore-Hoeppli* bodies (so-called “*Splendore-Hoeppli* phenomenon”) could be simultaneously found in close proximity to, or within pyogranulomatous lesions (Fig. 2, a). Pulmonary tissue smears showed Gram-positive, filamentous bacterial organisms and colonies (Fig. 2, b). These microbial aggregates, which were frequently observed either within or at the periphery of the aforementioned pyogranulomatous lesions, were positively stained also by Grocott (Fig. 2, c) and negatively stained by PAS and Ziehl-Neelsen techniques. Their morphological and histochemical staining features were consistent with those of *Actinomycetales*. Bacterial aggregates were also seen neighbouring slight, lymphoplasmacytic inflammatory foci affecting the dolphin’s myocardium. Additionally, a moderate lymphoid cell depletion was found in the pulmonary, mediastinal, tracheo-bronchial and mesenteric lymph nodes.

Biomolecular, IHC and serological investigations for *Morbillivirus*, *T. gondii* and *Brucella* spp. yielded negative results, similarly to biomolecular analyses and cultures for fungi, mycobacteria and

Brucella spp.

Microbiological examinations allowed the isolation of *Photobacterium damsela* and an *Ureaplasma*-like agent from the lung tissue. For the latter, a genome fragment of approximately 1,400 bp from the 16s rDNA was amplified and sequenced. BLAST analysis revealed 100% identity with an uncultured *Ureaplasma* spp. (JQ193826.1). Moreover, BLAST analysis of a fragment of the gene coding for a penicillin-binding protein (PBP) of approximately 290 bp in length revealed 99% identity of our bacterial isolate with *Photobacterium damsela* subsp. *piscicida* (EU164926.1). Despite the repeated attempts of biomolecular characterization, it was not possible to identify the *Actinomyces*-like agent detected in close association with the pyogranulomatous lung lesions.

On the basis of the above results, coupled with those reported in the scientific literature (Baker, 1992; Di Guardo *et al.*, 1995), we believe that the extensive lung lesions played an important role in the stranding and subsequent death of the bottlenose dolphin. Although the chronology of the infection with the three concerned pathogens cannot be defined, the pyogranulomatous morphology of the pulmonary lesions, associated with the simultaneous occurrence of *Splendore-Hoeppli* bodies, strongly supports an *Actinomyces*-like/*Nocardia*-like or, alternatively, a fungal aetiology (Higgins, 2000). Indeed, a number of fungal, parasitic and bacterial infections have been causally linked to the occurrence of the “*Splendore-Hoeppli* phenomenon”, with actinomycosis and nocardiosis being also included among the latter conditions (Hussein, 2008). In this respect, we believe that an *Actinomyces*-like rather than a *Nocardia*-like agent was involved in the determinism of the pyogranulomatous inflammatory lesions found in the dolphin under study, since *Nocardia* spp. is often acid-fast, while *Actinomyces* spp. is a non-acid-fast microorganism (Robboy and Vickery, 1970). Additionally, since the pathogenic role of *P. damsela* for cetaceans - as well as for other mammalian species - still remains unsolved (Casalone *et al.*, 2014), we cannot assign a precise aetiological responsibility to this bacterial agent for the lung lesions reported herein. The isolation from the dolphin’s pulmonary parenchyma of an *Ureaplasma* spp. strain exhibiting a 100% sequence homology with an uncultured *Ureaplasma* spp. agent (JQ193826.1) is also of interest as this microorganism has not been hitherto identified in cetaceans. Conversely, *Mycoplasma* spp. infection has been reported in free-living pinnipeds (Geraci *et al.*, 1982; Higgins, 2000) and in cetaceans stranded in Scottish waters (Foster *et al.*, 2011).

Ureaplasma spp. infection has been documented in human patients and in non-human primates (Kanamoto *et al.*, 1983; Neto *et al.*, 2013; Taylor-Robinson, 2013; Gancia *et al.*, 2014), as well as in

cattle, goat, sheep, swine, cats, dogs, raccoon dogs (*Nyctereutes procyonoides viverrinus*) and chickens (Kanamoto et al., 1983; Burgher et al., 2014; dos Santos et al., 2014; Gaeti et al., 2014). *Ureaplasma* spp. has been detected in ovine semen samples (dos Santos et al., 2014), being additionally responsible for pustular vulvovaginitis and abortion in cattle (Gaeti et al., 2014), alongside with urethral inflammation in male chimpanzees (*Pan troglodytes*) (Taylor-Robinson, 2013). *Ureaplasma* spp. infection can also occur *in utero* or during the perinatal period in human premature infants, with some individuals developing a prominent lung pro-inflammatory and pro-fibrotic response, resulting at its turn in an increased risk of bronchopulmonary dysplasia occurrence (Gancia et al., 2014). Noteworthy, *Ureaplasma diversum* has been recently isolated from the lung tissue of pigs with pneumonia (Burgher et al., 2014).

The recognition of *Ureaplasma* spp. in the lung tissue from the dolphin under study raises a number of concerns addressing its role as a primary, secondary, or incidental pathogen. Furthermore, since no information is currently available on *Ureaplasma* spp. infection among free-ranging cetaceans, we cannot draw any conclusion, nor even make any “reliable” hypothesis on the associated/related “population level effects”. Nevertheless, the documented tropism of this microorganism for the female and the male reproductive system in several mammalian species (Neto et al., 2013; Taylor-Robinson, 2013; dos Santos et al., 2014; Gaeti et al., 2014; Gancia et al., 2014), coupled with the pathogen’s ability to cross the human placental barrier (Gancia et al., 2014), are of relevant concern, should a similar situation take place also in wild cetaceans.

The occurrence of a coinfection by three distinct microbial agents is made plausible by the lymphoid cell depletion observed in the dolphin under study, with the resulting immunosuppression likely acting as its common risk factor. Immunodeficiency may result from previous exposure to physical (such as radiation), chemical (such as “heavy metals” and “persistent organic pollutants”) and biological (such as *Morbillivirus*) “stressors”, acting alone or in combination. In this respect, Odontocete cetaceans like dolphins are known to accumulate within their body tissues, as “top predators”, high concentrations of immunotoxic pollutants, which can make them more susceptible to several microbial pathogens (Van Bresse et al., 2009). Additionally, a consistent proportion of *Dolphin Morbillivirus* (DMV)-infected striped dolphins found stranded along the Tyrrhenian Sea coast of Italy in the context of the “unusual mortality event” that occurred in the first mid of 2013, turned out to be simultaneously coinfecting by *P. damsela* subsp. *damsela* (Casalone et al., 2014).

In conclusion, additional investigations aimed at defining the timing of colonization of the pulmonary tissue, along with the pathogenic role exerted in lung lesions’ development by the three microbial agents identified, are warranted. Furthermore, we believe that *ad hoc* epidemiological

studies are needed to assess the occurrence, frequency, distribution and health/conservation impact(s) of *Mycoplasma* spp., *Ureaplasma* spp. and *P. damsela* in cetaceans found stranded in Mediterranean waters and in all other world seas.

Conflict of interest statement

The authors declare that no conflicts of interest of any kind exist in relation to the publication of this article.

Acknowledgements

We would like to thank the Italian Ministry of Health for having financially supported this study in the framework of “*Progetti di Ricerca Corrente 2010*”. We would also like to acknowledge the Italian “*Centro Studi Cetacei*” for kindly providing valuable technical support.

References

- Baker, J.R., 1992. Causes of mortality and parasites and incidental lesions in dolphins and whales from British waters. *Veterinary Record* 130, 569-572.
- Burgher, Y., Miranda, L., Rodriguez-Roche, R., de Almeida Campos, A.C., Lobo, E., Neves, T., Martínez, O., Timenetsky, J., 2014. *Ureaplasma diversum* in pneumonic lungs of swine. *Infection, Genetics and Evolution* 21, 486-488.
- Casalone, C., Mazzariol, S., Pautasso, A., Di Guardo, G., Di Nocera, F., Lucifora, G., Ligios, C., Franco, A., Fichi, G., Cocumelli, C., Cersini, A., Guercio, A., Puleio, R., Gorla, M., Podestà, M., Marsili, L., Pavan, G., Pintore, A., De Carlo, E., Eleni, C., Caracappa, S., 2014. Cetacean strandings in Italy: An unusual mortality event along the Tyrrhenian Sea coast in 2013. *Diseases of Aquatic Organisms* 109, 81-86.
- Di Guardo, G., Agrimi, U., Morelli, L., Cardeti, G., Terracciano, G., Kennedy, S., 1995. *Post mortem* investigations on cetaceans found stranded on the coasts of Italy between 1990 and 1993. *Veterinary Record* 136, 439-442.
- Di Guardo, G., Proietto, U., Di Francesco, C.E., Marsilio, F., Zaccaroni, A., Scaravelli, D., Mignone, W., Garibaldi, F., Kennedy, S., Forster, F., Iulini, B., Bozzetta, E., Casalone, C., 2010. Cerebral toxoplasmosis in striped dolphins (*Stenella coeruleoalba*) stranded along the Ligurian Sea coast of Italy. *Veterinary Pathology* 47, 245-253.
- dos Santos, S.B., de Souza Neto, O.L., de Albuquerque, P.P., da Rocha Mota, A., de Cássia Peixoto Kim, P., de Moraes, E.P., do Nascimento, E.R., do Mota, R.A., 2014. Detection of *Ureaplasma* spp. in semen samples from sheep in Brazil. *Brazilian Journal of Microbiology* 44, 911-914.
- Foster, G., McAuliffe, L., Dagleish, M.P., Barley, J., Howie, F., Nicholas, R.A., Ayling, R.D., 2011. *Mycoplasma* species isolated from harbor porpoises (*Phocoena phocoena*) and a Sowerby's beaked whale (*Mesoplodon bidens*) stranded in Scottish waters. *Journal of Wildlife Diseases* 47,

206-211.

Frisk, A.L., König, M., Moritz, A., Baumgärtner, W. 1999. Detection of *Canine Distemper Virus* nucleoprotein RNA by reverse transcription-PCR using serum, whole blood, and cerebrospinal fluid from dogs with distemper. *Journal of Clinical Microbiology* 37, 3634-3643.

Gaeti, J.G., Lana, M.V., Silva, G.S., Lerner, L., de Campos, C.G., Haruni, F., Colodel, E.M., Costa, E.F., Corbellini, L.G., Nakazato, L., Pescador, C.A., 2014. *Ureaplasma diversum* as a cause of pustular vulvovaginitis in bovine females in Vale Guapore, Mato Grosso State, Brazil. *Tropical Animal Health and Production* 46, 1059-1063.

Gancia, P., Delogu, A., Pomeroy, G., 2014. *Ureaplasma* and bronchopulmonary dysplasia. *Early Human Development* 90 (Suppl. 1), S39-41.

Geraci, J.R., Lounsbury, V.J. (Eds.), 2005. *Marine Mammals Ashore: A Field Guide for Strandings*, second ed. National Aquarium in Baltimore, Inc, Baltimore, MD, USA, p. 380.

Geraci, J.R., St Aubin, D.J., Barker, I.K., Webster, R.G., Hinshaw, V.S., Bean, W.J., Ruhnke, H.L., Prescott, J.H., Early, G., Baker, A.S., Madoff, S., Schooley, R.T., 1982. Mass mortality of harbor seals: Pneumonia associated with influenza A virus. *Science* 215, 1129-1131.

Higgins, R., 2000. Bacteria and fungi of marine mammals: A review. *Canadian Veterinary Journal* 41, 105-116.

Hussein, M.R., 2008. Mucocutaneous Splendore-Hoeppli phenomenon. *Journal of Cutaneous Pathology* 35, 979-988.

Kanamoto, Y., Kotani, H., Ogata, M., Matsuo, Y., 1983. Isolation of *Mycoplasma* and *Ureaplasma* species from raccoon dogs (*Nyctereutes procyonoides viverrinus*). *Journal of General Microbiology* 129, 2447-2450.

Kumar, V., Rana, R., Mehra, S., Rout, P.K., 2013. Isolation and characterization of *Mycoplasma*

mycoides subspecies *capri* from milk of natural goat mastitis cases. ISRN Veterinary Science 20, 593029; doi: 10.1155/2013/593029.

Neto, R.L., Marques, L.M., Guimarães, A.M., Yamaguti, M., Oliveira, R.C., Gaetti-Jardim, E. Jr., Medina, A.O., Sanfilippo, L.F., Timenetsky, J., 2013. Frequency of different human mollicutes species in the mucosa of the oropharynx, conjunctiva, and genitalia of free-ranging and captive capuchin monkeys (*Cebus* spp.). American Journal of Primatology 75, 973-978.

Robboy, S.J., Vickery, A.L., 1970. Tinctorial and morphologic properties distinguishing actinomycosis and nocardiosis. New England Journal of Medicine 282, 593-596.

Schoch, C.L., Seifert, K.A., Huhndorf, S., Robert, V., Spouge, J.L., Levesque, C.A., Chen, W., 2012. Nuclear ribosomal internal transcribed spacer (ITS) region as a universal DNA barcode marker for fungi. Proceedings of the National Academy of Sciences USA 109, 6241-6246.

Serracca, L., Ercolini, C., Rossini, I., Battistini, R., Giorgi, I., Prearo, M., 2011. Occurrence of both subspecies of *Photobacterium damsela* in mullets collected in the river Magra (Italy). Canadian Journal of Microbiology 57, 437-440.

Taylor-Robinson, D., 2013. Urethral inflammation in male chimpanzees caused by ureaplasmas and *Chlamydia trachomatis*. Journal of Medical Microbiology 62, 1609-1613.

Van Bresse, M.F., Raga, J.A., Di Guardo, G., Jepson, P.D., Duignan, P.J., Siebert, U., Barrett, T., Santos, M.C., Moreno, I.B., Siciliano, S., Aguilar, A., Van Waerebeek, K., 2009. Emerging infectious diseases in cetaceans worldwide and the possible role of environmental stressors. Diseases of Aquatic Organisms 86, 143-157.

World Organisation for Animal Health (Office International des Épizooties: OIE), 2011. Bovine brucellosis. In: Manual of Diagnostic Tests and Vaccines for Terrestrial Animals, Chapter 2.4.3., OIE, Paris, 343 pp.

FIGURES' LEGENDS

Figure 1: Bottlenose dolphin (*Tursiops truncatus*). Thoracic cavity. Extensive adhesions (arrow) are seen between the lung and the coastal pleural surfaces (a); lung. Multifocal to coalescing necrotic foci (arrow) are found scattered throughout the parenchyma (b).

Figure 2: Bottlenose dolphin (*T. truncatus*). Lung. Microscopic appearance of the pyogranulomatous lesions, centered by necrotic foci, scattered throughout both lungs' parenchyma. *Splendore-Hoeppli* bodies (so-called “*Splendore-Hoeppli* phenomenon”) are evident within the pulmonary inflammatory lesions. Haematoxylin and eosin (HE) stain, 40X objective, bar = 50 microns (a); lung. Positive histochemical labeling for filamentous bacterial organisms and colonies is seen in a pulmonary tissue smear. Gram stain, 100X objective, bar = 20 microns (b); lung. Positive histochemical labeling for *Actinomyces*-like organisms and colonies is shown in a pulmonary tissue section. Grocott stain, 40X objective, bar = 50 microns (c).

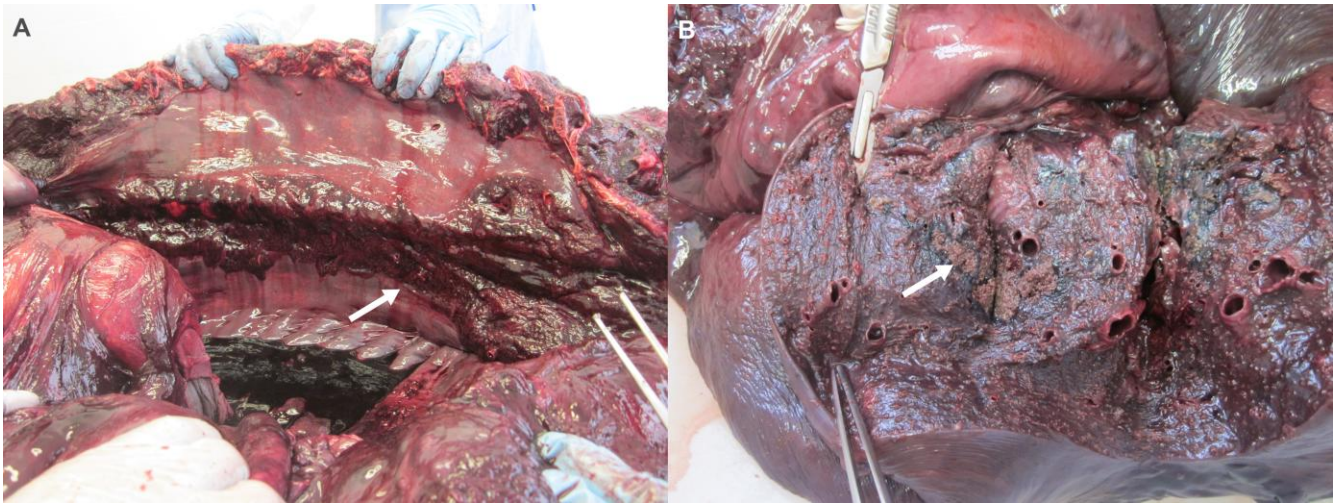


Figure 1

ACCEPTED MANUSCRIPT

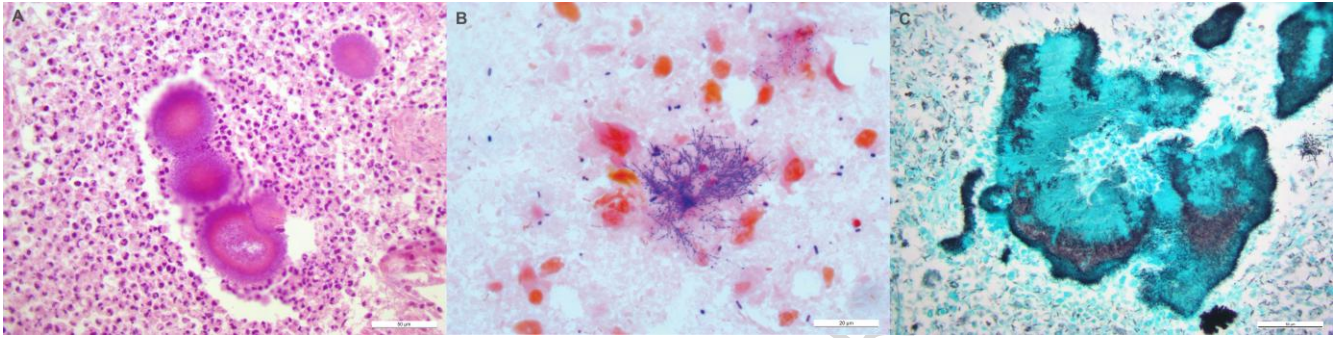


Figure 2