

in vivo 29: 493-496 (2015)

# Laparoscopic Totally Extraperitoneal Inguinal Hernia Repair in the Elderly: A Prospective Control Study\*

SIMONE ZANELLA<sup>1</sup>, ANTONIOS VASSILIADIS<sup>1</sup>, FRANCESCO BUCCELLETTI<sup>2</sup>,  
ENRICO LAURO<sup>1</sup>, FRANCESCO RICCI<sup>1</sup> and FRANCO LUMACHI<sup>3</sup>

<sup>1</sup>General Surgery, S. Maria del Carmine Hospital, Rovereto, Italy;

<sup>2</sup>Department of Emergency, S. Chiara Hospital, Trento, Italy;

<sup>3</sup>Department of Surgery, Oncology and Gastroenterology, University of Padua, School of Medicine, Padova, Italy

**Abstract.** Inguinal hernia (IH) repair can be obtained with both open and laparoscopic techniques, which are usually performed using a transabdominal preperitoneal (TAPP) or a totally extraperitoneal (TEP) approach. The aim of the study was to evaluate whether the results of laparoscopic TEP IH repair in the elderly ( $\geq 65$  years old) are different with respect to results obtained in younger patients. One hundred and four consecutive patients (four women and 100 men, median age of 57 years, range=21-85 years) with unilateral ( $N=21$ , 20.2%) or bilateral ( $N=83$ , 79.8%) IH were prospectively enrolled in the study. Patients were divided into two groups according to their age: group A ( $N=68$ , 65.4%) aged  $<65$  years and group B ( $N=36$ , 34.6%) aged  $\geq 65$  years. The mean operative time was not significantly different between groups ( $48 \pm 20$  vs.  $52 \pm 20$  min,  $p=0.33$ ). One case of increased PaCO<sub>2</sub> was observed in each group ( $p=0.72$ ) and two and one case of pneumoperitoneum ( $p=0.57$ ) in groups A and B, respectively. Two (1.9%) patients (one in each group;  $p=0.55$ ) required TEP conversion. Mild postoperative complications developed in four patients of each group ( $p=0.44$ ). After one-year follow-up, three (2.9%) recurrences occurred (group 1=1, group 2=2,  $p=0.55$ ), both in patients who had undergone direct IH repair. The overall postoperative relative risk of complications related to age was 1.08 (95% confidence interval=0.91-1.27,  $p=0.53$ ). In conclusion, our results suggest that in patients with IH scheduled for TEP repair, age does not represent a contraindication to surgery in terms of complication rate and postoperative results.

Inguinal hernia (IH) repair is one of the most common surgical operations performed worldwide and every year from 100 to 300 patients per 100,000 people undergo this procedure (1). Approximately 90% of IH repairs involve the use of a variety of meshes on an outpatient basis (2). Two standardized laparoscopic techniques of IH repair are available, both performed using mesh prosthesis: (i) transabdominal preperitoneal (TAPP) and (ii) totally extraperitoneal (TEP) repair, first described in the 1990s (3, 4). Laparoscopic IH repair is comparable to open-mesh techniques in terms of overall outcome, but superior in terms of shorter recovery time and reduced risk of wound infection or hematoma formation (5-7). Patients with IH who underwent open Lichtenstein repair under local anesthesia usually experience more postoperative pain than those treated with laparoscopic TEP or TAPP repair (7). TEP represents usually the procedure of choice having several advantages, such as shorter hospital stay and early return to work compared to TAPP and open surgery, respectively (7, 8). However, what the most cost-effective procedure for IH repair is, is still under discussion (8). The aim of the study was to evaluate whether the results of laparoscopic TEP IH repair in the elderly ( $\geq 65$  years old) are different with respect to results obtained in younger patients. We hypothesized that the results of laparoscopic TEP repair are independent of age. Primary end-points were the evaluation of operative time and intraoperative complications, while secondary end-points were the evaluation of postoperative complications and length of hospital stay.

## Patients and Methods

**Study population and definitions.** One-hundred and four consecutive patients with unilateral ( $N=21$ , 20.2%) or bilateral ( $N=83$ , 79.8%) IH were prospectively enrolled in the study. There were four (3.8%) women and 100 (96.2%) men, with an overall median age of 57 years (range 21-85 years). Patients were divided into two groups according to the age: group A ( $N=68$ , 65.4%) aged  $<65$  years and group B ( $N=36$ , 34.6%) aged  $\geq 65$  years. Informed consent was obtained from all participants.

\*Presented at the 1st World Conference on Abdominal Wall Hernia Surgery, Milan (Italy), April 25-29, 2015.

Correspondence to: Dr. Simone Zanella, General Surgery, S. Maria del Carmine Hospital, Corso Verona 4, 38068 Rovereto, Italy. Tel: +39 0464403301, Fax: +39 0464403304, e-mail: simonezanella@apss.tn.it

**Key Words:** Elderly, inguinal hernia, inguinal hernia repair, laparoscopic repair, totally extraperitoneal repair, TEP, TAPP.

Laparoscopic repair was performed under general anesthesia in all patients, by or under the supervision of the same surgeon (A.V.). Operative time was defined as the time from skin incision to skin closure. Pneumoperitoneum requiring another trocar insertion or carbon dioxide elevation pressure during surgery was considered as an intraoperative complication. The length of hospital stay was defined as the total number of nights spent in the hospital after surgery. All patients were followed-up regularly at the Outpatient Clinic for at least one year.

**Surgical technique.** The surgical procedure was similar to that reported by Dehal *et al.* (6) and by Putnis and Berney (9). It was performed by using a standard 3-trocar operative approach. The first skin incision was made below the umbilicus. A channel between the rectus muscle and the posterior rectus sheath was created digitally. The preperitoneal space was insufflated with carbon dioxide and the pressure was maintained between 12 and 15 mm Hg by continuous insufflation. Two more 5-mm ports were inserted under direct vision at the midline between the two previous ports. Dissection of the hernia sac was performed to expose the spermatic cord/round ligament and all hernia orifices. Dissection of the contralateral side was obtained, with no need to place further trocars. After dissection of the inguinal region, the reduction of the IH sac was completed and mesh prostheses (Bard® 3DMax™ or PolySoft® mesh, Davol Inc., Warwick, RI, USA) were inserted to cover all potential hernia orifices. The mesh fixation was obtained using tacks and seal. The patients were transferred to the recovery room, observed for a few hours before returning to the hospital ward and then discharged the same day. Pneumoperitoneum was managed by a peritoneal trocar introduction to remove carbon dioxide.

**Statistical analysis.** Continuous variables are reported as the mean±standard deviation (SD), median (range) or frequency (percentage) distribution. Outcomes were compared using Student's *t*-test, chi-squared ( $\chi^2$ ) test, or Fisher's exact probability test if the frequencies were 5 or less than 5. The relative risk (RR) of complications related to age and its 95% confidence interval (95% CI) were also calculated. The differences were considered significant at a *p*-value of less than 0.05. The software used for analyses was Statistica® (StatSoft, Tulsa, OK, USA).

## Results

The main characteristics of the patient population, mean operative time, type and size of mesh used for the surgical procedure and intra- and postoperative complications for each group are reported in Table I. The mean operative time was not significantly different between groups (48±20 vs. 52±20 min, *p*=0.33). Overall, the length of hospital stay was less than one day in both groups and no patient required overnight admission. Complications occurred in 13 (12.5%) patients. One case of increased PaCO<sub>2</sub> was observed in each group (1.5% vs. 2.8%, *p*=0.72) and two and one case of pneumoperitoneum (2.9% vs. 2.8%, *p*=0.57) in groups A and B, respectively. Two (1.9%) patients required TEP conversion to TAPP (group B) or to open-approach (group A) due to local anatomy resulting in a poor field of vision or to difficult in preparing the pre-peritoneal space, respectively.

Postoperative hematoma developed in two (2.9%) patients (group A), urinary retention in one patient of each group, temporary hematuria in one (2.8%) patient (group B), and prolonged pain requiring analgesics for more than 5-6 days was observed in one and two patients in groups A and B, respectively. After one-year follow-up, three (2.9%) recurrences had occurred (group A=1, group B=2, *p*=0.55), both in patients who had undergone direct IH repair. As shown in Figure 1, the overall postoperative RR of complications related to age was 1.08 (95% CI=0.91-1.27, *p*=0.53).

## Discussion

Inguinal hernia is common, especially in elderly men, accounting for approximately 97% of groin hernias (10). The incidence of IH increases with age, while being overweight or obese represent protective factors against developing IH (11).

The main indications for laparoscopic IH repair are bilateral and recurrent hernias but this approach can also be safely used in the presence of unilateral IH (6). IH repair can also be performed in very elderly patients (*i.e.*, octogenarians), laparoscopically rather than *via* open approaches, using mesh prosthesis (12). TEP and TAPP laparoscopic repair of IH have similar outcomes but usually require longer total operating room time than open repair, such as Lichtenstein repair under local anesthesia (13-15). However, some studies report no difference in the operating time between open repair and TEP, which offers several advantages, especially when a laparoendoscopic single-site technique is chosen (7, 16, 17).

Our results show that the mean operating time was shorter than that reported in other studies and did not differ between age groups (*p*=NS). When laparoscopic TEP repair without mesh fixation is performed, a further shortening of the intervention time is achieved (6). Comparing TAP repair with mesh fixation and that without, a significant decrease in the postoperative complication rate (*e.g.*, urinary retention) and overall costs has been noted (18, 19). The development of pneumoperitoneum is a frequent intraoperative adverse event after a TEP procedure, reported in up to 34% of patients, but can be easily managed by a Veress needle (16). In our series, pneumoperitoneum was observed in only three (2.9%) patients. No influence of age on postoperative pain was observed in patients who underwent IH repair and the improvement of physical and social dimensions of quality of life was also independent of age (20). Several studies reported that both elderly and younger patients experience similar outcomes with respect to postoperative symptoms and satisfaction (21). In any case, even in the elderly, TEP IH repair is associated with a quicker return to normal activities and less chronic pain compared to Lichtenstein hernioplasty (22-24).

Table I. Main preoperative parameters and results (mean±standard deviation).

Parameter	Group A, <65 years	Group B, ≥65 years	p-Value
No. of patients (%)	68 (65.4%)	36 (34.6%)	-
Age (years)	49.5±9.1	74.3±7.7	<0.001
Males/females, n	66/2	34/2	0.61
Weight (kg)	74.2±11.1	77.2±10.2	0.17
Height (cm)	175.7±7.6	173.3±8.6	0.16
Unilateral/bilateral hernia, n	12/56	9/27	0.37
Operative time (min)	48±20	52±20	0.33
3DMax/PolySoft, n	62/6	29/7	0.21
Mesh size (large/medium), n	67/1	34/2	0.54
Complications, n (%)			
Total	7 (10.3%)	6 (16.7%)	0.53
Intraoperative	3 (4.4%)	2 (5.6%)	0.57
Postoperative	4 (5.9%)	4 (11.1%)	0.44
Conversions, n (%)	1 (1.5%)	1 (2.8%)	0.57
Recurrences, n (%)	1 (1.5%)	2 (5.6%)	0.55

In conclusion, laparoscopic repair should be considered a cost-effective procedure and the true total cost for both TEP and TAPP surgery is lower when compared to open IH repair (5, 8). Our results suggest that in patients with IH scheduled for TEP repair, the relative risk related to being elderly is very low (RR=1.08,  $p=0.53$ ) and thus age does not represent a contraindication to surgery in terms of intra- and postoperative complications.

## References

- 1 Kingsnorth AN and LeBlanc KA: Management of abdominal hernias. Third Edition. London, Edward Arnold, pp. 40-47, 2003.
- 2 Rutkow IM: Demographic and socioeconomic aspects of hernia repair in the United States in 2003. *Surg Clin North Am* 83: 1045-1051, 2003.
- 3 Arregui ME, Davis CJ, Yucel O and Nagan RF: Laparoscopic mesh repair of inguinal hernia using a preperitoneal approach: A preliminary report. *Surg Laparosc Endosc* 2: 53-58, 1992.
- 4 McKernan JB and Laws HL: Laparoscopic repair of inguinal hernias using a totally extraperitoneal prosthetic approach. *Surg Endosc* 7: 26-28, 1993.
- 5 Wittenbecher F, Scheller-Kreinsen D, Röttger J and Busse R: Comparison of hospital costs and length of stay associated with open-mesh, totally extraperitoneal inguinal hernia repair and transabdominal preperitoneal inguinal hernia repair: An analysis of observational data using propensity score matching. *Surg Endosc* 27: 1326-1333, 2013.
- 6 Dehal A, Woodward B, Johna S and Yamanishi F: Bilateral laparoscopic totally extraperitoneal repair without mesh fixation. *JLS* 18: 1-7, 2014.
- 7 Dahlstrand U, Sandblom G, Ljungdahl M, Wollert S and Gunnarsson U: TEP under general anesthesia is superior to Lichtenstein under local anesthesia in terms of pain 6 weeks

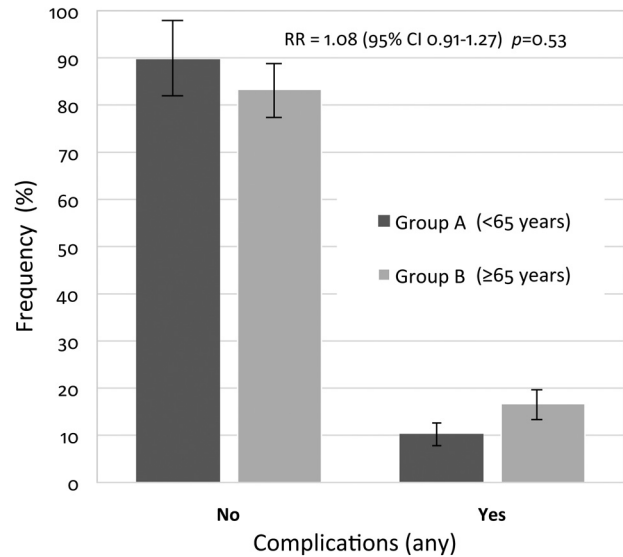


Figure 1. Postoperative complications related to age in patients undergoing inguinal hernia repair.

after surgery: Results from a randomized clinical trial. *Surg Endosc* 27: 3632-3638, 2013.

- 8 Jacobs VR and Morrison JE Jr.: Comparison of institutional costs for laparoscopic preperitoneal inguinal hernia versus open repair and its reimbursement in an ambulatory surgery center. *Surg Laparosc Endosc Percutan Tech* 18: 70-74, 2008.
- 9 Putnis S and Berney CR: Totally extraperitoneal repair of inguinal hernia: techniques and pitfalls of a challenging procedure. *Langenbecks Arch Surg* 397: 1343-1351, 2012.
- 10 Burcharth J, Pedersen M, Bisgaard T, Pedersen C and Rosenberg J: Nationwide prevalence of groin hernia repair. *PLoS One* 8: e54367, 2013.
- 11 de Goede B, Timmermans L, van Kempen BJ, van Rooij FJ, Kazemier G, Lange JF, Hofman A and Jeekel J: Risk factors for inguinal hernia in middle-aged and elderly men: Results from the Rotterdam Study. *Surgery* 157: 540-546, 2015.
- 12 Hope WW, Bools L, Menon A, Scott CM 3rd, Adams A and Hooks WB 3rd: Comparing laparoscopic and open inguinal hernia repair in octogenarians. *Hernia* 17: 719-722, 2013.
- 13 McCormack K, Scott NW, Go PM, Ross S and Grant AM: Laparoscopic techniques versus open techniques for inguinal hernia repair. *Cochrane Database Syst Rev* 1: CD001785, 2003.
- 14 Bansal VK, Misra MC, Babu D, Victor J, Kumar S, Sagar R, Rajeshwari S, Krishna A and Rewari V: A prospective, randomized comparison of long-term outcomes: chronic groin pain and quality of life following totally extraperitoneal (TEP) and transabdominal preperitoneal (TAPP) laparoscopic inguinal hernia repair. *Surg Endosc* 27: 2373-2382, 2013.
- 15 Dhankhar DS, Sharma N, Mishra T, Kaur N, Singh S and Gupta S: Totally extraperitoneal repair under general anesthesia versus Lichtenstein repair under local anesthesia for unilateral inguinal hernia: a prospective randomized controlled trial. *Surg Endosc* 28: 996-1002, 2014.

- 16 Cugura JF, Kirac I, Kulis T, Sremac M, Ledinsky M and Beslin MB: Comparison of single incision laparoscopic totally extraperitoneal and laparoscopic totally extraperitoneal inguinal hernia repair: initial experience. *J Endourol* 26: 63-66, 2012.
- 17 Siddiqui MR, Kovzel M, Brennan SJ, Priest OH, Preston RS and Soon Y: The role of the laparoendoscopic single site totally extraperitoneal approach to inguinal hernia repairs: a review and meta-analysis of the literature. *Can J Surg* 57: 116-126, 2014.
- 18 Tam KW, Liang HH and Chai CY: Outcomes of staple fixation of mesh *versus* nonfixation in laparoscopic total extraperitoneal inguinal repair: a meta-analysis of randomized controlled trials. *World J Surg* 34: 3065-3074, 2010.
- 19 Garg P, Nair S, Shereef M, Thakur JD, Nain N, Menon GR and Ismail M: Mesh fixation compared to nonfixation in total extraperitoneal inguinal hernia repair: a randomized controlled trial in a rural center in India. *Surg Endosc* 25: 3300-3306, 2011.
- 20 Pierides G, Mattila K and Vironen J: Quality of life change in elderly patients undergoing open inguinal hernia repair. *Hernia* 7: 729-736, 2013.
- 21 Sinha S, Srinivas G, Montgomery J and DeFriend D: Outcome of day-case inguinal hernia in elderly patients: How safe is it? *Hernia* 11: 253-625, 2007.
- 22 Langeveld HR, van't Riet M, Weidema WF, Stassen LP, Steyerberg EW, Lange J, Bonjer HJ and Jeekel J: Total extraperitoneal inguinal hernia repair compared with Lichtenstein (the LEVEL-Trial): A randomized controlled trial. *Ann Surg* 251: 819-824, 2010.
- 23 Zhu X, Cao H, Ma Y, Yuan A, Wu X, Miao Y and Guo S: Totally extraperitoneal laparoscopic hernioplasty *versus* open extraperitoneal approach for inguinal hernia repair: a meta-analysis of outcomes of our current knowledge. *Surgeon* 12: 94-105, 2014.
- 24 Bobo Z, Nan W, Qin Q, Tao W, Jianguo L and Xianli H: Meta-analysis of randomized controlled trials comparing Lichtenstein and totally extraperitoneal laparoscopic hernioplasty in treatment of inguinal hernias. *J Surg Res* 192: 409-420, 2014.

*Received April 3, 2015*  
*Revised May 11, 2015*  
*Accepted May 13, 2015*