

Laryngeal Subsite Analysis of Granulomatosis With Polyangiitis (Wegener's)

Natasha J. Minaya, MD¹, Vishwanatha Rao²,
 Matthew R. Naunheim, MD, MBA^{2,3}, and Phillip C. Song, MD^{2,3}

OTO Open
 2021, Vol. 5(3) 1–6
 © The Authors 2021
 Article reuse guidelines:
sagepub.com/journals-permissions
 DOI: 10.1177/2473974X211036394
<http://oto-open.org>


Abstract

Objective. To analyze specific intralaryngeal findings associated with granulomatosis with polyangiitis (GPA).

Study Design. Retrospective chart review.

Setting. Tertiary referral center.

Methods. A retrospective chart review was performed on all patients diagnosed with GPA who were evaluated at the laryngology division of Massachusetts Eye and Ear Infirmary between January 2006 and September 2019.

Results. Forty-four patients (14 male, 30 female) were evaluated for laryngeal pathology. The mean age at onset was 48 years. Nine patients (21%) were identified with only vocal fold disease, 11 (25%) with subglottic disease, and 8 (18%) with disease at the glottis and subglottis (transglottic). The remaining 16 patients (36%) had a normal airway upon examination although they presented with laryngeal symptoms. Patients with glottic disease had statistically significantly lower voice-related quality of life scores than patients with isolated subglottic stenosis.

Conclusions. Although laryngeal manifestations of GPA is often described as a subglottic disease presenting with respiratory symptoms, subsite analysis show that only 25% of patients had subglottic disease alone, with similar rates of glottic disease alone. Laryngeal subsites have different epithelial mucosa, function, and physiology, and understanding the specific sites of involvement will determine symptoms and enable better analysis of the underlying mechanisms of disease. Glottic disease is associated with a reduction in vocal fold motion and voice changes. Subglottic involvement presents more frequently with airway symptoms. Further research is necessary to better define the specific regions of laryngeal involvement in patients diagnosed with GPA.

Keywords

Wegener's granulomatosis, granulomatosis with polyangiitis, laryngeal manifestations, subglottic stenosis.

Received July 9, 2021; accepted July 13, 2021.

Granulomatosis with polyangiitis (GPA), previously referred to as Wegener's granulomatosis, is a systemic necrotizing vasculitis that affects small- and medium-sized blood vessels.¹ Limited forms of GPA predominantly affect the upper and lower respiratory tracts.¹ Laryngeal manifestations in patients diagnosed with GPA are almost invariably described as subglottic disease,² but the larynx is composed of multiple subsites, including the supraglottic, glottic, and subglottic regions.³ These sites have histologic, biomolecular, and physiologic heterogeneity. The supraglottic region is composed of the epiglottis, the arytenoid cartilages with the aryepiglottic folds, the vestibular folds, and the ventricles.³ The glottis is a space located at the level of the vocal folds, which are covered in stratified squamous epithelium without mucus glands, and any disruption in this area will have consequences in voice production.⁴ The transition from this stratified squamous epithelium to the respiratory epithelium is a histologic landmark of the lower border of the glottic region, located 5 to 10 mm below the free edge of the true vocal folds.³ The subglottic region extends from a plane that is approximately 1 cm below the free margin of the true vocal folds to the lower border of the cricoid cartilage³; it is covered with ciliated columnar epithelium, and granulomatous inflammation and scarring result in airway symptoms that can be life-threatening.¹ The histologic

1 Department of Otolaryngology, Vall d'Hebron University Hospital, Barcelona, Spain

2 Department of Otolaryngology, Harvard Medical School, Boston, Massachusetts, USA

3 Department of Otolaryngology, Massachusetts Eye and Ear Infirmary, Boston, Massachusetts, USA

This article was presented as an ePoster at the AAO-HNSF 2020 Virtual Annual Meeting and OTO Experience; September 13–October 25, 2020.

Corresponding Author:

Phillip C. Song, MD, Massachusetts Eye and Ear Infirmary, Boston, MA 02481, USA.

Email: phillip_song@meei.harvard.edu



and physiologic differences reflect the distinct functions of each site: glottis, voice; subglottis, respiration. Understanding the subsites is critical to understanding autoimmune laryngeal diseases from a clinical level of symptom presentation and bio-molecular level based on histology.

The objective of this retrospective review is to document the specific subsites of involvement within the larynx and correlate them with presenting voice and airway symptoms.

Methods

A retrospective chart review was performed of all patients aged ≥ 18 years with a diagnosis of GPA who attended the laryngology clinics at Massachusetts Eye and Ear Infirmary between January 2006 and September 2019. Clinical diagnosis of GPA was previously made by the referring rheumatologist and/or nephrologist. Patients with incomplete medical records without a documented diagnostic laryngoscopy were excluded. Institutional board review approval from the Mass General Brigham Human Research Committee was obtained in advance.

Clinical diagnosis was retrieved through electronic medical record extraction via *ICD-9* and *ICD-10 CM* codes (*International Classification of Diseases, Ninth Revision and Tenth Revision, Clinical Modification*). Data were extracted regarding patient demographics, age of onset, anatomic site of involvement, and perinuclear antineutrophil cytoplasmic antibodies (p-ANCA) status.

Procedures were retrieved per the American Medical Association's *CPT* codes (*Current Procedural Terminology*). Laryngoscopic video examinations were reviewed by the senior author, and laryngeal subsite analysis was performed. GPA was found to be involved in the laryngeal subsites if there was vocal fold motion impairment, erythema, hypervascularity, stenosis, granulation tissue, edema, ulcerations, and/or fibrosis. Laryngoscopy findings were then broadly divided into 3 categories: glottic (including the infraglottic region), subglottic, or both (transglottic). No supraglottic involvement was found on our analysis.

Quality of life scores, specifically voice-related quality of life (VRQL) scores, were reviewed.

Statistical Analysis

We conducted a Fisher's exact test to determine whether there was an association between site of disease involvement and presenting symptoms. $P < .05$ was considered statistically significant.

Furthermore, patients with VRQL data were split into 4 discrete categories based on site of disease involvement: normal, subglottic, glottic, or transglottic (both). Statistical analysis of the VRQL scores was conducted with the Kruskal-Wallis H test to compare the VRQL total score distributions by disease group. $P < .05$ was considered statistically significant.

Results

Eighty-one patients were identified from the initial electronic medical record review, and 44 met inclusion criteria for the study. Of these, 30 were women and 14 were men. The average age at onset was 48 years. All patients underwent

endoscopic evaluation of the larynx. We identified 11 patients (25%) with subglottic disease (**Figure 1A**), 9 (21%) with glottic disease (**Figure 1B** and **1C**), and 8 (18%) with transglottic disease (**Figure 1D**); the remaining 16 patients (36%) had a normal airway upon examination (**Table 1**). The most common presenting laryngeal symptoms in our group were hoarseness and airway obstruction. ANCA test results were available for 40 patients. Of these, 24 were p-ANCA positive, 12 were p-ANCA negative, and 4 had a borderline result (**Table 2**). All of the patients had a confirmatory diagnosis of GPA by a rheumatologist or nephrologist.

Fisher's exact test showed no statistical relationship between the site of disease involvement and the presenting symptoms ($P = .114$). The Kruskal-Wallis H test showed a statistically significant difference among the VRQL total score distributions based on site of disease involvement ($H[3] = 9.359$, $P = .0249$, $\alpha = 0.05$; **Table 3**). The Kruskal-Wallis H test results for VRQL total score are summarized in **Table 3**. The box plot for VRQL total score by site of involvement is shown on **Figure 2**. Post hoc Dunn pairwise comparisons with Bonferroni-adjusted P values (**Table 4**) demonstrated a significant difference between the normal (mean, 88.000) and glottic (mean, 52.125) VRQL distributions ($z = 2.9191$, $P = .0211$, $\alpha = 0.05$). No other significant differences were observed.

Discussion

This study analyzed specific regions of the larynx in patients diagnosed with GPA and revealed that vocal fold disease alone is as common as subglottic disease, with a presenting diagnosis of hoarseness being as common as airway obstruction. Prior studies are limited to case reports or smaller series without detailed subsite assessment of the larynx. The majority of articles describe subglottic inflammation as the primary and often only laryngeal manifestation of disease. Hoarseness is not a measured or recorded symptom in the Birmingham Vasculitis Activity Score for Wegener's granulomatosis,⁵ and laryngeal involvement other than subglottic inflammation is not recorded in most randomized clinical trials.⁶ In this series, just 25% of referrals for laryngeal examination had subglottic inflammation alone, while 39% of patients had glottic involvement.

Evaluating the larynx as a homogenous organ limits the understanding of autoimmune diseases of the aerodigestive tract. The mucosal lining, tissue composition, and function of the glottis and subglottis are distinct. Head and neck manifestations are the most common symptoms of presentation in GPA, including nasal, laryngeal, and ocular involvement; however, the site-specific mechanisms of disease are not well elucidated.⁶ GPA manifestations are based on the autoantigen-mediated inflammation of peroxidase 3 or myeloperoxidase with histopathologic findings of necrotizing vasculitis and granulomatous inflammation. Many systemic disorders have a spectrum of laryngeal symptoms that mimic those of GPA, such as cough, stridor, hoarseness, or airway compromise. IgG4-related disease has a strong tendency to cause lesions involving pharyngeal or laryngeal subsites and

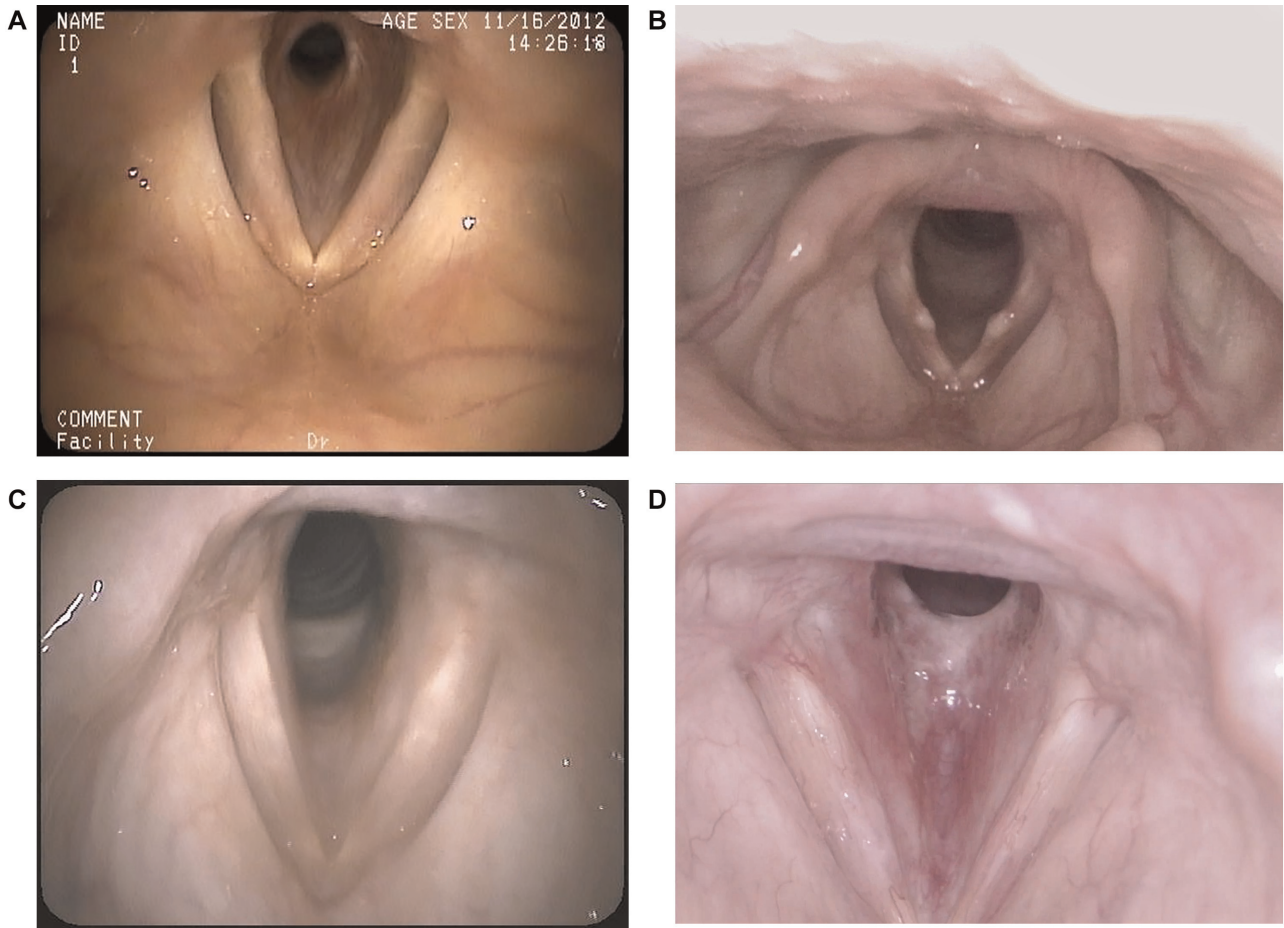


Figure 1. (A) Isolated subglottic disease. This is the classically described subglottic stenosis that begins below the edges of the thyroid cartilage, involving the space occupied by the cricoid ring. Vocal folds are mobile, and symptoms are primarily shortness of breath. (B) Isolated glottic disease. (C) Infraglottic fibrosis with normal subglottis, including airway and voice symptoms secondary to fibrosis and swelling. (D) Involvement of the vocal folds and subglottis with fibrosis, narrowing, and reduced vocal fold motion. Symptoms include airway and voice symptoms.

can be misdiagnosed as a granulomatous condition such as GPA.⁷ Sarcoidosis is a granulomatous disease that can affect the larynx as a manifestation of systemic disease or as isolated laryngeal involvement; classically, laryngeal involvement affects the supraglottis and less commonly the subglottis and true vocal folds.^{8,9} Amyloidosis is a disorder characterized by the deposition of insoluble fibrillar proteins, and laryngeal deposition of amyloid (mostly in the true and vocal folds and the ventricles) is the most common involvement within the head and neck.^{10,11} Other conditions can affect the larynx and mimic symptoms of GPA, such as pemphigus, tuberculosis, idiopathic subglottic stenosis, trauma (eg, endotracheal intubation), and radiation.

Comparing other diseases of the subglottis raises intriguing biomolecular questions. For instance, idiopathic subglottic stenosis is a laryngeal disease characterized by formation of an intraluminal scar centered at the level of the cricoid with pronounced subepithelial fibrosis and collagen remodeling. These histologic features are dissimilar to GPA subglottic stenosis, which is marked with significant inflammation and leukocytosis. However, the etiology of both diseases may be based on a

cell-mediated autoimmune mechanism, and researchers have found alterations in T-cell response in both conditions.¹²

Epithelial analysis of the larynx has been partially characterized. For instance, the vocal folds express cytokeratin 13 in the absence of cytokeratin 8.¹³ In contrast, cytokeratin 8 is expressed in the ciliated epithelium of the larynx in the laryngeal ventricle, supraglottis, and subglottis.¹³ Cytokeratin 8 and 13 staining is mutually exclusive and thus clearly delineates the region of stratified squamous epithelium in the true vocal folds and ciliated epithelium.¹³⁻¹⁵ The distribution pattern of these molecular markers at different laryngeal subsites needs to be better elucidated and may provide clues to the pathophysiology of diseases such as GPA.

This study has multiple limitations inherent in retrospective design and single-institution analysis. The primary drawbacks are selection bias based on referral to a tertiary care academic practice as well as the high percentage of excluded patients secondary to incomplete records. Although this is the largest assessment of laryngeal findings in GPA, there is a relative rarity of laryngeal consultation given the high percentage

Table 1. Demographic Characteristics and Laryngoscopic Examination Findings.

Age of onset, y	Sex	Presenting symptom	ANCA status	Site of involvement	Laryngoscopy findings
52	Female	Airway obstruction	Borderline	Glottic	Bilateral vocal fold immobility
29	Female	Airway obstruction	Borderline	Transglottic	Bilateral vocal fold immobility; infra- and subglottic stenosis
25	Female	Airway obstruction	—	Transglottic	Vocal fold granuloma; subglottic stenosis, edema, and erythema
26	Female	Airway obstruction	Positive	Subglottic	Subglottic stenosis
18	Male	Epistaxis	Positive	Subglottic	Subglottic stenosis
65	Male	Nasal congestion	Positive	Subglottic	Subglottic stenosis
48	Male	Hoarseness	Positive	Subglottic	Subglottic stenosis
—	Male	Hoarseness	Negative	Glottic	Infraglottic edema
30	Female	Hoarseness	Positive	Glottic	Bilateral vocal fold edema and erythema
19	Female	Epistaxis	Positive	Subglottic	Subglottic stenosis
46	Female	Epistaxis	Negative	Transglottic	Severe posterior pharyngeal wall and bilateral true and false vocal fold crusting, erythema, and edema that extend to the subglottis
64	Female	Nasal congestion	Positive	Transglottic	Glottic erythema; subglottic stenosis and erythema
52	Female	Arthralgia	—	Glottic	Glottic and infraglottic erythema
21	Female	Airway obstruction	Negative	Subglottic	Subglottic stenosis
75	Male	Epistaxis	Positive	Subglottic	Subglottic edema
57	Female	Hoarseness	—	Transglottic	Bilateral vocal fold edema, infraglottic edema, subglottic edema and stenosis
23	Male	Epistaxis	Negative	Subglottic	Subglottic stenosis
70	Male	Hoarseness	Positive	Glottic	Glottic and infraglottic edema
63	Female	Airway obstruction	—	Subglottic	Subglottic stenosis
40	Female	Epistaxis	Negative	Subglottic	Subglottic stenosis
57	Female	Nasal congestion	Negative	Glottic	Infraglottic stenosis, edema, and erythema
43	Male	Hoarseness	Positive	Glottic	Vocal fold hypomobility; glottic and infraglottic stenosis
48	Male	Airway obstruction	Positive	Glottic	Vocal fold hypomobility; glottic and infraglottic stenosis
19	Male	Airway obstruction	Positive	Transglottic	Bilateral vocal fold hypomobility; glottic, infra-, and subglottic stenosis
30	Female	Epistaxis	Negative	Transglottic	Infra- and subglottic stenosis
48	Female	Airway obstruction	Negative	Transglottic	Glottic, infra-, and subglottic stenosis
—	Female	Nasal congestion	Negative	Subglottic	Subglottic stenosis
55	Female	Hoarseness	Borderline	Glottic	Vocal fold erythema and edema

Abbreviation: p-ANCA, perinuclear antineutrophil cytoplasmic antibodies.

Table 2. Site of Involvement and ANCA Test Results.

	Normal airway (n = 16)	Glottic (n = 9)	Subglottic (n = 11)	Transglottic (n = 8)
p-ANCA				
+	13	4	6	1
-	3	2	4	3
Borderline	0	2	0	2

Abbreviation: p-ANCA, perinuclear antineutrophil cytoplasmic antibodies.

Table 3. Kruskal-Wallis Test for Voice-Related Quality of Life Score.^a

Site of involvement	No.	Rank sum
Normal	5	79
Transglottic	7	64
Subglottic	4	50
Glottic	4	17

^aH(3) = 9.359, P = .0249.

Table 4. Post Hoc Dunn's Test With Bonferroni-Adjusted P Values.

	Normal	Transglottic	Subglottic
Transglottic	1.9276 (.1512)		
Subglottic	0.8340 (.7420)	-0.9080 (.7002)	
Glottic	2.9191 (.0211)	1.3235 (.4427)	1.9781 (.1354)

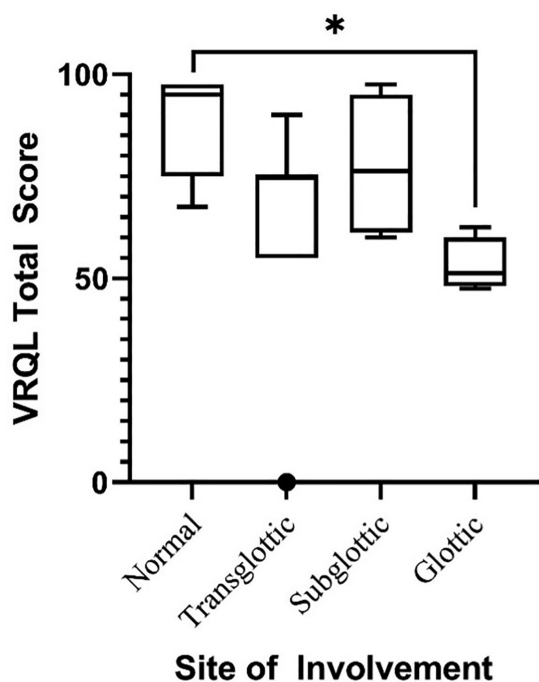


Figure 2. Box plot for voice-related quality of life (VRQL) total score by site of involvement.

of head and neck findings. This may be related to limited recognition that hoarseness can be a manifestation of GPA.

Conclusion

GPA is widely recognized as a subglottic disease but can involve multiple subsites within the larynx and manifest as different symptoms, including hoarseness. Glottic disease is associated with a reduction in vocal fold motion and voice changes, while subglottic involvement presents more frequently with airway symptoms. Patients with glottic disease had significantly lower VRQL scores than patients with subglottic stenosis. Further research with larger samples is necessary to better define voice quality changes in patients diagnosed with GPA.

Author Contributions

Natasha J. Minaya, substantial contributions to conception and design, acquisition of data, and analysis and interpretation of data; drafting the article as well as revising it critically for important intellectual content; final approval of the version to be published and agreed to be accountable for all aspects of the work in ensuring that questions related to the accuracy or integrity of any part of the work are appropriately investigated and resolved; Vishwanatha Rao,

substantial contributions to conception and design, acquisition of data, and analysis and interpretation of data; drafting the article as well as revising it critically for important intellectual content; final approval of the version to be published and agreed to be accountable for all aspects of the work in ensuring that questions related to the accuracy or integrity of any part of the work are appropriately investigated and resolved; **Matthew R. Naunheim**, substantial contributions to acquisition of data; final approval of the version to be published; agreed to be accountable for all aspects of the work in ensuring that questions related to the accuracy or integrity of any part of the work are appropriately investigated and resolved; **Phillip C. Song**, substantial contributions to conception and design, acquisition of data, and analysis and interpretation of data; drafting the article as well as revising it critically for important intellectual content; final approval of the version to be published and agreed to be accountable for all aspects of the work in ensuring that questions related to the accuracy or integrity of any part of the work are appropriately investigated and resolved.

Disclosures

Competing interests: None.

Sponsorships: None.

Funding source: None.

References

1. Comarmond C, Cacoub P. Granulomatosis with polyangiitis (Wegener): clinical aspects and treatment. *Autoimmun Rev*. 2014;13:1121-1125.
2. Langford CA, Sneller MC, Hallahan CW, et al. Clinical features and therapeutic management of subglottic stenosis in patients with Wegener's granulomatosis. *Arthritis Rheum*. 1996;39:1754-1760.
3. Thurnher D, Moukarbel RV, Novak CB, et al. The glottis and subglottis: an otolaryngologist's perspective. *Thorac Surg Clin*. 2007;17(4):549-560.
4. Noordzi JP, Ossoff RH. Anatomy and physiology of the larynx. *Otolaryngol Clin N Am*. 2006;39:1-10.
5. Mahr AD, Neogi T, Lavalley MP, et al; Wegener's Granulomatosis Etanercept Trial Research Group. Assessment of the item selection and weighting in the Birmingham vasculitis activity score for Wegener's granulomatosis. *Arthritis Rheum*. 2008;59(6):884-891.
6. Miloslavsky EM, Lu N, Unizony S, et al. Myeloperoxidase-antineutrophil cytoplasmic antibody (ANCA)-positive and ANCA-negative patients with granulomatosis with polyangiitis (Wegener's): distinct patient subsets. *Arthritis Rheumatol*. 2016;68(12):2945-2952.
7. Reder L, Della-Torre E, Stone JH, et al. Clinical manifestations of IgG4-related disease in the pharynx: case series and review of the literature. *Ann Otol Rhinol Laryngol*. 2015;124(3):173-178.
8. McLaughlin RB, Spiegel JR, Selber J, et al. Laryngeal sarcoidosis presenting as an isolated submucosal vocal fold mass. *J Voice*. 1999;13:240-245.
9. Dean CM, Sataloff RT, Hawkshaw MJ, et al. Laryngeal sarcoidosis. *J Voice*. 2002;16:283-288.
10. Pribitkin E, Friedman O, O'Hara B, et al. Amyloidosis of the upper aerodigestive tract. *Laryngoscope*. 2003;113(12):2095-2101.
11. Dedo HH, Izdebski K. Laryngeal amyloidosis in 10 patients. *Laryngoscope*. 2004;114(10):1742-1746.
12. Gelbard A, Katsantonis NG, Mizuta M, et al. Idiopathic subglottic stenosis is associated with activation of the inflammatory IL-17A/IL-23 axis. *Laryngoscope*. 2016;126(11):E356-E361.
13. Dowdall JR, Sadow PM, Hartnick C, et al. Identification of distinct layers within the stratified squamous epithelium of the adult human true vocal fold. *Laryngoscope*. 2015;125(9):E313-E319.
14. Flint PW, Cummings CW. *Otolaryngology: Head and Neck Surgery*. Mosby Elsevier; 2010.
15. Janfaza P Jr, Nadol JB, Galla RJ, Fabian RL, Montgomery WW. *Surgical Anatomy of the Head and Neck*. Harvard University Press.