


# MRI Characteristics of Pediatric Renal Tumors: A SIOP-RTSG Radiology Panel Delphi Study

Justine N. van der Beek, MD,<sup>1,2\*</sup>  Tom A. Watson, MBChB,<sup>3</sup>

Rutger A.J. Nievelstein, MD, PhD,<sup>1,2</sup> Hervé J. Brisse, MD, PhD,<sup>4</sup> Carlo Morosi, MD,<sup>5</sup>

Henrique M. Lederman, MD, PhD,<sup>6</sup> Ana Coma, MD,<sup>7</sup> Maria M. Gavra, MD, PhD,<sup>8</sup>

Kristina Vult von Steyern, MD, PhD,<sup>9</sup> Karoly Lakatos, MD,<sup>10</sup> Luc Breysem, MD,<sup>11</sup>

Edit Varga, MD, PhD,<sup>12</sup> Hubert Ducou Le Pointe, MD, PhD,<sup>13</sup> Maarten H. Lequin, MD, PhD,<sup>1,2</sup>

Jürgen F. Schäfer, MD, PhD,<sup>14</sup> Hans-Joachim Mentzel, MD,<sup>15</sup> Andreas M. Hötker, MD,<sup>16</sup>

Giuseppina Calareso, MD,<sup>17</sup> Sophie Swinson, MBBS,<sup>18</sup> Martin Kyncl, MD, PhD,<sup>19</sup>

Claudio Granata, MD,<sup>20</sup> Michael Aertsen, MD,<sup>11</sup> Pier Luigi Di Paolo, MD, PhD,<sup>21</sup>

Ronald R. de Krijger, MD, PhD,<sup>2,22</sup> Norbert Graf, MD,<sup>23</sup> Øystein E. Olsen, MD, PhD,<sup>3</sup>

Jens-Peter Schenk, MD,<sup>24</sup> Marry M. van den Heuvel-Eibrink, MD, PhD,<sup>2</sup> and

Annemieke S. Littooij, MD, PhD<sup>1,2</sup>

**Background:** The SIOP-Renal Tumor Study Group (RTSG) does not advocate invasive procedures to determine histology before the start of therapy. This may induce misdiagnosis-based treatment initiation, but only for a relatively small percentage of approximately 10% of non-Wilms tumors (non-WTs). MRI could be useful for reducing misdiagnosis, but there is no global consensus on differentiating characteristics.

**Purpose:** To identify MRI characteristics that may be used for discrimination of newly diagnosed pediatric renal tumors.

**Study Type:** Consensus process using a Delphi method.

**Population:** Not applicable.

View this article online at [wileyonlinelibrary.com](http://wileyonlinelibrary.com). DOI: 10.1002/jmri.27878

Received Jun 17, 2021, Accepted for publication Jul 28, 2021.

\*Address reprint requests to: J.N.B., UMC Utrecht Heidelberglaan 100 3584 CX, Utrecht, The Netherlands. E-mail: [j.n.vanderbeek-6@umcutrecht.nl](mailto:j.n.vanderbeek-6@umcutrecht.nl)

From the <sup>1</sup>Department of Radiology and Nuclear Medicine, University Medical Center Utrecht/Wilhelmina Children's Hospital, Utrecht University, Utrecht, The Netherlands; <sup>2</sup>Princess Máxima Center for Pediatric Oncology, Utrecht, The Netherlands; <sup>3</sup>Department of Paediatric Radiology, Great Ormond Street Hospital NHS Foundation Trust, London, UK; <sup>4</sup>Imaging Department, Institut Curie, Paris, France; <sup>5</sup>Department of Radiology, Fondazione IRCCS Istituto Nazionale dei Tumori, Milan, Italy; <sup>6</sup>Department of Diagnostic Imaging, Escola Paulista de Medicina, UNIFESP, São Paulo, Brazil; <sup>7</sup>Department of Pediatric Radiology, Hospital Vall d'Hebron, Barcelona, Spain; <sup>8</sup>Department of Pediatric Radiology and Nuclear Medicine, 'Aghia Sophia' Children's Hospital, Athens, Greece; <sup>9</sup>Center for Medical Imaging and Physiology, Skåne University Hospital, Lund University, Lund, Sweden; <sup>10</sup>Department of Radiology, St. Anna Children's Hospital, University Clinic of Pediatrics, Medical University of Vienna, Vienna, Austria; <sup>11</sup>Department of Radiology, University Hospitals Leuven, Leuven, Belgium; <sup>12</sup>Department of Pediatrics, Semmelweis University, Budapest, Hungary; <sup>13</sup>Department of Pediatric Imaging, Hôpital d'Enfants Armand-Trousseau APHP, Paris, France; <sup>14</sup>Division of Pediatric Radiology, Department of Radiology, University Hospital Tübingen, Tübingen, Germany; <sup>15</sup>Section of Pediatric Radiology, Institute of Diagnostic and Interventional Radiology, University Hospital Jena, Jena, Germany; <sup>16</sup>Institute of Diagnostic and Interventional Radiology, University Hospital Zurich, Zurich, Switzerland; <sup>17</sup>Radiology Unit, Fondazione IRCCS Istituto Nazionale dei Tumori, Milan, Italy; <sup>18</sup>Department of Paediatric Radiology, Leeds Teaching Hospitals, Leeds, UK; <sup>19</sup>Department of Radiology, Second Faculty of Medicine, Charles University and University Hospital Motol, Prague, Czech Republic; <sup>20</sup>Department of Paediatric Radiology, Institute for Maternal and Child Health – IRCCS “Burlo Garofolo”, Trieste, Italy; <sup>21</sup>Department of Radiology, Bambino Gesù Children's Hospital, Rome, Italy; <sup>22</sup>Department of Pathology, University Medical Center Utrecht, Utrecht, The Netherlands; <sup>23</sup>Department of Pediatric Oncology & Hematology, Saarland University Medical Center and Saarland University Faculty of Medicine, Homburg, Germany; and <sup>24</sup>Clinic of Diagnostic and Interventional Radiology, Division of Pediatric Radiology, Heidelberg University Hospital, Heidelberg, Germany

Additional supporting information may be found in the online version of this article

This is an open access article under the terms of the Creative Commons Attribution-NonCommercial-NoDerivs License, which permits use and distribution in any medium, provided the original work is properly cited, the use is non-commercial and no modifications or adaptations are made.

**Field Strength/Sequence:** Abdominal MRI including T1- and T2-weighted imaging, contrast-enhanced MRI, and diffusion-weighted imaging at 1.5 or 3 T.

**Assessment:** Twenty-three radiologists from the SIOP-RTSG radiology panel with  $\geq 5$  years of experience in MRI of pediatric renal tumors and/or who had assessed  $\geq 50$  MRI scans of pediatric renal tumors in the past 5 years identified potentially discriminatory characteristics in the first questionnaire. These characteristics were scored in the subsequent second round, consisting of 5-point Likert scales, ranking- and multiple choice questions.

**Statistical Tests:** The cut-off value for consensus and agreement among the majority was  $\geq 75\%$  and  $\geq 60\%$ , respectively, with a median of  $\geq 4$  on the Likert scale.

**Results:** Consensus on specific characteristics mainly concerned the discrimination between WTs and non-WTs, and WTs and nephrogenic rest(s) (NR)/nephroblastomatosis. The presence of bilateral lesions (75.0%) and NR/nephroblastomatosis (65.0%) were MRI characteristics indicated as specific for the diagnosis of a WT, and 91.3% of the participants agreed that MRI is useful to distinguish NR/nephroblastomatosis from WT. Furthermore, all participants agreed that age influenced their prediction in the discrimination of pediatric renal tumors.

**Data Conclusion:** Although the discrimination of pediatric renal tumors based on MRI remains challenging, this study identified some specific characteristics for tumor subtypes, based on the shared opinion of experts. These results may guide future validation studies and innovative efforts.

Level of Evidence: 3

Technical Efficacy Stage: 3

J. MAGN. RESON. IMAGING 2022;55:543-552.

## Introduction

Renal tumors account for 6%–7% of all pediatric cancers.<sup>1</sup> Wilms tumor (WT) is the most frequently occurring malignant renal tumor in children, accounting for over 90% of pediatric renal tumors.<sup>2</sup> Other, non-WT subtypes are more rare, with renal cell carcinoma (RCC) representing 6%–7% of pediatric renal tumors, and an even lower frequency of other tumors such as rhabdoid tumor of the kidney (RTK) and clear cell sarcoma of the kidney (CCSK).<sup>2</sup> Furthermore, remnants of persistent embryonal renal tissue (nephrogenic rest(s) (NR)/nephroblastomatosis) often occur in conjunction with WT.<sup>3,4</sup>

Each of these pediatric renal tumors requires a different treatment approach. The standard of the Children's Oncology Group (COG in North-America) Renal Tumor Committee is to pursue upfront surgery, followed by postoperative chemotherapy based on histopathological classification.<sup>5</sup> In contrast, the Renal Tumor Study Group of the International Society of Pediatric Oncology (SIOP-RTSG) argues in favor of preoperative chemotherapy followed by tumor nephrectomy, and does not advocate invasive procedures to determine histology before the start of therapy.<sup>6</sup> Exceptions are made in selective cases suspected to be a non-WT, however the high incidence of WT for most ages limits the number of biopsies.<sup>5,6</sup> Both treatment approaches have been shown to result in equal survival rates.<sup>7</sup> Nevertheless, imaging appears to be a fundamental part of the diagnostic and preoperative assessment, especially to identify specific cases that might benefit from, for instance, preoperative histological confirmation or upfront surgery, before starting cytotoxic treatment.<sup>3,8</sup>

Diagnostic assessment and monitoring of oncological treatment response in children with renal tumors is mainly performed using cross-sectional imaging.<sup>3</sup> In recent years, MRI has become the preferred modality for imaging childhood abdominal tumors.<sup>3</sup> In addition, MRI offers functional

imaging tools such as diffusion weighted imaging (DWI) which has been shown to be of use for assessing pediatric renal tumors.<sup>8-10</sup>

Even though MRI is currently the preferred modality for diagnostic and response assessment of pediatric renal tumors, there is no global consensus on which imaging findings could differentiate between WTs and non-WTs.<sup>3</sup> With increasing importance of consistency in health care practice, the Delphi technique is a frequently used method when gaps of knowledge are subject to expert opinion.<sup>11</sup> MRI characteristics reaching consensus among experts, as well as the identification of other imaging findings, may guide future retrospective and prospective studies.

Thus the aim of this study, initiated by the SIOP-RTSG radiology panel, was to identify MRI characteristics that may be taken into consideration for discriminating pediatric renal tumor subtypes using a Delphi approach.

## Materials and Methods

### Study Design

The institutional ethical board waived the need for ethical approval for this study, because it was a consensus paper without research on patients, nor did it compromise the position of the participating experts. All participants gave informed consent to participate in the study, before completing the first questionnaire.

A core group with expertise in the radiological, clinical, and pathological fields of pediatric renal tumors (JNB, 5 years of experience; TAW, 7 years of experience; RAJN, 7 years of experience; RRK, 22 years of experience; NG, 32 years of experience; ØEO, 18 years of experience; JPS, 18 years of experience; MMHE, 27 years of experience; ASL, 8 years of experience) was responsible for the study design and the selection of topics to be included in the questionnaire. It was decided which tumors were most difficult and important to distinguish from WTs based on experience in these different fields of expertise and based on previous literature. Through discussion within the core group, the set of renal tumors was

systematically formulated, focusing on the most relevant topics for everyday clinical practice. A subset of the core group (JNB, 5 years of experience; TAW, 7 years of experience; RAJN, 7 years of experience; RRK, 22 years of experience; NG, 32 years of experience; MMHE, 27 years of experience) formulated the questions, whereas three members (ØEO, 18 years of experience; JPS, 18 years of experience; ASL, 8 years of experience) were included as participants.

The first round of the Delphi study started in June 2020, and the process was completed in October 2020 after two rounds. Questionnaires were built online and sent to the participants via e-mail using a secure URL-link. Each participant was assigned a study ID, secured by the lead investigator to ensure blinded analysis of the results. For both questionnaires, a pilot among two radiologists (members of the core group, nonparticipants: TAW, 7 years of experience; RAJN, 7 years of experience;) was conducted to ensure clarity and efficacy.

### Selection of the Study Participants

Members of the SIOP-RTSG radiology panel and radiologists involved in the central radiology review of the SIOP-RTSG 2016 UMBRELLA protocol were identified as potential experts in the field of pediatric oncologic radiology. They received an invitation letter accompanied by an information sheet which was visualized in a PowerPoint presentation, including a request to introduce other pediatric radiologists as potential participants through a snowballing technique (Fig. 1).<sup>12</sup> We aimed for at least 20 experts agreeing to participate and complete the study, in which the anticipated rate for acceptance of the invitation was 60%. Participants needed to have  $\geq 5$  years of experience in MRI of pediatric renal tumors and/or have

assessed  $\geq 50$  MRI scans of pediatric renal tumors in the past 5 years. Particular care was taken to ensure that various countries within the SIOP-RTSG were represented (Fig. S1). In order to increase the participation rate after acceptance of the invitation, reminder emails were sent before the predefined deadlines, which were postponed in exceptional cases.

### First Round of the Delphi Study

The first round of the Delphi study consisted of a combination of open-ended questions, in some cases directed by preceding closed-ended questions. These questions focused on the potential differentiating value of MRI and DWI for WT compared with non-WT and NR/nephroblastomatosis, and also separately for neuroblastoma, congenital mesoblastic nephroma (CMN), RTK, CCSK, RCC, and the differentiation between cystic nephroma (CN), cystic partially differentiated nephroblastoma (CPDN), and cystic WT. The participants were asked for their opinion about the distinguishing value of MRI in the concerning renal tumors and to list useful discriminating characteristics.

### Second Round of the Delphi Study

The second round of the Delphi study consisted of closed-ended questions with characteristics and statements, entirely based on answers given in the first round. There were 5-point Likert scales ranging from 1 (definitely not specific/strongly disagree) to 5 (definitely specific/strongly agree), ranking (from least to most useful) and multiple-choice questions.

### Data Analysis and Consensus Evaluation

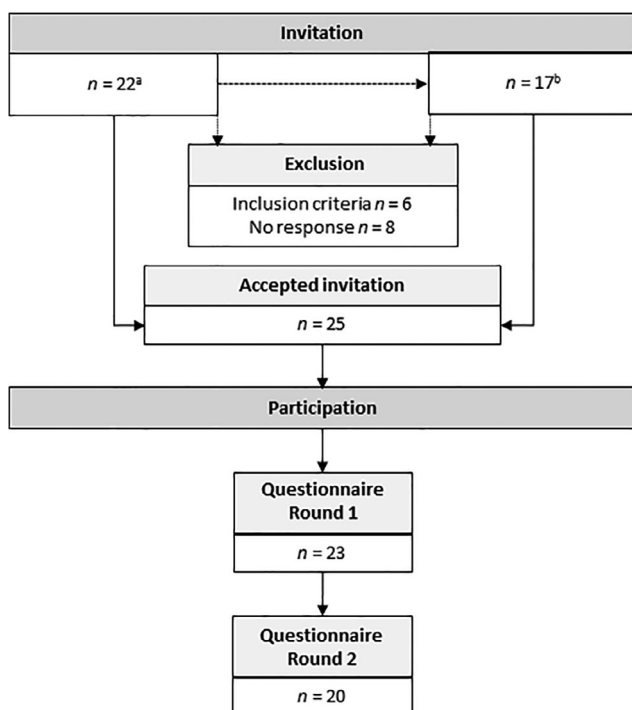
Analysis of the responses of the participants was prospectively performed by the lead investigator (JNB, 5 years of experience) together with two independent pediatric radiologists (TAW, 7 years of experience; RAJN, 7 years of experience). Two other members of the core group (RRK, 22 years of experience; MMHE, 27 years of experience), specialized in different fields of pediatric renal tumors, ensured quality of the analysis. In the first round, a cut-off value of  $\geq 75\%$  was used to consider consensus. A secondary cut-off value of  $\geq 60\%$  was used to consider agreement among the majority of the participants. The level of agreement reached, and the type of answers given in the first questionnaire defined the approach for the type of closed-ended questions in the second round. All imaging characteristics, except the ones that were only mentioned once and/or were not notable, were fed back to participants (Tables S1A and S1B).

In the second round, the same cut-off values were used. Furthermore, for 5-point Likert scales, consensus or an agreement among the majority was defined as a median of  $\geq 4$  with  $\geq 75\%$  or  $\geq 60\%$  answering 4 or 5, respectively.<sup>13</sup> Results were analyzed only among participants who felt competent to answer the concerning questions. Finally, missing answers for any reason were regarded as “nonparticipation.”

## Results

### Participants

A total of 39 radiologists were invited, of whom 25 (64.1%) accepted the invitation. Eight radiologists did not respond to the invitation, whereas six radiologists revealed they did not



**FIGURE 1:** Number of participants in all stages of the study. <sup>a</sup>Pediatric radiologists identified through the SIOP-RTSG Radiology Panel network; <sup>b</sup>Pediatric radiologists initiated by colleagues as experts in the field of pediatric oncologic radiology as potential participants.

meet the inclusion criteria. The participating experts were geographically distributed across 14 countries (Fig. S1). The first round was completed by 23/25 (92.0%) participants and the second round by 20/23 (87.0%) participants (Fig. 1). The median number of years of experience in MRI of pediatric renal tumors was 10 years (range 5–20 years), with a median of 60 (range 20–600) MRI scans of pediatric renal tumors the past 5 years. In the SIOP-RTSG 2016 UMBRELLA protocol, STIR or T2-weighted imaging with fat suppression and T2-weighted and T1-weighted imaging, both nonfat suppressed, are mandatory imaging protocols, whereas DWI and contrast-enhanced MRI are recommended (Table S2). All participants (23/23, 100%) had DWI included in their standard MRI protocol, while this was true for 19/23 (82.6%) concerning contrast-enhanced MRI.

### **Wilms Tumor and Non-Wilms Tumor**

The presence of NR/nephroblastomatosis and a bilateral tumor were MRI characteristics indicated as specific for the diagnosis of a WT (Table 1). The majority (16/23, 69.6%) agreed that contrast-enhanced MRI was of added value to noncontrast MRI in the discrimination of WTs and non-WTs. Furthermore, all participants (20/20, 100%) agreed calcifications were often difficult to detect on MRI. A majority of the participants (15/23, 65.2%) agreed that ultrasound (US) examination is of added value in the discrimination of WTs and non-WTs (Table S3).

All participants (23/23, 100%) agreed that age influenced their prediction in the discrimination of pediatric renal tumors. Consensus was reached on a range from 1–3 years being indicative for WT, with a peak incidence at 3 years. Furthermore, participants mentioned 0–6 months for CMN, <2 years for RTK and  $\geq 10$  years for RCC as suggestive for these non-WTs.

### **Congenital Mesoblastic Nephroma**

There was consensus (21/23, 91.3%) on the statement that MRI is useful to distinguish CMN from other pediatric renal tumors in children <6 months of age. CMN can be divided into classic, cellular, and mixed type, with homogeneity being the only characteristic for classic type CMN reaching an agreement among the majority of the participants (Table 2).

### **Rhabdoid Tumor of the Kidney**

The majority (17/23, 73.9%) agreed MRI is useful to distinguish an RTK from other pediatric renal tumors. There was consensus on the presence of a (synchronous) intracranial/brain tumor being specific for the diagnosis of RTKs (Table 1).

### **Clear Cell Sarcoma of the Kidney**

There was no agreement on the value of MRI in the characterization of CCSK, with 56.5% (13/23) indicating MRI

may not be useful to distinguish a CCSK from other pediatric renal tumors. Only the presence of bone metastases was indicated as a specific characteristic (Table 1).

### **Cystic Nephroma, Cystic Partially Differentiated Nephroblastoma and Cystic Wilms Tumor**

A majority (16/22, 72.7%) agreed, that cystic WT can be reliably differentiated from CPDN on MRI. The presence of enhancing solid and/or nodular components in the septa of the tumor, with restricted diffusion on DWI, is specific for cystic WT in the discrimination from CN and CPDN (Tables 1 and 2). Nevertheless, a majority (14/20, 70.0%) felt that when solid WT components in a cystic WT are small and difficult to detect, its differentiation from CN and CPDN is unreliable. Finally, there was consensus (19/21, 90.5%) that MRI cannot reliably differentiate CN from CPDN.

### **Renal Cell Carcinoma**

No agreement (12/23, 52.2%) was reached on the value of MRI for discrimination of RCC from other pediatric renal tumors in children  $\geq 10$  years of age. Participants agreed (16/20, 80.0%) that experience was too limited to describe specific MRI characteristics of RCCs in children, let alone the description of histological subtypes (Table S1A).

### **Neuroblastoma**

Consensus (22/23, 95.7%) was reached on the statement that MRI is useful to distinguish neuroblastomas with marked renal extension from a renal tumor. The presence of tumor calcification, vascular encasement, an extra-renal origin of the tumor often indicated by the absence of a claw sign, adrenal gland involvement, and extension into the spinal canal/foramen reached consensus on being specific for neuroblastoma. A majority agreed that the presence of bone marrow metastases and lifting/anterior displacement of the aorta provided additional specific MRI characteristics (Table 1).

### **Wilms Tumor and Nephrogenic Rest(s)/Nephroblastomatosis**

Twenty-one/23 (91.3%) radiologists agreed that MRI is useful to distinguish NR/nephroblastomatosis from WT. DWI and contrast-enhanced T1-weighted imaging were indicated as the most valuable sequences to detect NR/nephroblastomatosis. Eighteen/23 (78.3%) participants had experience with DWI in this discrimination, but only 9/18 (50.0%) agreed that it is useful (Table 1, Table S4). The participants indicated NR/nephroblastomatosis show little, or even no enhancement on contrast-enhanced T1-weighted imaging, are hypointense compared with renal parenchyma on T1-weighted imaging, with varying intensity on T2-weighted imaging depending on the lesions being hyperplastic (hyper-intense) or sclerotic (hypo-intense). Appearance is largely dependent on the

**TABLE 1. MRI Characteristics and Statements Reaching Consensus or a Majority in the Second Questionnaire by Means of Likert Scales**

MRI Characteristics/Statements	Median	Range	Number of Participants Answering 4 (%)	Number of Participants Answering 5 (%)	Conclusion <sup>a</sup>
<b>MRI characteristics specific for the diagnosis of a Wilms tumor</b>					
The presence of NR/nephroblastomatosis	4	3–5	8/20 (40.0%)	7/20 (35.0%)	Consensus
The presence of a bilateral tumor	4	1–5	10/20 (50.0%)	3/20 (15.0%)	Majority
<b>MRI characteristics specific for the diagnosis of rhabdoid tumor of the kidney</b>					
The presence of a (synchronous) intracranial/brain tumor	5	1–5	4/20 (20.0%)	12/20 (60.0%)	Consensus
<b>MRI characteristics specific for the diagnosis of clear cell sarcoma of the kidney</b>					
The presence of bone metastases	4	1–5	10/20 (50.0%)	4/20 (20.0%)	Majority
<b>Statements considering the differentiation between cystic Wilms tumor and cystic partially differentiated nephroblastoma</b>					
A cystic WT shows heterogeneous enhancement, due to presence of solid components	4	1–4	12/20 (60.0%)	0/20 (0%)	Majority
A cystic WT can show areas of diffusion restriction in solid components in the septa <sup>b</sup>	4	1–5	13/20 (65.0%)	1/20 (5.0%)	Majority
A CPDN is a rare tumor and there is little experience with the imaging of this tumor, so the reliability of the use of (DWI-)MRI in the differentiation of a CPDN and a cystic WT is limited <sup>b</sup>	4	1–5	13/20 (65.0%)	1/20 (5.0%)	Majority
<b>MRI characteristics specific for the diagnosis of a neuroblastoma</b>					
The presence of tumor calcification	4	1–5	9/20 (45.0%)	7/20 (35.0%)	Consensus
The presence of vascular encasement	5	1–5	5/20 (25.0%)	12/20 (60.0%)	Consensus
An extra-renal origin of the tumor, often indicated by the absence of a claw sign	4	1–5	5/20 (25.0%)	12/20 (60.0%)	Consensus
The presence of adrenal gland involvement	5	2–5	6/20 (30.0%)	11/20 (55.0%)	Consensus
Extension into the spinal canal/foramen	5	1–5	3/20 (15.0%)	13/20 (65.0%)	Consensus
The presence of bone marrow metastases	4	1–5	9/20 (45.0%)	5/20 (25.0%)	Majority
Lifting/Anterior displacement of the aorta	4	1–5	6/20 (30.0%)	8/20 (40.0%)	Majority
<b>Statements considering the differentiation between Wilms tumor and nephrogenic rest(s)/nephroblastomatosis</b>					
In contrast to WTs, on contrast-enhanced (T1-weighted) imaging, NR/nephroblastomatosis show little or even no enhancement after intravenous administration of contrast	4	2–5	14/20 (70.0%)	3/20 (15.0%)	Consensus
NR/nephroblastomatosis have a homogeneous appearance on MRI, especially on contrast-enhanced (T1-weighted) imaging	4	1–5	12/20 (60.0%)	7/20 (35.0%)	Consensus

TABLE 1. Continued

MRI Characteristics/Statements	Median	Range	Number of Participants Answering 4 (%)	Number of Participants Answering 5 (%)	Conclusion <sup>a</sup>
NR/nephroblastomatosis are often multiple, small (ovoid shaped) nodules	4	1–5	15/20 (75.0%)	3/20 (15.0%)	Consensus
Small WTs may present similar to large NR/nephroblastomatosis	4	1–5	13/20 (65.0%)	2/20 (10.0%)	Consensus
NR/nephroblastomatosis are often located subcapsular (peripheral)	4	2–5	17/20 (85.0%)	2/20 (10.0%)	Consensus
On DWI, NR/nephroblastomatosis show diffusion restriction <sup>b</sup>	4	1–5	11/20 (55.0%)	4/20 (20.0%)	Consensus
On T1-weighted imaging, NR/nephroblastomatosis are hypo-intense in comparison to the renal parenchyma	4	2–4	15/20 (75.0%)	0/20 (0%)	Consensus
On T2-weighted imaging, intensity of NR/nephroblastomatosis varies depending on the lesions being hyperplastic/active (hyper-intense) or sclerotic/dormant (hypo-intense)	4	1–5	13/20 (65.0%)	2/20 (10.0%)	Consensus
NR/nephroblastomatosis often present bilateral	4	2–5	11/20 (55.0%)	8/20 (40.0%)	Consensus
The exact localization of NR/nephroblastomatosis is dependent on an intralobar or perilobar presentation (or a combination of both)	4	2–5	11/20 (55.0%)	2/20 (10.0%)	Majority
The appearance of NR/nephroblastomatosis is largely dependent on whether it presents as diffuse nephroblastomatosis and/or (multiple) nodules of NR	4	1–5	12/20 (60.0%)	1/20 (5.0%)	Majority
There is a lack of knowledge about the specific use of DWI and ADC-values in the discrimination of Wilms tumors and NR/nephroblastomatosis <sup>b</sup>	4	1–5	13/20 (65.0%)	1/20 (5.0%)	Majority

WT = Wilms tumor; CPDN = cystic partially differentiated nephroblastoma; NR = nephrogenic rest(s); MRI = magnetic resonance imaging; DWI = diffusion weighted imaging; ADC = apparent diffusion coefficient.

<sup>a</sup>Consensus is defined as  $\geq 75\%$   $\geq 4$  based on a Likert scale from 1 (definitely not specific/strongly disagree) to 5 (definitely specific/strongly agree), majority is defined as  $\geq 60\%$   $\geq 4$  based on a Likert scale from 1 (definitely not specific/strongly disagree) to 5 (definitely specific/strongly agree), both with a median  $\geq 4$ .

<sup>b</sup>Characteristics concerning DWI are also included in Table S4, in the perspective of additional information concerning the value of DWI in the tumor type.

lesions being diffuse (nephroblastomatosis) or nodular (NR). NR/nephroblastomatosis have a homogeneous appearance, often presenting as small (ovoid shaped) bilateral nodules, with diffusion restriction. They are often located subcapsular, but the exact localization is dependent on intralobar or perilobar presentation. Finally, small WTs may present similar to large NR (Table 1).

### Diffusion Weighted Imaging

Overall, experience with DWI varied, resulting in subgroups of participants feeling competent to give their opinion on the potential value of this MRI sequence to predict certain renal tumor types (Table S4). DWI plays a role in the characterization of neuroblastoma (14/18, 77.8%) and the discrimination

**TABLE 2. MRI Characteristics and Statements Reaching Consensus or a Majority in the Second Questionnaire by Means of Multiple-Choice Questions**

MRI Characteristics/Statements	Number of Participants of Total (%)	Number of Participants Excluding Those Not Feeling Competent to Answer the Question (%)	Conclusion <sup>a</sup>
<b>MRI characteristics specific for congenital mesoblastic nephroma</b>			
Tumor homogeneity is specific for classic type CMN	12/20 (60.0%)	12/18 (66.7%)	Majority
<b>MRI characteristics differentiating between cystic nephroma and cystic Wilms tumor</b>			
The presence of solid (nodular) components in the septa of the tumor is specific for cystic WT	11/20 (55.0%)	11/17 (64.7%)	Majority
The presence of hemorrhage can be seen in both CN and cystic WT	11/20 (55.0%)	11/18 (61.1%)	Majority
(Nodular/Solid) Areas of diffusion restriction (in the septa) is specific for cystic WT <sup>b</sup>	9/19 (47.4%)	9/15 (60.0%)	Majority

CMN = congenital mesoblastic nephroma; WT = Wilms tumor; CN = cystic nephroma; MRI = magnetic resonance imaging.

<sup>a</sup>Consensus is defined as  $\geq 75\%$  agreement among the participants feeling competent to answer the question, majority is defined as  $\geq 60\%$  agreement among the participants feeling competent to answer the question.

<sup>b</sup>Characteristics concerning DWI are also included in Table S4, in the perspective of additional information concerning the value of DWI in the tumor type.

of cystic WT from CN (12/15, 80.0%), but not in the discrimination between CN and CPDN. Experience with the value of DWI in the characterization of CMN, RTK, CCSK, and RCC was lacking (Table S4).

## Discussion

This study aimed to identify discriminative MRI characteristics for the diagnosis of the most common pediatric renal tumors. Two consecutive online questionnaire rounds provided information from experts in the field of imaging of pediatric renal tumors. Answers were analyzed and subjected to a scoring system, using predetermined cut-off values. Previous studies concluded that only a few imaging findings seem to be reliable to differentiate between WTs and non-WTs.<sup>3,14</sup> The appearance of renal tumor tissue on different MRI sequences is highly dependent on the presence of common tumor components such as hemorrhage and necrosis.<sup>15</sup> Therefore, the lack of pathognomonic characteristics for pediatric renal tumors and the rarity of non-WTs limit the ability of MRI to distinguish between the variety of potential diagnoses.<sup>16</sup> Nevertheless, some MRI characteristics reached consensus or agreement among the majority of the participants for being specific for certain renal tumor types.

WTs are generally described as solid intrarenal masses with a pseudocapsule, showing heterogeneity due to areas of hemorrhage, necrosis, and/or cysts.<sup>16–20</sup> These features were not indicated as specific by the participants, probably because they are not pathognomonic for WT. Calcifications, best identified on US, were mentioned as indicative for non-WTs, given their rarity in WTs.<sup>16,21</sup> They are most common in RCCs, but their appearance might also lead to additional imaging for the differentiation of neuroblastoma from WTs, especially in upper-pole tumors.<sup>16,20,21</sup> However, given the low incidence of non-WTs, the diagnosis of a WT might still be more likely even when calcifications are present.<sup>14,17,22</sup> US examination is being performed as standard of care in the diagnostic process of children with renal tumors in the SIOP-RTSG 2016 UMBRELLA protocol. On US examination, a majority agreed on the presence of an encapsulated tumor and a claw sign as indicative for a WT.

A homogeneous appearance was indicated by the participants as specific for classic type CMN, in accordance with previous studies.<sup>23</sup> Nevertheless, the more aggressive cellular type CMN cannot be reliably distinguished from WT, since hemorrhage, necrosis, and cysts may be present, resulting in a heterogeneous appearance.<sup>14,19</sup> For the same reason CCSK may resemble WT at MRI, typically appearing as a well-circumscribed, solid, heterogeneously enhancing mass, with

T1-weighted hypo-intensity, and T2-weighted hyper-intensity.<sup>15,16,19</sup> Also imaging features of RTK overlap with those of other pediatric renal tumors, especially WT.<sup>15,19,24</sup> An imaging feature described as rather specific for RTK is the presence of subcapsular fluid, often representing necrosis and/or hemorrhage.<sup>15,24</sup> This characteristic was assessed as being specific for RTK by only 50% of the participants, probably because this imaging feature is not uncommon in WT either.

No imaging characteristics were identified as specific for RCC, especially in the differentiation from WT. Nevertheless, previous studies have speculated RCC is often hyper-intense on T1-weighted imaging and hypo-intense on T2-weighted imaging, whereas this seems to be the opposite for WTs.<sup>21,22</sup>

CN and CPDN are uncommon, low-risk lesions, that based on previous literature cannot be differentiated by imaging.<sup>25,26</sup> CPDN is regarded as a variant of WT with a good prognosis. Likewise, CN is considered to have excellent outcome, although in this lesion, potentially underlying DICER1-aberrations should be taken into consideration. Furthermore, WTs can present with cystic components.<sup>3</sup> Although the diagnostic criteria by Joshi and Beckwith describe CN as a lesion composed entirely of cysts and their septa, this turned out not to be a discriminating MRI characteristic in this study.<sup>27,28</sup> Therewithal, for instance also CMNs can contain multiple cysts.<sup>26</sup> The results concerning the reliability of MRI in the differentiation of cystic masses are largely based on the degree of discernment of enhancing solid nodules in the septa. As agreed on by the participants, there is limited experience with these lesions on MRI, as they are rare.

Since NR/nephroblastomatosis occur in up to 99% of bilateral WTs, differentiation of these lesions from metachronous WTs is important.<sup>3,29</sup> DWI and contrast-enhanced T1-weighted imaging are considered the most useful sequences to detect NR/nephroblastomatosis, although the discriminating value of DWI might need further specification since NR/nephroblastomatosis and WT can both show low apparent diffusion coefficient (ADC)-values.<sup>3,4</sup> Nevertheless, in accordance with previous results, consensus was reached on the hypo-intense appearance on T1-weighted imaging and the homogeneous appearance after contrast, whereas the previously reported limited enhancement of these lesions was not specifically mentioned by the participants.<sup>4,14,30</sup> NRs are often ovoid-shaped and located peripherally when perilobar. However, histologically NR/nephroblastomatosis can be classified as dormant, sclerosing, hyperplastic, or neoplastic, which results in a variety of presentations on MRI reported in previous studies.<sup>4,19,31</sup> Taking the described diversity into consideration, MRI seems useful in the discrimination of NR/nephroblastomatosis from malignant tumors.

Over recent decades, knowledge on the use of DWI in pediatric renal tumors has been increasing.<sup>10,32,33</sup> ADC-values have shown a significant relationship with WT-

subtypes, and may have potential in future discrimination of pediatric renal tumors.<sup>8,9</sup> Also, the correlation between ADC-values after preoperative therapy and histological findings could be important for its future use as prognostic biomarker. Nevertheless, so far, experience remains limited, and especially the absence of accepted standards and consensus in ADC quantification may have had an effect on the lack of agreement and limited specific DWI-characteristics in this study.<sup>33,34</sup> Future research should focus on exploring the different applications of DWI and other MRI techniques such as intravoxel incoherent motion imaging.<sup>32,34</sup>

Our Delphi study showed, that, apart from MRI characteristics, epidemiology and clinical presentation contribute substantially to the differential diagnostic considerations for pediatric radiologists in the case of a newly diagnosed pediatric renal tumor.<sup>3,14,19</sup> The presence of a tumor thrombus, a bilateral tumor and NR/nephroblastomatosis were already described as indicative for WT in previous studies.<sup>4,14,17,21</sup> Intravascular extension of a tumor thrombus can occur in up to 10% of WT-cases, often best demonstrated on T2-weighted imaging.<sup>17</sup> The presence of a tumor thrombus and a bilateral tumor were also indicated by the participants as specific for a WT on US examination. Meanwhile, CMN has never been shown to invade the renal vessels or inferior vena cava.<sup>23</sup> However, venous thrombosis is not specific and can also be observed in other non-WTs such as RCC and primitive neuroectodermal tumor of the kidney.<sup>35</sup>

Also, the site of metastases determines diagnostic discrimination considerations for pediatric radiologists. In WTs, metastases are most commonly present in the lungs, followed by the liver, and are a strong indication for this diagnosis.<sup>18,36</sup> According to the described resemblance of CCSK with WTs on MRI, participants did not indicate any tumor characteristics as specific, whereas the presence of bone metastases was indicated as specific. Other pediatric renal tumors rarely metastasize to the bone, resulting in the historical designation of CCSK as “bone-metastasizing tumor.”<sup>15,37</sup>

Accordingly, although a majority of the participants agreed that MRI is useful to distinguish RTK from other pediatric renal tumors, they felt that the only imaging characteristic reaching consensus concerned the presence of a (synchronous) intracranial tumor. This has been established as an important feature in various studies, as it occurs in 10–15% of the RTK-cases.<sup>16,36,38</sup> Furthermore, the SIOP-RTSG 2016 UMBRELLA protocol recommends a biopsy in children <24 months suffering from metastasis, especially to the lungs, since it makes the diagnosis of an RTK more likely. However, this detailed characteristic was not assessed in the second round of the study. Finally, tumor size was not classified as specific for any renal tumor, but might play a differentiating role, given the apparently smaller size of RCCs and RTKs compared to especially WTs and CCSKs.<sup>6,16,17,19,22</sup>



All participants indicated that they were influenced by the age of the patient in their radiological assessment, which can be supportive as well as precarious. WT's present with a peak age around 3.5 years, with the vast majority presenting in the first decade of life.<sup>2,3,6,19</sup> In accordance with previous literature, CMN was indicated as most common renal neoplasm in the first months of life.<sup>19</sup> The consensus on the value of MRI in the discrimination of CMN from other pediatric renal tumors in this study was most likely strongly influenced by specifically limiting the question to a population <6 months of age, since the homogeneous classic type presents early in life as well as prenatally, making it potentially more distinguishable from WT's and other non-WT's.<sup>17,23</sup> RTK and CCSK show an overlap in peak age and range with WT-patients, with RTK mostly occurring  $\leq 2$  years of age.<sup>19,21,24</sup> In accordance with the increased incidence in adults, RCC becomes more common in the second decade of life.<sup>2</sup> Nevertheless, the appearance of RCCs is so close to that of WT's, that patients in this age group presenting with a renal tumor are described to be equally likely to have an RCC as a WT.<sup>38</sup> Since age-distribution is already extensively described, it was not systematically included in both questionnaires.<sup>2</sup>

Finally, nonrenal tumors, such as neuroblastoma, can be difficult to distinguish from renal tumors in cases of extensive renal invasion, especially when showing similarities with MRI characteristics of WT.<sup>20,30</sup> Vascular encasement and adrenal gland involvement, indicated as the most specific characteristics for neuroblastoma by the participants, hardly ever occur in renal tumors. Furthermore, the tendency of neuroblastoma to infiltrate and/or encase adjacent structures rather than displace them, has also been described in previous studies.<sup>19,20,30</sup> Malignancies that even more rarely present in the kidney, such as renal lymphomas, teratomas, and primitive neuroectodermal tumors, were not taken into consideration in this study.

According to the available literature, the advice is to limit the number of participants within a Delphi study to a maximum of 30, in order to enhance the quality of results and the likelihood of consensus.<sup>39</sup> Given the explicit field of expertise, strict inclusion criteria and a snowballing technique were used to reach a minimum of 20 participants, with a preferable maximum of 35.<sup>12</sup> This approach resulted in participation of 23 experts from 14 countries with a high response rate (92.0% and 87.0% in the first and second round, respectively).

### Limitations

This Delphi process was designed following a conventional/classical method, using a combination of closed- and open-ended questions in the first round, with the purpose of reducing bias by not limiting or controlling participants' answers.<sup>11,39</sup> Consequently, participants became largely responsible for the content, anticipating on the expected

different uses of MRI in diagnosing pediatric renal tumors. A limitation was the risk of imaging characteristics known in the literature not being introduced by participants for the second questionnaire. Furthermore, the study could not distinguish between an expert opinion based on own clinical experience or on evidence in the literature. Results generated through expert opinion are at high risk of error in advance, and Delphi studies are often ranked as having a low level of evidence.<sup>40</sup> Nevertheless, this Delphi process assumed that the participants critically submitted themselves to the inclusion criteria and that they answered the questions to their best ability, while only focusing on experts in this specific field of interest.

A universally agreed cut-off value for consensus in Delphi studies is lacking and was therefore based on previous studies with corresponding circumstances.<sup>11</sup> Meeting the aimed number of participants, and achieving meaningful results after two rounds, implies the feasibility of the Delphi method for the current setting.

### Conclusion

This study provides specific imaging characteristics of pediatric renal tumors based on the shared opinion of experts in the field of pediatric oncologic radiology, following a Delphi process. Based on this expert consensus and agreement, we have identified MRI characteristics that could be used to differentiate between pediatric renal tumors. However, the discrimination of pediatric renal tumors based on solely MRI characteristics remains challenging.

Based on our findings, we recommend to follow the imaging guidelines of the SIOP-RTSG 2016 UMBRELLA protocol, and we emphasize the importance of including DWI and contrast-enhanced T1-weighted imaging within the MRI protocol. Furthermore, the SIOP-RTSG is currently reconsidering which patients may benefit from biopsy based on certain imaging characteristics in combination with age, clinical characteristics, and genetic predisposition.

Our findings could especially be of value for validation in retrospective and prospective studies and innovative efforts by radiologists, including the increasing knowledge on quantitative MRI techniques such as DWI, to noninvasively diagnose renal tumors in children.

### Acknowledgments

The authors acknowledge Chris van Kesteren, graphical designer from the Imaging Division of the University Medical Center Utrecht in The Netherlands, for his assistance in the building of the online questionnaires. This work was supported by a grant (Grant Number 341) from the Stichting Kinderen Kankervrij (KiKa).

## References

1. Brok J, Treger TD, Gooskens SL, van den Heuvel-Eibrink MM, Pritchard-Jones K. Biology and treatment of renal tumours in childhood. *Eur J Cancer* 2016;68:179-195.
2. Nakata K, Colombet M, Stiller CA, Pritchard-Jones K, Steliarova-Foucher E. Incidence of childhood renal tumours: An international population-based study. *Int J Cancer* 2020;147(12):3313-3327.
3. Watson T, Oostveen M, Rogers H, Pritchard-Jones K, Olsen Ø. The role of imaging in the initial investigation of paediatric renal tumours. *Lancet Child Adolesc Health* 2020;4(3):232-241.
4. Gylys-Morin V, Hoffer FA, Kozakewich H, Shamberger RC. Wilms tumor and nephroblastomatosis: Imaging characteristics at gadolinium-enhanced MR imaging. *Radiology* 1993;188(2):517-521.
5. Nelson MV, van den Heuvel-Eibrink MM, Graf N, Dome JS. New approaches to risk stratification for Wilms tumor. *Curr Opin Pediatr* 2021;33(1):40-48.
6. de la Monneraye Y, Michon J, Pacquement H, et al. Indications and results of diagnostic biopsy in pediatric renal tumors: A retrospective analysis of 317 patients with critical review of SIOP guidelines. *Pediatr Blood Cancer* 2019;66(6):e27641.
7. Dome JS, Graf N, Geller JI, et al. Advances in Wilms tumor treatment and biology: Progress through international collaboration. *J Clin Oncol* 2015;33(27):2999-3007.
8. Littooij AS, Sebire NJ, Olsen ØE. Whole-tumor apparent diffusion coefficient measurements in nephroblastoma: Can it identify blastemal predominance? *J Magn Reson Imaging* 2017;45(5):1316-1324.
9. Hötker AM, Lollert A, Mazaheri Y, et al. Diffusion-weighted MRI in the assessment of nephroblastoma: Results of a multi-center trial. *Abdom Radiol (NY)* 2020;45(10):3202-3212.
10. Humphries PD, Sebire NJ, Siegel MJ, Olsen ØE. Tumors in pediatric patients at diffusion-weighted MR imaging: Apparent diffusion coefficient and tumor cellularity. *Radiology* 2007;245(3):848-854.
11. Hasson F, Keeney S, McKenna H. Research guidelines for the Delphi survey technique. *J Adv Nurs* 2000;32(4):1008-1015.
12. Streeton R, Cooke M, Campbell J. Researching the researchers: Using a snowballing technique. *Nurse Res* 2004;12(1):35-46.
13. Harpe SE. How to analyze Likert and other rating scale data. *Curr Pharm Teach Learn* 2015;7(6):836-850.
14. Riccabona M. Imaging of renal tumours in infancy and childhood. *Eur Radiol* 2003;13(Suppl 4):L116-L129.
15. Prasad SR, Humphrey PA, Menias CO, et al. Neoplasms of the renal medulla: Radiologic-pathologic correlation. *Radiographics* 2005;25(2):369-380.
16. Siegel MJ, Chung EM. Wilms' tumor and other pediatric renal masses. *Magn Reson Imaging Clin N Am* 2008;16(3):479-497. vi.
17. Birkemeier KL. Imaging of solid congenital abdominal masses: A review of the literature and practical approach to image interpretation. *Pediatr Radiol* 2020;50(13):1907-1920.
18. Brisse HJ, Smets AM, Kaste SC, Owens CM. Imaging in unilateral Wilms tumour. *Pediatr Radiol* 2008;38(1):18-29.
19. Lowe LH, Isuani BH, Heller RM, et al. Pediatric renal masses: Wilms tumor and beyond. *Radiographics* 2000;20(6):1585-1603.
20. Aslan M, Aslan A, Anöz Habibi H, et al. Diffusion-weighted MRI for differentiating Wilms tumor from neuroblastoma. *Diagn Interv Radiol* 2017;23(5):403-406.
21. Stanescu AL, Acharya PT, Lee EY, Phillips GS. Pediatric renal neoplasms: MR imaging-based practical diagnostic approach. *Magn Reson Imaging Clin N Am* 2019;27(2):279-290.
22. Chen X, Zhu Q, Li B, et al. Renal cell carcinoma associated with Xp11.2 translocation/TFE gene fusion: Imaging findings in 21 patients. *Eur Radiol* 2017;27(2):543-552.
23. Linam LE, Yu X, Calvo-Garcia MA, et al. Contribution of magnetic resonance imaging to prenatal differential diagnosis of renal tumors: Report of two cases and review of the literature. *Fetal Diagn Ther* 2010;28(2):100-108.
24. Eftekhari F, Eryl WK, Jaffe N. Malignant rhabdoid tumor of the kidney: Imaging features in two cases. *Pediatr Radiol* 1990;21(1):39-42.
25. Stout TE, Au JK, Hicks JM, Gargollo PC. A case of bilateral cystic partially differentiated Nephroblastoma vs cystic Wilms' tumor: Highlighting a diagnostic dilemma. *Urology* 2016;92:106-109.
26. van den Hoek J, de Krijger R, van de Ven K, Lequin M, van den Heuvel-Eibrink MM. Cystic nephroma, cystic partially differentiated nephroblastoma and cystic Wilms' tumor in children: A spectrum with therapeutic dilemmas. *Urol Int* 2009;82(1):65-70.
27. Joshi VV, Beckwith JB. Multilocular cyst of the kidney (cystic nephroma) and cystic, partially differentiated nephroblastoma. Terminology and criteria for diagnosis. *Cancer* 1989;64(2):466-479.
28. Vujanic GM, Gessler M, Ooms A, et al. The UMBRELLA SIOP-RTSG 2016 Wilms tumour pathology and molecular biology protocol. *Nat Rev Urol* 2018;15(11):693-701.
29. Beckwith JB. New developments in the pathology of Wilms tumor. *Cancer Invest* 1997;15(2):153-162.
30. Dumba M, Jawad N, McHugh K. Neuroblastoma and nephroblastoma: A radiological review. *Cancer Imaging* 2015;15(1):5.
31. Rohrschneider WK, Weirich A, Rieden K, Darge K, Tröger J, Graf N. US, CT and MR imaging characteristics of nephroblastomatosis. *Pediatr Radiol* 1998;28(6):435-443.
32. Meeus EM, Zarinabad N, Manias KA, et al. Diffusion-weighted MRI and intravoxel incoherent motion model for diagnosis of pediatric solid abdominal tumors. *J Magn Reson Imaging* 2018;47(6):1475-1486.
33. Hales PW, Olsen ØE, Sebire NJ, Pritchard-Jones K, Clark CA. A multi-Gaussian model for apparent diffusion coefficient histogram analysis of Wilms' tumour subtype and response to chemotherapy. *NMR Biomed* 2015;28(8):948-957.
34. Padhani AR, Liu G, Koh DM, et al. Diffusion-weighted magnetic resonance imaging as a cancer biomarker: Consensus and recommendations. *Neoplasia* 2009;11(2):102-125.
35. Chu WC, Reznikov B, Lee EY, Grant RM, Cheng FW, Babyn P. Primitive neuroectodermal tumour (PNET) of the kidney: A rare renal tumour in adolescents with seemingly characteristic radiological features. *Pediatr Radiol* 2008;38(10):1089-1094.
36. Powis M. Neonatal renal tumours. *Early Hum Dev* 2010;86(10):607-612.
37. Marsden HB, Lawler W, Kumar PM. Bone metastasizing renal tumor of childhood: Morphological and clinical features, and differences from Wilms' tumor. *Cancer* 1978;42(4):1922-1928.
38. Broecker B. Non-Wilms' renal tumors in children. *Urol Clin North Am* 2000;27(3):463-469. ix.
39. de Villiers MR, de Villiers PJ, Kent AP. The Delphi technique in health sciences education research. *Med Teach* 2005;27(7):639-643.
40. Evans D. Hierarchy of evidence: A framework for ranking evidence evaluating healthcare interventions. *J Clin Nurs* 2003;12(1):77-84.