




## CASE REPORT

# A case of pulmonary pleomorphic carcinoma with preexisting interstitial pneumonia successfully treated with pembrolizumab

Masahiro Sako<sup>1,2</sup>  | Hiroshi Nokihara<sup>1</sup>  | Kensuke Kondo<sup>1,2</sup> | Atsushi Mitsuhashi<sup>1</sup> | Ryohiko Ozaki<sup>1</sup> | Yohei Yabuki<sup>1</sup> | Akane Abe<sup>1</sup> | Hiroto Yoneda<sup>1</sup> | Hirokazu Ogino<sup>1</sup> | Kenji Otsuka<sup>1</sup> | Hisanori Uehara<sup>3</sup> | Yasuhiko Nishioka<sup>1</sup> 

<sup>1</sup>Department of Respiratory Medicine and Rheumatology, Graduate School of Biomedical Sciences, Tokushima University, Tokushima, Japan

<sup>2</sup>Department of Community Medicine, Tokushima Prefectural Central Hospital, Tokushima, Japan

<sup>3</sup>Division of Pathology, Tokushima University Hospital, Tokushima, Japan

## Correspondence

Hiroshi Nokihara, Department of Respiratory Medicine and Rheumatology, Graduate School of Biomedical Sciences, Tokushima University, 3-18-15 Kuramoto-cho, Tokushima 770-8503, Japan.  
Email: hnokihara@tokushima-u.ac.jp

## Abstract

Pulmonary pleomorphic carcinoma is often refractory to chemotherapy and follows an aggressive clinical course. Immune checkpoint inhibitors (ICIs) have revolutionized the treatment of advanced lung cancer, and a few cases with pleomorphic carcinoma have been reported to show tumor shrinkage after therapy with ICIs. When treating patients with ICIs, patient selection is essential, and monitoring and management of immune-related adverse events, including pneumonitis, are needed. We herein report a case of pulmonary pleomorphic carcinoma with preexisting interstitial pneumonia treated with pembrolizumab, antiprogrammed cell death 1 antibody. Our report highlights important considerations necessary when treating advanced pleomorphic carcinoma patients complicated with interstitial pneumonia. We also review the literature regarding the use of ICIs in such patients.

## KEYWORDS

interstitial pneumonia, pembrolizumab, pulmonary pleomorphic carcinoma

## INTRODUCTION

Pleomorphic carcinoma is a rare, very aggressive subtype of cancer that follows the clinical pattern of carcinosarcoma. Among such lesions, pulmonary pleomorphic carcinoma accounts for 0.1–0.4% of all lung cancers<sup>1</sup> and is considered to be one type of non-small-cell lung cancer (NSCLC). It is often refractory to the most popular chemotherapeutic regimens used for NSCLC and responds poorly to radiation therapy. The prognosis of pleomorphic carcinoma of the lung has a worse prognosis than other histological types of NSCLC, and the 5-year survival rate and median survival time have been reported to be approximately 12% and 10 months, respectively.<sup>2</sup>

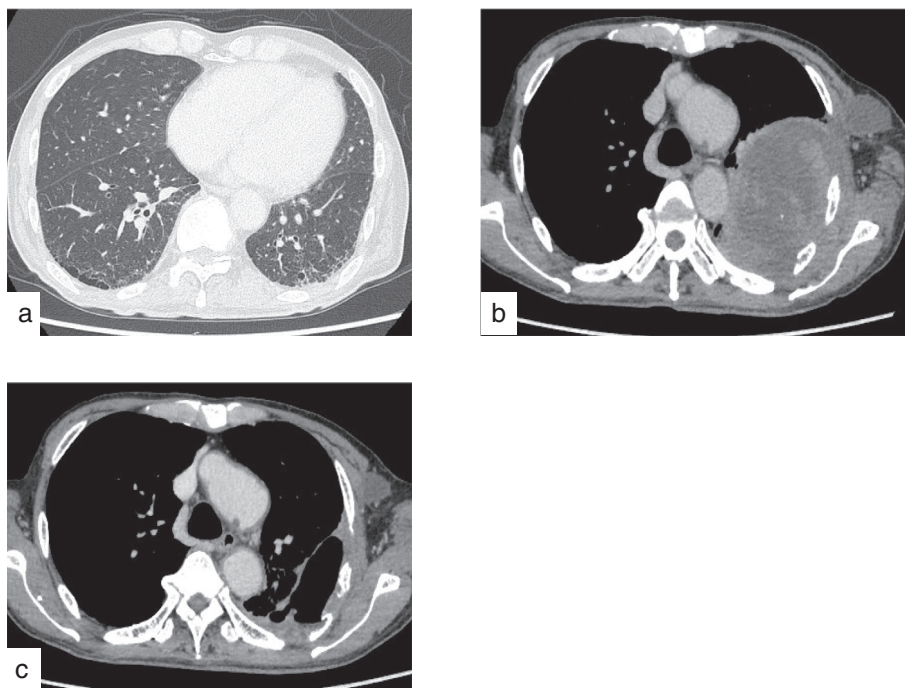
Immune checkpoint inhibitors (ICIs), including pembrolizumab, have been shown to provide a survival benefit in NSCLC patients, and treatment with ICIs has been established as standard therapy for advanced NSCLC.<sup>3,4</sup> However, interstitial pneumonia related to ICIs reportedly occurs in approximately 5%.<sup>3–5</sup>

The complication rate of interstitial pneumonia in lung cancer patients is 4–8%.<sup>6</sup> The efficacy of anticancer agents in lung cancer complicated with interstitial pneumonia seems to be equivalent to that of patients with noninterstitial pneumonia.<sup>7</sup> However, the high frequency (22–30%) of acute exacerbations caused by anticancer drugs limits the availability of therapeutic agents in these patients.<sup>8</sup>

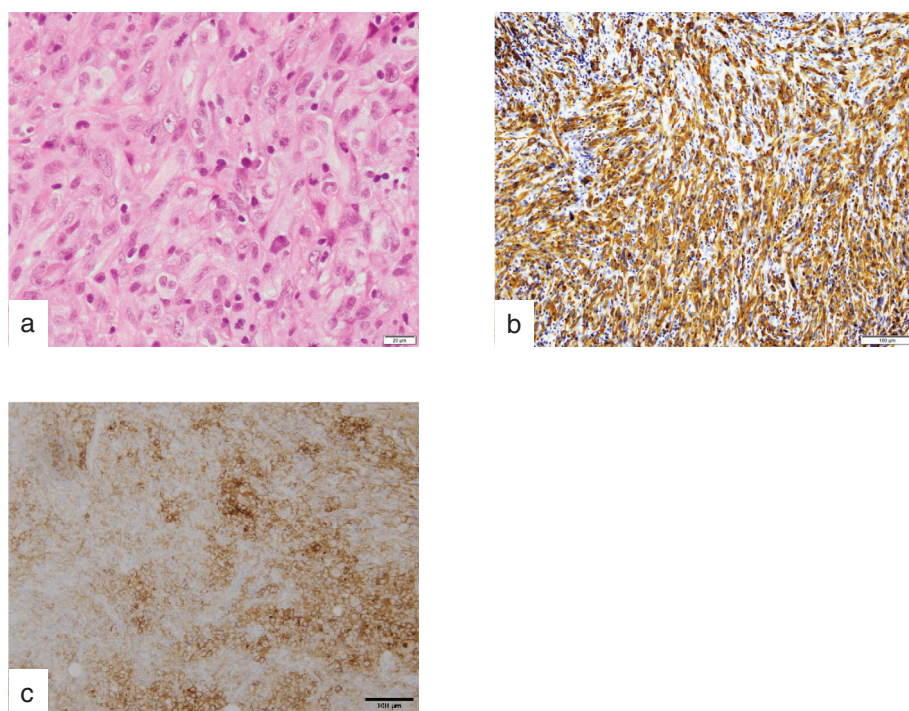
We herein report a case of pulmonary pleomorphic carcinoma complicated with interstitial pneumonia that showed a durable response to pembrolizumab.

## Case report

A 72-year-old man who was a 75-pack-year tobacco smoker developed left anterior chest pain. His Eastern Cooperative Oncology Group (ECOG) performance status was 1, and fine crackles were heard in the bilateral lower lung fields on chest auscultation. His saturation of



**FIGURE 1** Computed tomography images. (a) A minor interstitial pneumonia with a predominantly reticular shadow just below the bilateral lung base pleura was noted. (b) A mass shadow with internal necrosis in the upper lobe of the left lung as well as an enlarged left axillary lymph node was observed. (b, c) Computed tomography after treatment of pembrolizumab showed a reduction in the sizes of both the primary lung lesions and the lymph nodes



**FIGURE 2** Pathological findings of a left axillary lymph node biopsy. (a) Hematoxylin and eosin staining. (b) Immunohistochemistry staining for cytokeratin AE1/AE3. (c) Immunohistochemistry staining for programmed cell death ligand 1

percutaneous oxygen was 97% (room air). Computed tomography (CT) revealed a mass shadow with cavities in the upper lobe of the left lung and a metastatic lesion in the lower lobe of the left lung. He had lymphadenopathy in his left supraclavicular fossa and left axilla, and high-resolution computed tomography (HRCT) showed interstitial pneumonia with predominantly reticulated shadows at the bilateral lung bases (probable usual interstitial pneumonia pattern) without a honeycomb pattern

(Figure 1a). Blood tests showed an increased inflammatory indices and anemia. Tumor markers, including carcinoembryonic antigen, cytokeratin subunit 19 fragment, and progastrin-releasing peptide, were not elevated. Antinuclear antibody and rheumatoid factors were negative. Pulmonary function tests showed a predicted vital capacity (%VC) of 84%, a predicted forced vital capacity (%FVC) of 83%, and a diffusing capacity of the lung carbon monoxide (DLCO) of 10.4 mL/min/mmHg (65%).

A left axillary lymph node biopsy was performed, and pathological findings revealed a proliferation of spindle-shaped to polygonal atypical cells in a solid pattern (Figure 2a). Immunohistochemical staining showed that the atypical cells were positive for cytokeratin AE1/AE3 (Figure 2b) and negative for thyroid transcription factor 1, p40, S100 protein, ETS-related gene, and calretinin. Based on these findings, a diagnosis of pleomorphic carcinoma was thus made. The Ki-67 labeling index was 40%. The programmed cell death ligand 1 (PD-L1) tumor proportion score (TPS) was 65% (Figure 2c). *Epidermal growth factor receptor (EGFR)* activating mutations and *anaplastic lymphoma kinase (ALK)* fusion genes were not observed.

The diagnosis was pulmonary pleomorphic carcinoma with idiopathic pulmonary fibrosis at clinical stage T4N3M1c IVB. Six cycles of carboplatin and paclitaxel were administered as initial chemotherapy. There was no acute exacerbation of interstitial pneumonia, and minor tumor shrinkage was observed. However, 5 months later, the left chest pain had progressed, and enlargement of the primary tumor and left cervical and left axillary lymph nodes was noted (Figure 1b), along with new metastatic lesions in the brain. After informing the patient of the risk of exacerbation of interstitial pneumonia, the antiprogrammed cell death 1 (PD-1) antibody pembrolizumab was administered as a second-line treatment, and the tumors shrank significantly (Figure 1c).

Ten months after starting pembrolizumab treatment, pembrolizumab was discontinued due to arthralgia of the hands related to the drug. He had no acute exacerbation of interstitial pneumonia and maintained tumor shrinkage for more than 2 years after treatment interruption.

## DISCUSSION

Sarcomatoid carcinoma includes pleomorphic carcinoma, carcinosarcoma, and pulmonary blastoma. Pleomorphic carcinoma is a poorly differentiated non-small-cell carcinoma that contains at least 10% spindle and/or giant cells or a carcinoma consisting only of spindle and giant cells.<sup>9</sup> With regard to pulmonary pleomorphic carcinoma, surgery, chemotherapy, and radiation therapy have been performed, but many reports indicate that chemotherapy and radiation therapy are not effective. The promising effects of chemotherapy with bevacizumab have been reported for patients with pulmonary pleomorphic carcinoma,<sup>10</sup> so anti-angiogenic inhibitors may be useful for treating pleomorphic carcinoma. Because driver gene abnormalities are sometimes found in pleomorphic carcinoma and molecular-targeted drugs are effective in some cases,<sup>11–14</sup> a search for driver gene abnormalities, including *EGFR* mutations, is recommended.

ICIs have revolutionized treatment in advanced lung cancer.<sup>6,7</sup> The PD-L1 expression in NSCLC is used to predict the therapeutic efficacy of ICIs as better therapeutic effects can be expected for tumors with a high expression of PD-L1.<sup>15</sup> Recent studies have reported that 70–90% of pulmonary pleomorphic carcinomas show a high expression of

PD-L1.<sup>16,17</sup> Therefore, anti-PD-1/PD-L1 antibodies may be expected to be effective in patients with pulmonary pleomorphic cancer. Several other case reports have shown tumor shrinkage with pembrolizumab treatment.<sup>18–20</sup> In the present case, the PD-L1 TPS was 65% and the tumor clearly shrank after the initiation of pembrolizumab treatment.

Several prospective and retrospective studies have recently been reported concerning the efficacy and safety of anti-PD-1/PD-L1 antibodies in NSCLC associated with interstitial pneumonia. Eighteen patients were enrolled in a phase II study to evaluate the efficacy and safety of nivolumab in NSCLC patients with interstitial pneumonia.<sup>21</sup> Fujimoto et al.<sup>21</sup> reported a response rate of 39%, median progression-free survival of 7.4 months, and median overall survival of 15.6 months. Acute exacerbations of interstitial pneumonia were found in two patients (11%) in this phase II study, but there were no treatment-related deaths. Another phase II study of atezolizumab for NSCLC with interstitial pneumonia was terminated early owing to 29.4% of the patients (five of 17) experiencing acute exacerbation of interstitial pneumonia.<sup>22</sup>

In terms of acute exacerbation of preexisting interstitial pneumonia induced by cytotoxic chemotherapy, a honeycomb pattern on CT<sup>5</sup> and a low predicted FVC<sup>23</sup> have been reported to be the most common risk factors. A phase II study of nivolumab<sup>21</sup> excluded patients with a honeycomb pattern on HRCT or with a predicted VC <80%. In addition, the exclusion criteria included collagen vascular disease (CVD)-associated interstitial pneumonia, assessed by screening for CVD-associated antibody. Although an atezolizumab study<sup>22</sup> excluded patients with a predicted FVC <70%, seven of 17 patients (47.1%) had honeycomb lungs and a total of 57.1% patients (4 of 7) with honeycomb lung developed pneumonitis. Yamaguchi et al. showed that pulmonary fibrosis on chest CT was a risk factor for anti-PD-1-related pneumonitis in patients with NSCLC and that even mild pulmonary fibrosis might carry a risk of anti-PD-1-related pneumonitis.<sup>24</sup>

## CONCLUSION

Although systemic treatment regimens for pulmonary pleomorphic carcinoma are limited, ICIs may be an effective therapy. However, patient selection is essential when ICIs are used for patients complicated with interstitial pneumonia.

## ORCID

Masahiro Sako  <https://orcid.org/0000-0001-7985-3070>  
Hiroshi Nokihara  <https://orcid.org/0000-0002-1219-6966>  
Yasuhiko Nishioka  <https://orcid.org/0000-0001-6311-1654>

## REFERENCES

1. Chang YL, Lee YC, Shih JY, Wu CT. Pulmonary pleomorphic (spindle) cell carcinoma: peculiar clinicopathologic manifestations different from ordinary non-small cell carcinoma. *Lung Cancer*. 2001;34:91–7. [https://doi.org/10.1016/s0169-5002\(01\)00224-0](https://doi.org/10.1016/s0169-5002(01)00224-0)

2. Fishback NF, Travis WD, Moran CA, Guinee DG Jr, McCarthy WF, Koss MN. Pleomorphic (spindle/giant cell) carcinoma of the lung. A clinicopathologic correlation of 78 cases. *Cancer*. 1994;73:2936–45.
3. Reck M, Rodríguez-Abreu D, Robinson AG, Hui R, Csöszszi T, Fülöp A, et al. Pembrolizumab versus chemotherapy for PD-L1-positive non-small-cell lung cancer. *N Engl J Med*. 2016;375:1823–33. <https://doi.org/10.1056/NEJMoa1606774>
4. Herbst RS, Baas P, Kim DW, et al. Pembrolizumab versus docetaxel for previously treated, PD-L1-positive, advanced non-small-cell lung cancer (KEYNOTE-010): a randomised controlled trial. *Lancet*. 2016;387:1540–50. [https://doi.org/10.1016/S0140-6736\(15\)01281-7](https://doi.org/10.1016/S0140-6736(15)01281-7)
5. Naidoo J, Wang X, Woo KM, et al. Pneumonitis in patients treated with anti-programmed death-1/programmed death ligand 1 therapy. *J Clin Oncol*. 2017;35:709–17. <https://doi.org/10.1200/JCO.2016.68.2005>
6. Goto T. Measuring surgery outcomes of lung cancer patients with concomitant pulmonary fibrosis: a review of the literature. *Cancer*. 2018;10:223. <https://doi.org/10.3390/cancers10070223>
7. Otsubo K, Okamoto I, Hamada N, et al. Anticancer drug treatment for advanced lung cancer with interstitial lung disease. *Respir Investig*. 2018;56:307–11. <https://doi.org/10.1016/j.resinv.2018.03.002>
8. Kenmotsu H, Naito T, Kimura M, et al. The risk of cytotoxic chemotherapy-related exacerbation of interstitial lung disease with lung cancer. *J Thorac Oncol*. 2011;6:1242–6. <https://doi.org/10.1097/JTO.0b013e318216ee6b>
9. Travis WD, Brambilla E, Nicholson AG, et al. The 2015 World Health Organization classification of lung tumors: impact of genetic, clinical and radiologic advances since the 2004 classification. *J Thorac Oncol*. 2015;10:1243–60. <https://doi.org/10.1097/JTO.0000000000000630>
10. Oda T, Sekine A, Kato T, et al. Promising effect of chemotherapy with bevacizumab for patients with pulmonary pleomorphic carcinoma: two case reports and a literature review. *Respir Investig*. 2015;53:296–9. <https://doi.org/10.1016/j.resinv.2015.05.004>
11. Kaira K, Horie Y, Ayabe E, et al. Pulmonary pleomorphic carcinoma: a clinicopathological study including EGFR mutation analysis. *J Thorac Oncol*. 2010;5:460–5. <https://doi.org/10.1097/JTO.0b013e3181ce3e3c>
12. Tamura Y, Fujiwara Y, Yamamoto N, et al. Retrospective analysis of the efficacy of chemotherapy and molecular targeted therapy for advanced pulmonary pleomorphic carcinoma. *BMC Res Notes*. 2015;8:800. <https://doi.org/10.1186/s13104-015-1762-z>
13. Inoue A, Suzuki T, Fukuhara T, et al. Prospective phase II study of gefitinib for chemotherapy naive patients with advanced non-small-cell lung cancer with epidermal growth factor receptor gene mutations. *J Clin Oncol*. 2006;24:3340–6. <https://doi.org/10.1200/JCO.2005.05.4692>
14. Asahina H, Yamazaki K, Kinoshita I, et al. A phase II trial of gefitinib as first-line therapy for advanced non-small cell lung cancer with epidermal growth factor receptor mutations. *Br J Cancer*. 2006;95:998–1004. <https://doi.org/10.1038/sj.bjc.6603393>
15. Kumagai S, Togashi Y, Kamada T, et al. The PD-1 expression balance between effector and regulatory T cells predicts the clinical efficacy of PD-1 blockade therapies. *Nat Immunol*. 2020;21:1346–58. <https://doi.org/10.1038/s41590-020-0769-3>
16. Chang YL, Yang CY, Lin MW, et al. High co-expression of PD-L1 and HIF-1 $\alpha$  correlates with tumour necrosis in pulmonary pleomorphic carcinoma. *Eur J Cancer*. 2016;60:125–35. <https://doi.org/10.1016/j.ejca.2016.03.012>
17. Kim S, Kim MY, Koh J, et al. Programmed death-1 ligand 1 and 2 are highly expressed in pleomorphic carcinomas of the lung: comparison of sarcomatous and carcinomatous areas. *Eur J Cancer*. 2015;51:2698–707. <https://doi.org/10.1016/j.ejca.2015.08.013>
18. Tokuyasu H, Ishikawa S, Sakai H, et al. Single pembrolizumab treatment causing profound durable response in a patient with pulmonary pleomorphic carcinoma. *Respir Med Case Rep*. 2019;28:100879. <https://doi.org/10.1016/j.rmcr.2019.100879>
19. Matsumoto Y, Miura T, Horiuchi H, et al. The successful treatment of pulmonary pleomorphic carcinoma with pembrolizumab: a case report. *Case Rep Oncol*. 2017;10:752–7. <https://doi.org/10.1159/000479552>
20. Chang HC, Hsu CL, Chang YL, et al. Pulmonary pleomorphic carcinoma with pembrolizumab monotherapy. *Respirol Case Rep*. 2020;8:e0597. <https://doi.org/10.1002/rrc2.597>
21. Fujimoto D, Yomota M, Sekine A, et al. Nivolumab for advanced non-small cell lung cancer patients with mild idiopathic interstitial pneumonia: a multicenter, open-label single-arm phase II trial. *Lung Cancer*. 2019;134:274–8. <https://doi.org/10.1016/j.lungcan.2019.06.001>
22. Ikeda S, Kato T, Kenmotsu H, et al. A phase 2 study of atezolizumab for pretreated NSCLC with idiopathic interstitial pneumonitis. *J Thorac Oncol*. 2020;15:1935–42. <https://doi.org/10.1016/j.jtho.2020.08.018>
23. Enomoto Y, Inui N, Kato T, et al. Low forced vital capacity predicts cytotoxic chemotherapy-associated acute exacerbation of interstitial lung disease in patients with lung cancer. *Lung Cancer*. 2016;96:63–7. <https://doi.org/10.1016/j.lungcan.2016.03.017>
24. Yamaguchi T, Shimizu J, Hasegawa T, et al. Pre-existing pulmonary fibrosis is a risk factor for anti-PD-1-related pneumonitis in patients with non-small cell lung cancer: a retrospective analysis. *Lung Cancer*. 2018;125:212–7. <https://doi.org/10.1016/j.lungcan.2018.10.001>

**How to cite this article:** Sako M, Nokihara H, Kondo K, Mitsuhashi A, Ozaki R, Yabuki Y, et al. A case of pulmonary pleomorphic carcinoma with preexisting interstitial pneumonia successfully treated with pembrolizumab. *Thorac Cancer*. 2022;13:129–32. <https://doi.org/10.1111/1759-7714.14243>