





OPEN ACCESS

Changes in choroidal structure following intravitreal aflibercept therapy for retinal vein occlusion

Yoshinori Mitamura ^{1,2}, Tserennadmid Enkhmaa,^{1,2} Hiroki Sano,^{1,2} Masanori Niki,^{1,2} Fumiko Murao,^{1,2} Mariko Egawa,^{1,2} Shozo Sonoda,^{2,3} Taiji Sakamoto ^{2,3}

► Additional material is published online only. To view please visit the journal online (<http://dx.doi.org/10.1136/bjophthalmol-2020-316214>).

¹Department of Ophthalmology, Institute of Biomedical Sciences, Tokushima University Graduate School, Tokushima, Japan

²Japan Clinical Retina Study Group (J-CREST Group), Kagoshima, Japan

³Department of Ophthalmology, Kagoshima University Graduate School of Medical and Dental Sciences, Kagoshima, Japan

Correspondence to

Yoshinori Mitamura, Department of Ophthalmology, Institute of Biomedical Sciences, Tokushima University Graduate School, 3-18-15 Kuramoto, Tokushima 770-8503, Japan; ymitaymitaymita@yahoo.co.jp

YM and TE contributed equally to this work.

Received 2 March 2020

Revised 26 April 2020

Accepted 8 June 2020

Published Online First

3 July 2020

ABSTRACT

Aims To examine the choroidal change accompanying retinal vein occlusion (RVO) in detail, we measured changes in choroidal structure after intravitreal aflibercept (IVA) injections for RVO using binarisation of enhanced depth imaging optical coherence tomographic (EDI-OCT) images and assessed associations with clinical outcome.

Methods Retrospective, observational case series. Forty treatment-naïve patients (10 central, 18 major branch and 12 macular branch RVO) were examined by EDI-OCT before and 1, 3 and 6 months after IVA injections. EDI-OCT images were binarised using ImageJ. Subfoveal cross-sectional areas of the luminal, stromal and total choroid over a 1500 µm span were measured and the stromal area to total choroidal area (S/C) ratio was calculated.

Results Compared to normal contralateral eyes, afflicted eyes at baseline exhibited significantly greater stromal area ($p<0.001$), total choroidal area ($p=0.001$) and S/C ratio ($p<0.001$), but no difference in luminal area ($p=0.083$). The stromal area, S/C ratio and total choroidal area were significantly reduced in afflicted eyes at 1, 3 and 6 months after IVA (all $p<0.006$). Baseline S/C ratio was significantly correlated with baseline visual acuity (VA), baseline central retinal thickness (CRT) and VA and CRT improvement at 1, 3 and 6 months post-treatment even after adjusting for the axial length, age and sex (all $p<0.012$).

Conclusion RVO induces substantial oedema of the choroidal stromal area that is detectable by binarisation of EDI-OCT images. This stromal oedema likely stems from high intraocular vascular endothelial growth factor levels. Changes in choroidal structure may be used to assess severity and prognosis of RVO.

INTRODUCTION

Retinal vein occlusion (RVO) increases intravascular pressure of the capillary vessels and veins, causing the vessel barrier breakdown and ensuing leakage of blood or plasma components into the tissue (oedema). Antivascular endothelial growth factor (anti-VEGF) therapy can relieve this oedema and improve visual acuity (VA),^{1 2} but there are cases of treatment resistance and a poor prognosis. Therefore, clinical findings reflective of disease activity may help in estimating prognosis.

We previously reported that choroidal structure can be quantified by dividing the total choroidal area on enhanced depth imaging optical coherence tomographic (EDI-OCT) image into luminal and stromal areas by binarisation processing,^{3–13} and this method is now used for clinical studies.^{14–16}

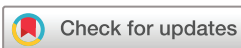Our studies also indicated that changes in choroidal structure are strongly associated with the pathogenesis of retinochoroidal disorders, such as central serous chorioretinopathy and Vogt-Koyanagi-Harada disease, as well as with disease activity, response to therapy and prognosis.^{3 5 6 8 9 11 13} Therefore, the changes in choroidal structure have been found to be crucial information in actual clinical settings.

Studies using EDI-OCT have revealed choroidal thickening associated with macular oedema in both patients with branch RVO (BRVO) and central RVO (CRVO) before treatment, and subsequent choroidal thinning after anti-VEGF therapy; furthermore, choroidal thickness before treatment was correlated with response to therapy and prognosis.^{17–22} However, to the best of our knowledge, the changes in choroidal structure, such as the relative luminal and stromal areas on EDI-OCT images, after anti-VEGF treatment for RVO, have not been documented previously. These changes may help to elucidate pathogenic mechanisms and provide useful information for disease severity, treatment response and prognosis. Therefore, we quantified choroidal luminal and stromal areas before and after intravitreal aflibercept (IVA) injection for RVO and explored the relationships with other clinical parameters, including retinal thickness and visual function.

MATERIALS AND METHODS

This retrospective study evaluated 40 consecutive untreated patients of macular oedema associated with acute-onset RVO who had received IVA injections at the Tokushima University Hospital from August 2015 to July 2019. Acute-onset RVO was defined as RVO with a period from the onset to the start of treatment within 4 months. All patients with acute-onset RVO during this time period were included regardless of ischaemic or non-ischaemic RVO and VA level. Exclusion criteria were intense myopia, defined as an axial length of 26.0 mm or more or a refractive error of -6.0 D or more, other eye diseases that could affect clinical findings, low EDI-OCT image quality defined as an image quality index of <27 and systemic diseases (except controlled hypertension). Additionally, patients receiving treatment for RVO and macular oedema other than IVA injections, such as focal/grid laser photocoagulation, panretinal photocoagulation and intravitreal or sub-Tenon injections of corticosteroids, were also excluded.

VA examination, measurement of average macula thickness within the central 1 mm (termed central retinal thickness, CRT) by 3D-OCT and imaging of the choroid by EDI-OCT were performed just



© Author(s) (or their employer(s)) 2021. Re-use permitted under CC BY-NC. No commercial re-use. See rights and permissions. Published by BMJ.

To cite: Mitamura Y, Enkhmaa T, Sano H, et al. *Br J Ophthalmol* 2021;**105**:704–710.

before the first IVA, and 1, 3 and 6 months after treatment. Similar tests were performed on the 40 untreated healthy fellow eyes. The VA was measured with a standard Japanese Landolt VA chart, corrected on the basis of results of subjective and objective refraction test and converted into the logarithm of the minimal angle resolution (logMAR) units. Prior to study commencement, the research methods were approved by the Institutional Review Board of the Tokushima University Hospital, and informed consent was obtained from all patients. This study was conducted in accordance with the tenets of the Declaration of Helsinki.

The treatment protocol was based on pro re nata therapy. All RVO eyes received two consecutive IVA injections (2.0 mg) separated by 1 month as initial treatment followed by monthly visits, with additional injections if VA worsened by >0.2 logMAR units or OCT images revealed subretinal fluid or macular oedema.

Optical coherence tomography

All eyes were examined using the Heidelberg Spectralis OCT system (Heidelberg Engineering, Heidelberg, Germany). The

OCT examinations were performed with the eye tracking system and follow-up mode turned on. Horizontal and vertical EDI-OCT scans centred on the fovea were performed in the area of 30°, and 100 scans were averaged for improving the signal-to-noise ratio. Central choroidal thickness was measured manually using the Caliper function of the OCT device by two masked examiners. We have previously reported that choroidal structures exhibit diurnal variations,¹² so all EDI-OCT scans were performed between 9:00 and 12:00.

Analyses of choroidal structure

The Niblack application in ImageJ version 1.47 (NIH, Bethesda, Maryland, USA) was used to binarise the horizontal and vertical EDI-OCT scans of each patient eye (figure 1). Luminal, stromal and total choroidal areas from binarised images were measured, as previously reported.^{3–13} Two independent examiners blinded to clinical data performed binarisation three times for each horizontal and vertical scan, and these two sets of six measurements were averaged to obtain the luminal, stromal and total choroidal areas for analyses.

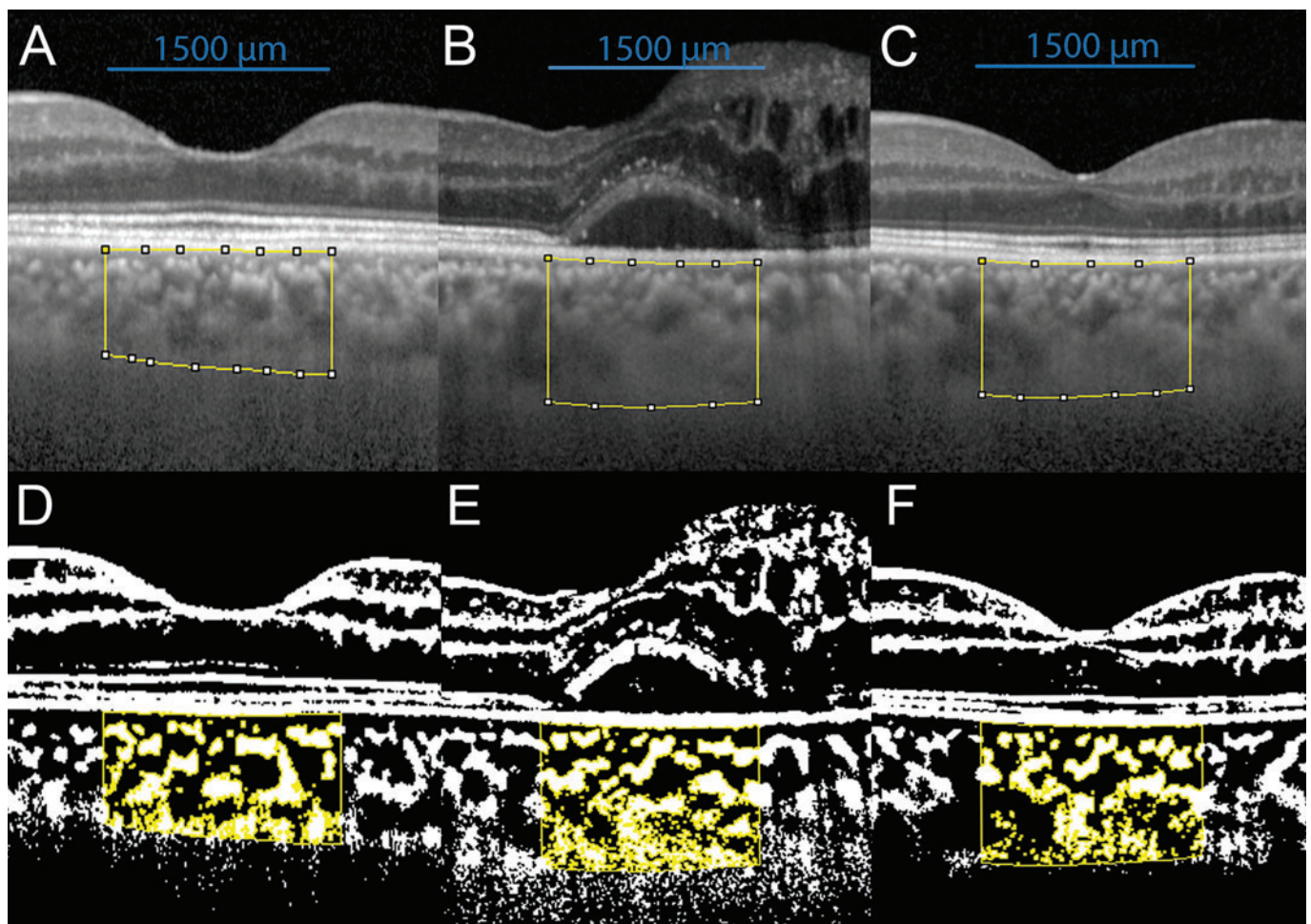


Figure 1 Representative enhanced depth imaging optical coherence tomographic (EDI-OCT) images and converted binary images from a patient with branch retinal vein occlusion. EDI-OCT images through the fovea were converted to binary images using ImageJ. Visual acuity of the affected eye was 0.9 at baseline and 1.2 at 3 months after aflibercept therapy. (A–C) EDI-OCT images of the healthy fellow eye (A), the treated eye at baseline (B) and the treated eye at 3 months after aflibercept therapy (C). The luminal area and the stromal area can be distinguished as dark and light regions, respectively. The examined area was a 1500 µm-wide span of subfoveal choroid extending from the choroid–scleral junction to Bruch’s membrane (defined by yellow lines). (D–F) The converted binary images of the EDI-OCT images shown in A (D), B (E) and C (F). Light regions are stromal areas and dark regions are luminal areas. Yellow lines indicate the margins of traced areas. Note that the stromal area of the affected eye is elevated at baseline compared to the healthy fellow eye, but is reduced after aflibercept therapy.

Table 1 Baseline clinical data of patients with retinal vein occlusion

	Mean±SD	Range
Age (years)	69.9±10.8	41–88
Sex	20 men/20 women	
Type of RVO (central/major branch/ macular branch)	10/18/12	
Hypertension (+/–)	25/15	
Refractive error (dioptres)	–1.050±2.831	–5.250–2.500
Visual acuity (logMAR units (Snellen equivalents))	0.435±0.368 (20/54)	–0.176–1.398
Axial length (mm)	24.18±1.52	22.03–25.12
CRT (µm)	580.5±191.7	334.0–1155.0
Number of IVA injections	3.1±0.9	2–5
Recurrence (+/–)	17/23	

The number of IVA injections was defined as total injections during the 6 months of follow-up from the baseline.

CRT, central retinal thickness; IVA, intravitreal aflibercept; logMAR, logarithm of the minimum angle of resolution; RVO, retinal vein occlusion.

Examined choroidal areas were set manually using the region of interest (ROI) manager of ImageJ. The ROI was within the horizontal 1500 µm span centred on the fovea and from the choroid–scleral junction to Bruch's membrane. The three choroidal vessel lumens exceeding 100 µm in diameter were selected using the Oval Selection Tool on the ImageJ toolbar, and the mean reflectivity of these three areas was calculated. To minimise noise for area measurements, this reflectivity value was set as the cut-off minimum on each EDI-OCT image. Next, the image was converted to 8 bits and binarised using the Niblack Auto Local Threshold function. The binarised image was reconverted to an RGB image, and the luminal region was determined using the Threshold Tool. Light pixels were analysed as stromal regions and dark pixels as luminal regions. After entering data on the relationship between the pixel pitch of the original EDI-OCT image and the actual fundus distance, the luminal, stromal and total choroidal areas were automatically calculated by the software. The stromal area to total choroidal area (S/C) ratio was also calculated.

This method of choroidal structure analysis has been shown in our previous research to have high reproducibility and repeatability in normal eyes and eyes suffering from various retinochoroidal diseases,^{3 5 7–13} and reproducibility and repeatability were reconfirmed for the patient eyes of the present study.

Statistical analyses

The reproducibility of the pretreatment measurement results was confirmed by calculating the intrarater and inter-rater correlation coefficients using a one-way random effects model. VA, CRT and choroidal parameters (luminal, stromal and total choroidal areas and S/C ratio) were compared among measurement time points (before and 1, 3 and 6 months after treatment) by repeated-measures analysis of variance with Greenhouse-Geisser correction. In cases showing a significant fluctuation, each post-treatment value was compared to the baseline value by the Bonferroni test. Paired samples were compared by t-test.

When comparing parameters related to the choroidal structure between individuals, the effects of axial length, age and gender are strongly seen.^{4 6} Therefore, associations between clinical findings and choroidal measurement parameters were evaluated by Pearson's correlations and also partial correlation analyses correcting for axial length, age and sex. Multivariate regression analyses were performed to determine the parameters that were significantly

correlated with CRT improvement. A $p < 0.050$ (two-tailed) was considered significant for all tests.

RESULTS

Table 1 summarises the clinical findings of all patients. Of the 40 RVO eyes enrolled, 10 had CRVO and remaining 30 had BRVO. No eye was excluded because of low image quality. During the 6-month observation period, 17 of the 40 RVO eyes exhibited recurrence, defined as the reappearance of subretinal fluid or intraretinal oedema on OCT images after the persistence of dry macula without IVA injections for at least 1 month. The intrarater agreement was extremely high for both baseline luminal and stromal areas, as indicated by intraclass correlation coefficients of 0.999 (both $p < 0.001$). The inter-rater agreement was also high for both baseline luminal and stromal areas, as indicated by intraclass correlation coefficients of 0.930 and 0.924, respectively (both $p < 0.001$).

Choroidal parameters at baseline

Compared to unaffected eyes, affected eyes at baseline demonstrated significantly greater total choroidal area ($p = 0.001$), stromal area ($p < 0.001$), S/C ratio ($p < 0.001$) and central choroidal thickness ($p = 0.007$), while the luminal area did not differ ($p = 0.083$) (**figure 2**).

Changes in choroidal parameters after intravitreal aflibercept injections

There were significant fluctuations in total choroidal area ($p < 0.001$), luminal area ($p = 0.009$), stromal area ($p < 0.001$) and S/C ratio ($p < 0.001$) following IVA injections (**figure 2**), and pairwise comparisons between baseline and each post-treatment time point (1, 3 and 6 months) revealed significant decreases in total choroidal area ($p < 0.001$, $p = 0.005$, $p < 0.001$, respectively), stromal area (all $p < 0.001$) and S/C ratio (all $p < 0.001$). Conversely, luminal area was not significantly reduced ($p = 0.067$, $p = 0.652$, $p = 0.051$, respectively). Further, stromal area and S/C ratio returned almost to the levels of the healthy fellow eyes after the treatment.

Correlation between baseline choroidal structure and clinical findings

Baseline S/C ratio was significantly correlated with baseline CRT and baseline VA ($r = 0.516$, $p < 0.001$; $r = 0.433$, $p = 0.005$, respectively; **table 2**; **figure 3**). In partial correlation analysis adjusted for axial length, age and sex, S/C ratio was still significantly associated with baseline CRT and VA ($rp = 0.488$, $p = 0.002$; $rp = 0.413$, $p = 0.011$, respectively), although the rp values were only showing a relatively weak correlation.

The CRT was significantly improved after IVA injections, from 580.5 ± 191.7 µm (mean ± SD) at baseline to 312.4 ± 89.2 µm at 1 month, 300.1 ± 75.7 µm at 3 months and 356.3 ± 122.0 µm at 6 months (all $p < 0.001$). The baseline S/C ratio was significantly correlated with CRT improvement, defined as baseline minus post-IVA value, at 1 month ($r = 0.554$, $p < 0.001$), 3 months ($r = 0.610$, $p < 0.001$; **figure 3**) and 6 months ($r = 0.465$, $p = 0.002$). Thus, higher baseline S/C ratio predicted a greater decrease in CRT following treatment. In partial correlation analysis adjusted for axial length, age and sex, S/C ratio was still significantly correlated with CRT improvement at 1 month ($rp = 0.519$, $p = 0.001$), 3 months ($rp = 0.582$, $p < 0.001$) and 6 months ($rp = 0.443$, $p = 0.006$).

The VA was also significantly improved after IVA injections, from 0.435 ± 0.368 in logMAR units (20/54 Snellen equivalents) at baseline to 0.189 ± 0.268 (20/31) at 1 month, 0.113 ± 0.229

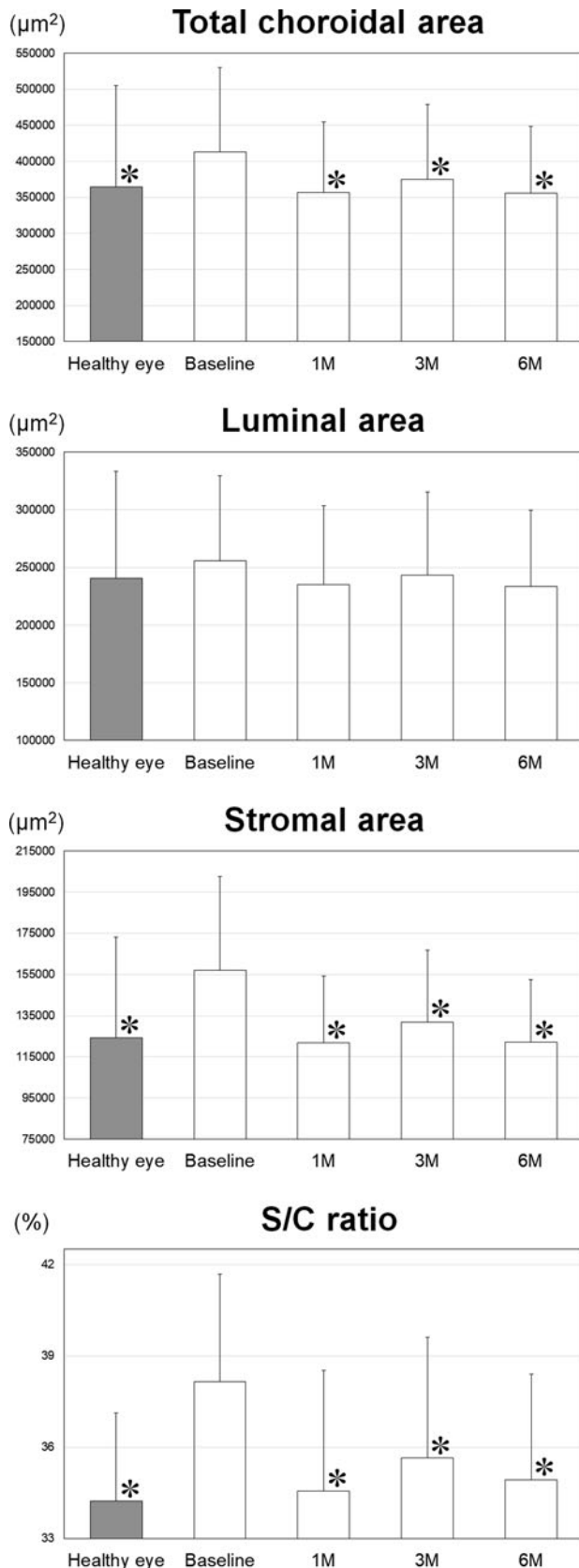


Figure 2 Total choroidal, luminal and stromal areas and stromal area to total choroidal area (S/C) ratio at baseline and 1, 3 and 6 months after intravitreal aflibercept (IVA) injections. At baseline, the affected eyes show significantly greater total choroidal area ($p=0.001$), stromal area ($p<0.001$) and S/C ratio ($p<0.001$) but no difference in luminal area ($p=0.083$) compared to the contralateral healthy eye. After IVA injections, repeated-

(20/26) at 3 months and 0.146 ± 0.271 (20/28) at 6 months (all $p<0.001$). The baseline S/C ratio was significantly correlated with VA improvement at 1 month ($r=0.455$, $p=0.003$), 3 months ($r=0.513$, $p<0.001$; figure 3) and 6 months ($r=0.447$, $p=0.004$). After correcting for axial length, age and sex, these correlations were still significant (1 month: $r_p=0.417$, $p=0.010$; 3 months: $r_p=0.484$, $p=0.002$; 6 months: $r_p=0.425$, $p=0.009$). The stromal area and total choroidal area were not significantly correlated with the clinical outcomes (ie, baseline value and improvement of CRT and VA) (table 2).

Considering each of the three subtypes of RVO, p values worsened in all correlations of the baseline S/C ratio with the clinical outcomes in all subtypes (online supplementary materials). Conversely, correlation coefficients were improved in most correlations. All correlations of the baseline stromal area and total choroidal area with the clinical outcomes in each of all subtypes were not significant.

The baseline S/C ratio was not significantly associated with recurrence ($p=0.367$) and not correlated with the number of IVA injections during the 6-month observation period ($r=0.166$, $p=0.309$). The number of IVA injections was also not significantly correlated with CRT or VA improvement (all $|r|<0.200$, $p>0.219$). Baseline central choroidal thickness was not significantly correlated with baseline CRT, baseline VA, CRT improvement or VA improvement (all $|r|<0.089$, all $p>0.589$).

The baseline CRT was significantly correlated with CRT improvement at 1, 3 and 6 months (all $|r|>0.841$, $p<0.001$). Multivariate regression analyses including the baseline CRT and S/C ratio as explanatory variables were performed. The CRT improvement at 1 and 6 months was significantly correlated with only the baseline CRT (both $p<0.001$). The CRT improvement at 3 months was significantly correlated with both the baseline CRT ($p<0.001$) and S/C ratio ($p=0.010$).

DISCUSSION

Several studies have measured choroidal thickness after anti-VEGF therapy for RVO-associated macular oedema,^{17–21} but none have examined changes in choroidal structure. In this study, we found that the increase in choroidal thickness was due mainly to expansion of the stromal region rather than the luminal region, and this expansion of the stromal region indicates choroidal stromal oedema.

The primary area affected by RVO is the retina, and the changes in choroidal structure revealed in this study are likely to be secondary changes due to the underlying retinal disease. We speculate that VEGF produced in response to retinal

Figure 2 Continued

measures analysis of variance reveals a significant fluctuation in total choroidal area ($p<0.001$), luminal area ($p=0.009$), stromal area ($p<0.001$) and S/C ratio ($p<0.001$). Pairwise comparisons indicate significant decreases at 1, 3 and 6 months in total choroidal area ($p<0.001$, $p=0.005$, $p<0.001$, respectively), stromal area (all $p<0.001$) and S/C ratio (all $p<0.001$). In contrast, the luminal area is not significantly reduced compared to baseline ($p=0.067$, $p=0.652$, $p=0.051$, respectively). Further, stromal area and S/C ratio return almost to the levels of the healthy fellow eyes after the treatment. The asterisks indicate significant differences from baseline values in the affected eyes. Bars indicate SD.

Table 2 Correlations of baseline choroidal structure with central retinal thickness and visual acuity

	Stromal area to total choroidal area ratio		Stromal area	Total choroidal area
	Simple regression analysis	Partial correlation analysis (adjusted by axial length, age and sex)	Simple regression analysis	Simple regression analysis
Baseline CRT (μm)	$r=0.516$ $p<0.001$	$r_p=0.488$ $p=0.002$	$r=0.119$ $p=0.468$	$r=-0.015$ $p=0.925$
CRT improvement at 1 month	$r=0.554$ $p<0.001$	$r_p=0.519$ $p=0.001$	$r=0.170$ $p=0.297$	$r=0.031$ $p=0.852$
CRT improvement at 3 months	$r=0.610$ $p<0.001$	$r_p=0.582$ $p<0.001$	$r=0.172$ $p=0.292$	$r=0.013$ $p=0.935$
CRT improvement at 6 months	$r=0.465$ $p=0.002$	$r_p=0.443$ $p=0.006$	$r=0.075$ $p=0.650$	$r=-0.044$ $p=0.791$
Baseline VA (logMAR units)	$r=0.433$ $p=0.005$	$r_p=0.413$ $p=0.011$	$r=0.003$ $p=0.987$	$r=-0.093$ $p=0.570$
VA improvement at 1 month	$r=0.455$ $p=0.003$	$r_p=0.417$ $p=0.010$	$r=0.174$ $p=0.285$	$r=0.080$ $p=0.627$
VA improvement at 3 months	$r=0.513$ $p<0.001$	$r_p=0.484$ $p=0.002$	$r=0.133$ $p=0.417$	$r=0.023$ $p=0.889$
VA improvement at 6 months	$r=0.447$ $p=0.004$	$r_p=0.425$ $p=0.009$	$r=0.049$ $p=0.766$	$r=-0.054$ $p=0.741$

VA or CRT improvement is defined as baseline value minus post-treatment value.

CRT, central retinal thickness; logMAR, logarithm of the minimum angle of resolution; r_p , partial correlation coefficient; VA, visual acuity.

ischaemia in the region of RVO translocates to the choroid and increases leakage from choroidal blood vessels,^{19 23 24} resulting in oedema of the choroidal stroma. Indeed, several studies to date have also speculated that VEGF produced in the retina causes choroidal thickening,^{17 20} and we show that choroidal stromal oedema is normalised by anti-VEGF therapy. Moreover, IVA injection in monkeys significantly reduced the number of choriocapillaris endothelial cell fenestrations.²⁵ It can be inferred that leakage through such fenestrated vascular walls was reduced by anti-VEGF therapy, thereby reducing swelling of the choroidal stroma. In fact, anti-VEGF therapy has been reported to induce choroidal thinning, not only in RVO but also in other retinal vascular diseases such as diabetic macular oedema.^{17 26 27}

Although increased choroidal thickness has been reported in eyes with macular oedema due to acute-onset RVO,^{17 18 20 28 29} no such increase was found in eyes with longstanding RVO and no macular oedema in the Beijing Eye Study.³⁰ However, intraocular VEGF concentration is presumed not to increase substantially in such longstanding cases without macular oedema,³¹ again consistent with the idea that excessive VEGF signalling underlies choroidal oedema and concomitant thickening. Previous reports have also suggested that an increase in intraocular VEGF concentration stimulates the production of nitric oxide, which then dilates choroidal vessels and leads to thickening of the choroid.^{21 28 32} However, there was no significant increase in choroidal luminal area in RVO-afflicted eyes prior to anti-VEGF treatment in the present study, so this pathway does not appear relevant to choroidal thickening in acute-onset RVO. However, the reason why increased intraocular VEGF in RVO-afflicted eyes leads to the choroidal stromal oedema but not vascular enlargement remains unknown.

Oedema of the choroidal stroma appears to occur specifically in RVO with macular oedema, which is distinct from other retinal diseases. In central serous chorioretinopathy, only the luminal region is increased throughout the entire choroid,^{5 11} while in diabetic retinopathy, both the luminal region and stromal region are increased in association with disease progression and macular oedema.^{6 33} It is known that both the luminal and stromal regions

are decreased in eyes with retinitis pigmentosa.⁸ Therefore, choroidal stromal expansion alone appears to be a unique sign of RVO.

If RVO-associated stromal oedema of choroid is triggered primarily by VEGF production in response to retinal ischaemia, increase of stromal area in addition to choroidal thickness on EDI-OCT images may provide an objective scale of RVO disease activity. Consistent with this notion, pretreatment S/C ratio was significantly correlated with both pretreatment retinal thickness and reduction after treatment, even when adjusted for axial length, age and sex. Pretreatment S/C ratio was also associated with pretreatment VA and post-treatment visual improvement even when adjusted for axial length, age and sex.

In the present study, the number of IVAs during the follow-up period did not correlate with post-treatment visual improvement as well as improvement of retinal thickness. The choroidal structure is considered to be superior to the number of treatments as an index that reflects the disease activity and treatment prognosis of macular oedema associated with RVO. However, the baseline S/C ratio was inferior to the baseline retinal thickness for predicting the post-treatment improvement of retinal thickness. In contrast to previous reports, choroidal thickness did not correlate with pretreatment retinal thickness, pretreatment VA or improvement of these parameters after treatment in the present study. In these previous studies, however, the correlation of choroidal thickness with visual prognosis found in univariable analyses did not remain significant in multivariable regression analysis.^{17 18} The results of this study suggested that S/C ratio is a more sensitive predictor of treatment response than choroidal thickness, underscoring the importance of analysing choroidal structure rather than gross morphology.

Rayess *et al* proposed two hypotheses for the better prognosis of eyes with thickened choroid before treatment.¹⁸ First, such eyes may maintain greater choroidal circulation to supply the outer retina, increasing the possibility of good visual outcome after treatment for macular oedema. Conversely, it was speculated that eyes with thinning choroid may have some circulatory failure in the choroid and not enough nutritional supply for outer retina. Second, high VEGF may be the primary aetiology of thickened choroid. Conversely, intraocular VEGF concentration may be relatively lower in eyes with thinner choroid, while other

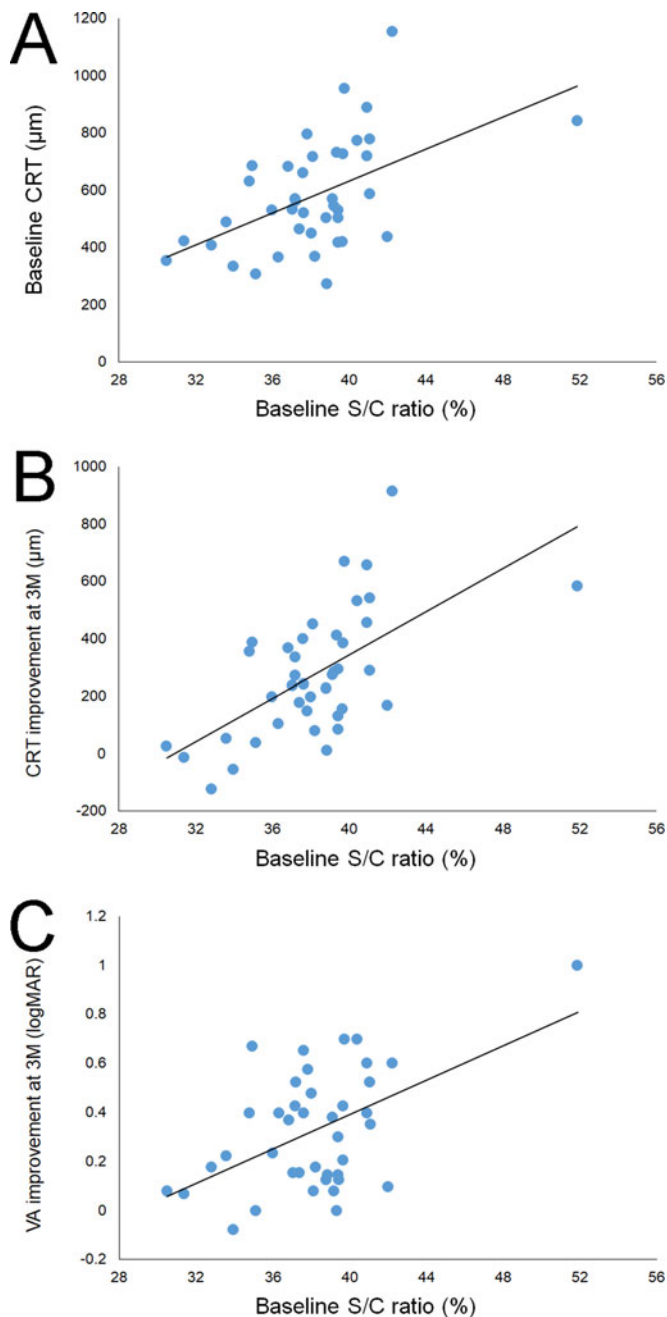


Figure 3 Correlations of baseline stromal area to total choroidal area (S/C) ratio with (A) baseline central retinal thickness (CRT), (B) post-treatment improvement in CRT and (C) post-treatment improvement in visual acuity (VA). (A) Baseline S/C ratio is significantly correlated with baseline CRT ($r=0.516$, $p<0.001$). The solid line represents the best fit linear regression line ($y=27.935x - 485.043$). (B) Baseline S/C ratio is significantly correlated with CRT improvement (baseline minus post-treatment) at 3 months ($r=0.610$, $p<0.001$). The solid line represents the best fit linear regression line ($y=37.595x-1159.532$). (C) Baseline S/C ratio is significantly correlated with VA improvement (baseline minus post-treatment) at 3 months ($r=0.513$, $p<0.001$). The VA is expressed in logarithm of the minimum angle of resolution (logMAR) units. The solid line represents the best fit linear regression line ($y=0.035x-1.009$).

factors not targeted by anti-VEGF treatment such as pro-inflammatory cytokines may contribute to the development of macular oedema. However, it is not possible to determine which hypothesis is more certain from the results of the present study.

The limitations of this study include the retrospective design, small sample size, no usage of the Early Treatment Diabetic Retinopathy Study charts in the VA examination and limited follow-up period. Additionally, both CRVO and BRVO patients were included in the study. Considering each of the subtypes of RVO, correlation coefficients were improved in most correlations between the choroidal structure and clinical findings in the present study. Therefore, a study examining the choroidal structure in a large number of patients with each subtype of RVO will be necessary. Finally, subjective factors may have influenced manual tracing of the choroid–scleral junction for area measurement, although we report high intrarater and inter-rater reproducibility.

In conclusion, the choroidal stromal area instead of the luminal area increased in eyes with macular oedema associated with RVO and decreased after anti-VEGF therapy. This result suggests that the greater choroidal thickness in eyes with RVO is due to stromal oedema originating from high intraocular VEGF levels rather than vessel dilation. The pretreatment relative increase of stromal area was significantly correlated with the pretreatment retinal oedema, pretreatment VA, and improvement of retinal oedema and VA after anti-VEGF therapy even when adjusted for axial length, age and sex. Taken together, these changes in the choroidal structure may be useful to quantify the activity of RVO and predict the efficacy of anti-VEGF therapy.

Contributors All authors have given final approval of this version to be published. YM, SS, TS designed the study; YM, TE, HS, MN, FM, ME conducted the study; YM, TE, HS, MN, FM managed the data; YM, TE, ME, SS analysed the data; YM, TE, SS, TS interpreted the data; YM and TE prepared the manuscript; and YM and TS did overall coordination.

Funding This work was supported in part by grant-in-aid 19K09951 (to YM) from the Ministry of Education, Science, Sports and Culture, Japan.

Competing interests None declared.

Patient consent Obtained.

Ethics approval The Institutional Review Board of Tokushima University Hospital.

Provenance and peer review Not commissioned; externally peer reviewed.

Data sharing statement Data are available from the corresponding author upon reasonable request.

Open access This is an open access article distributed in accordance with the Creative Commons Attribution Non Commercial (CC BY-NC 4.0) license, which permits others to distribute, remix, adapt, build upon this work non-commercially, and license their derivative works on different terms, provided the original work is properly cited, appropriate credit is given, any changes made indicated, and the use is non-commercial. See: <http://creativecommons.org/licenses/by-nc/4.0/>

ORCID iDs

Yoshinori Mitamura <http://orcid.org/0000-0002-4813-672X>
Taiji Sakamoto <http://orcid.org/0000-0003-0287-3801>

REFERENCES

- Brown DM, Campochiaro PA, Bhisitkul RB, *et al*. Sustained benefits from ranibizumab for macular edema following branch retinal vein occlusion: 12-month outcomes of a phase III study. *Ophthalmology* 2011;118:1594–602.
- Campochiaro PA, Brown DM, Awh CC, *et al*. Sustained benefits from ranibizumab for macular edema following central retinal vein occlusion: twelve-month outcomes of a phase III study. *Ophthalmology* 2011;118:2041–9.
- Sonoda S, Sakamoto T, Yamashita T, *et al*. Choroidal structure in normal eyes and after photodynamic therapy determined by binarization of optical coherence tomographic images. *Invest Ophthalmol Vis Sci* 2014;55:3893–9.
- Sonoda S, Sakamoto T, Yamashita T, *et al*. Luminal and stromal areas of choroid determined by binarization method of optical coherence tomographic images. *Am J Ophthalmol* 2015;159:1123–31.
- Sonoda S, Sakamoto T, Kuroiwa N, *et al*. Structural changes of inner and outer choroid in central serous chorioretinopathy determined by optical coherence tomography. *PLoS One* 2016;11:e0157190.

- 6 Kinoshita T, Imaizumi H, Shimizu M, *et al.* Systemic and ocular determinants of choroidal structures on optical coherence tomography of eyes with diabetes and diabetic retinopathy. *Sci Rep* 2019;9:16228.
- 7 Nagasato D, Mitamura Y, Egawa M, *et al.* Changes of choroidal structure and circulation after water drinking test in normal eyes. *Graefes Arch Clin Exp Ophthalmol* 2019;257:2391–9.
- 8 Egawa M, Mitamura Y, Niki M, *et al.* Correlations between choroidal structures and visual functions in eyes with retinitis pigmentosa. *Retina* 2019;39:2399–409.
- 9 Daizumoto E, Mitamura Y, Sano H, *et al.* Changes of choroidal structure after intravitreal aflibercept therapy for polypoidal choroidal vasculopathy. *Br J Ophthalmol* 2017;101:56–61.
- 10 Kinoshita T, Mori J, Okuda N, *et al.* Effects of exercise on the structure and circulation of choroid in normal eyes. *PLoS One* 2016;11:e0168336.
- 11 Kinoshita T, Mitamura Y, Akaiwa K, *et al.* Changes in choroidal structures in eyes with chronic central serous chorioretinopathy after half-dose photodynamic therapy. *PLoS One* 2016;11:e0163104.
- 12 Kinoshita T, Mitamura Y, Shinomiya K, *et al.* Diurnal variations in luminal and stromal areas of choroid in normal eyes. *Br J Ophthalmol* 2017;101:360–4.
- 13 Egawa M, Mitamura Y, Akaiwa K, *et al.* Changes of choroidal structure after corticosteroid treatment in eyes with Vogt-Koyanagi-Harada disease. *Br J Ophthalmol* 2016;100:1646–50.
- 14 Agrawal R, Gupta P, Tan KA, *et al.* Choroidal vascularity index as a measure of vascular status of the choroid: measurements in healthy eyes from a population-based study. *Sci Rep* 2016;6:21090.
- 15 Corvi F, Souied EH, Capuano V, *et al.* Choroidal structure in eyes with drusen and reticular pseudodrusen determined by binarisation of optical coherence tomographic images. *Br J Ophthalmol* 2017;101:348–52.
- 16 Giannaccare G, Pellegrini M, Sebastiani S, *et al.* Choroidal vascularity index quantification in geographic atrophy using binarization of enhanced-depth imaging optical coherence tomographic scans. *Retina* 2019;
- 17 Rayess N, Rahimy E, Ying GS, *et al.* Baseline choroidal thickness as a predictor for treatment outcomes in central retinal vein occlusion. *Am J Ophthalmol* 2016;171:47–52.
- 18 Rayess N, Rahimy E, Ying GS, *et al.* Baseline choroidal thickness as a short-term predictor of visual acuity improvement following anti-vascular endothelial growth factor therapy in branch retinal vein occlusion. *Br J Ophthalmol* 2019;103:55–9.
- 19 Hasegawa T, Kawano T, Maruko I, *et al.* Clinical findings of eyes with macular edema associated with branch retinal vein occlusion refractory to ranibizumab. *Retina* 2018;38:1347–53.
- 20 Okamoto M, Yamashita M, Sakamoto T, *et al.* Choroidal blood flow and thickness as predictors for response to anti-vascular endothelial growth factor therapy in macular edema secondary to branch retinal vein occlusion. *Retina* 2018;38:550–8.
- 21 Lee EK, Han JM, Hyon JY, *et al.* Changes in choroidal thickness after intravitreal dexamethasone implant injection in retinal vein occlusion. *Br J Ophthalmol* 2015;99:1543–9.
- 22 Shin YU, Lee MJ, Lee BR. Choroidal maps in different types of macular edema in branch retinal vein occlusion using swept-source optical coherence tomography. *Am J Ophthalmol* 2015;160:328–34.
- 23 Tilton RG, Chang KC, LeJeune WS, *et al.* Role for nitric oxide in the hyperpermeability and hemodynamic changes induced by intravenous VEGF. *Invest Ophthalmol Vis Sci* 1999;40:689–96.
- 24 Noma H, Funatsu H, Yamasaki M, *et al.* Pathogenesis of macular edema with branch retinal vein occlusion and intraocular levels of vascular endothelial growth factor and interleukin-6. *Am J Ophthalmol* 2005;140:256–61.
- 25 Julien S, Biesemeier A, Taubitz T, *et al.* Different effects of intravitreally injected ranibizumab and aflibercept on retinal and choroidal tissues of monkey eyes. *Br J Ophthalmol* 2014;98:813–25.
- 26 Kang HM, Kwon HJ, Yi JH, *et al.* Subfoveal choroidal thickness as a potential predictor of visual outcome and treatment response after intravitreal ranibizumab injections for typical exudative age-related macular degeneration. *Am J Ophthalmol* 2014;157:1013–21.
- 27 Rayess N, Rahimy E, Ying GS, *et al.* Baseline choroidal thickness as a predictor for response to anti-vascular endothelial growth factor therapy in diabetic macular edema. *Am J Ophthalmol* 2015;159:85–91.
- 28 Esen E, Sizmaz S, Demircan N. Choroidal thickness changes after intravitreal dexamethasone implant injection for the treatment of macular edema due to retinal vein occlusion. *Retina* 2016;36:2297–303.
- 29 Tsuiki E, Suzuma K, Ueki R, *et al.* Enhanced depth imaging optical coherence tomography of the choroid in central retinal vein occlusion. *Am J Ophthalmol* 2013;156:543–7.
- 30 Du KF, Xu L, Shao L, *et al.* Subfoveal choroidal thickness in retinal vein occlusion. *Ophthalmology* 2013;120:2749–50.
- 31 Noma H, Minamoto A, Funatsu H, *et al.* Intravitreal levels of vascular endothelial growth factor and interleukin-6 are correlated with macular edema in branch retinal vein occlusion. *Graefes Arch Clin Exp Ophthalmol* 2006;244:309–15.
- 32 Mrejen S, Spaide RF. Optical coherence tomography: imaging of the choroid and beyond. *Surv Ophthalmol* 2013;58:387–429.
- 33 Kase S, Endo H, Takahashi M, *et al.* Alteration of choroidal vascular structure in diabetic macular edema. *Graefes Arch Clin Exp Ophthalmol*