

# Surgical Orthodontic Treatment of Skeletal Mandibular Protrusion with Multiple Impacted Ankylosed Teeth Treated with Alveolar Corticotomy

Toyoaki Takagi<sup>1</sup>, So Shimizu<sup>2</sup>, Eiji Tanaka<sup>3</sup>

## ABSTRACT

**Aim:** To present a case of skeletal mandibular protrusion with multiple impacted ankylosed teeth, which were treated with conventional orthognathic surgery and alveolar corticotomy, respectively.

**Background:** Tooth ankylosis is characterized by the fusion of a root surface with the surrounding alveolar bone. Various treatment modalities for tooth ankylosis have been developed and are used commonly in the clinic. Corticotomy is defined as the application of intentional surgical injury to the cortical bone to mobilize a tooth with the adjacent bone and soft tissues. The corticotomy technique has been improved in recent years to avoid possible risks such as periodontal damage, tooth devitalization, and osseous necrosis due to an inadequate blood supply.

**Case description:** A female patient aged 16 years and 3 months was diagnosed with anterior crossbite and the impaction and ankylosis of multiple canines. After the confirmation of ankylosis, alveolar corticotomy was performed on the maxillary left and mandibular right canines. After 6 months of traction (patient age, 19 years and 7 months), both canines had extruded successfully. After the completion of preoperative treatment, bilateral intraoral vertical ramus osteotomy was performed to correct the anterior crossbite involving a skeletal mandibular protrusion. The amounts of mandibular setback on the right and left sides were approximately 7 and 5 mm, respectively. The total treatment period was 55 months. Acceptable occlusion with a balanced profile was maintained over a 5-year retention period, indicating the long-term stability and success of the treatment.

**Conclusion:** Our results indicate that alveolar corticotomy should be considered to facilitate the treatment of multiple impacted ankylosed teeth.

**Clinical significance:** This report proposes an efficacy of alveolar corticotomy for extrusion of impacted ankylosed teeth.

**Keywords:** Alveolar corticotomy, Multiple ankylosed teeth, Orthognathic surgery, Tooth impaction.

*The Journal of Contemporary Dental Practice* (2021): 10.5005/jp-journals-10024-3071

## INTRODUCTION

The most prevalent dental anomaly is tooth impaction, with approximately 14% of orthodontic patients affected by this condition.<sup>1</sup> The maxillary canine is most often affected, followed by the mandibular canine.<sup>2,3</sup> The etiology of tooth impaction consists of local and systemic factors.<sup>4-6</sup> Adverse effects of the systemic factors can impact treatment time and outcome.<sup>7</sup> Factors reported to extend treatment time include the patient age at the time of treatment initiation, severity of root dilaceration, root formation stage, tooth position and direction, and the distance of the tooth from the occlusal plane.<sup>8-10</sup> Thus, the success of impacted tooth traction depends on these factors. Orthodontists often hesitate to treat impacted teeth, as ankylosis, and root resorption during and/or after tooth traction can increase the potential for failure.<sup>7,11,12</sup>

Tooth ankylosis is characterized by the fusion of a root surface with the surrounding alveolar bone. This condition affects occlusion and esthetics. The majority of proven ankylosis events occur in deciduous molars.<sup>13</sup> Ankylosis of the permanent teeth frequently involves the permanent maxillary incisors after periodontal ligament damage due to local trauma.<sup>14,15</sup> Ankylosis of the permanent canines, premolars, and molars is likely to occur without a traumatic history and appears to be a multifactorial phenomenon, usually of unidentified cause. Regardless of its cause, the treatment of tooth ankylosis is complicated; various treatment modalities have been developed and are used commonly in the clinic.<sup>16-18</sup> In the absence of external root resorption and root

<sup>1</sup>Takagi Orthodontic Clinic, Takarazuka, Hyogo, Japan

<sup>2</sup>Department of Orthodontics and Dentofacial Orthopedics, Tokushima University Graduate School of Oral Sciences, Tokushima, Japan

<sup>3</sup>Department of Orthodontics and Dentofacial Orthopedics, Institute of Biomedical Sciences, Tokushima University Graduate School, Tokushima, Japan

**Corresponding Author:** Eiji Tanaka, Department of Orthodontics and Dentofacial Orthopedics, Institute of Biomedical Sciences, Tokushima University Graduate School, Tokushima, Japan, Phone: +81 88 6337356; Department of Orthodontics, King Abdulaziz University, Jeddah, Kingdom of Saudi Arabia e-mail: etanaka@tokushima-u.ac.jp

**How to cite this article:** Takagi T, Shimizu S, Tanaka E. Surgical Orthodontic Treatment of Skeletal Mandibular Protrusion with Multiple Impacted Ankylosed Teeth Treated with Alveolar Corticotomy. *J Contemp Dent Pract* 2021;22(4):412-421.

**Source of support:** Nil

**Conflict of interest:** None

dilaceration, subluxation and traction of the ankylosed tooth may be suitable. Possible side effects include the loss of vitality and root fracture. In addition, ankylosis may reoccur as the luxation is repaired. Compared with surgical osteotomy and osteodistraction, corticotomy-facilitated orthodontic treatment is less invasive and associated with fewer adverse effects and shorter treatment time.<sup>19</sup> Corticotomy is defined as the application of intentional surgical

injury to the cortical bone to mobilize a tooth with the adjacent bone and soft tissues.<sup>18</sup> The corticotomy technique has been improved in recent years to avoid possible risks such as periodontal damage, tooth devitalization, and osseous necrosis due to an inadequate blood supply. However, to our knowledge, no report of a case in which multiple impacted ankylosed permanent teeth were treated with alveolar corticotomy has been published. Here, we present a case of skeletal mandibular protrusion with multiple impacted ankylosed teeth, which were treated with conventional orthognathic surgery and alveolar corticotomy, respectively.

## CASE DESCRIPTION

A female patient (aged 16 years and 3 months) presented with discomfort due to an anterior crossbite, prolonged retention of deciduous teeth, and delayed eruption of multiple permanent teeth. The patient's medical and dental history included no traumatic injury to the head, neck, or jaw, and no family history of skeletal mandibular protrusion.

The patient's facial profile was concave, and the frontal view was nearly symmetrical (Fig. 1A). The bilateral molar relationships were angle class III (Fig. 1B). The interincisal relationship was characterized by overjet of  $-4.0$  mm and overbite of  $2.0$  mm. The maxillary dental arch form was square. Prolonged retention of the mandibular right first and second deciduous molars and left second deciduous molar was noted. The permanent maxillary left canine, mandibular right canine and first and second premolars, and mandibular left canine and second premolar were unerupted. The maxillary dental midline matched the facial midline, whereas the mandibular dental midline was shifted  $2$  mm to the left of the midline. A panoramic radiograph showed that all of the patient's permanent teeth had short roots and that the alveolar bone level was reduced slightly (Fig. 1D). The maxillary left canine was impacted horizontally. The mandibular right canine and first and second premolars, and left canine and second premolar were also impacted (Fig. 1D). The mandibular right second molar was inclined mesially. Although temporomandibular joint disorders were absent, gingival recession with gingivitis was present in the anterior teeth.

Cephalometric analysis indicated that the patient's skeletal jaw-base relationship was class III (A-point-nasion-B-point angle (ANB),  $-4.2^\circ$ ) relative to the Japanese female norm<sup>20</sup> (Fig. 1C and Table 1). The mandibular plane was acute (Frankfort mandibular plane angle (FMA),  $19.9^\circ$ ). The inclination of maxillary central incisors was within the normal range (U1-SN,  $101.5^\circ$ ), whereas the mandibular central incisors were inclined lingually (L1-Mand. Pl.,  $80.9^\circ$ ), indicating dental compensation.

## Treatment Objectives

The patient was diagnosed with an anterior crossbite, impaction of multiple permanent teeth, a skeletal class III jaw-base relationship, and a low mandibular plane angle. The cause of impaction of six permanent teeth could not be identified; all of these impacted teeth required orthodontic traction to diagnose ankylosis. Thus, the following treatment objectives were established: (1) exposure of the six impacted permanent teeth, (2) correction of the anterior crossbite, and (3) achievement of an adequate overjet and overbite for an acceptable and functional class I occlusion. As the etiology of the anterior crossbite possibly involved the patient's large mandible, we additionally planned to perform bilateral conventional osteotomy. Traction of the six impacted teeth was required to achieve functional class I occlusion; if it failed, alveolar corticotomy was planned upon confirmation of the suspected ankyloses.

## Treatment Alternatives

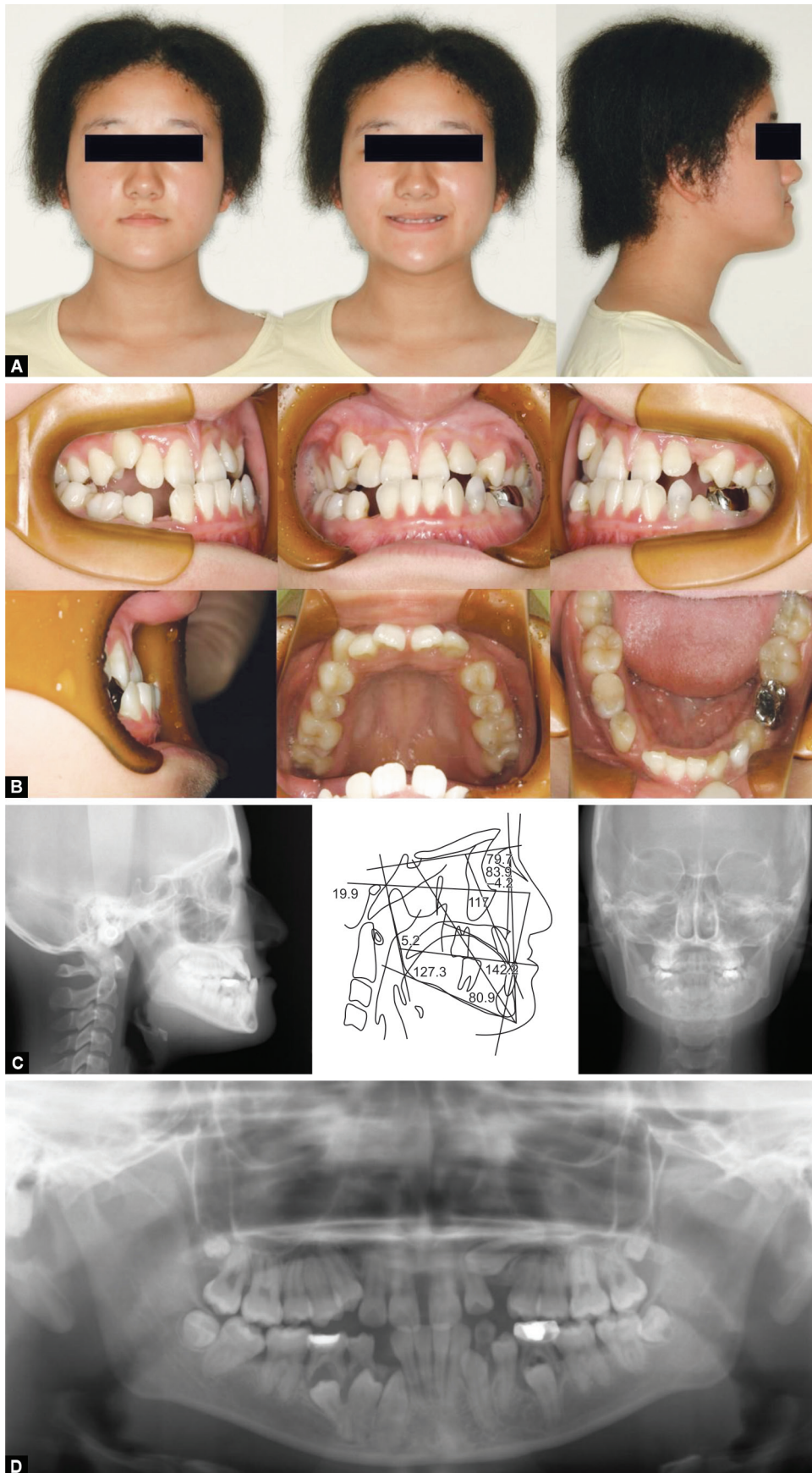
Several surgical procedures for ankylosed teeth, including single tooth osteotomy, surgical luxation, and distraction osteogenesis, were explored. Single tooth osteotomy enables rapid tooth movement with a bony block and is feasible for ankylosed mandibular molars. In performing this procedure, maintenance of the soft tissue pedicle attached to the cortices is essential.<sup>21</sup> When greater movement of the bony block is required, the surgeon should be carefully to avoid stretching of the limited soft tissue, which could lead to gingival recession. Surgical luxation is attempted to break the fusion between the tooth-root surface and the alveolar bone. It is minimally invasive, resulting in less postoperative pain and discomfort but may cause loss of vitality and root fracture. In addition, ankylosis may recur after tooth luxation, resulting in insufficient extrusion of the ankylosed tooth. Distraction osteogenesis may be feasible for the extrusion of the ankylosed tooth. It can induce new bone formation without bone grafting. Moreover, as the tooth in the bony block is distracted gradually, the attached soft tissue can regenerate along with the transported bony segment. However, distraction osteogenesis requires broad flap surgery, associated with a longer healing period and more pain and discomfort than is individual corticotomy. Other disadvantages include the difficulty of placing a large distractor in the mouth and the possibility of nerve and tooth injury, and bone nonunion or poor union.<sup>16,18</sup> In addition, in a split-mouth study of distraction osteogenesis after corticotomy and osteotomy, Hu et al.<sup>22</sup> reported more bone formation and earlier mineralization on the corticotomy side than on the osteotomy side.

Thus, alveolar corticotomy should be attempted before the application of distraction osteogenesis. Alveolar corticotomy is likely to maintain the integrity of the endosteum, bone marrow, and capillary networks. For these reasons, we decided to use individual alveolar corticotomy for the traction of the ankylosed teeth in this case. The patient provided informed consent to this procedure, indicating that she understood that alveolar corticotomy of some of the impacted teeth might be necessary if ankylosis was detected.

To treat skeletal class III malocclusion with severe dentoskeletal discrepancies, surgical orthodontic treatment is recommended. Especially, two-jaw surgery with posterior impaction of the maxilla and setback of the mandible is suitable to correct the labially inclined maxillary incisors, protrusive upper lip, and flat occlusal plane in patients with skeletal class III.<sup>23</sup> When the flat occlusal plane is corrected by posterior impaction of the maxilla, an amount of the mandibular setback increases compared to only setback of the mandible. Taken these into consideration, we recommended the patient to receive two-jaw surgery; however, the patient selected surgical approach to only mandible, intraoral vertical ramus osteotomy (IVRO), to avoid postoperative risks such as neurosensory disturbances and extreme complications such as bleeding, swelling, and infection.

## Treatment Progress

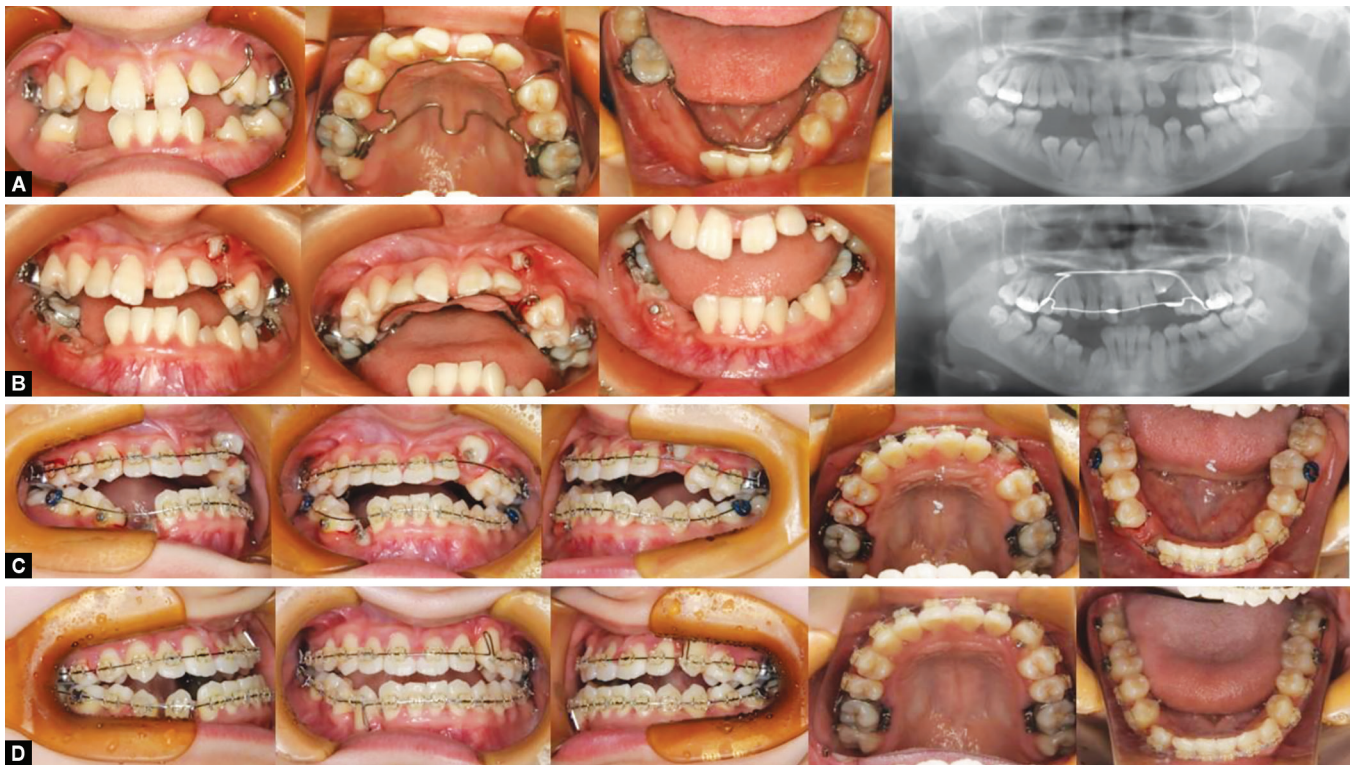To gain space for traction of the maxillary left canine, a rapid expansion appliance was applied to the maxillary dentition. Lateral expansion of the maxilla was initiated at a rate of  $0.5$  mm/day; the total amount of maxillary expansion achieved was  $6.0$  mm. After a 6-month healing period, the rapid expansion appliance was repositioned on the lingual arch (Fig. 2A) and the four retained deciduous teeth were extracted. Thereafter, natural eruption of the impacted mandibular permanent teeth was observed. Three



**Figs 1A to D:** Pretreatment facial (A) and intraoral photographs (B), frontal and lateral cephalograms, cephalometric tracing (C), and panoramic radiograph (D) (patient age, 16 years and 3 months)

**Table 1:** Summary of cephalometric analyses

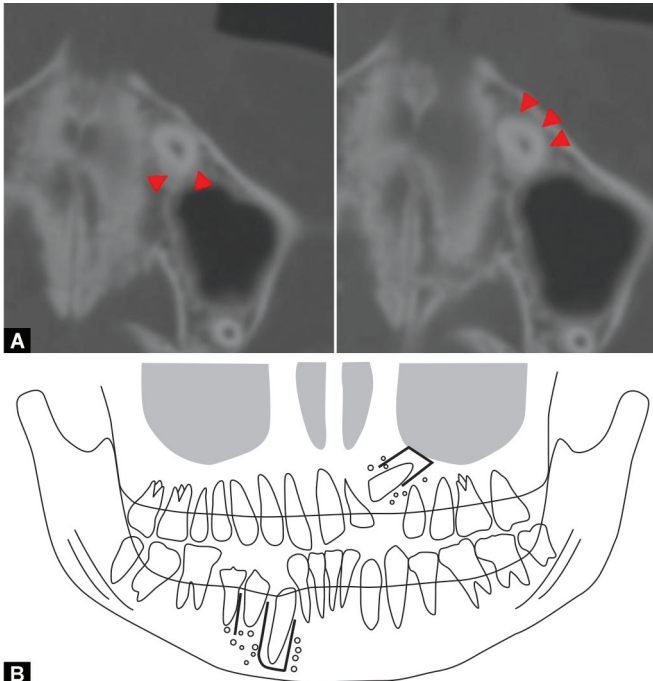
Variable	Japanese norm*	SD	Pretreatment	Posttreatment	Postretention
			16 years 3 months	21 years 3 months	26 years 3 months
<i>Angular items (°)</i>					
A-point-nasion-B-point angle (ANB)	2.8	2.4	-4.2	0.1	0.1
Sella-nasion-A-point angle (SNA)	80.8	3.6	79.7	79.7	79.6
Sella-nasion-B-point angle (SNB)	77.9	4.5	83.9	79.6	79.5
Mandibular plane/ Frankfort horizontal plane (FH)	30.5	3.6	19.9	22.4	21.3
Gonial angle	122.1	5.3	127.3	129.3	128.2
U1-SN	105.9	8.8	101.5	107.1	107.4
L1-mandibular plane	93.4	6.8	80.9	82.2	83.4
Interincisal angle	123.6	10.6	142.2	132.8	134.4
Occlusal plane	16.9	4.4	5.2	2.0	1.0
<i>Linear items (mm)</i>					
S-N	67.9	3.7	66.4	66.0	66.8
N-Me	125.8	5.0	59.9	53.9	56.2
Ar-Go	47.3	3.3	59.9	53.9	56.2
Ar-Me	106.6	5.7	116.4	114.2	114.6
Go-Me	71.4	4.1	73.0	75.7	77.2
Overjet	3.1	1.1	-4.0	2.5	3.0
Overbite	3.3	1.9	2.0	2.0	2.0

\*Wada et al.<sup>20</sup>

**Figs 2A to D:** Intraoral photographs and panoramic radiographs taken during treatment. (A) Six months after maxillary lateral expansion (patient age, 17 years). (B) One year after traction of the maxillary left canine (patient age, 18 years and 2 months). (C) Three months after corticotomy (patient age, 19 years and 4 months). (D) Six months after corticotomy (patient age, 19 years and 7 months)

months later, the maxillary left canine was surgically exposed, and orthodontic traction of this tooth was initiated with an elastic chain. However, it showed little or no movement even after 1-year of

traction, when the patient was aged 18 years and 2 months (Fig. 2B). The mandibular second premolars, left canine, and first premolar had erupted naturally to some extent. In contrast, the mandibular



**Figs 3A and B:** Computed tomography taken before alveolar corticotomy (A) and schematic illustration of alveolar corticotomy (B). Red arrowheads indicate partial ankyloses suspected. Black lines indicate cutting line of alveolar corticotomy

right canine exhibited none or very minimal eruption. According to the computed tomography (CT) images, the maxillary left and mandibular right canines were suspected as partial ankylosis although the images of partial loss of periodontal space were not obvious (Fig. 3A). Based on these findings, ankylosis of these two teeth was preliminarily diagnosed.

When the patient was aged 18 years and 6 months, 0.018" slot standard edgewise appliances were placed on her maxillary and mandibular dentition. Initial leveling was performed. At the age of 19 years and 1 month, the patient underwent outpatient alveolar corticotomy under local anesthesia (Fig. 3B). Full-thickness flaps were raised in the buccal regions of the maxillary left canine and mandibular right canine to first premolar, exposing the alveolus surrounding the ankylosed teeth. Cortical bone was removed with a surgical bur under continuous irrigation with sterile saline solution. For the mandibular right canine and first premolar, vertical cuts were made in the mesial and distal interproximal areas, starting at the alveolar crest and extending 2 to 3 mm beyond the root apices. For the maxillary left canine, a horizontal cut was made along the impaction axis in the mesial and distal interproximal areas. Several small round perforations (approximate diameter, 1 mm) were also made in the areas circumscribed by those cuts to accelerate bone healing. Immediately after the alveolar corticotomy, traction of the maxillary left canine with the surrounding alveolar bone was initiated via an elastomeric chain from the archwire (0.016" × 0.022" titanium–niobium alloy wire). Similarly, the mandibular right canine was extruded by attaching an elastomeric chain from the archwire (0.016" nickel–titanium alloy wire; Fig. 2C). After 6 months of traction, when the patient was aged 19 years and 7 months, the maxillary left and mandibular right canines had extruded successfully (Fig. 2D).

After a total of 21 months of preoperative orthodontic treatment, including traction of the ankylosed teeth, bilateral IVRO was performed to correct the anterior crossbite involving skeletal mandibular protrusion (Figs. 4A to C). The mandibular setback on the right and left sides were approximately 7 and 5 mm, respectively. Four orthodontic miniscrews were implanted in the maxillary and mandibular interradicular areas between the central and lateral incisors to avoid extrusion of the anterior teeth during intermaxillary skeletal fixation. This fixation was performed over 1 week, and mouth-opening training was initiated thereafter. After 10 months of postoperative orthodontic treatment, acceptable and functional occlusion had been achieved and the multibracket appliances were removed. Immediately thereafter, lingually bonded retainers were set on both dental arches; at night, the patient wore wraparound retainers on the maxillary and mandibular dentition. The total treatment time, including traction of the multiple ankylosed teeth, was 55 months.

### Treatment Results

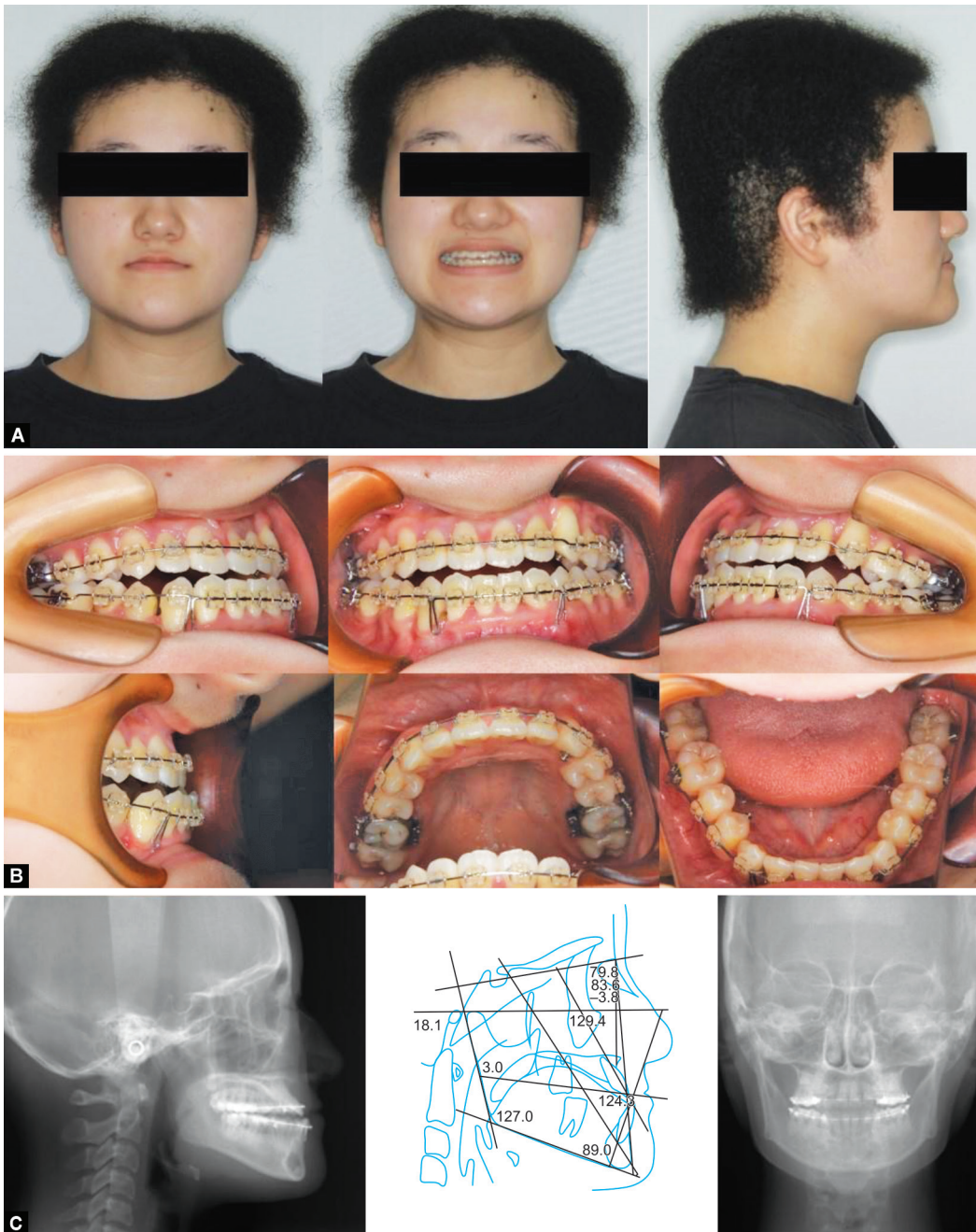
Posttreatment facial photographs showed improvement of the patient's overall facial balance, with straightening of the facial profile (Fig. 5A). Her anterior crossbite had improved, and adequate intercuspation of the teeth was achieved, with class I canine and molar relationships (Fig. 5B). The patient's overjet was increased to +2.5 mm and her overbite was maintained at +2.0 mm, resulting in an adequate interincisal relationship. Finally, the formerly ankylosed maxillary left and mandibular right canines had extruded to the occlusal plane, with the achievement of occlusal contact with the opposing teeth.

A panoramic radiograph showed that root parallelism was almost completely achieved (Fig. 5D). Posttreatment cephalometric analysis revealed a skeletal class I jaw-base relationship (ANB, +0.1°; Figs 5C and 5E, Table 1). The mandibular plane angle had increased by 2.5° but remained smaller than Japanese female norm (FMA, 22.4°). The maxillary central incisors were inclined labially (U1-SN, 107.1°), and the inclination of the mandibular central incisors was almost completely maintained.

Five years after the retention period, the patient maintained a good facial profile and an acceptable occlusion, with no recurrence of the anterior crossbite (Figs 6A and 6B). Thus, long-term occlusal stability had been achieved. The maxillary left and mandibular right canines were still vital, indicating little or no side effects of alveolar corticotomy. A panoramic radiograph revealed little or no change in the alveolar bone level and root parallelism (Fig. 6D). Postretention cephalometric evaluation showed little or no change, with no substantial skeletal or dental relapse (Figs 5E and 6C, Table 1).

### DISCUSSION

Systemic and local factors identified as contributors to the failure of tooth eruption include physical and functional interference, ankylosis, and disturbance of the mechanism underlying eruption.<sup>24</sup> In the patient described here, failure of eruption was observed for the maxillary left canine and the mandibular left canine and second premolar and right canine and the first and second premolars. The mandibular second premolars and right first premolar did not undergo eruption due to physical interference involving the prolonged retention of the deciduous molars. CT revealed the partial loss of periodontal space around the maxillary left and mandibular right canines,

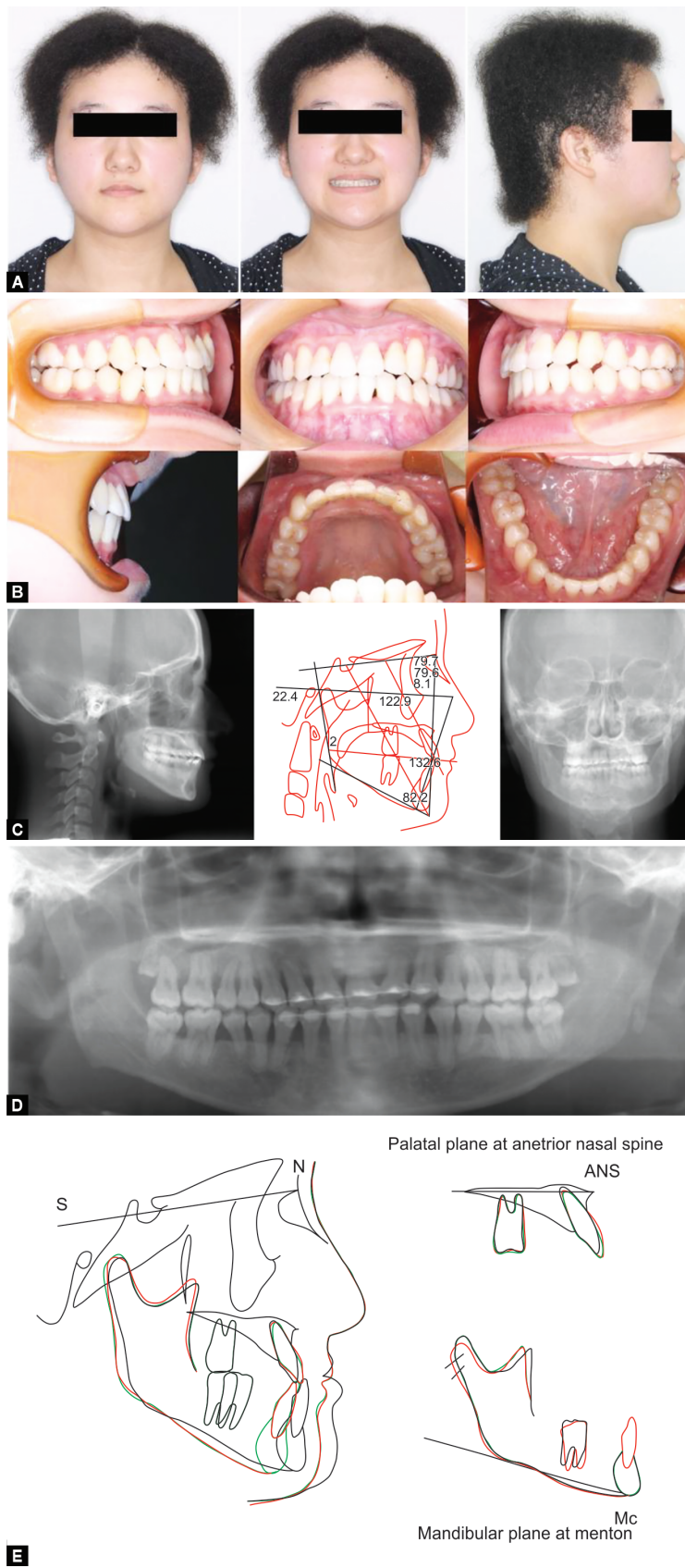


**Figs 4A to C:** Facial (A) and intraoral photographs (B), lateral and frontal cephalograms, and cephalometric tracing (C) taken before orthognathic surgery (patient age, 20 years and 3 months)

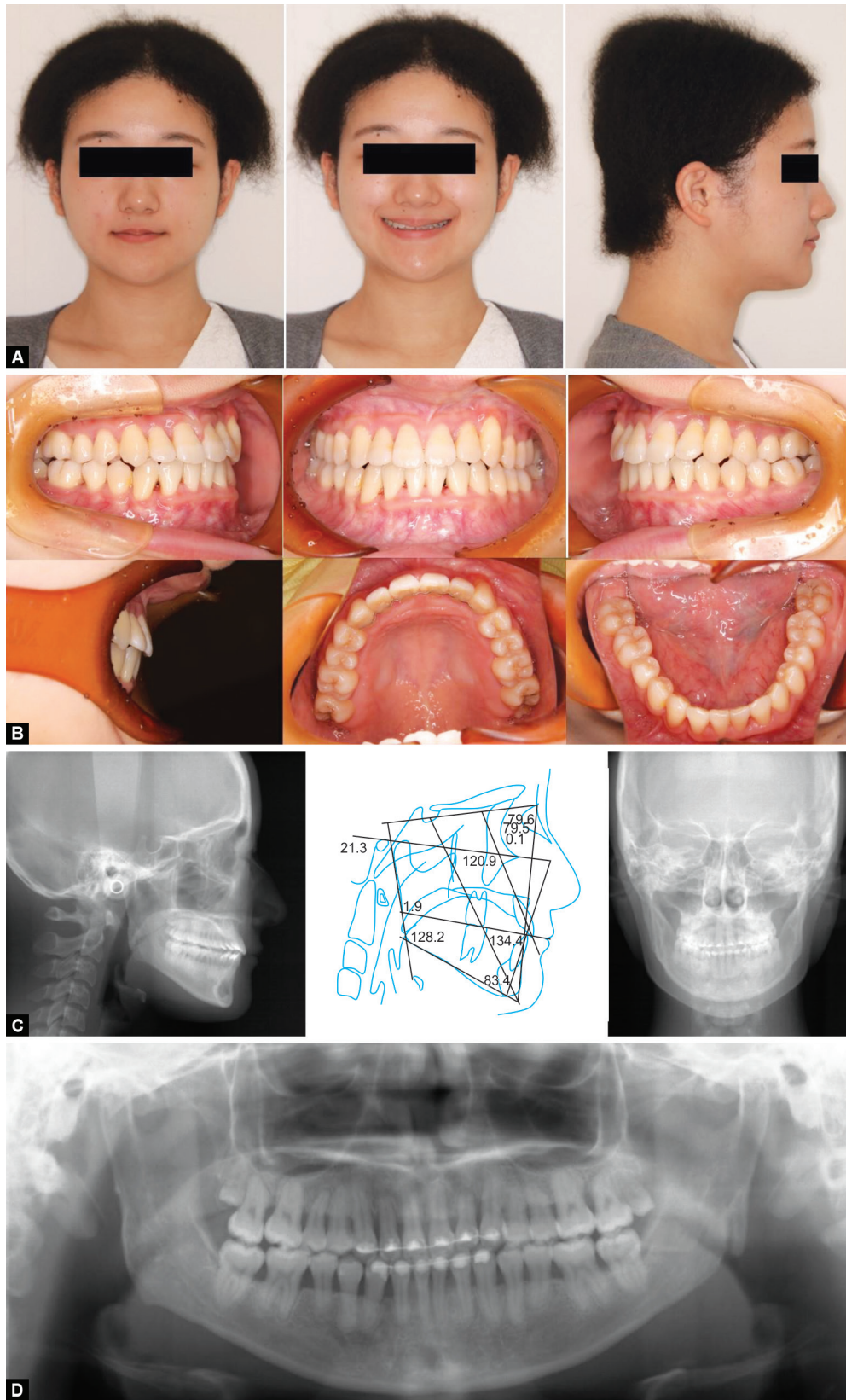
implying ankyloses, although only one-third of patients with ankylosed teeth exhibit such loss of periodontal space on CT images.<sup>25</sup> In such cases, an absolute diagnosis of tooth ankylosis is obtained with the application of orthodontic force. In the present case, orthodontic force was applied to the impacted canine for 1 year. And the immobility of this tooth confirmed that it was ankylosed. Although permanent maxillary incisors frequently become ankylosed after periodontal ligament damage due to local trauma,<sup>26</sup> ankylosed canines, especially multiple instances, are rare. In this case, the performance of alveolar corticotomy to improve the infraocclusion achieved sufficient

extrusion of multiple ankylosed canines within 6 months, with no postoperative complication (e.g., tooth devitalization or discoloration due to nerve injury, root resorption, or toothache). The patient exhibited no relapse at 5 years postoperatively. Thus, this approach may be useful for other patients with infraocclusion involving tooth ankyloses.

The present report describes combined orthodontic and orthognathic surgical treatment of skeletal mandibular protrusion, involving IVRO. Generally, sagittal split-ramus osteotomy (SSRO) is recognized to provide greater postoperative stability than that achieved with IVRO. Other disadvantages of IVRO include slow



**Figs 5A to E:** Posttreatment facial (A) and intraoral photographs (B), frontal and lateral cephalograms, cephalometric tracing (C), panoramic radiograph (D) (patient age, 21 years and 2 months), and superimposition of cephalometric tracings at pretreatment (black line), posttreatment (red line), and 5 years postretention (green line) on the sella-nasion plane at sella, on the palatal plane at anterior nasal spine, and on the mandibular plane at menton (E)



**Figs 6A to D:** Postretention facial (A) and intraoral photographs (B), frontal and lateral cephalograms, cephalometric tracing (C), and panoramic radiograph (D) (patient age, 26 years and 3 months)



postoperative osseous healing and projection of the antegonial notch. However, a recent study showed that IVRO was equivalent to SSRO in terms of bone healing and morphological recovery of the mandible.<sup>27</sup> In addition, Kung and Leung<sup>28</sup> reported no significant difference in relapse after IVRO and other mandibular orthognathic surgeries. Taken together, these observations indicate that the performance of IVRO to treat mandibular setback yields stable long-term results, as observed in the present case. Al Yami et al.<sup>29</sup> reported that approximately half of all relapses occur within the first 2 years after retention. Moreover, most postoperative skeletal changes following IVRO for orthognathic mandibular setback are likely to appear within the first year after surgery.<sup>28</sup> Our patient showed little or no relapse at 5 years. Thus, the present case demonstrates that the orthognathic surgical treatment of mandibular prognathism with IVRO can provide predictable and good long-term stability.

## CONCLUSION

In the present case, skeletal mandibular protrusion with multiple impacted ankylosed teeth was treated successfully with conventional osteotomy and alveolar corticotomy. Thus, alveolar corticotomy may facilitate the treatment of multiple impacted ankylosed teeth in patients with infraocclusion. After orthodontic-orthognathic treatment, an acceptable occlusion with class I canine and molar relationships was accomplished. During 5-year retention period, no relapse toward mandibular protrusion was found. Since the alveolar support of the ankylosed teeth is likely to be lowered due to continuous replacement resorption of the root, our case report indicates the necessity of long-term observation of a patient with ankylosed teeth after active treatment.

## AUTHORS' CONTRIBUTIONS

Toyoaki Takagi, and So Shimizu contributed to performing the orthodontic treatment and writing the manuscript. Eiji Tanaka contributed to the planning of the orthodontic treatment and editing the manuscript. All authors read and approved the final manuscript.

## CONSENT FOR PUBLICATION

Written informed consent was obtained from the patient for publication of this case report and any accompanying images.

## REFERENCES

1. Fernandez CCA, Pereira CVCA, Luiz RR, et al. Dental anomalies in different growth and skeletal malocclusion patterns. *Angle Orthod* 2018;88(2):195–201. DOI: 10.1016/j.archoralbio.2018.01.010.
2. Becker A, Chaushu S. Etiology of maxillary canine impaction: a review. *Am J Orthod Dentofacial Orthop* 2015;148(4):557–567. DOI: 10.1016/j.ajodo.2015.06.013.
3. Al Balbeesi HO, Al Kawari HM, Al Tamimi AS, et al. Association between canine impaction and skeletal pattern in the sagittal and vertical planes. *Int J Periodontics Restorative Dent* 2020;40(2):253–259. DOI: 10.11607/prd.4210.
4. Bishara SE. Impacted maxillary canines: a review. *Am J Orthod Dentofacial Orthop* 1992;101(2):159–171. DOI: 10.1016/0889-5406(92)70008-X.
5. Becker A, Lustmann J, Shteyer A. Cleidocranial dysplasia: part 1—general principles of the orthodontic and surgical treatment modality. *Am J Orthod Dentofacial Orthop* 1997;111(1):28–33. DOI: 10.1016/s0889-5406(97)70298-1.
6. Kuroda S, Yanagita T, Kyung HM, et al. Titanium screw anchorage for traction of many impacted teeth in a patient with cleidocranial dysplasia. *Am J Orthod Dentofacial Orthop* 2007;131(5):666–669. DOI: 10.1016/j.ajodo.2005.06.026.
7. Tanaka E, Kawazoe A, Nakamura S, et al. An adolescent patient with multiple impacted teeth. *Angle Orthod* 2008;78(6):1110–1108. DOI: 10.2319/121007-581.1.
8. Tanaka E, Watanabe M, Nagaoka K, et al. Orthodontic traction of an impacted maxillary central incisor. *J Clin Orthod* 2001;35(6):375–378. PMID: 11494940.
9. Stewart JA, Heo G, Glover KE, et al. Factors that relate to treatment duration for patients palatally impacted maxillary canines. *Am J Orthod Dentofacial Orthop* 2001;119(3):216–225. DOI: 10.1067/mod.2001.110989.
10. Becker A, Chaushu S. Success rate and duration of orthodontic treatment for adult patients with palatally impacted maxillary canines. *Am J Orthod Dentofacial Orthop* 2003;124(5):509–514. DOI: 10.1016/s0889-5406(03)00578-x.
11. Tanaka E, Iwabe T, Watanabe M, et al. An adolescent case of anterior open bite with masticatory muscle dysfunction. *Angle Orthod* 2003;73(5):608–613. DOI: 10.1043/0003-3219(2003)073<0608:AACAO>2.0.CO;2.
12. Takagi T, Shimizu S, Tanaka E. Treatment of unilateral posterior open bite by an ankylosed mandibular first molar with alveolar corticotomy. *J Clin Orthod* 2020 [in press].
13. Silvestrini Biavati A, Signori A, Castaldo A, et al. Incidence and distribution of deciduous molar ankylosis, a longitudinal study. *Eur J Paediatr Dent* 2011;12(3):175–178. PMID: 22077686.
14. Andreasen JO, Andreasen FM. Essentials of traumatic injuries to the teeth. Copenhagen, Denmark: Munksgaard; 1991. p. 103–131.
15. Senisik NE, Kocer G, Ureyen Kaya B. Ankylosed maxillary incisor with severe root resorption treated with a single-tooth dento-osseous osteotomy, vertical alveolar distraction osteogenesis, and mini-implant anchorage. *Am J Orthod Dentofacial Orthop* 2014;146(3):371–384. DOI: 10.1016/j.ajodo.2013.10.026.
16. Kofod T, Würtz V, Melsen B. Treatment of an ankylosed central incisor by single tooth dentoosseous osteotomy and a simple distraction device. *Am J Orthod Dentofacial Orthop* 2005;127(1):72–80. DOI: 10.1016/j.ajodo.2003.12.020.
17. Ohkubo K, Susami T, Mori Y, et al. Treatment of ankylosed maxillary central incisors by single tooth dentoosseous osteotomy and alveolar bone distraction. *Oral Surg Oral Med Oral Pathol Oral Radiol Endod* 2011;111(5):561–567. DOI: 10.1016/j.tripleo.2010.06.026.
18. Uzuner FD, Darendeliler N. Dentoalveolar surgery techniques combined with orthodontic treatment: a literature review. *Eur J Dent* 2013;7(2):257–265. DOI: 10.4103/1305-7456.110201.
19. Patterson BM, Dalci O, Darendeliler MA, et al. Corticotomies and orthodontic tooth movement: a systematic review. *J Oral Maxillofac Surg* 2016;74(3):453–473. DOI: 10.1016/j.joms.2015.10.011.
20. Wada K, Matsushita K, Shimazaki S, et al. An evaluation of a new case analysis of a lateral cephalometric roentgenogram. *J Kanazawa Med Univ* 1981;6:60–70.
21. Hwang DH, Park KH, Kwon YD, et al. Treatment of Class II open bite complicated by an ankylosed maxillary central incisor. *Angle Orthod* 2011;81(4):726–735. DOI: 10.2319/102010-578.1.
22. Hu J, Li J, Wang D, et al. Differences in mandibular distraction osteogenesis after corticotomy and osteotomy. *Int J Oral Maxillofac Surg* 2002;31(2):185–189. DOI: 10.1054/ijom.2001.0193.
23. Baek SH, Kim K, Choi JY. Evaluation of treatment modality for skeletal Class III malocclusion with labioversed upper incisors and/or protrusive maxilla: surgical movement and stability of rotational maxillary setback procedure. *J Craniofac Surg* 2009;20(6):2049–2054. DOI: 10.1097/SCS.0b013e3181be87ba.
24. Chaushu S, Becker A, Chaushu G. Orthosurgical treatment with lingual orthodontics of an infraoccluded maxillary first molar in an adult. *Am J Orthod Dentofacial Orthop* 2004;125(3):379–387. DOI: 10.1016/j.ajodo.2003.05.003.
25. Raghoobar GM, Boering G, Jansen HW, et al. Secondary retention of permanent molars: a histologic study. *J Oral Pathol Med* 1989;18(8):427–431. DOI: 10.1111/j.1600-0714.1989.tb01338.x.

26. Andreason JO. Injuries to developing teeth. In: Andreason JO, Andreason FM, editors. Textbook and color atlas of traumatic injuries to the teeth. Copenhagen, Denmark: Munksgaard; 1994. p. 457–494.
27. Rokutanda S, Yamada S, Yanamoto S, et al. Comparison of osseous healing after sagittal split ramus osteotomy and intraoral vertical ramus osteotomy. *Int J Oral Maxillofac Surg* 2018;47(10):1316–1321. DOI: 10.1016/j.ijom.2018.05.013.
28. Kung AYH, Leung YY. Stability of intraoral vertical ramus osteotomies for mandibular setback: a longitudinal study. *Int J Oral Maxillofac Surg* 2018;47(2):152–159. DOI: 10.1016/j.ijom.2017.09.004.
29. Al Yami EA, Kuijpers-Jagtman AM, van't Hof MA. Stability of orthodontic treatment outcome: follow-up until 10 years postretention. *Am J Orthod Dentofacial Orthop* 1999;115(3):300–304. DOI: 10.1016/s0889-5406(99)70333-1.