

## Combined orthodontic and surgical open bite correction: Principles for success. Part 2

G. William Arnett<sup>a</sup>; Antonio D'Agostino<sup>b</sup>; Elisabetta Grendene<sup>c</sup>; Richard P. McLaughlin<sup>d</sup>; Lorenzo Trevisiol<sup>b</sup>

### ABSTRACT

**Objectives:** To present a clinical description of the team's treatment techniques.

**Materials and Methods:** In Part 1, 30 patients underwent segmental maxillary orthodontics, multisegment Le Fort I, and bilateral sagittal osteotomies of the mandible. Part 1 reported excellent occlusal stability at a mean follow-up of 49.43 months (range, 36–92 months). Cases presented in Part 2 were selected based on availability of excellent technique photographs. The same techniques described in Part 2 cases were used on all Part 1 patients.

**Results:** The coordination of arch widths and forms, overbite, overjet, and maxillary curve of Spee corrections were stable using the team protocols for orthodontic and surgical treatment.

**Conclusions:** In the study group, long-term three-dimensionally stable occlusal results were achieved. To duplicate these results, specific orthodontic preparation, intraoperative surgical steps, and postsurgical steps must be carefully planned and executed. These steps are described in this article, Part 2. (*Angle Orthod.* 2022;92:431–445.)

**KEY WORDS:** Orthognathic; Open bite; Correction; Stability

### INTRODUCTION

Anterior open bite is the lack of overlap of the anterior teeth in centric occlusion.<sup>1</sup> Ideally, open bite treatment corrects the bite but also improves facial balance and increases airway size.

Occlusal correction and open bite treatment options range from several orthodontic interventions to numerous orthognathic surgery interventions. Inherent with any treatment method is a potential level of occlusal relapse, which may render treatment inadequate.<sup>2–9</sup> However, as described by Proffit et al., open bite closure is considered one of the most difficult malocclusions to treat with stability.<sup>10</sup>

The objective of Part I was to study the long-term stability of patients with anterior open bite and accentuated maxillary curve of Spee corrected with specific protocols.

It was found that the orthodontic and surgical methods, as presented in Part 1, produced stable long-term occlusal results. Part 2 of this article discusses the detailed surgical and orthodontic techniques employed by the team, consisting of one orthodontist and two surgeons.

### MATERIALS AND METHODS

The inclusion criteria for the 30-patient group was detailed in Part 1 of this study.

Many published studies are insufficient because different techniques are reported as if they are the same techniques but are most likely different. Here, to the contrary, only one orthodontist (Dr Grendene) was involved, which was extremely important to the homogeneity of the orthodontic preparation or finish and thus the findings.

Treatment plans and surgeries were all performed by the same two surgeons (Drs D'Agostino and Trevisiol). Again, as with orthodontic preparation/finishing, only two surgeons performed the surgery, which lends homogeneity to the surgical techniques used and thus the validity of the surgical findings.

<sup>a</sup> Private Practice, Santa Barbara, Calif, USA.

<sup>b</sup> Associate Professor, Section of Oral and Maxillofacial Surgery, Department of Surgical Sciences, Dentistry, Gynaecology and Paediatrics, University of Verona, Verona, Italy.

<sup>c</sup> Private Practice, Verona, Italy.

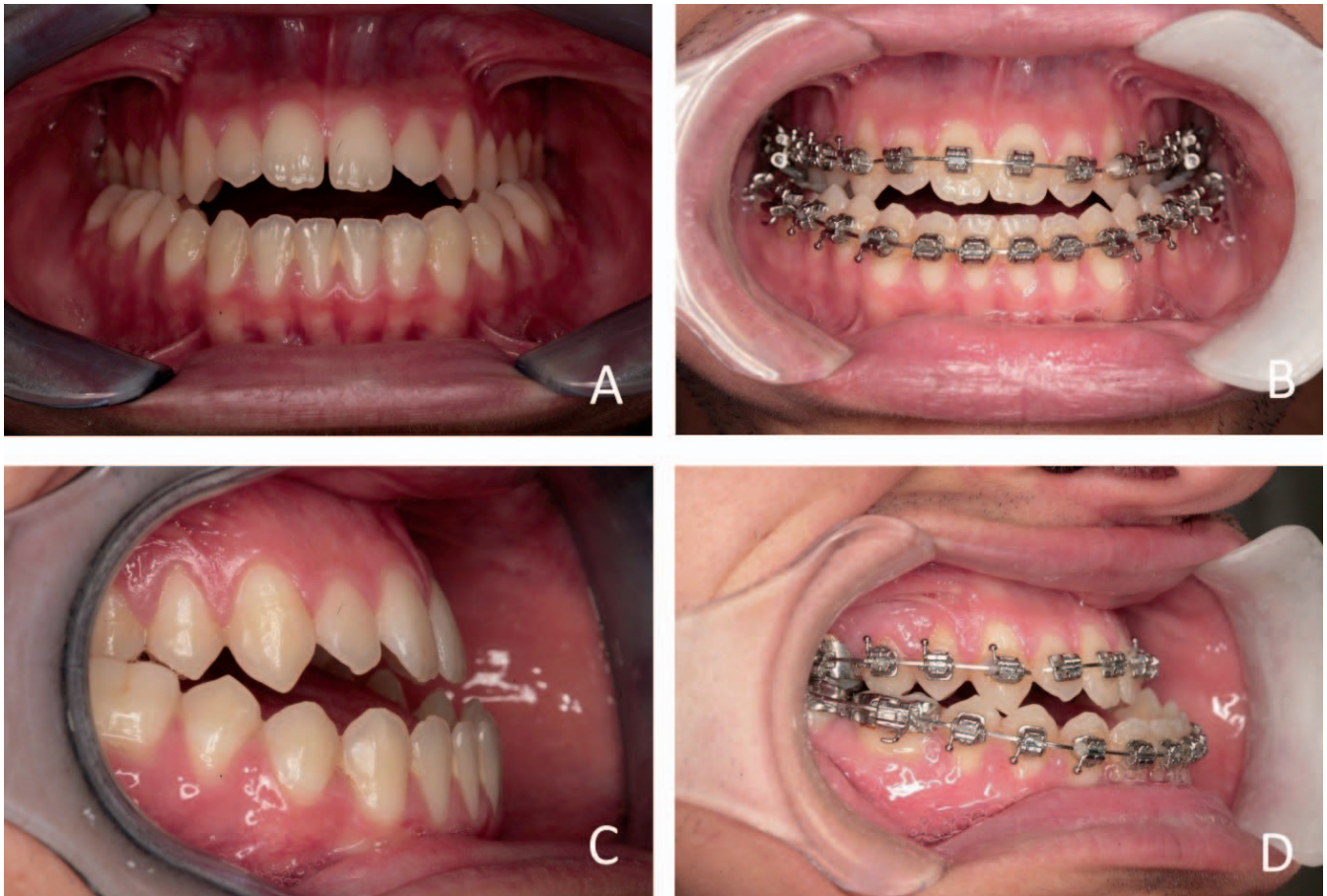<sup>d</sup> Private Practice, San Diego, Calif, USA.

Corresponding author: G. William Arnett, DDS, FACD, Oral and Maxillofacial Surgeon, Private Practice, 2250 Santiago Rd, Santa Barbara, CA 93103, USA (e-mail: Arnett@arnettcourses.com)

Accepted: January 2022. Submitted: December 2021.

Published Online: March 16, 2022

© 2022 by The EH Angle Education and Research Foundation, Inc.



**Figure 1.** Orthodontic preparation for surgery. (A) Pretreatment frontal view with the maxillary occlusal plane change between canines and lateral incisors. (B) Orthodontic treatment, immediate presurgical frontal view. Note maxillary archwire sectioned between canines and lateral incisors; lower central incisor brackets are high, which prevents deep overbite, and the top bracket legs can be removed with a diamond bur to allow deep overbite in the operating room (OR). (C) Preorthodontic lateral view. (D) Presurgery lateral view. Note: maxillary dual-plane occlusion maintained and mandatory upper first molar bands (not brackets) to facilitate accurate IMF in the operating room. The maxillary first molar bands have lingual cleats and sheaths (not seen) for postsurgery cross arch elastics and/or a palatal bar to support expansion of the maxilla when necessary.

General treatment consisted of presurgical mandibular continuous archwires, maxillary segmental archwires, bimaxillary surgery (multisegment Le Fort I [MSLFI] and Bilateral Sagittal Split Osteotomy [BSSO]), and counterclockwise occlusal plane changes to optimize the profile and airway changes. The profiles were treatment planned with the techniques outlined by Arnett et al. based on clinical facial examination and soft tissue cephalometric analysis.<sup>11-14</sup>

The following four key sections detail the techniques employed by the treatment team that produced the stable occlusal changes described in Part 1 of this article: Orthodontic Preparation Protocol, Surgical Technique Protocol Basics, Maximizing Dental Intercuspation Protocol, and Postsurgical Care Protocol.

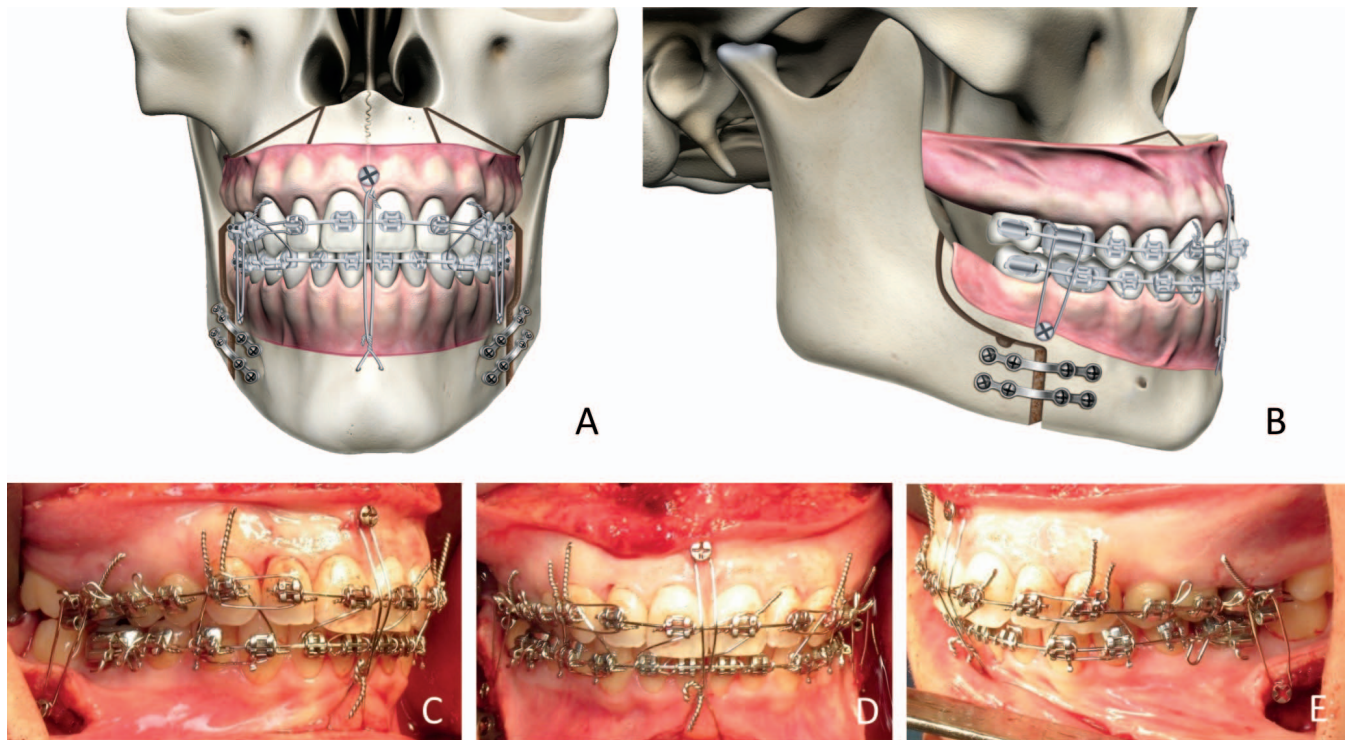
### Orthodontic Preparation Protocol

All orthodontic preparation techniques were based on the published orthodontic stability literature.<sup>2,4-6,9,15-27</sup>

The guiding preparation principle was to minimize orthodontic tooth movement distance during surgical preparation to minimize orthodontic relapse after surgery. The orthodontic literature is clear: relapse is proportionate to orthodontic dental (tooth) movement distances.<sup>2,4-6,9,15-27</sup> The basics of the orthodontic preparation techniques were listed in Tables 1 and 2 of Part 1 of this article.<sup>28</sup>

Orthodontic appliance brackets were metal because they have proven less likely to dislodge in the operating room. Hooks were placed on the posterior teeth to receive elastics after surgery. There were two basic orthodontic preparation goals: stable orthodontic preparation and produce maximal intercuspation during surgery. The philosophy was to produce an orthodontically stable lower arch that the segmental upper arch could be built on during surgery.

*Mandibular arch orthodontics (Figure 1).* All lower arch curves of Spee were leveled with continuous



**Figure 2.** Top row A and B drawings: surgical stage as depicted; mandibular surgery and plating are completed, and the maxilla is cut but not plated. MSLFI with interdental cuts between canines/lateral incisors. Routine final IMF in place with no final splint. Posterior IMF from the maxillary first molars to  $2 \times 11$  mandibular unicortical screws. Anterior skeletal IMF from bicortical  $2 \times 16$  maxillary midline screw to B point wire. Note the mandatory maxillary first molar bands. Bottom row C, D, and E: operating room photos at the same surgical stage as top row A and B. Note: IMF demonstrating excellent intercuspation without final splint and deep overbite allowed by low mandibular central incisor bracket placement and/or diamond bur reduction of superior bracket height.

archwires. To maximize intercuspation during surgery, orthodontic preparation corrected incisor inclinations, marginal ridge heights, rotations, and alignment of the lower dentition. Composite bonding was used to replace worn buccal cusps, again to maximize intercuspation. Crowding was addressed with either premolar extractions or interproximal reduction depending on the severity of crowding. Orthodontic changes of the mandibular arch form and width are prone to relapse<sup>15–27</sup>; therefore, orthodontic preparation attempted to maintain arch form and width.

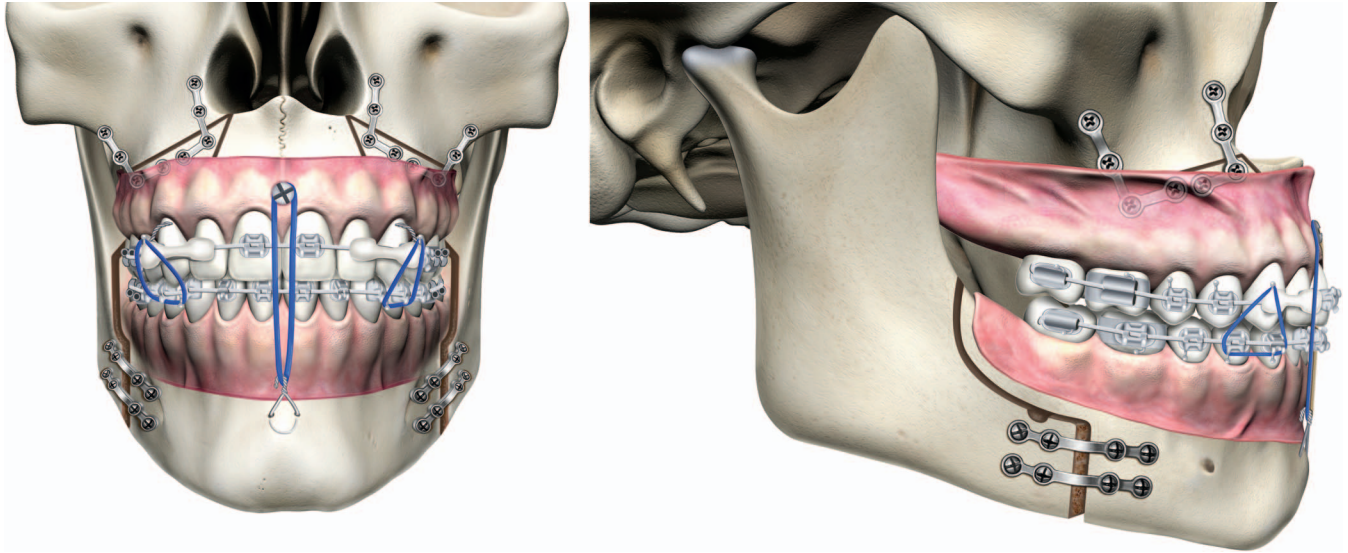
**Maxillary arch orthodontics (Figure 1).** To maximize surgical intercuspation of the upper arch, orthodontic preparation carefully corrected incisor inclination, marginal ridge heights, rotations, and alignment of the upper dentition within each segmental piece of the maxilla. Composite bonding was used to replace worn buccal cusps and/or upper incisor length as needed, with the goal of maximizing intercuspation and overbite in the operating room. Premolars were extracted when excessive crowding was present. Maxillary arch form, width, and curve of Spee were maintained to avoid potential orthodontic relapse.<sup>15–27</sup> At 4 months before surgery, the upper archwires were cut to allow relapse of the unstable arch changes.

### Surgical Technique Protocol Basics

Different aspects of surgical care are presented in Tables 3 (surgical philosophy) and 4 (surgical techniques in the operating room) of Part 1 of this article.<sup>28</sup>

This surgical technique section is not a detailed surgical “how to” but, rather, shares basic knowledge between the team members to improve the bite and to control postsurgical occlusal relapse. This section provides a list of essential surgical principles with limited explanations. The list that follows is a timeline starting with the first and ending with the last surgical consideration (see Figures 1–3).

1. Make sure maxillary archwire was cut 4 months before surgery to allow for possible orthodontic relapse of arch form, arch width, and maxillary dual-plane occlusion (Figure 1).
2. Bond worn lower buccal cusps (plunger) and the upper buccal cusps (locking). Equilibrate the upper and lower central fossae (to accept plunger cusps) to maximize locking of posterior occlusion in the operating room. Bonding is usually done by a dentist or the orthodontist shortly prior to surgery. Equilibration is done by the surgeon on the immediate presurgical models.



**Figure 3.** Depiction of surgery completed, IMF removed, and postsurgery standard elastics. Note the maxillary archwire composite placed from canine to lateral prior to release of IMF. Composite prevents IMF elastic mobilization of the maxillary fragments postsurgery. Elastic details are in Table 2. Note: 24-gauge B point wire runs behind the buccal cortex and functions well for 6 months, whereas B point screws fail rapidly.

3. Always have upper first molar bands (strong) with lingual cleats and sheaths. The bands provide strength and do not displace during intermaxillary fixation (IMF) during the operation (Figure 2).
4. Operate and plate the lower jaw first. For a variety of reasons, this is more accurate than operating the upper jaw first (Figure 2).
5. Plate the lower jaw with two plates per side with monocortical screws (Figure 2). This technique is stable as demonstrated in Part I of this article. Graft the osteotomy gap when greater than 4 mm.
6. Operate the multisegment upper jaw second, building the upper dentition using the lower dentition as the template (Figure 2).
7. Perform MSLFI surgery to coordinate the upper arch with the lower arch and maximize dental intercuspation (occlusal lock). Multisegmental Le Fort I (MSLFI) produces greater intercuspation than a single-piece LFI (Figure 2).
8. After the segmental LFI is cut, apply IMF without a final splint (Figure 2). The posterior IMF goes from the upper first molar band to a unicortical  $2 \times 11$  screw between the roots of the lower first and second molars (Figure 2). Tooth fit (intercuspation lock) is always superior without a final splint. A final splint is not necessary to maintain maxillary expansion; the intercuspation locking maintains maxillary expansion (Figure 2).
9. Plate the segmented maxilla with two plates per side for support of arch width/form changes (Figure 3).
10. Apply light cured acrylic across the maxillary segmental archwire prior to the release of the

IMF. The acrylic, in effect, stabilizes the segments of the maxilla, which allows postoperative elastic wear without inadvertent mobilization of segments (Figure 3).

11. Graft surgical sites as needed, remove  $2 \times 11$  mandibular screws, and close incisions.

#### **Maximizing Dental Intercuspation Protocol (Table 1)**

Part 1 of this article verified that multisegment surgery with maximal intercuspation, as described, is a clinically stable procedure in three planes of space. A brief summary of the techniques to increase intercuspation was presented in Table 5 of Part 1 of this article.<sup>28</sup>

Intercuspation of the dentition is so important to occlusal stability that a thorough description is necessary. Table 1 of the current article is a complete list of intercuspation factors. In addition, a pictorial review of important intercuspation techniques and principles was presented in Figures 1–3.

In the context of this study, what is the definition of *maximal dental intercuspation*? Simply stated, maximizing dental intercuspation means locking the mandibular buccal cusps into the maxillary central fossae and locking the maxillary buccal cusps outside the mandibular buccal cusp surfaces. Maximizing intercuspation is produced by developing upper and lower buccal cusps and central fossae. This is accomplished by using orthodontic preparation, composite bonding of worn buccal cusps, equilibration of central fossae, MSLFI surgery, and final surgical splint avoidance. Importantly and probably unique to this study was the presurgical dental reconstruction (buccal cusp bonding

**Table 1.** Complete List of Intercuspatation Factors<sup>a</sup>

Dental reconstruction as needed	<ul style="list-style-type: none"> <li>• Composite bonding of worn buccal cusps</li> <li>• Equilibrate central fossae</li> <li>• Usually accomplished week before surgery</li> </ul>
Orthodontic	<ul style="list-style-type: none"> <li>• Remove rotations</li> <li>• Decompensate incisors</li> <li>• Level marginal ridges</li> <li>• Level lower curve of Spee</li> <li>• Maintain upper curve of Spee</li> <li>• Upper first molar bands and lingual cleats/sheaths</li> <li>• Postsurgery elastics as per Figure 3</li> <li>• Palatal bar and/or cross arch elastics (expansion &gt;4 mm, shallow palatal vault) per Figure 5</li> <li>• Bonded lower retainer as per Figure 6</li> <li>• Hawley rap around retainer upper as per Figure 6</li> </ul>
Surgery	<ul style="list-style-type: none"> <li>• Equilibrate immediately if bite opens</li> <li>• MSLFI, which produces improved intercuspation over one piece</li> <li>• No final splint, which prevents intercuspation</li> <li>• IMF as per Figure 2 description</li> <li>• Plate MSLFI, place composite across cut archwire before release of IMF as per Figure 3</li> <li>• Remove IMF</li> <li>• Remove 2 × 11 screws as shown in Figure 2</li> <li>• Close all incisions</li> <li>• Postsurgery elastics as per Figure 3</li> <li>• Equilibrate immediately if bite opens</li> </ul>

<sup>a</sup> Intercuspatation involves orthodontic treatment, dental reconstruction, and surgical technique. Maximal intercuspation produces maximal stability of the upper arch form and width changes. Arch width and shape changes that involve flat teeth are unstable.

and central fossa development) and final splint avoidance. Surprisingly, it is important to avoid the final splint because the final splint prevents full intercuspation of the teeth in the operating room and early postsurgery periods.

The purpose of maximal dental intercuspation is to coordinate upper and lower arch form and width changes that may occur after surgery. Indeed, as reported in Part 1, there was minimal but significant width relapse of the maxillary width that corresponded to the same minimal but significant width decrease of the lower arch. What proof exists of intercuspation significance? Lima et al.<sup>29</sup> and Adkins et al.<sup>30</sup> reported that orthodontic rapid maxillary expansion is accompanied by an equal expansion of the mandibular arch without treatment: spontaneous mandibular expansion. How can the mandibular arch expand without treatment? How does the lower arch respond to upper arch expansion? Intercuspation and redistribution of occlusal forces were proposed by Lima et al.<sup>29</sup> and Adkins et al.<sup>30</sup> This same phenomenon is

**Table 2.** Surgeon and Orthodontist Postsurgery Protocols<sup>a</sup>

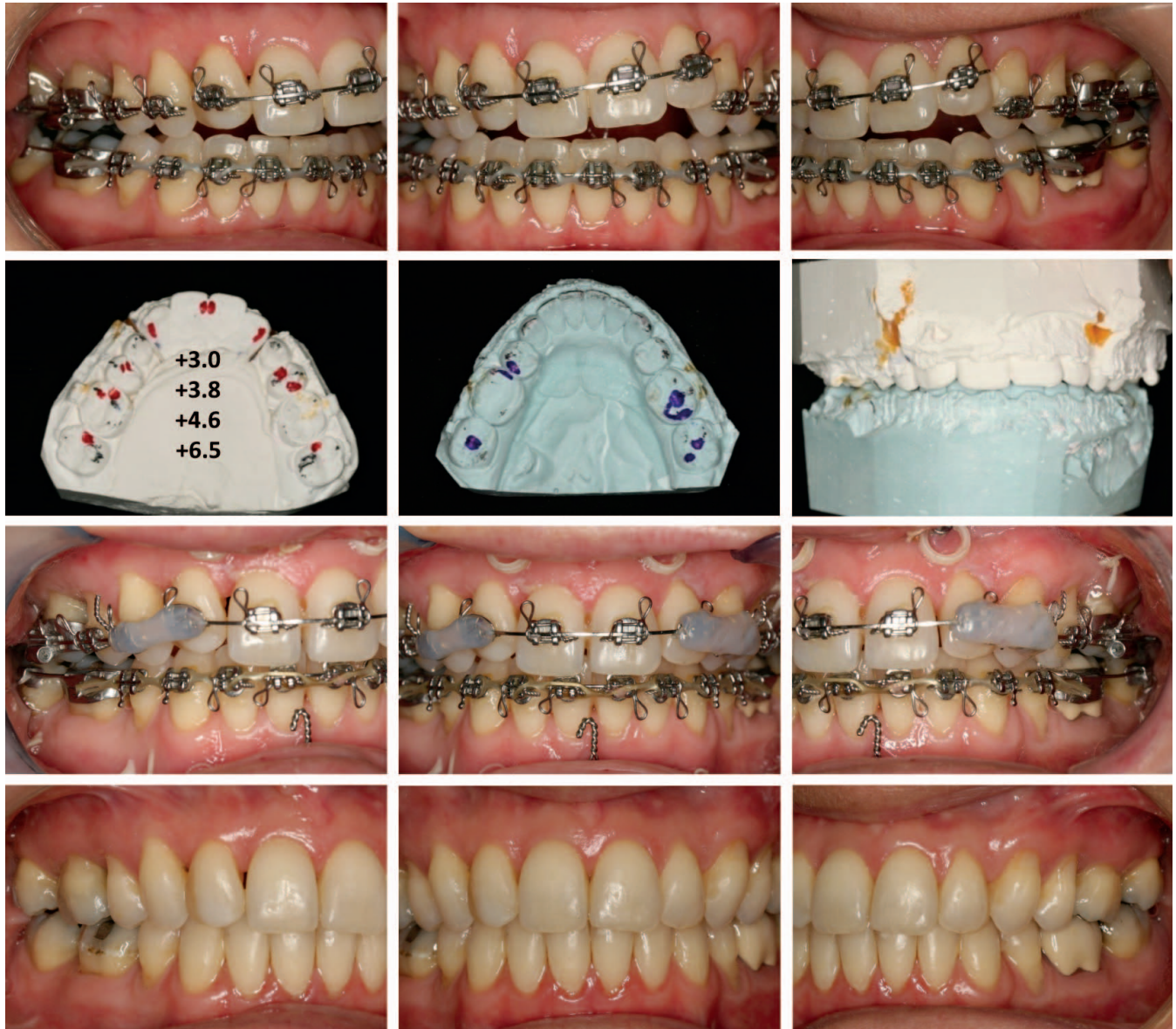
Surgeon	<p><b>Surgeon postsurgical patient visits:</b></p> <ul style="list-style-type: none"> <li>• First week postsurgery twice and/or as needed, then weekly for 8 weeks, then monthly for 6 months, and then yearly for 5 years.</li> </ul> <p><b>Elastics (Figure 3):</b></p> <ul style="list-style-type: none"> <li>• Full-time 8 weeks, nights 8 weeks to 6 months</li> <li>• Canine triangles—one daytime, two nighttime</li> <li>• Cross arch elastics—one or two only if maxillary narrowing occurs (Figure 5B)</li> <li>• Midline skeletal elastics—one daytime, two nighttime (maxillary 2 × 16 or 18 screw to B point 24-gauge wire; Figure 5C)</li> <li>• Remove all elastics twice a day for 30 minutes to allow range of motion exercises during first 8 weeks of full-time wear</li> <li>• Class II or Class III elastics when overjet change is required</li> </ul> <p><b>Equilibration:</b></p> <ul style="list-style-type: none"> <li>• Immediately if posterior prematurity decreases overbite; done by the orthodontist or surgeon</li> </ul>
Orthodontist	<p><b>Orthodontist postsurgical patient visits:</b></p> <ul style="list-style-type: none"> <li>• First visit at 8–10 weeks after surgery then monthly until debanding at approximately 8 months after surgery</li> </ul> <p><b>Elastics (Figure 3):</b></p> <ul style="list-style-type: none"> <li>• Same pattern as surgeon</li> </ul> <p><b>Palatal bar:</b></p> <ul style="list-style-type: none"> <li>• &gt;4 mm expansion or flat palatal vaults, which tend to narrow after surgery (Figure 5A)</li> </ul> <p><b>First archwire change after surgery:</b></p> <ul style="list-style-type: none"> <li>• 8–10 weeks after surgery</li> <li>• Remove upper archwire acrylic placed at surgery</li> <li>• Rebracket anterior 6 maxillary teeth</li> <li>• New archwires must be passive to maintain surgical bite correction</li> <li>• Check bite 2 days after archwire change for bite problems</li> </ul> <p><b>Rebracketing:</b></p> <ul style="list-style-type: none"> <li>• When placing new arch wire (8–10 weeks)</li> </ul> <p><b>Equilibration:</b></p> <ul style="list-style-type: none"> <li>• Immediately if posterior prematurity develops to close any anterior open bite; done by the orthodontist or surgeon</li> </ul> <p><b>Retainers (Figure 6):</b></p> <ul style="list-style-type: none"> <li>• Placed at debanding, maxillary wraparound, mandibular fixed</li> </ul>

<sup>a</sup> The patients were followed very closely to identify any occlusal problems. If an occlusal problem is identified early, it can be rectified. If a problem is not identified, it will be permanent.

considered to be important to postsurgery coordination of the arches: the greater the intercuspation leaving the operating room, the greater long-term coordination of the arches. Figure 4 serves as a one-patient visual summary of occlusal intercuspation techniques.

**Postsurgical Care Protocol**

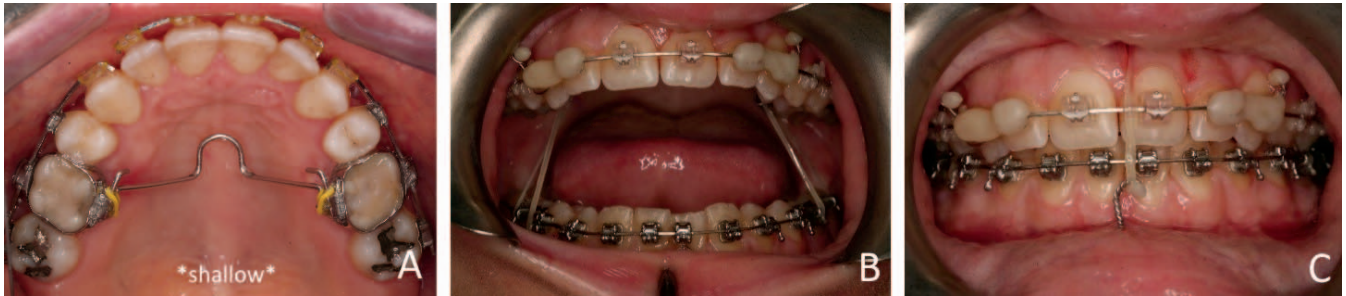Three important aspects of postsurgical care are described in Table 2: visits, elastics, and orthodontic finishing.



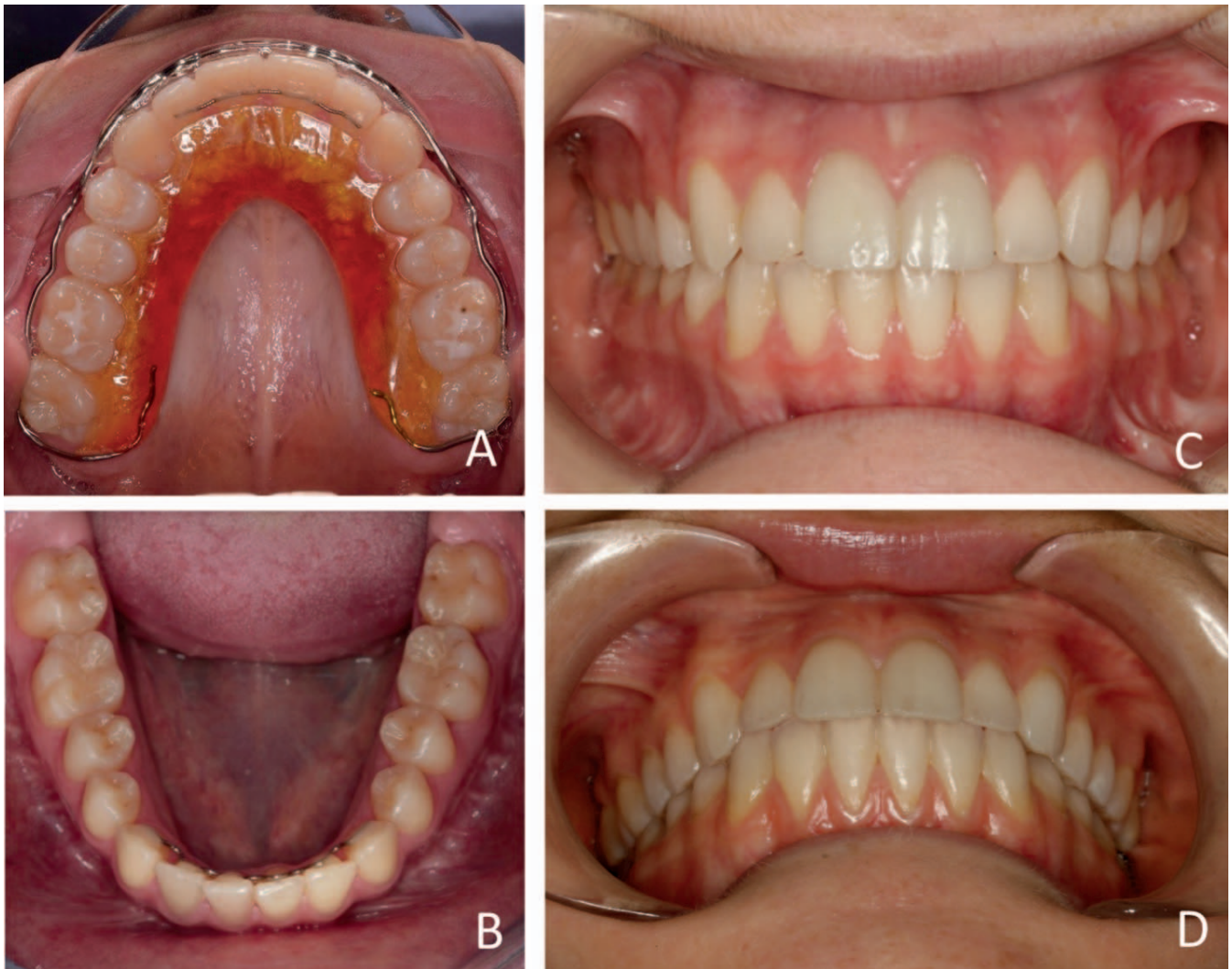**Figure 4.** Intercuspation summary case. Top row: presurgical orthodontic preparation is shown. Note the segmented upper archwire to maintain unusual dual-plane occlusion, the preorthodontic arch widths and forms maintained, and the mandatory maxillary first molar bands with lingual cleats and sheaths (not seen). Second row: immediate presurgery models. The expansion increases are indicated in millimeters. The upper model is segmented between canines and laterals, allowing matching of upper and lower arch forms, widths, and occlusal planes. Note the equilibration: red, upper central fossa; blue, lower central fossa. Achieved but not apparent is the buccal cusp wear composite bonding. The stable orthodontic preparation, MSLFI, equilibration, and buccal cusp bonding maximize intercuspation, which is the key to upper jaw expansion stability. Third row: occlusion 6 weeks postsurgery. Note the composite bonding (laterals to canines), which was placed during the operation before the release of IMF to stabilize multisegment fragments. Note also the deep overbite allowed by removing the top of the lower central incisor orthodontic brackets by using a diamond bur during the operation. Not shown: first archwire change at 8–10 weeks when the archwire composite was removed, six anterior teeth were rebracketed, and new upper passive archwire was placed. Bottom row: final occlusion at 3 years postsurgery, demonstrating maximal intercuspation; intercuspation is the ultimate retention. Note that the gingival defect between the upper right central and lateral incisor predated surgery.

*Follow-up visits.* The principle of follow-up is simple: if a problem develops after surgery, it cannot be corrected if no one sees the problem—follow the patients closely. Follow-up visits for the orthodontist and surgeon are listed in Table 2.

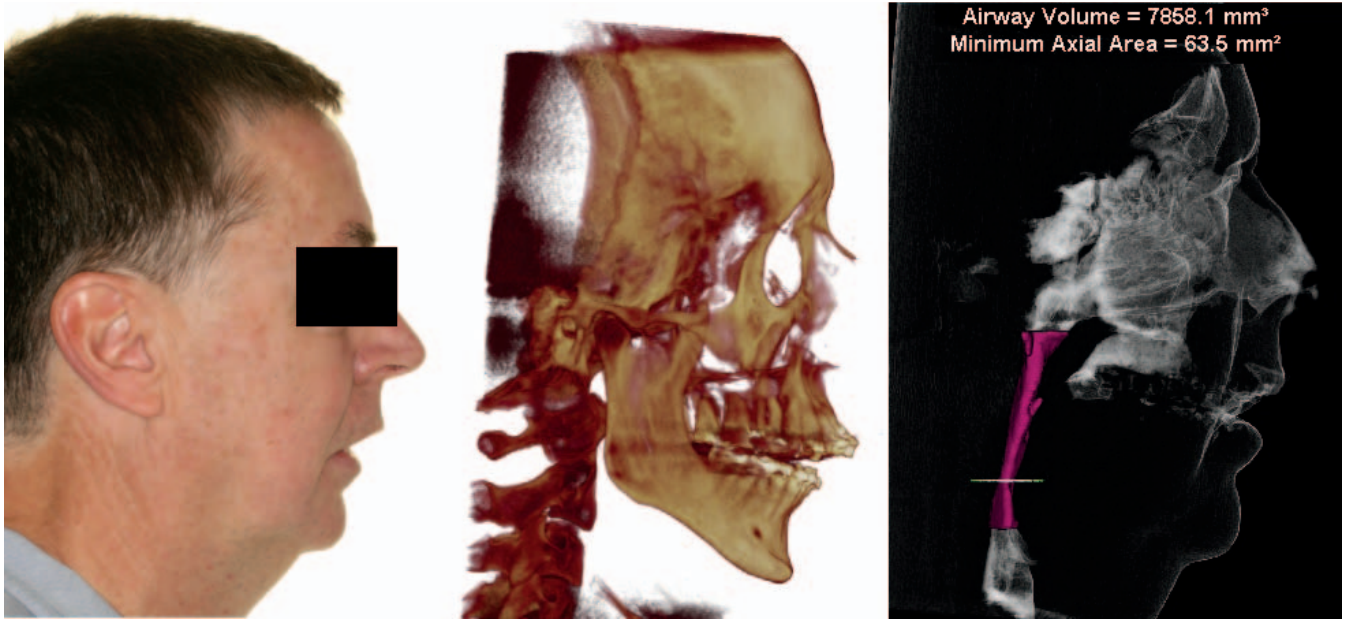
At all visits, the patient's opening, bite, and temporomandibular joint (TMJ) status were assessed. Cone beam computed tomography (CBCT) images were obtained immediately postsurgery and 1 year, 3 years, and at the longest term follow-up appointment.



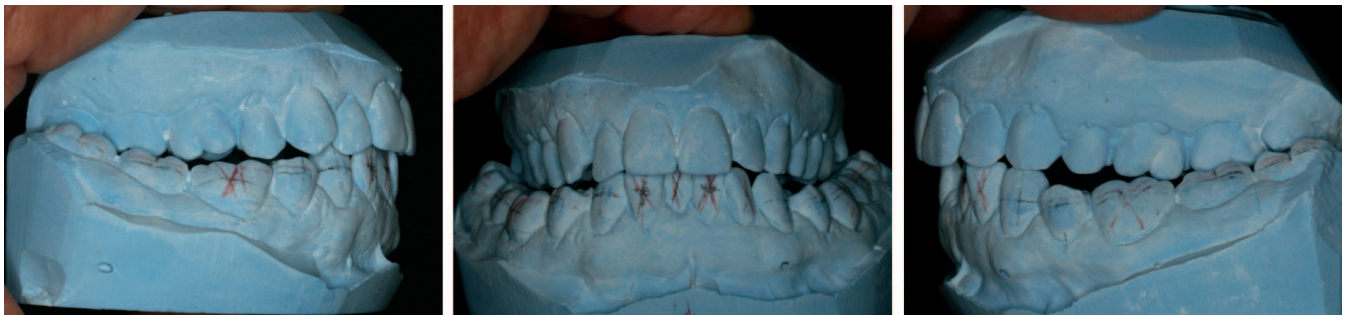**Figure 5.** Postsurgical finishing depicted. (A) Transpalatal bar support used most commonly for shallow palatal vaults, which tend to relapse. (B) Cross arch elastics (in-to-out) used to maintain transverse expansion. (C) Anterior skeletal elastics to maintain overbite skeletally and, thus, avoid dental extrusion of incisors, which relapse.



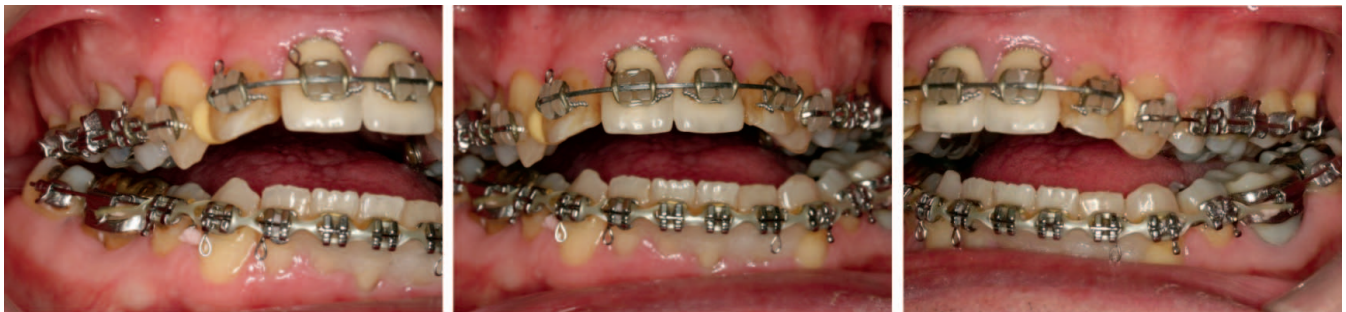**Figure 6.** Standard orthodontic retention. (A) Upper Hawley-type retainer specifically designed to allow maximal dental intercuspatation. (B) Mandibular lingual wire retainer canine to canine. (C, D) The ultimate retention is dental intercuspatation. The mandibular buccal cusps seat into the maxillary central fossae, and the maxillary buccal cusps lock outside the mandibular buccal cusps. Postsurgery changes of arch form and width, which occur, are coordinated by maximal intercuspatation. Flat teeth do not intercuspatate and are associated with loss of arch coordination, which leads to posterior interferences and open bite. Table 1 lists the intercuspatation techniques employed.



**Figure 7.** Complex case. History: 50-year-old man; two prior orthodontic treatments, including headgear, Class II elastics, and four premolar extractions. Chief complaint: severe obstructive sleep apnea (OSA). Left: profile with centric relation waxbite. Center: centric relation CBCT reveals severe anterior open bite and Class II. Right: CBCT airway; smallest (white line) cross-sectional area 63.5 mm<sup>2</sup> (less than 100 mm<sup>2</sup>, suggestive of OSA). The sleep study revealed an Apnea Hypopnea Index (AHI) of 73 (severe OSA).

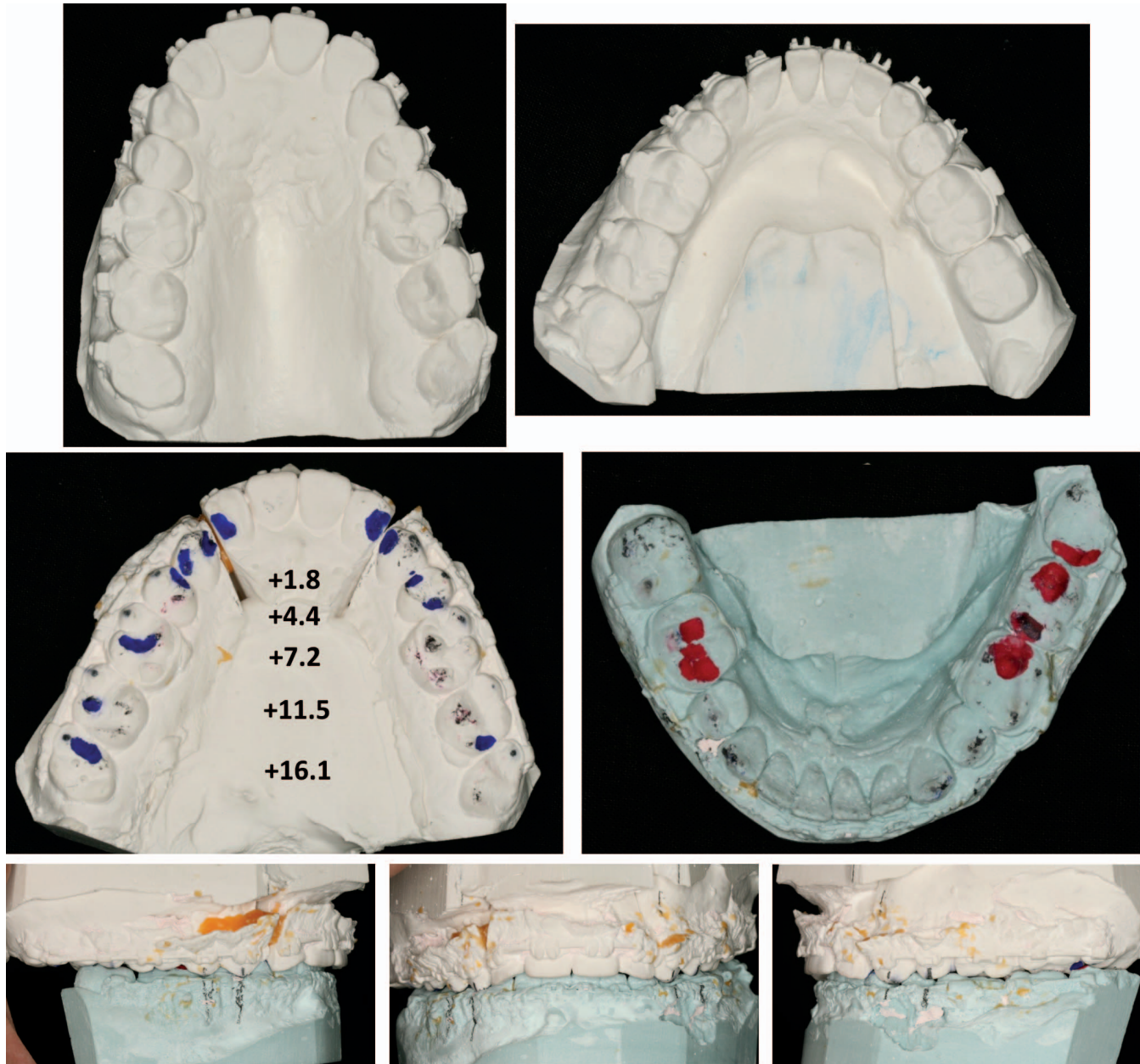


**Figure 8.** Complex case. Preorthodontic Class I handheld models. Upper arch notes: extremely narrow arch and complicated dual-plane occlusion. Lower arch notes: accentuated curve of Spee. Class I interarch relationship: severe cross bite, indicating need for extreme maxillary surgical expansion to match the mandibular width.



**Figure 9.** Complex case. Orthodontic preparation (by Richard P McLaughlin): 1-week presurgery, centric relationship bite after orthodontic preparation. Upper arch orthodontic notes: upper arch width, shape, and plane of occlusion maintained, mandatory first molar bands, brackets, and cleats in place. Lower arch orthodontic notes: curve of Spee is not flat secondary to ankylosed teeth within the arch. Anterior tooth mass note: upper arch increased with separators and lower arch decreased with interproximal reduction to allow for maximal overbite in the operating room.





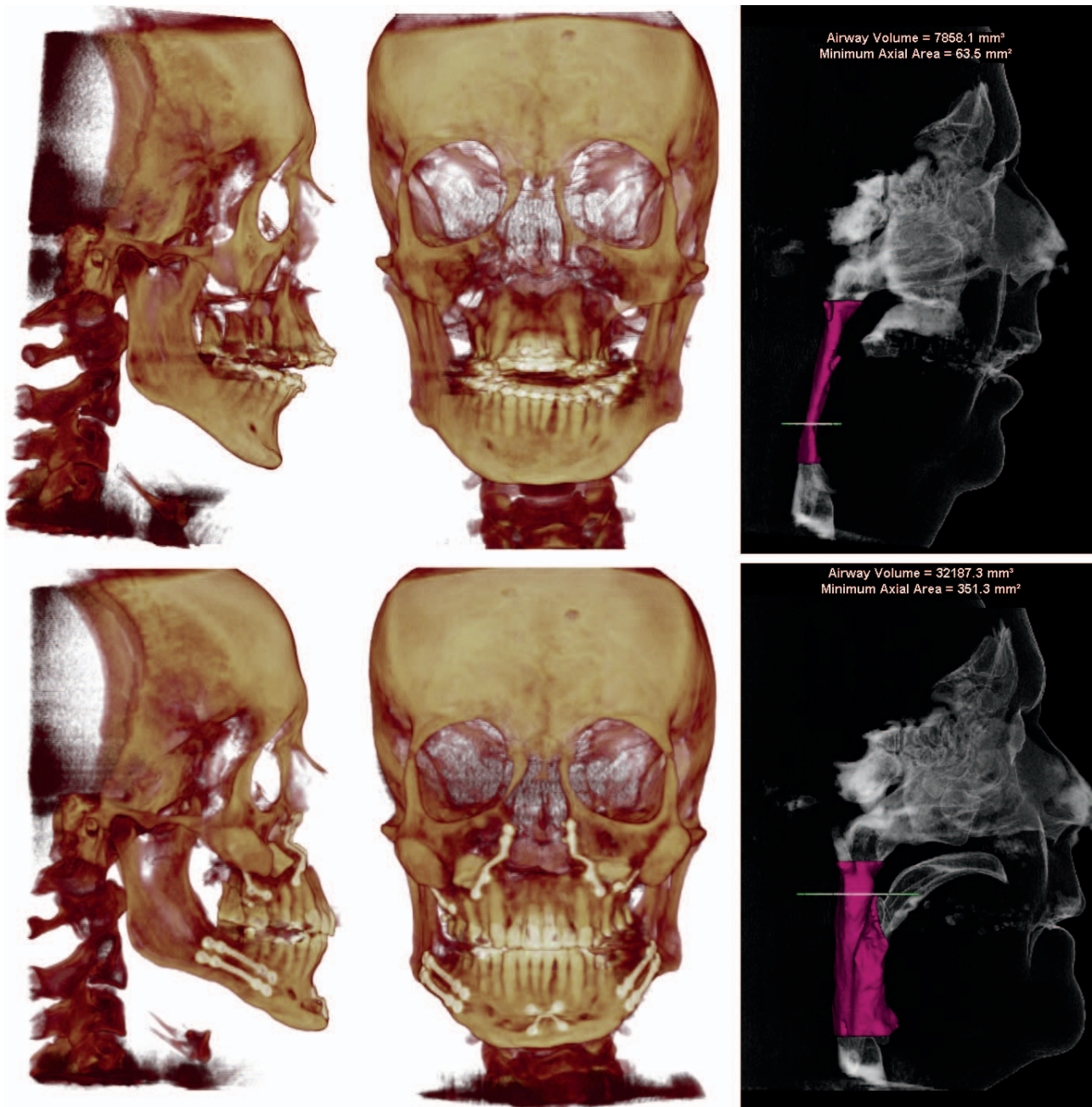
**Figure 10.** Complex case. Presurgery model surgery plan: 1 week presurgery, orthodontic preparation complete (RPM). Above left: stable upper arch orthodontic preparation. Important note: the high palatal vault indicates large expansion is feasible. Rule: high vaults expand easily, whereas low vaults do not. Above right: stable lower arch orthodontic preparation. Middle occlusal view: segmented models with equilibration and composite buccal cusp bonding. Upper arch (blue) and lower arch (red) equilibration will be duplicated in the operating room. Note the upper arch expansion of 1.8 mm at the canines and 16.1 mm at the distal molars. Maximal intercuspation is mandatory to maintain postsurgery maxillary width increase. Bottom: segmented models demonstrating excellent occlusal fit via orthodontic preparation, MSLFI, equilibration of central fossae, and buccal cusp bonding.

*Postsurgical elastics.* Elastics were managed by both the orthodontist and surgeons as listed in Table 2.

Of note, intermaxillary elastics were positioned between the mandibular 24-gauge B point skeletal wire and a 2 × 16 mm miniscrew positioned between the upper central incisors (Figure 3). These interskeletal elastics helped control skeletal open bite relapse and limited dental extrusion of the incisors, which

occurs with elastics between the upper and lower incisors. The skeletal elastics may be increased to as many as four at night; this contributes to the overbite stability as reported in Part 1. Patients were instructed to not open against elastics and to remove elastics twice daily for range-of-motion exercise.

*Postsurgical orthodontic principles.* At 8 to 10 weeks after surgery, orthodontic finishing commenced with



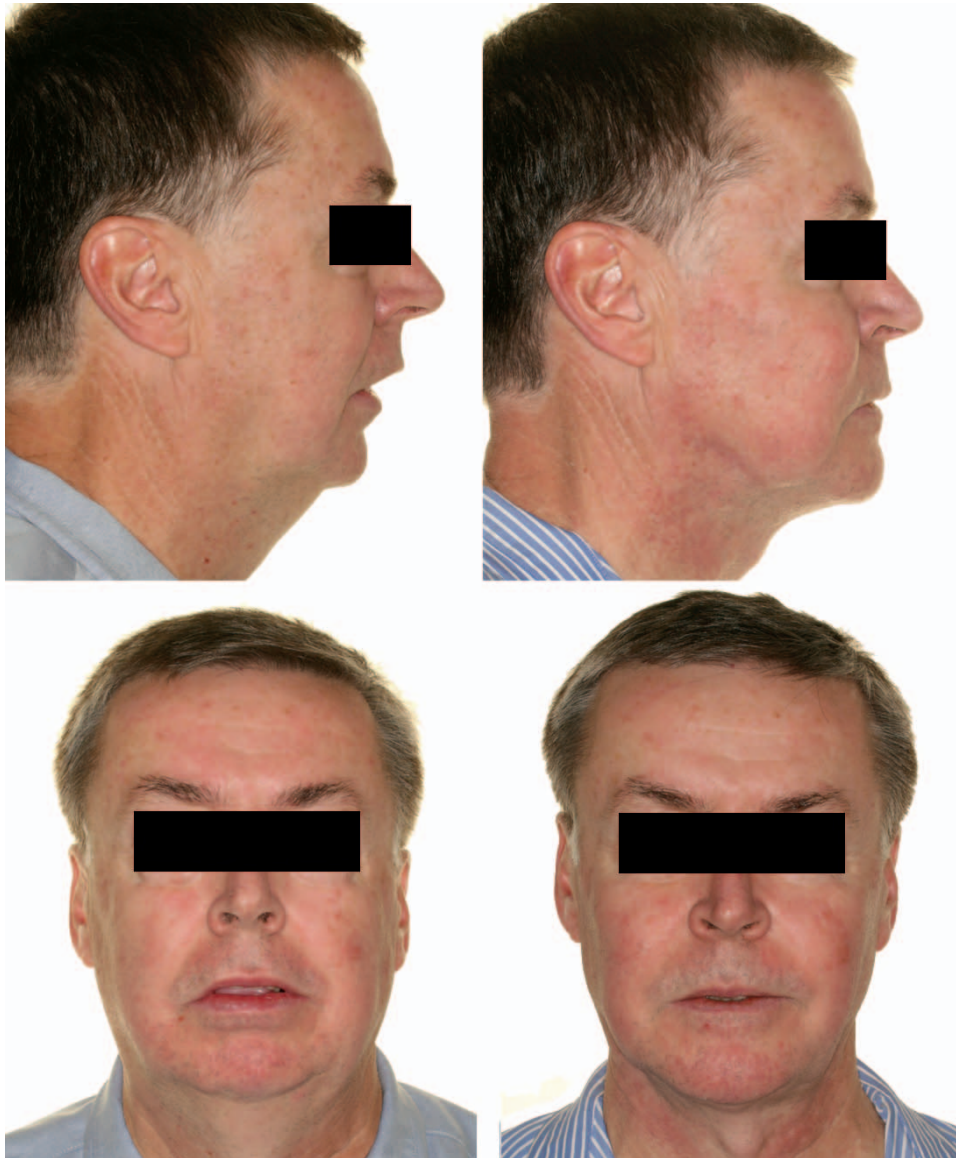**Figure 11.** Complex case. CBCT. Top row left: severe Class II anterior open bite. Top row center: maxillary midline deviation right, lower occlusal plane canted down to the patient's left. Top row right: airway volume 7868 mm<sup>3</sup> (<10,000 is suggestive of OSA), minimal cross-sectional area 63.5 mm<sup>2</sup> (<100 mm<sup>2</sup> is suggestive of OSA). Bottom row postsurgery: face, airway, bite correction with bimaxillary counterclockwise (CCW) advancement, cheekbone augmentations, small chin augmentation, and submental lipectomy. Note airway changes: volume 4.1× increase (7868 mm<sup>3</sup> to 32,187 mm<sup>3</sup>) and cross-sectional increase 5.5× (63.5 mm<sup>2</sup> to 351 mm<sup>2</sup>).

the first archwire change. At this archwire change, the orthodontist placed passive continuous upper and lower wires to maintain the postsurgical occlusion and maintain maximal intercuspation. The occlusions were excellent at 8 to 10 weeks, so a passive archwire to maintain the bite was mandatory. To assist in passive placement, the anterior six maxillary teeth were rebracketed. The first archwire changes were

critical. At 1 to 2 days after that archwire change, the patients were examined to assess for unwanted occlusal change. If unwanted change occurred, the archwires were corrected.

With orthodontic finishing, the elastics were directed by the orthodontist as described in Table 2.

A maxillary transpalatal bar (Figure 5A) and/or cross arch elastics (Figure 5B) were used for 3 months after



**Figure 12.** Complex case. Facial changes. Top left, profile presurgery: midface projection normal, large nose, upper lip retrusion (history: upper premolar extractions, headgear, Class II elastics), severe lower lip/chin retrusion, and extremely short throat length. Top right, profile postsurgery: note postsurgery profile balance of midface, nose, upper lip, chin, and throat. Bottom left, frontal presurgery: vertical normal and total lack of mandibular outline and throat length definition. Bottom right, frontal postsurgery: note definition of mandibular outline and throat length. (Authors' note: the corrected Class I occlusion was placed to maximize facial esthetics and airway size.)

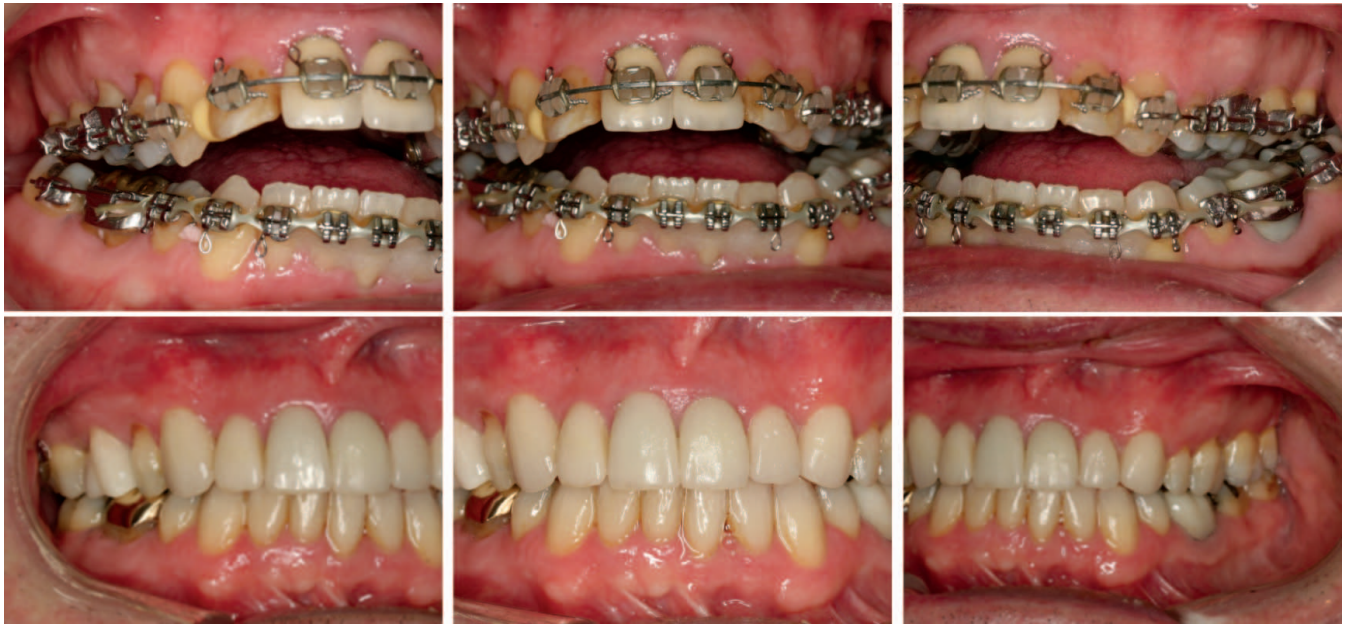surgery for larger expansions. The transpalatal bar was placed 1 week after surgery by the orthodontist when the second molar expansion was greater than 4 mm or when a presurgery flat palatal vault was present; flat vaults are very prone to expansion tension and relapse (Figure 5A). Approximately 8 months after surgery, after removal of the orthodontic appliances, a maxillary wrap-around retainer was used for 24 months. The retainer design stabilized the dental arch while allowing maximal intercuspation to hold maxillary width increases (Figure 5). A long-lasting lingual wire retainer was positioned on the mandibular anterior teeth from

canine to canine (Figure 6). Ultimately, intercuspation is the best retention (Figures 4 and 6).

A very difficult, complex case is presented in Figures 7–13 to emphasize the orthodontic and surgical techniques and principles employed in Parts 1 and 2 of this article.

## DISCUSSION

The objective of Part 1 of this study was to evaluate long-term stability based on strict orthodontic and surgical concepts in occlusal reconstruction. It was revealed that occlusal stability produced by one



**Figure 13.** Complex case. Bite photos. Above: immediate presurgical bite photos. Below: 36-month bite photos. Note: intercuspatation maintained the extreme width increase of the maxillary arch. The simple stability answer is excellent orthodontic preparation, dental reconstruction to produce maximal intercuspatation, and surgery designed for stability (Table 1). The patient had the braces removed (9 months postsurgery) and immediately had equilibration and enhanced maxillary buccal cusp bonding to further stabilize the transverse expansion of the maxilla after orthodontics.

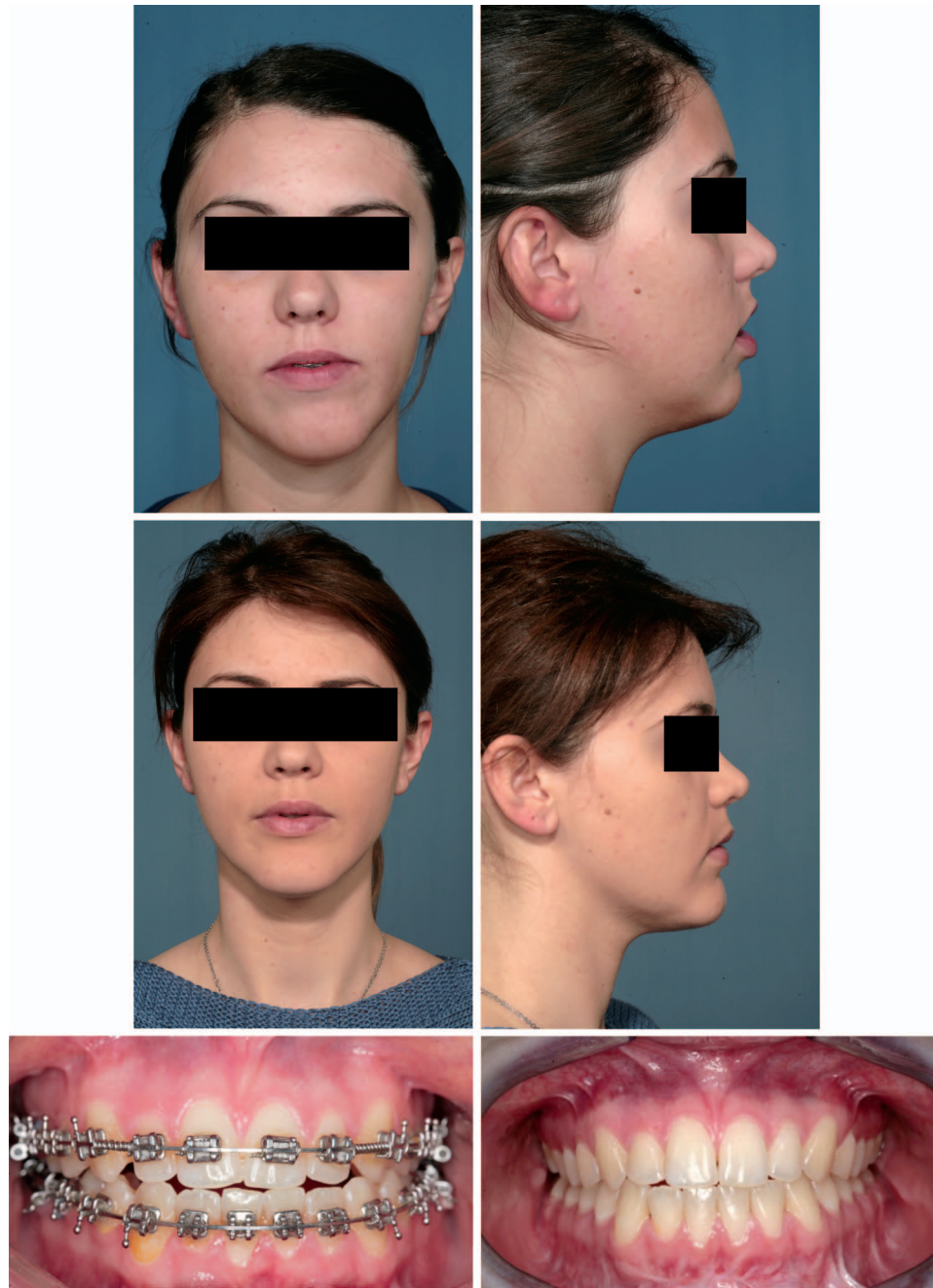orthodontist and two surgeons, using strict treatment protocols, was excellent in all planes of space.

Orthodontic relapse following orthodontic bite correction has been well documented.<sup>2-4,8,16-19,21-26,30</sup> In addition, surgical anterior open bite closure has been reported as unstable. It should be recognized that the net relapse after a surgery is the sum of the orthodontic relapse and the actual surgical relapse. Denison et al.<sup>31</sup> reported significant long-term surgical open bite relapse. However, Denison et al.<sup>31</sup> and many others used large orthodontic tooth movements to match upper and lower arch forms, arch widths, and occlusal planes to limit surgery to a one- or two-piece LFI. It is probable that Denison et al.<sup>31</sup> and others reporting surgical relapse were, in fact, reporting combined orthodontic and surgical relapse on surgical cases. In this study, the arch forms, arch widths, and maxillary plane of occlusion were maintained during orthodontic preparation, therefore limiting orthodontic relapse postsurgery. In fact, the upper archwire was cut 4 months presurgery to ensure the upper arch would be orthodontically stable. In this study, the possibility of orthodontic relapse was reduced as far as possible. Orthodontic tooth movement distances were minimal, leading to minimal orthodontic relapse after surgery in these patients. Relapse after surgery under these circumstances (limiting orthodontic relapse) is owned by the surgeons. A systematic literature review by Haas

Junior et al.<sup>32</sup> found that segmental LFI expansion relapse was more dental (orthodontic) than skeletal (surgical), which supports the methodology presented of limiting orthodontic tooth movement before surgery.

In the literature, open bite relapse is common.<sup>2,4-6,8</sup> In this study, the long-term overbite was  $2.21 \pm 0.63$  at a minimum of 36 months of follow-up. Overbite relapse was  $-0.21 \pm 0.61$  mm, a small amount. Of the patients, 60% (18/30) showed no long-term open bite relapse, whereas 40% (12/30) experienced variable degrees of overbite relapse. Among the 12 relapse patients at long term, nine had positive overbites between 2–4 mm and three had positive overbites between 0.5 and 2 mm. Of the 30 patients, only one had an overbite of 0.5 mm, which is minimal (see Figure 14). These results are in stark contrast to other studies<sup>10,31-36</sup> reporting much greater open bite relapse.

Haymond et al.<sup>15</sup> and others have stated that transverse maxillary relapse opens the bite by producing posterior interferences; this did not happen in the current study. In this study, although there was statistically significant width relapse at the maxillary first and second molars, this relapse did not produce anterior open bite. The reason that maxillary width relapse did not open the bite was that, long term, the lower arch narrowed simulta-



**Figure 14.** This patient presented from Part 1 of this study. Above: presurgery facial photos. Middle: facial photos 5 years after bimaxillary surgery. Bottom left: bite 4 months presurgery, immediately before sectioning of the maxillary archwire. Bottom right: bite 5 years postsurgery. Note: positive overbite of 0.5 mm at the central incisors and canine contact, which allows disocclusion with lateral mandibular movements. This case is shown because this patient represents the least overbite of the 30 patients published in Part 1 of this article.

neously with the upper arch, therefore maintaining posterior intercuspation.

**CONCLUSIONS**

- The results in this retrospective study demonstrate

that bimaxillary counterclockwise correction of dental skeletal open bite is clinically safe and stable.

- The procedures, as outlined in the articles, resulted in the stable treatment of overjet, overbite, arch form, arch width, and maxillary accentuated curve of Spee deformities.

- To duplicate these results, treatment must adhere to specific orthodontic and surgical principles to minimize orthodontic relapse and optimize the predictability and stability of the surgical results.

## SUPPLEMENTAL DATA

Part 1 Tables 1–5 are available online in Part 1, published in *The Angle Orthodontist*, Volume 92, No. 2.

## REFERENCES

1. Subtelny JD, Sakuda M. Open-bite: diagnosis and treatment. *Am J Orthod.* 1964;50(5):337–358.
2. Lopez-Gavito G, Wallen TR, Little RM, Joondeph DR. Anterior open-bite malocclusion: a longitudinal 10-year postretention evaluation of orthodontically treated patients. *Am J Orthod* 1985;87(3):175–186.
3. Di Carlo G, Saccucci M, Ierardo G, et al. Rapid maxillary expansion and upper airway morphology: a systematic review on the role of cone beam computed tomography. *BioMed Research Inter.* 2017;2017:5460429.
4. De Freitas MR, Beltrão RTS, Janson G, Henriques JFC, Cañado RH. Long-term stability of anterior open bite extraction treatment in the permanent dentition. *Am J Orthod Dentofacial Orthop.* 2004;125(1):78–87.
5. Janson G, Valarelli FP, Henriques JFC, de Freitas MR, Cañado RH. Stability of anterior open bite nonextraction treatment in the permanent dentition. *Am J Orthod Dentofacial Orthop.* 2003;124(3):265–276; quiz 340.
6. Remmers D, Van'T Hullenaar RWGJ, Bronkhorst EM, Bergé SJ, Katsaros C. Treatment results and long-term stability of anterior open bite malocclusion. *Orthod Craniofacial Res.* 2008;11(1):32–42.
7. Akay MC, Aras A, Günbay T, Akyalçın S, Koyuncue BO. Enhanced effect of combined treatment with corticotomy and skeletal anchorage in open bite correction. *J Oral Maxillofac Surg.* 2009;67(3):563–569.
8. Baek MS, Choi YJ, Yu HS, Lee KJ, Kwak J, Park YC. Long-term stability of anterior open-bite treatment by intrusion of maxillary posterior teeth. *Am J Orthod Dentofacial Orthop.* 2010;138(4):396.e1–396.e9.
9. Zuroff JP, Chen SH, Shapiro PA, Little RM, Joondeph DR, Huang GJ. Orthodontic treatment of anterior open-bite malocclusion: stability 10 years postretention. *Am J Orthod Dentofacial Orthop.* 2010;137(3):302.e1–302.e8.
10. Proffit WR, Turvey TA, Phillips C. Orthognathic surgery: a hierarchy of stability. *Int J Adult Orthodon Orthognath Surg.* 1996;11(3):191–204.
11. Arnett GW, Bergman RT. Facial keys to orthodontic diagnosis and treatment planning—part II. *Am J Orthod Dentofacial Orthop.* 1993;103(5):395–411.
12. Arnett GW, Jelic JS, Kim J, et al. Soft tissue cephalometric analysis: diagnosis and treatment planning of dentofacial deformity. *Am J Orthod Dentofacial Orthop.* 1999;116(3):239–253.
13. Arnett GW, Gunson MJ. Esthetic treatment planning for orthognathic surgery. *J Clin Orthod.* 2010;44(3):196–200.
14. Arnett GW, Gunson MJ. Facial planning for orthodontists and oral surgeons. *Am J Orthod Dentofacial Orthop.* 2004;126(3):290–295.
15. Haymond CS, Stoelinga PJW, Blijdorp PA, Leenen RJ, Merkens NM. Surgical orthodontic treatment of anterior skeletal open bite using small plate internal fixation. One to five year follow-up. *Int J Oral Maxillofac Surg.* 1991;20(4):223–227.
16. Simons ME, Joondeph DR. Change in overbite: a ten-year postretention study. *Am J Orthod.* 1973;64(4):349–367.
17. Little RM, Riedel RA, Stein A. Mandibular arch length increase during the mixed dentition: postretention evaluation of stability and relapse. *Am J Orthod Dentofacial Orthop.* 1990;97(5):393–404.
18. McReynolds DC, Little RM. Mandibular second premolar extraction—postretention evaluation of stability and relapse. *Angle Orthod.* 1991;61(2):133–144.
19. Uhde MD, Sadowsky C, BeGole EA. Long-term stability of dental relationships after orthodontic treatment. *Angle Orthod.* 1983;53(3):240–252.
20. Canan S, Şenışık NE. Comparison of the treatment effects of different rapid maxillary expansion devices on the maxilla and the mandible. Part 1: evaluation of dentoalveolar changes. *Am J Orthod Dentofacial Orthop.* 2017;151(6):1125–1138.
21. Swanson WD, Riedel RA, D'Anna JA. Postretention study: incidence and stability of rotated teeth in humans. *Angle Orthod.* 1975;45(3):198–203.
22. Sinclair PM, Little RM. Maturation of untreated normal occlusions. *Am J Orthod.* 1983;83(2):114–123.
23. Staley RN, Stuntz WR, Peterson LC. A comparison of arch widths in adults with normal occlusion and adults with Class II, Division 1 malocclusion. *Am J Orthod.* 1985;88(2):163–169.
24. Felton JM, Sinclair PM, Jones DL, Alexander RG. A computerized analysis of the shape and stability of mandibular arch form. *Am J Orthod Dentofacial Orthop.* 1987;92(6):478–483.
25. Glenn G, Sinclair PM, Alexander RG. Nonextraction orthodontic therapy: posttreatment dental and skeletal stability. *Am J Orthod Dentofacial Orthop.* 1987;92(4):321–328.
26. Harris EF, Behrents RG. The intrinsic stability of Class I molar relationship: a longitudinal study of untreated cases. *Am J Orthod Dentofacial Orthop.* 1988;94(1):63–67.
27. Wertz RA. Skeletal and dental changes accompanying rapid midpalatal suture opening. *Am J Orthod.* 1970;58(1):41–66.
28. Arnett GW, Trevisiol L, Grendene E, McLaughlin RP, D'Agostino A. Combined orthodontic and surgical open bite correction - Part 1. *Angle Orthod.* 2022; 92(2):161–172.
29. Lima AC, Lima AL, Filho RMAL, Oyen OJ. Spontaneous mandibular arch response after rapid palatal expansion: a long-term study on Class I malocclusion. *Am J Orthod Dentofacial Orthop.* 2004;126(5):576–582.
30. Adkins MD, Nanda RS, Currier GF. Arch perimeter changes on rapid palatal expansion. *Am J Orthod Dentofacial Orthop.* 1990;97(3):194–199.
31. Denison TF, Kokich VG, Shapiro PA. Stability of maxillary surgery in openbite versus nonopenbite malocclusions. *Angle Orthod.* 1989;59(1):5–10.
32. Haas Junior OL, Gujjarro-Martínez R, de Sousa Gil AP, da Silva Meirelles L, de Oliveira RB, Hernández-Alfaro F. Stability and surgical complications in segmental Le Fort I osteotomy: a systematic review. *Int J Oral Maxillofac Surg.* 2017;46(9):1071–1087.

33. Burford D, Noar JH. The causes, diagnosis and treatment of anterior open bite. *Dent Update*. 2003;30(5):235–241.
34. Tanaka E, Tanaka M, Watanabe M, Del Pozo R, Tanne K. Influences of occlusal and skeletal discrepancies on biomechanical environment in the TMJ during maximum clenching: an analytic approach with the finite element method. *J Oral Rehabil*. 2001;28(9):888–894.
35. Proffit WR, Turvey TA, Phillips C. The hierarchy of stability and predictability in orthognathic surgery with rigid fixation: an update and extension. *Head Face Med*. 2007;3(1):21.
36. Shapiro PA. Stability of open bite treatment. *Am J Orthod Dentofacial Orthop*. 2002;121(6):566–568.