

DOI: 10.17650/1683-3295-2021-23-4-82-86



ЭНДОСКОПИЧЕСКОЕ УДАЛЕНИЕ ЖЕЛУДОЧКОВОГО КАТЕТЕРА У ПАЦИЕНТА ГРУППЫ ВЫСОКОГО РИСКА

A. Puzzolante¹, G. Pavesi¹, A. Feletti²¹Department of Neurosciences, Unit of Neurosurgery, OCSAE Modena Hospital; Via Giardini 1355, 41121 Modena, Italy;²Department of Neurosciences, Biomedicine, and Movement Sciences, Institute of Neurosurgery, University of Verona; Piazzale Stefani 1, 37126 Verona, Italy**Контакты:** Alberto Feletti alberto.feletti@univr.it

Введение. Вентрикулоперитонеальное шунтирование ассоциировано с достаточно высоким риском осложнений, которые могут потребовать проведения нескольких повторных хирургических вмешательств в течение жизни пациента. Наиболее частым осложнением является обструкция желудочкового катетера, который может врастать в спайки с сосудистым сплетением, эпендимальной тканью, участками фиброза. В подобных случаях, а также при наличии внутрижелудочковой опухоли удаление желудочкового катетера необходимо проводить с особой осторожностью. Образование спаек с наконечником желудочкового катетера значительно повышает риск опасности для жизни кровотечения.

Материалы и методы. В статье представлен случай проксимальной ревизии вентрикулоперитонеального шунта у пациента с болезнью Гиппеля–Линдау. Нейроэндоскопическое обследование, направленное на восстановление проходимости желудочковой системы, позволило обнаружить фиброзную адгезию между кончиком катетера и гемангиобластомой гипофиза, примыкающей к III желудочку.

Обсуждение. Гемангиобластома редко поражает стемель гипофиза, однако эта локализация является наиболее частой супратенториальной локализацией у пациентов с болезнью Гиппеля–Линдау. В описанном и подобных ему клинических наблюдениях ревизия шунта с помощью эндоскопа позволяет визуализировать кончик желудочкового катетера и возможные спайки, которые могут быть коагулированы и рассечены простыми методами без риска осложнений для пациентов.

Заключение. При выполнении ревизии вентрикулоперитонеального шунта у пациентов с сопутствующими внутрижелудочковыми опухолями или при наличии участков с высоким риском кровотечения необходим нейроэндоскопический контроль для снижения риска внутрижелудочкового кровоизлияния.

Ключевые слова: ревизия вентрикулоперитонеального шунта, гемангиобластома стебля гипофиза, болезнь Гиппеля–Линдау, нейроэндоскопия

Для цитирования: Puzzolante A., Pavesi G., Feletti A. Эндоскопическое удаление желудочкового катетера у пациента группы высокого риска. Нейрохирургия 2021;23(4):82–6. (На англ.). DOI: 10.17650/1683-3295-2021-23-4-82-86.

Endoscopic-assisted removal of ventricular catheter in high-risk patients

A. Puzzolante¹, G. Pavesi¹, A. Feletti²¹Department of Neurosciences, Unit of Neurosurgery, OCSAE Modena Hospital; Via Giardini 1355, 41121 Modena, Italy;²Department of Neurosciences, Biomedicine, and Movement Sciences, Institute of Neurosurgery, University of Verona; Piazzale Stefani 1, 37126 Verona, Italy**Contacts:** Alberto Feletti alberto.feletti@univr.it

Introduction. Ventriculoperitoneal shunt carries a non-negligible failure rate often requiring multiple surgical procedures during patient's lifetime. The most common cause is obstruction of the ventricular catheter that can be embedded in adhesions with choroid plexus, ependymal tissue, and fibrous material. In such cases, or when an intraventricular tumor is present, particular attention must be paid when removal of the ventricular catheter is required. The potential adhesions with the tip of the ventricular catheter results in an increased risk of life-threatening hemorrhage.

Materials and methods. We present the case of a ventriculoperitoneal shunt proximal revision in a von Hippel–Lindau affected patient. The neuroendoscopic exploration to restore the patency of the ventricular system made it possible to notice a fibrous adhesion between the tip of the catheter and a pituitary hemangioblastoma abutting into the third ventricle.

Discussion. Pituitary stalk hemangioblastoma is an infrequent localization, although it represents the most common supratentorial site of hemangioblastoma in patients affected by von Hippel–Lindau syndrome. In this and in similar cases, endoscopic-assisted shunt revision allows visualizing the tip of the ventricular catheter and eventual adhesions that can be coagulated and cut by simple maneuvers, without any morbidity for patients.

Conclusion. In a ventriculoperitoneal shunt revision with the concomitant presence of an intraventricular tumor or lesion at risk of bleeding, the surgical procedure should be performed under neuroendoscopic observation to reduce the risk of intraventricular hemorrhage.

Key words: ventriculoperitoneal shunt revision, pituitary stalk hemangioblastoma, von Hippel–Lindau disease, neuroendoscopy

For citation: Puzzolante A., Pavesi G., Feletti A. Endoscopic-assisted removal of ventricular catheter in high-risk patients. *Neurokhirurgiya = Russian Journal of Neurosurgery* 2021;23(4):82–6. DOI: 10.17650/1683-3295-2021-23-4-82-86.

INTRODUCTION

The standard treatment of non-obstructive hydrocephalus is the placement of a ventriculoperitoneal (VP) shunt. Although it is a very common procedure in neurosurgery, unfortunately it has a non-negligible rate of failure and morbidity with a mean of 2.2 reoperations per patient in 23.3 % of cases [1]. Shunt malfunction may have several causes, including obstruction, infection, pseudocyst formation, and bowel perforation. The reported rate of mechanical malfunction ranges from 8 % to 64 % [2], and it often occurs at the level of proximal catheter [3].

When the proximal catheter must be replaced, it is advisable to remove the malfunctioning system because of the possible complications of a retained catheter [4, 5]. When the VP-shunt revision is necessary in a patient with an intraventricular tumor, the removal of the ventricular catheter carries the non-negligible risk of a life-threatening bleeding, especially in case of vascular lesions as hemangioblastomas (HB). Intraventricular location is quite uncommon for HBs, representing 3 % of all von Hippel–Lindau (VHL) – associated HBs [6], being the pituitary stalk the most common supratentorial site for supratentorial HBs.

We present the case of a VP-shunt revision performed in a VHL-affected woman with a conservatively managed pituitary stalk HB. The use of neuroendoscopy to remove the proximal obstructed catheter allowed cutting a fibrous adhesion between the HB and the tip of the catheter, avoiding intraventricular hemorrhage.

CASE REPORT

A 44-year-old woman affected by VHL disease was admitted to our hospital because of headache, worsening of tetraparesis and drowsiness. Her medical history was significant for several operations to resect three cerebellar and one bulbar HBs, and for a left frontal VP-shunt placement. The patient harbored new HBs at the pituitary stalk, obex and cervico-medullary junction that were managed conservatively. The HB of the obex consisted of a little mural nodule and a large associated cyst. Emergency head CT scan showed hydrocephalus (Fig. 1) and trapped fourth ventricle. A neuroendoscopic exploration was performed with a flexible scope (Karl Storz, Tuttlingen, Germany) through an already existing right precoronal burr hole, in order to explore the ventricular

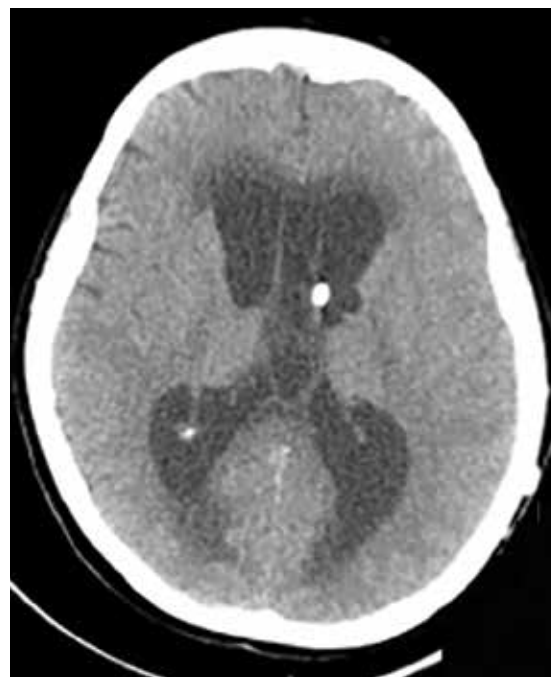

Fig. 1. Preoperative CT scan showing hydrocephalus with transependymal edema in a malfunctioning left ventriculoperitoneal shunt

system and restore its patency. The aqueduct was obstructed by a membrane, which was fenestrated. Moreover, the outlets of the fourth ventricle were also obstructed, in particular a cyst associated to the small HB of the obex was closing the Magendie foramen and was therefore fenestrated. We decided to replace the ventricular catheter with a longer catheter which could drain both supratentorial and infratentorial ventricles. However, in the third ventricle we noticed a fibrous band between the ventricular catheter tip and the HB of the pituitary stalk (Fig. 2, 3) that was stretched when we tried to remove the catheter. After coagulation, using endoscopic forceps we detached the fibrous band from the catheter (Fig. 4). Ventricular catheter removal was uneventful. A new right catheter was placed into the fourth ventricle under direct endoscopic vision and connected to the valve of the shunt. The patient fully recovered, and a postoperative magnetic resonance imaging showed initial reduction of hydrocephalus and ruled out any complication (Fig. 5, 6).

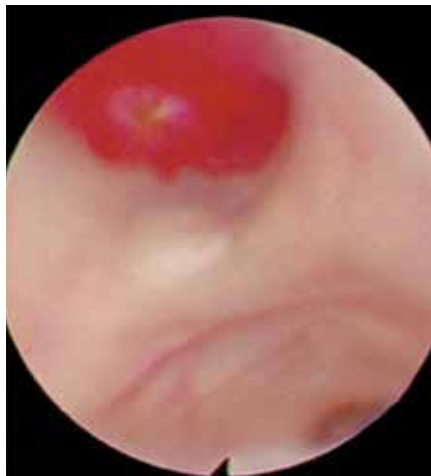

Fig. 2. Intraoperative endoscopic view of the vascular pituitary stalk hemangioblastomas

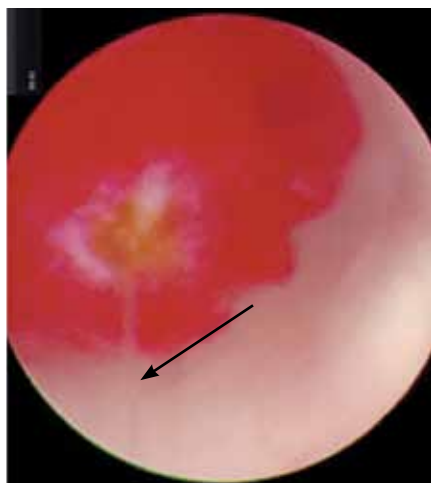

Fig. 3. Intraoperative image showing the fibrous band (arrow) attached to the hemangioblastomas with an inflammatory reaction on its surface

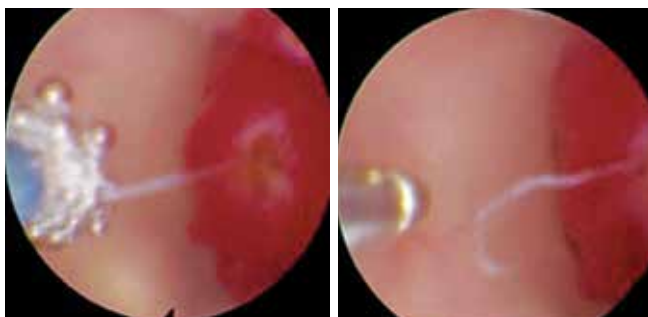

Fig. 4. Coagulation with monopolar (left) and detachment with forceps (right) of the adhesion

DISCUSSION

VHL disease is a neoplastic multisystemic autosomal-dominant disorder resulting from germline mutation or deletion of the VHL tumor suppressor gene mapped on the short arm of chromosome 3 (3p25–p26) [7], predisposing to develop benign and malignant tumors of kidney,

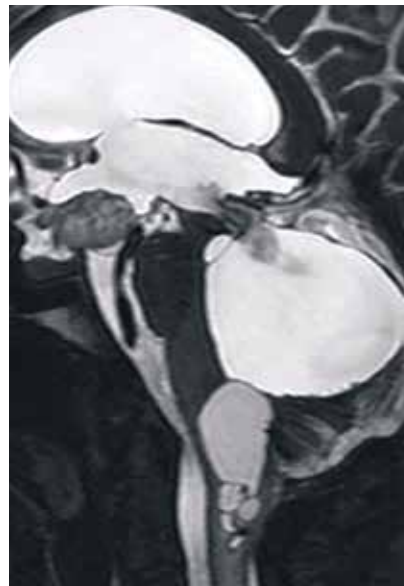


Fig. 5. Postoperative sagittal T2-weighted magnetic resonance imaging showing the flow from fourth ventricle, the cysts associated with obex and bulb-medullary junction hemangioblastomas without hemorrhagic complications

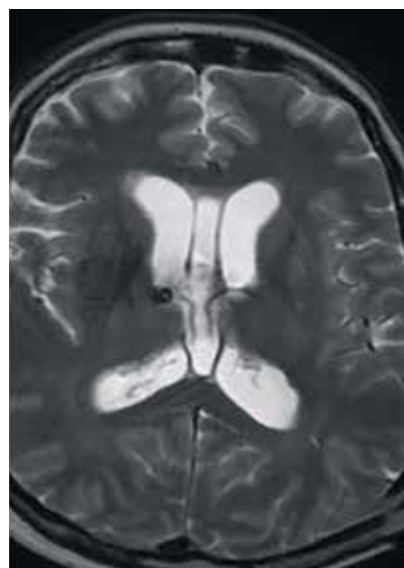


Fig. 6. Postoperative axial T2-weighted magnetic resonance imaging showing the initial reduction of hydrocephalus and the ventricular catheter placed in right ventricle

adrenal gland, pancreas and, particularly, multiple central nervous system HBs and endolymphatic sac tumors [8]. Although included in the list of rare diseases, VHL syndrome is not uncommon, accounting for about 1 case in 36.000 live births and having a highly penetrant autosomal dominant trait [9]. For this reason, it is likely a neurosurgeon will face this disease during his clinical practice, and knowledge about the management of tumors related to VHL syndrome is mandatory.

HBs are benign vascular tumors that occur sporadically or as part of VHL syndrome. Central nervous system HBs

originate more frequently in the cerebellum, the spinal cord and the brainstem, while supratentorial location is rare. Wanebo reported supratentorial location in 4 % of 231 patients with VHL syndrome [10]. In a large series of 250 patients with VHL disease, R.R. Lonser et al. reported that 11 % of patients had supratentorial HBs and the most common supratentorial site was the pituitary stalk, accounting for 29 % of supratentorial HBs and 3 % of all VHL-affected patients [6]. All patients with HB of the pituitary stalk were asymptomatic, with normal endocrinological laboratory profile and ophthalmological examination. Furthermore, the clinical follow up was uneventful, suggesting a conservative management of HBs of pituitary stalk [6, 11]. Surgery for both sporadic and VHL-related suprasellar HBs is indicated for symptomatic lesions [12]. Conversely, our patient experienced amenorrhea and severe osteoporosis; pituitary – thyroid axis function and cortisol levels were preserved. Considering the clinical, endocrine work-up and neuroradiological stability, we decided not to remove the pituitary stalk HB avoiding the high surgical morbidity represented by panhypopituitarism. VHL patients harbor multiple HBs, especially in the posterior fossa, requiring several surgical procedures. In the context of a multidisciplinary clinical surveillance considering a favorable impact on quality of life and survival of VHL-patients, not all of these lesions must be removed at the initial radiological evidence and can be monitored during lifetime [13]. Therefore, during the twenty-year medical history of our patient, three HBs of cerebellum and a HB of bulb were removed, while a HB of the obex and a cervico-medullary HB were treated conservatively. Because of the several posterior fossa operations and the cysts related to the untreated HBs, our patient developed an obstructive hydrocephalus requiring a VP-shunt. VP-shunt operation for the treatment of hydrocephalus is one of the most common procedures performed in neurosurgery, but it has a not negligible rate of shunt failure and carries a high morbidity rate with a mean of 2.2 reoperations per patient in 23.3 % of patients [1].

In over a 1-year period of admissions related to shunt surgery procedures in the United States, shunt dysfunction accounted for 40.7 %, non-communicating hydrocephalus for 16.6 % and communicating hydrocephalus for 13.2 %; shunt infection was the primary diagnosis in 7.2 % of admissions [14]. In a review of the neurosurgery literature about adverse events in CSF shunt surgery, the reported rate of mechanical malfunction ranged from 8 % to 64 % [2]. VP-shunt malfunction is most commonly caused by obstruction of the ventricular catheter [3]. This obstruction is usually caused by choroid plexus, less frequently by epen-

dymal tissue; fibrous and cellular material was also found [15]. Tissue or adhesions can be embedded in the proximal catheter producing its occlusion and subsequent shunt malfunction. Patients with obstructed shunt and increased intracranial pressure need urgent shunt revision and it is advisable to remove the obstructed ventricular catheter, because of the possible complications for a retained catheter. These include: the development of a granuloma resulting of the persistent chronic inflammatory reactions between the ventricular catheter left in situ and the brain parenchyma [4]; infection of the catheter itself due to its prosthetic nature, resulting in CSF infection or pericatheter brain abscess formation [5]. In some cases, when performing a VP-shunt revision, the removal of ventricular catheter is not feasible for the risk of life-threatening intraventricular hemorrhage. Several maneuvers can be used to remove the ventricular catheter: exerting a gentle traction on the catheter, rotating the catheter, placing a hemostatic clip on the protruding catheter allowing the weight of the clip to provide traction, passing a stylet down the lumen of the catheter placed in contact with a monopolar diathermy instrument with choroid plexus coagulation [16]. Sometimes these techniques fail, but currently neuroendoscopy is an available and widespread tool used in proximal shunt revisions. Endoscopic-assisted procedures allow retrieving left or lost ventricular catheter or parts of them, to visualize catheter adhesions to the choroid plexus or the ependyma and cut them after monopolar coagulation [17].

In our case of proximal shunt revision in the context of an intraventricular vascular tumor conservatively managed, attention must be paid to remove the ventricular catheter that had adhesions with the tumor at risk of bleeding. This hemorrhagic event could be avoided with the aid of neuroendoscopy, which is a well-consolidated tool available in many centers. The constant visualization of the tip of the ventricular catheter, the possibility of coagulation and cutting made endoscopic-assisted shunt revision safer by simple maneuvers, without any morbidity for our patient.

CONCLUSION

Nowadays, neuroendoscopy is a well-consolidated tool that allows restoring ventricular patency avoiding major posterior fossa surgery, to safely remove a ventricular catheter wrapped in adhesions to choroid plexus or ependyma. Mostly when a shunt revision is needed in a patient harbouring an intraventricular vascular tumor, like suprasellar HB, which are more frequent in VHL-affected patients, the use of neuroendoscopy should be mandatory to reduce the risk of intraventricular hemorrhage.

ЛИТЕРАТУРА / REFERENCES

- Korinek A.M., Fulla-Oller L., Boch A.L. et al. Morbidity of ventricular cerebrospinal fluid shunt surgery in adults: an 8-year study. *Neurosurgery* 2011;68(4):985–94. DOI: 10.1227/NEU.0b013e318208f360.
- Wong J.M., Ziewacz J.E., Ho A.L. et al. Patterns in neurosurgical adverse events: cerebrospinal fluid shunt surgery. *Neurosurg Focus* 2012;33(5):E13. DOI: 10.3171/2012.7.FOCUS12179.
- Browd S.R., Ragel B.T., Gottfried O.N., Kestle J.R. Failure of cerebrospinal fluid shunts: part I: Obstruction and mechanical failure. *Pediatr Neurol* 2006;34(2):83–92. DOI: 10.1016/j.pediatrneurol.2005.05.020.
- Iaquinandì A., Corrivetti F., Lunardi P. et al. Brain granuloma: rare complication of a retained catheter. *World Neurosurg* 2018;110:210–6. DOI: 10.1016/j.wneu.2017.11.066.
- Gupta R., Mohindra S., Dhingra A.K. Are non-functioning intraventricular shunt catheters really dormant? *Br J Neurosurg* 2017;21(3):297–8. DOI: 10.1080/02688690701317151.
- Lonser R.R., Butman J.A., Kiringoda R. et al. Pituitary stalk hemangioblastomas in von Hippel–Lindau disease. *J Neurosurg* 2009;110(2):350–3. DOI: 10.3171/2008.4.17532.
- Latif F., Tory K., Gnarr J. et al. Identification of the von Hippel–Lindau disease tumor suppressor gene. *Science* 1993;260(5112):1317–20. DOI: 10.1126/science.8493574.
- Friedrich C.A. Von Hippel–Lindau syndrome. A pleomorphic condition. *Cancer* 1999;86(11 Suppl):2478–82.
- Lonser R.R., Glenn G.M., Walther M. et al. Von Hippel–Lindau disease. *Lancet* 2003;361(9374):2059–67. DOI: 10.1016/S0140-6736(03)13643-4.
- Wanebo J.E., Lonser R.R., Glenn G.M., Oldfield E.H. The natural history of central nervous system hemangioblastomas in patients with von Hippel–Lindau disease. *J Neurosurg* 2003;98(1):82–94. DOI: 10.3171/jns.2003.98.1.0082.
- Fomekong E., Hernalsteen D., Godfraind C. et al. Pituitary stalk hemangioblastoma: the fourth case report and review of the literature. *Clin Neurol Neurosurg* 2007;109(3):292–8. DOI: 10.1016/j.clineuro.2006.11.007.
- Alshafai N., Maduri R., Shail M. et al. Surgical approach for suprasellar hemangioblastomas preserving the pituitary stalk: Review of the literature and report of a further case. *Clin Neurol Neurosurg* 2018;168:147–52. DOI: 10.1016/j.clineuro.2018.03.010.
- Pavesi G., Feletti A., Berlucchi S. et al. Neurosurgical treatment of von Hippel–Lindau-associated hemangioblastomas: benefits, risks and outcome. *J Neurosurg Sci* 2008;52(2):29–36.
- Patwardhan R.V., Nanda A. Implanted ventricular shunts in the United States: the billion-dollar-a-year cost of hydrocephalus treatment. *Neurosurgery* 2005;56(1):139–44. DOI: 10.1227/01.neu.0000146206.40375.41.
- Collins P., Hockley A.D., Woollam D.H. Surface ultrastructure of tissues occluding ventricular catheters. *J Neurosurg* 1978;48(4):609–13. DOI: 10.3171/jns.1978.48.4.0609.
- Whitfield P.C., Guazzo E.P., Pickard J.D. Safe removal of retained ventricular catheters using intraluminal choroid plexus coagulation. Technical note. *J Neurosurg* 1995;83(6):1101–2. DOI: 10.3171/jns.1995.83.6.1101.
- Pettorini B.L., Frassanito P., Tamburrini G. et al. Retrieval of ventricular catheter with the aid of endoscopy: technical note. *J Neurosurg Pediatr* 2008;2(1):71–4. DOI: 10.3171/PED/2008/2/7/071.

Вклад авторов

A. Puzzolante: подготовка статьи, обзор публикаций по теме статьи, написание текста рукописи, обсуждение результатов;
G. Pavesi: подготовка статьи, общее руководство, обсуждение результатов;
A. Feletti: общее руководство, обсуждение результатов.

Authors' contributions

A. Puzzolante: drafted the manuscript, performed the review of literature, wrote the manuscript, discussion of the results;
G. Pavesi: drafted the paper, supervised the work, discussion of the results;
A. Feletti: supervised the work, discussion of the results.

ORCID авторов

A. Feletti: <https://orcid.org/0000-0001-6285-3648>

Конфликт интересов. Авторы заявляют об отсутствии конфликта интересов.

Conflict of interest. The authors declare no conflict of interest.

Финансирование. Работа выполнена без спонсорской поддержки.

Financing. The work was performed without external funding.

Соблюдение прав пациентов. Пациентка подписала информированное согласие на публикацию своих данных.

Compliance with patient rights. The patient gave written informed consent to the publication of his data.

Статья поступила: 08.06.2021. **Принята к публикации:** 18.11.2021.

Article submitted: 08.06.2021. **Accepted for publication:** 18.11.2021.