

REVIEW

Current and future diagnostic and treatment strategies for patients with invasive lobular breast cancer

K. Van Baelen^{1,2}, T. Geukens^{1,3}, M. Maetens¹, V. Tjan-Heijnen⁴, C. J. Lord⁵, S. Linn^{6,7,8}, F.-C. Bidard⁹, F. Richard¹, W. W. Yang⁵, R. E. Steele⁵, S. J. Pettitt⁵, C. Van Ongeval¹⁰, M. De Schepper^{1,11}, E. Isnaldi¹, I. Nevelsteen¹², A. Smeets¹², K. Punie³, L. Voorwerk^{13,14}, H. Wildiers³, G. Floris¹¹, A. Vincent-Salomon¹⁵, P. W. B. Derksen⁶, P. Neven², E. Senkus^{16†}, E. Sawyer^{17†}, M. Kok^{13,14†} & C. Desmedt^{1*†}

¹Laboratory for Translational Breast Cancer Research (LTBCR), Department of Oncology, KU Leuven, Leuven; Departments of ²Gynaecology and Obstetrics; ³General Medical Oncology, UZ Leuven, Leuven, Belgium; ⁴Medical Oncology Department, Maastricht University Medical Center (MUMC), School of GROW, Maastricht, The Netherlands; ⁵The CRUK Gene Function Laboratory and Breast Cancer Now Toby Robins Research Centre, The Institute of Cancer Research, London, UK; ⁶Department of Pathology, University Medical Center Utrecht, Utrecht; Departments of ⁷Medical Oncology; ⁸Molecular Pathology, Netherlands Cancer Institute, Amsterdam, The Netherlands; ⁹Department of Medical Oncology, Institut Curie, UVSQ/Paris-Saclay University, Paris, France; Departments of ¹⁰Radiology; ¹¹Pathology; ¹²Surgical Oncology, UZ Leuven, Leuven, Belgium; Departments of ¹³Medical Oncology; ¹⁴Tumour Biology and Immunology, The Netherlands Cancer Institute, Amsterdam, The Netherlands; ¹⁵Department of Pathology, Institut Curie, Paris, France; ¹⁶Department of Oncology and Radiotherapy, Medical University of Gdańsk, Gdańsk, Poland; ¹⁷School of Cancer and Pharmaceutical Sciences, Faculty of Life Sciences and Medicine, Guy's Cancer Centre, King's College London, London, UK



Available online 21 May 2022

Background: Invasive lobular breast cancer (ILC) is the second most common type of breast cancer after invasive breast cancer of no special type (NST), representing up to 15% of all breast cancers.

Design: Latest data on ILC are presented, focusing on diagnosis, molecular make-up according to the European Society for Medical Oncology Scale for Clinical Actionability of molecular Targets (ESCAT) guidelines, treatment in the early and metastatic setting and ILC-focused clinical trials.

Results: At the imaging level, magnetic resonance imaging-based and novel positron emission tomography/computed tomography-based techniques can overcome the limitations of currently used imaging techniques for diagnosing ILC. At the pathology level, E-cadherin immunohistochemistry could help improving inter-pathologist agreement. The majority of patients with ILC do not seem to benefit as much from (neo-)adjuvant chemotherapy as patients with NST, although chemotherapy might be required in a subset of high-risk patients. No differences in treatment efficacy are seen for anti-human epidermal growth factor receptor 2 (HER2) therapies in the adjuvant setting and cyclin-dependent kinases 4 and 6 inhibitors in the metastatic setting. The clinical utility of the commercially available prognostic gene expression-based tests is unclear for patients with ILC. Several ESCAT alterations differ in frequency between ILC and NST. Germline *BRCA1* and *PALB2* alterations are less frequent in patients with ILC, while germline *CDH1* (gene coding for E-cadherin) alterations are more frequent in patients with ILC. Somatic *HER2* mutations are more frequent in ILC, especially in metastases (15% ILC versus 5% NST). A high tumour mutational burden, relevant for immune checkpoint inhibition, is more frequent in ILC metastases (16%) than in NST metastases (5%). Tumours with somatic inactivating *CDH1* mutations may be vulnerable for treatment with *ROS1* inhibitors, a concept currently investigated in early and metastatic ILC.

Conclusion: ILC is a unique malignancy based on its pathological and biological features leading to differences in diagnosis as well as in treatment response, resistance and targets as compared to NST.

Key words: invasive lobular breast cancer, treatment strategies, clinical management, imaging, ESCAT alterations, ongoing trials

INTRODUCTION

Invasive lobular breast cancer (ILC) is the second most commonly diagnosed type of breast cancer in women, after invasive breast cancer of no special type (NST). ILC accounts for up to 15% of all invasive breast cancers in women.^{1,2} An increase in ILC incidence was seen in the past two decades and can be partially explained by the advances in the diagnosis of ILC³ and the increased use of hormone

*Correspondence to: Prof. Christine Desmedt, Department of Oncology, Laboratory for Translational Breast Cancer Research (LTBCR), KU Leuven, Herestraat 49, O&N IV, Box 810, Leuven, 3000, Belgium. Tel: +32-16-39-33-06
E-mail: christine.desmedt@kuleuven.be (C. Desmedt).

†These authors are co-last authors.

0923-7534/© 2022 The Authors. Published by Elsevier Ltd on behalf of European Society for Medical Oncology. This is an open access article under the CC BY-NC-ND license (<http://creativecommons.org/licenses/by-nc-nd/4.0/>).

replacement therapy (HRT) in postmenopausal women.³⁻⁷ While ILC differs from NST on a clinical, histological and molecular level, in current clinical practice the histological type is barely considered when systemic treatment decisions are made. In this review, we discuss the pathological, clinical and biological differences between ILC and NST and the subsequent challenges and opportunities in ILC management.

CLINICAL PRESENTATION

In general, at diagnosis, women with ILC are slightly older than women with NST (mean age 63.4 versus 59.5 years, respectively).^{8,9} ILC is more difficult to detect through standard screening programs and presents more often as a larger tumour⁹ and with nodal involvement,¹⁰ as compared to NST. Additionally, ILC is more often multifocal.¹¹ ILC is thought to come with increased rates of bilateral disease as well¹²; however, controversy exists as Pestalozzi et al. found similar rates of bilateral disease for NST and ILC.⁹ In some series, the long-term risk of developing metastatic disease is higher for ILC in comparison to NST, even when estrogen receptor (ER)-positive ILC is compared to ER-positive NST.^{9,13} Other series, like the one from Timbres et al., found similar long-term survival rates for patients with NST and ILC.¹⁴ Late relapses are more frequently seen in patients with ILC than in patients with NST, with relapses of ILC frequently occurring >10 years after primary diagnosis.⁹ ILC has a distinct metastatic pattern with a wider metastatic spread,^{15,16} favouring serosa and including metastases in the gastrointestinal and reproductive tract. In patients with ER-positive ILC, metastases are less frequently seen in the lung, central nervous system (with the exclusion of leptomeningeal disease which is more frequent in ILC) and distant lymph nodes as compared to NST.^{9,17-21}

RISK FACTORS FOR DEVELOPING ILC

Early menarche, use of progesterone-based HRT, late age at first live birth⁴ and alcohol consumption²² are more strongly associated with the risk of developing ILC as compared to NST. Obesity in postmenopausal women does not seem to affect the risk of developing ILC over NST^{4,23} (Supplementary Figure S1, available at <https://doi.org/10.1016/j.annonc.2022.05.006>). Several studies have reported that germline *BRCA2* and *CDH1* (the gene coding for E-cadherin) mutations are associated with a high risk of developing ILC, and germline *ATM*, *CHEK2* and *PALB2* mutations are associated with a moderate risk of developing ILC.²⁴⁻²⁶ Germline *BRCA1* mutations are not associated with a clinically relevant risk of developing ILC.^{25,26} Yadav et al. also reported germline *BRCA1* and *PALB2* mutations to be significantly less frequent in patients with ILC and germline *CDH1* mutations, which also predispose to diffuse type gastric cancer, to be significantly more frequent (Table 1). While germline *CDH1* mutations are rare in patients with ILC (<1%), they appear to be more common (8%) in women with bilateral ILC.²⁷ In a study investigating 1434 women with ILC, 11% of women younger than 40 years of age had a

germline mutation associated with increased breast cancer risk.²⁴ There is also evidence that low penetrance breast cancer predisposition single nucleotide polymorphisms (SNPs) have differential effects on the development of ILC and NST, with one specific SNP for ILC at 7q34.²⁸

PATHOLOGICAL DIAGNOSIS AND CHARACTERIZATION OF ILC

According to the fifth edition of the World Health Organization's (WHO) Classification of Breast Tumours,²⁹ recognizing the non-cohesive nature, single file or targetoid pattern, observed on routine histology is essential for the pathological diagnosis of ILC. Supporting techniques such as immunohistochemistry (IHC) or DNA sequencing are, according to WHO, not required for diagnosis. However, a recent worldwide survey of pathologists highlighted that the vast majority uses IHC systematically to confirm ILC diagnosis.³⁰ Loss or aberrant expression of the cell-to-cell adhesion molecule E-cadherin supports the diagnosis of ILC.³⁰ Lack of E-cadherin protein expression, observed in the majority of ILC (>85% of the cases),^{31,32} is predominantly caused by somatic mutations and loss of heterozygosity, although promoter methylation of *CDH1* has also been reported in rare cases.^{31,33} Mutational loss of E-cadherin causes cytosolic translocation of p120-catenin (p120), a multifaceted protein that plays crucial roles in the pathobiology of ILC.³⁴⁻³⁶ Besides classic ILC that represents more than half of the ILC cases (~55%), special ILC subtypes exist.^{29,37,38} These ILC subtypes differ in the underlying molecular alterations, possibly impacting treatment targets and efficacy.³¹ Of note, multivariate analyses of a large series of ILC suggested that patients with pure classical patterns had the best outcome and patients with the solid and mixed non-classic types of ILC had worse outcomes.³⁷ Pathological diagnosis of ILC (versus NST) remains a point of concern as a retrospective analysis of two trials showed that only 60%-66% of the tumours diagnosed as ILC by local pathology were confirmed to be ILC by central pathology.^{39,40} In this context, a recent study has demonstrated that the inter-pathologist concordance can be significantly improved by using E-cadherin IHC for diagnosing ILC.⁴¹

More than 90% of primary ILCs express ER and progesterone receptors (PRs),³² although low ER and PR expression has been reported in the metastases of 11% and 38% of the patients, respectively.⁴² Human epidermal growth factor receptor 2 (HER2) amplification/overexpression is generally only present in 3%-13% of cases.^{29,38} Furthermore, most ILC cases have a low or intermediate proliferation grade.^{2,33} Triple-negative ILC represents only 2%-9% of all ILCs.³⁸ A vast majority of triple-negative ILCs express the androgen receptor (AR), implying that this rare subtype has a different biology compared to triple-negative NST.^{38,43,44} Controversy exists about the so-called 'HER2-low' tumours, *HER2* not amplified tumours with a 1+ or 2+ IHC score which could potentially benefit from novel anti-HER2 therapies.⁴⁵ Some studies reported that these 'HER2-low' tumours are less frequent in *HER2*-non-amplified ILC (33%)

Table 1. Actionability of the genomic alterations in primary and metastatic ILC as per ESCAT^{53,206}

Readiness of use in clinical practice	ESCAT alterations in breast cancer	% Primary ILC (% primary NST)	% Metastatic ILC (% metastatic NST)
Tier I Targets ready for implementation in routine clinical decisions	<i>ERBB2/HER2</i> amplification	7.4 (20.6) ²⁵	6.8 (11.4) ⁵⁵
	Germline <i>BRCA1</i> mutations		0.3 (2.3) ^{25,55}
	Germline <i>BRCA2</i> mutations		2.2 (2.4) ²⁵
	<i>NTRK1-3</i> fusions	0 (0)	0.6 (0) ³³
	<i>PIK3CA</i> mutations	43-48 (33.5) ³¹	38-47.2 (33.1) ^{42,55}
	MSI	NA	NA
	High TMB (>10 mutations/Mb)	4.7 (NA) ⁵⁴	16 (5) ⁵⁸
Tier II Investigational targets likely to define patients who benefit from a targeted drug, but additional data needed	<i>AKT1</i> mutations	1.6-4 (3.1) ^{31,33}	7.5-10 (6.4) ^{42,55}
	<i>ERBB2/HER2</i> mutations	3.9-5 (1.4) ^{31,33}	14.3-15 (4.6) ^{42,55}
	<i>ESR1</i> mutations	0-0.8 (0.8) ^{31,33}	15.5-18 (15.3) ^{42,55}
	<i>PTEN</i> loss	13.4 (11.2) ³³	14.3-15 (8.4) ⁴²
Tier III Clinical benefit previously demonstrated in other tumour type or for similar molecular targets	Somatic <i>BRCA1</i> mutations	0 (2.9) ^{31,33}	1.2 (1.9) ⁵⁵
	Somatic <i>BRCA2</i> mutations	0.8-2 (2.5) ^{31,33}	6.2 (3.5) ⁵⁵
	<i>MDM2</i> amplifications	2-2.4 (4.7) ^{31,33}	2-6.2 (4.2) ^{42,55}
	<i>NF1</i> mutations	1-3.9 (2.9) ^{31,33}	7-7.5 (5.8) ^{42,55}
	<i>ERBB3/HER3</i> mutations	0.8-4 (2.3) ³¹	0-2.5 (1.9) ^{42,55}
Tier IV Preclinical evidence of actionability	<i>ARID1A</i> mutations	5.5-6.3 (3.7) ³¹	8.7-15 (6.1) ^{42,55}
	<i>ARID1B</i> mutations	0.2-0.8 (2.1) ^{31,33}	2.5 (2.8) ⁵⁵
	Germline <i>ATR</i> mutations		NA
	Germline <i>ATM</i> mutations		1.03 (1.1) ²⁵
	Germline <i>PALB2</i> mutations		0.37 (1.5) ²⁵
	<i>CDH1</i> mutations	63-65 (2) ^{31,33}	69-75.8 (2.1) ^{42,55}
	Germline <i>CDH1</i> mutations		0.54 (0.04) ²⁵
	<i>IGF1R</i> mutations	0-1.6 (0.8) ^{31,33}	0-13 (2.1) ^{42,55}
	<i>INPP4B</i> loss	0.8 (0.8) ³³	0.6 (0.3)
	<i>MAP3K1</i> mutations	5.3-5.5 (8.2) ^{31,33}	7.5-17 (7) ^{42,55}
	<i>MAP2K4</i> mutations	1.2-1.4 (4.9) ^{31,33}	2-4.3 (3.7) ^{42,55}
	<i>MT4</i> mutations		NA
	<i>MYC</i> amplifications	4.7-6.3 (26.8) ^{31,33}	3.7-15 (11.6) ^{42,55}
	<i>PIK3R1</i> mutations	0-1 (1.8) ³³	1.9 (2.7) ⁵⁵
	<i>RUNX1</i> mutations/deletions	4-10.2 (2.5) ³³	5 (2.7) ⁵⁵
	<i>CBFB</i> mutations/deletions	3.2 (3.3) ³³	4.3 (3.5) ⁵⁵
	<i>SF3B1</i> mutations	1.5-3.1 (2.5) ³³	3.1 (1.7) ⁵⁵
<i>TP53</i> mutations	7.3-7.9 (44) ^{31,33}	12-19.9 (42.9) ^{42,55}	
Tier X Lack of evidence of actionability	<i>FGFR1</i> amplification	9.4-25 (13.9) ^{31,33}	14.3-15 (14.6) ^{42,55}
	<i>CCND1</i> amplification	17.3-38 (16.2) ^{31,33}	19.9-24 (22.7) ^{42,55}
	<i>ESR1</i> amplification	0.8-10 (3.5) ^{33,207}	1.0 (3.2) ⁵⁵
	<i>FGFR4</i> mutations	0 (0.2) ³³	2.5 (1.0) ⁵⁵

All alterations in the table are somatic unless otherwise specified. Red and darkgreen, respectively, denote the alterations that were found to be statistically significantly more and less prevalent in ILC versus IDC tumours, respectively. When referring to Desmedt et al.³⁰ and Richard et al.,⁴³ alterations were coloured when significantly different in the multivariate analyses comparing ER-positive/HER2-negative ILC versus NST tumours. *HER2* amplification status on the metastases was retrieved from the copy number data from Razavi et al.⁵⁵

ESCAT, ESMO Scale for Clinical Actionability of molecular Targets; ILC, invasive lobular breast cancer; MSI, microsatellite instability; NA, not available; TMB, tumour mutational burden.

as compared to *HER2*-non-amplified NST (53%),⁴⁶ while others reported similar rates.⁴⁷ With regard to stromal tumour-infiltrating lymphocytes (sTILs), studies have consistently shown lower levels in ER-positive/*HER2*-negative primary ILC versus NST.^{42,48,49} These studies also suggest that higher levels of sTIL could be associated with a worse prognosis in ER-positive breast cancer (regardless of histology). Finally, the expression of programmed death-ligand 1 (PD-L1) seems to be lower in ILC versus NST in primary treatment-naïve samples.⁵⁰

MOLECULAR FEATURES OF ILC

ILC presents several differences in its somatic mutational landscape as compared to NST, both at the primary^{31,33,51} and metastatic^{42,52} levels. Some of the genes that are differentially altered between ILC and NST harbour (potential) clinical relevance. This is shown in Table 1, where the alterations are displayed according to the European Society for Medical Oncology (ESMO) Scale for Clinical

Actionability of molecular Targets (ESCAT).⁵³ The extracted mutational frequencies reported in Table 1 should be taken with caution since the cohorts differ in terms of clinical and pathological characteristics.⁵⁴ Also, some studies report only ILC confirmed by central pathology,^{31,33,42} while others do not.⁵⁵ As reported in Table 1, the proportion of metastases with a high tumour mutational burden (TMB, >10 mutations per megabase) is significantly higher in ILC as compared to NST,^{52,56-58} suggesting that for a subset of patients with ILC, immune checkpoint inhibitors (ICIs) might be a valid treatment option, an hypothesis being tested in the Assessing Efficacy of Carboplatin and Atezolizumab in Metastatic Lobular Breast Cancer (GELATO) trial.⁵⁹ A significantly higher number of *HER2* mutations have also been reported in ILC versus NST, especially in grade 3 ILC and in the metastatic setting,⁶⁰ of relevance for treatment with second-generation *HER2* tyrosine kinase inhibitors.⁶¹ While alterations in the *HER2* and phosphoinositide 3-kinase (PI3K) pathway are frequently observed in ILC, Teo

et al. demonstrated increased responsiveness of the growth factor receptor-dependent activation of the PI3K/Akt pathway in experimental ILC models, highlighting a potential for drugs targeting the PI3K/Akt axis in ILC irrespective of mutations in the pathway.⁶² Several studies also documented the distinct regulation of ER signalling in ILC as compared to NST,⁶³⁻⁶⁵ identifying, for instance, lower levels of ER at the messenger RNA and protein level in ER-positive ILC versus ER-positive NST and a distinct regulation of ER signalling by selective ER downregulators in ILC versus NST cell lines. Finally, Nagle et al. reported an enhanced insulin-like growth factor-1 receptor (IGF-1R) pathway activity in ILC, which could potentially be targetable with IGF-1R/insulin receptor therapy.⁶⁶ Altogether, the molecular features of ILC are being slowly uncovered during the past decade, mainly thanks to the increasing number of human ILC samples and models that are becoming available.⁶⁷

CLINICAL IMAGING

Screening, diagnosis and pre-operative assessment

Mammography has some well-known limitations in detecting ILC,⁶⁸ because the peculiar growth patterns of ILC make it harder to distinguish it from normal mammary tissue (sensitivity 34%-83%, Table 2).⁶⁹ The sensitivity is further reduced to ~10% in women with dense breasts (American College of Radiology—ACR 4).⁷⁰ The accuracy of two-dimensional mammography can be improved by the use of digital breast tomosynthesis (DBT)^{71,72} or contrast-enhanced digital mammography.⁷³

Over the past decades, ultrasound techniques have improved, with an increase of overall sensitivity for the detection of ILC from 68% to 88%-98%.⁷⁴⁻⁷⁶ Although ultrasound is almost always used for diagnosis, it is not commonly used in population breast cancer screening. It has been suggested by some as an additional imaging technique in women with dense breasts and in women with a higher risk of developing ILC.^{77,78}

Magnetic resonance imaging (MRI) is the modality with the highest sensitivity for ILC, being 93%-100%.⁷⁹ High

sensitivity comes at the cost of a low specificity and overestimation of the size of the lesions in 20% of the patients (mainly because of the presence of lobular carcinoma *in situ*).^{69,80} Synchronous lesions are solely detected on MRI in 32% and 7% of patients in the ipsilateral and contralateral breast, respectively, with an accuracy of 80%-90%,⁸¹ impacting the surgical treatment approach of the patient.^{82,83}

Breast surveillance

Once a patient is treated for primary ILC, it is questioned which examination is most suitable to detect locoregional relapses. Routinely, a yearly mammogram is carried out, complemented with ultrasound if needed.⁸⁴ Regular MRI of the breast could be useful in certain subgroups of patients (e.g. women with dense breast tissue), although there is no available evidence addressing the impact on survival.⁸⁵

Metastatic disease assessment

Computer tomography (CT), bone scan and [¹⁸F]2-fluoro-2-deoxy-D-glucose (¹⁸F-FDG)—positron emission tomography (PET)/CT are commonly used for the detection and monitoring of metastatic spread in breast cancer.⁸⁶ However, the probability that ¹⁸F-FDG—PET/CT detects metastases is 2.82 times lower in patients with locally advanced ILC compared to NST.⁸⁷ This is due to the lower metabolic activity of ILC and the tendency to form sclerotic bone lesions.

Other PET/CT modalities show promising results in ILC. In a small cohort, a higher uptake of ¹⁸F-fluciclovine (a synthetic amino acid) than ¹⁸F-FDG was seen for ILC.⁸⁸ It is hypothesized that the metabolism of ILC might depend more on amino acids than on glucose.⁸⁸ ¹⁸F-fluoroestradiol (¹⁸F-FES) may be superior in the detection of ILC metastases given the high rate of ER expression and its use is currently investigated in an ILC-specific phase II trial (NCT04252859).⁸⁹⁻⁹¹ The potential clinical benefit of ¹⁸F-FES—PET/CT may lie in the detection of metastases in patients with false-negative ¹⁸F-FDG—PET/CT, the distinction between oligometastatic and diffuse metastatic disease, the

Table 2. Overview of imaging techniques for ILC in the pre-operative setting

Technique	Sensitivity ILC (%)	Imaging features ILC	Benefit of imaging technique as compared to mammography	Disadvantages of imaging technique as compared to mammography
Mammography	34-83 ⁶⁹	- Asymmetric density - Mass with poorly defined margins		
DBT	83.3 ²⁰⁸	- Small spiculated lesions - Stellar distortion - Non-calcified masses	- Increased detection rate (doubling of ILCs detected) ^{87,88}	
CEDM	100 (small sample sizes) ^{209,210}	- Asymmetric density	- Accuracy of 85% ^{90,91}	
Ultrasound	88-98 ^{74,75}	- Less 'taller than wide' lesions	- Better estimation of tumour size ^{97,98} - Improved detection of multifocality ^{97,98}	- Higher rate of false-positive findings
MRI	93-100 ⁷⁹	- Irregular mass with heterogeneous type 2 enhancement	- Improved detection of multifocality and bilateral disease ^{100,102}	- Higher rate of false-positive findings - Overestimation of tumour size

CEDM, contrast-enhanced digital mammography; DBT, digital breast tomosynthesis; ILC, invasive lobular breast cancer; MRI, magnetic resonance imaging.

detection of lesions that can be reached for biopsy and the prediction of endocrine treatment response.

Whole-body diffusion-weighted MRI (WB-DWI/MRI) appears to have the potential to detect distant metastases in patients with ILC earlier than CT and ^{18}F -FDG—PET/CT.⁹² For peritoneal lesions, which are common in ILC, WB-DWI/MRI is superior to CT and ^{18}F -FDG—PET/CT.⁹²

TREATMENT IN THE EARLY SETTING

Neoadjuvant therapy

Patients with ILC seem to benefit less from neoadjuvant chemotherapy (NACT) in terms of downstaging and facilitating breast-conserving surgery (BCS) than patients with NST.⁹³ The low proliferation rate and high ER expression make ILC less sensitive to chemotherapy, as reflected by low pathological complete response (pCR) rates.^{94–96} Conflicting results exist as to whether these low pCR rates can be attributed to differences in ER expression. Lips et al. investigated the influence of histology when adjusting for clinicopathological features and did not find differences in the responsiveness to chemotherapy between ILC and NST.⁹⁷ However, other trials have shown that when comparing ILC and NST with a similar receptor status, pCR rate is still lower for patients with ILC.¹⁴ Although pCR is seen as a good prognostic factor for most breast cancers, it seems that this might not hold true for ILC, since lower pCR rates do not seem to lead to significantly worse outcomes in patients with ILC versus NST.⁹⁵ The majority of patients with ILC still require a mastectomy after their NACT.^{95,98,99}

Since the majority of ILCs have high ER/PR expression, it is hypothesized that neoadjuvant endocrine treatment (NET) could be considered for treating ILC.¹⁰⁰ However, data are scarce, since patients with ILC were often not analysed separately.¹⁰¹ A retrospective study of 61 patients with ILC reported that after a treatment of ~9 months, the tumours of 40/61 patients were eligible for resection.¹⁰² No significant difference in survival rate (after adjustment for covariates) was seen for NET versus NACT for patients with node-positive ILC.¹⁰³

Recently, trials have looked into the effect of NET in combination with CDK4/6 inhibitors.^{104–106} In these trials, ~15% of the included patients had ILC, but the efficacy in ILC specifically was not reported.^{105,106} The addition of ICIs to NACT shows promising results especially in triple-negative breast cancer but separate results for ILC are currently lacking.¹⁰⁷

Surgery

Given the larger tumour size at diagnosis, the higher rates of multifocality and the difficulties estimating the actual size of ILC pre-operatively, mastectomy is more often carried out in patients with ILC than NST.^{108,109} Recent trials report mastectomy rates ranging from 22% to 52% in patients with ILC (compared to 14%–46% in patients with NST).³² A 17%–65% chance of having positive resection margins in patients with ILC undergoing BCS has been reported.³² Similar to

NST, there is no benefit seen regarding long-term survival for mastectomy in patients with ILC in comparison to BCS with clear margins and in combination with radiotherapy.¹¹⁰

Several studies report a higher nodal stage at diagnosis and a higher number of positive lymph nodes at the time of surgery in ILC compared to NST, resulting in a higher rate of axillary lymph node dissection.^{9,10,111} This might be attributable to the larger tumour sizes and other confounding factors, as this was no longer seen in multivariate analysis.¹¹² Following sentinel lymph node biopsy, there is a 38% rate of nodal positivity in clinically node-negative patients, highlighting the challenges of clinical nodal assessment in ILC.¹¹³

Adjuvant radiotherapy

Local control rates for BCS (with clear margins) followed by whole-breast radiotherapy are similar for ILC and NST.¹¹⁴ Since ILC is often multifocal, ILC has been an exclusion factor in partial breast irradiation (PBI) trials and therefore the technique is not recommended in ILC.⁸⁴ Concerns regarding PBI in ILC are supported by a single-institution retrospective review of accelerated PBI, which showed an increase in ipsilateral breast cancer recurrence in patients with ILC.¹¹⁵

ILC represented 10%–15% of the cases enrolled into the large hypofractionated radiotherapy trials in breast cancer [The UK Standardisation of Breast Radiotherapy (START)¹¹⁶ and Fastforward (NCT04148586)¹¹⁷] but the local relapse rates were not reported separately per histological type. Post-mastectomy radiation in patients with ILC appears to be as effective as it is in NST resulting in improved local control and survival.¹¹⁸

Adjuvant endocrine treatment

Metzger et al. reported a significant benefit of 5 years of the aromatase inhibitor (AI) letrozole over 5 years of tamoxifen for postmenopausal women in the Breast International Group (BIG) 1-98 trial, an effect that was more pronounced in ILC as compared to NST.¹¹⁹ The TEAM trial (Tamoxifen and Exemestane Adjuvant Multinational, NCT00279448, NCT00036270) comparing 5 years of exemestane versus 2.5 years of tamoxifen followed by 2.5 years of exemestane¹²⁰ reported no statistically significant differences in recurrence-free survival in patients with ILC or NST. However, follow-up was limited to 5 years, while recurrences in ILC might occur later.⁹ In a recent meta-analysis presented at San Antonio Breast Cancer Symposium 2021 including 7415 patients from TEAM, BIG 1-98 and Arimidex, Tamoxifen, Alone or in Combination (ATAC) trials, the differential effect for AI versus tamoxifen in ILC versus NST was not confirmed.¹²¹ Although AI is superior to tamoxifen for ILC, this meta-analysis did not support a more pronounced effect for ILC compared to NST. The addition of ovarian function suppression (OFS) in women with premenopausal diagnosis of ILC has not yet been analysed, which might be partially explained by the low incidence rate of ILC in young women. It is known from the Suppression of Ovarian

Function Trial (SOFT) (NCT00066690) and Tamoxifen and Exemestane Trial (TEXT) (NCT00066703) that in premenopausal patients with clinically high-risk tumours OFS can be beneficial.¹²² Furthermore, extended endocrine treatment with preference for AI needs to be considered in all patients with clinically high-risk ILC, similarly to patients with high-risk NST.⁸⁴ The addition of CDK4/6 inhibitors to adjuvant endocrine treatment needs further exploration since conflicting results of additional benefit were seen in monarchE¹²³ versus Palbociclib Collaborative Adjuvant Study (PALLAS)¹²⁴ and Penelope-B,¹²⁵ and to our knowledge, no separate conclusions were made about the effect in patients with ILC.¹²⁶

Adjuvant chemotherapy

Trapani et al. recently conducted a meta-analysis of eight retrospective trials consisting of 38 387 patients with ILC.¹²⁷ They did not identify a beneficial role for adjuvant chemotherapy with regard to overall survival (OS), in line with other literature.^{37,128-131} Most of the studies included in this meta-analysis did, however, not correct for ER, PR and HER2 and had a relatively short follow-up. A more recent US registry study that evaluated 17 789 patients with stage I-III ILC observed a similar OS after 5 years between patients receiving endocrine therapy alone and those receiving the combination of chemotherapy and endocrine therapy, after adjusting for age, stage, lymph node involvement, histology and radiotherapy.¹³² When comparing ILC with NST, a recent Oxford meta-analysis (37 298 patients) did not find significant differences in the magnitude of benefit between ILC and NST when dose-dense chemotherapy regimens were used.¹³³ de Nonneville et al. described a survival advantage of adjuvant chemotherapy in high-risk, ER-positive, HER2-negative ILC (defined as having either macroscopic lymph node involvement, or a tumour size >20 mm and lymphovascular invasion), but not in low-risk ILC, findings that were confirmed by Tamirisa et al.^{134,135} Recently, it was stated that anthracycline-free regimens containing only cyclophosphamide and taxanes had non-inferior efficacy to anthracycline-containing regimens in HER2-negative breast cancer patients while tolerability was significantly improved.^{136,137} de Gregorio et al. confirmed this observation for the global breast cancer population; however, patients with ILC, especially in case of pN2 and pN3, did seem to benefit more from anthracycline-containing than anthracycline-free regimens.¹³⁸ Overall, this suggests that although the majority of ILCs are not chemo-sensitive, there is a subset of patients with high-risk ILC who could benefit from chemotherapy.

Adjuvant anti-HER2 therapy

Results from the HERceptin Adjuvant (HERA) trial (NCT00045032) suggest that ILC patients benefit equally from adjuvant trastuzumab in comparison to NST patients.¹³⁹ Further research is necessary to analyse the efficacy of HER2-targeted treatments in the early setting for patients with *HER2*-mutated ILC.

Gene expression-based prognostic tests

Commercially available prognostic tests based on the assessment of the expression of predefined genes, such as Oncotype DX Breast Recurrence Score (RS)[®], MammaPrint[®], Prosigna-PAM50 risk of recurrence (ROR) score and EPclin, have a great potential in determining which patients with ER-positive/HER2-negative breast cancer benefit from adjuvant chemotherapy. However, most of these tests have been developed without considering the specific aetiology and histology of ILC. [Supplementary Table S1](https://doi.org/10.1016/j.annonc.2022.05.006), available at <https://doi.org/10.1016/j.annonc.2022.05.006>, summarizes the main features, characteristics and findings of the studies that evaluated these tests for patients with ILC. Of note, while the RS[®]^{39,128,131,140-148} and MammaPrint[®]^{40,149-151} have been evaluated in multiple studies (12 and 4, respectively), only a single study was reported for the other tests. A formal comparison of all tests cannot be done because they were all investigated in different patient cohorts, with important differences with regard to ILC definition (based on local versus central pathology), treatment and the duration of follow-up. Several messages can however be drawn from these studies. Firstly, the proportion of patients classified as 'high risk' varies significantly according to the test used, ranging between 1% and 2% for the RS[®] using the RS >30 cut-off (or ~8% when considering the RS >25 cut-off),^{39,128,131,140-148} 11% and 28% for MammaPrint[®],^{40,149-151} 31% for the Prosigna-PAM50 ROR score,¹⁵² 37% for EPclin¹⁵³ and 46% for The Breast Cancer Index (BCI) Risk of Recurrence.¹⁵⁴ A higher proportion of 'high-risk' patients were consistently identified in non-classic ILC compared to classic ILC, both when considering the RS[®]³⁹ and MammaPrint[®].⁴⁰ Secondly, all the tests were shown to carry independent prognostic value in multivariate analyses. Finally, it is currently still unclear whether the classifiers are only of prognostic value or whether they can also be used to tailor adjuvant treatment for patients with ILC.

Next to the commercial tests reported above, the Genomic Grade Index (GGI) identified 17% of the investigated ILC tumours as 'high risk' and recognized an independent prognostic value of the GGI.¹⁵⁵ LobSig is the only gene expression signature that was designed specifically for patients with ILC but additional validation is needed.¹⁵⁶

TREATMENT IN THE METASTATIC SETTING

Endocrine-based treatment

The pillar in treating metastatic ER-positive ILC consists of endocrine treatment. Recently, the addition of CDK4/6 inhibitors to endocrine treatment has become the standard of care in first-line treatment of ER-positive metastatic breast cancer as four out of seven phase III trials demonstrated a clear survival benefit over endocrine treatment alone.¹⁵⁷⁻¹⁶⁴ [Supplementary Table S2](https://doi.org/10.1016/j.annonc.2022.05.006), available at <https://doi.org/10.1016/j.annonc.2022.05.006>, gives an overview of these trials within the context of ILC. Of these trials, only PALOMA-2 reported data for ILC specifically with a clear improvement of progression-free survival (PFS) upon the

addition of palbociclib to letrozole.¹⁵⁹ A large, pooled analysis of all seven trials, carried out by the United States Food and Drug Administration, demonstrated that CDK4/6 inhibitors significantly improved PFS in patients with ILC.¹⁶⁵ More recently, a pooled analysis of OS in three trials exploring CDK4/6 inhibition combined with fulvestrant demonstrated a numerical survival benefit in patients with ILC.¹⁶⁶

Chemotherapy

Only a few trials comparing chemotherapy regimens in metastatic ILC versus NST exist. Pérez-García et al. carried out retrospective analyses on three trials where eribulin was administered after prior use of anthracyclines and

taxanes.¹⁶⁷ No difference was found between the efficacy in patients with ILC compared to NST. Furthermore, limited evidence exists that capecitabine results in similar disease-free survival in patients with metastatic ILC compared to NST.¹⁶⁸ In clinical practice, chemotherapy can be considered in patients with ILC in case of endocrine resistance or a visceral crisis.

Targeted therapy and immune checkpoint inhibitors

Although no specific studies have been carried out about the benefit of HER2-targeted therapies and the HER2-targeting antibody-drug conjugates (ADCs) for ILC, it is currently assumed that the benefit is similar for ILC versus NST. Approximately 15% of metastatic ILCs have underlying

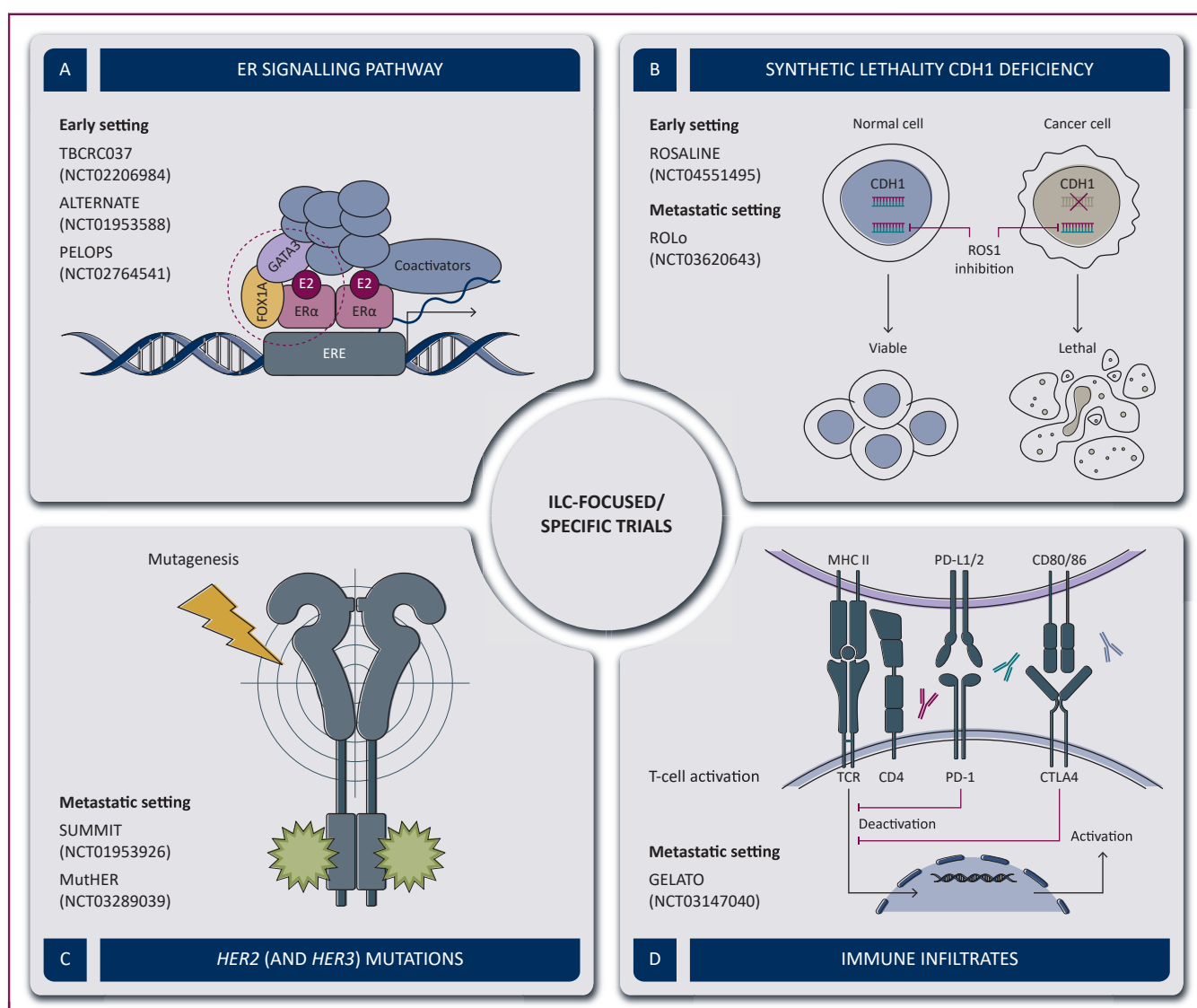


Figure 1. Overview of ILC-focused/specific ongoing trials investigating systemic treatment options.

(A) A schematic overview of the ER signalling pathway with the targets of the ongoing trials is shown. (B) This figure visualizes that when ROS inhibitors are administered in cells with CDH1 deficiency the cells are no longer viable whereas normal cells are not affected. (C) The effect of second-generation HER2 blockade (visualized in green) which forms irreversible covalent bonds to inhibit signal transduction is shown. (D) The mechanism behind PD-1 and PD-L1 inhibition, inhibiting the T-cell deactivation by the tumour cells, is shown (created with BioRender.com).

CTLA4, cytotoxic T-lymphocyte-associated antigen 4; ER, estrogen receptor; FOXA1, forkhead box protein A1; HER2, human epidermal growth factor receptor 2; ILC, invasive lobular breast cancer; MHC II, major histocompatibility complex II; PD-1, programmed cell death protein 1; PD-L1, programmed death-ligand 1; ROS, reactive oxygen species; TCR, T-cell receptor.

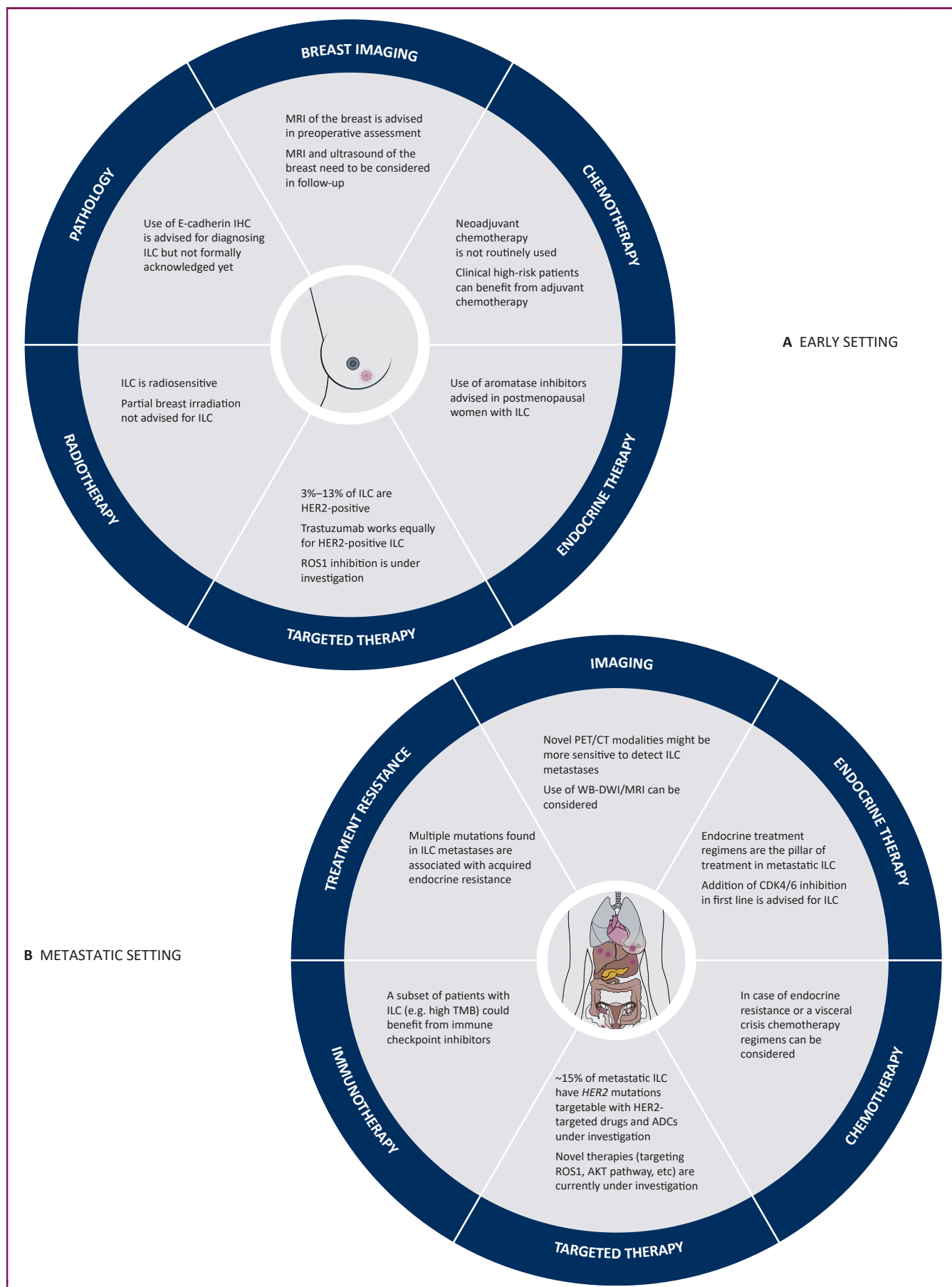


Figure 2. Overview of the key concepts of ILC.

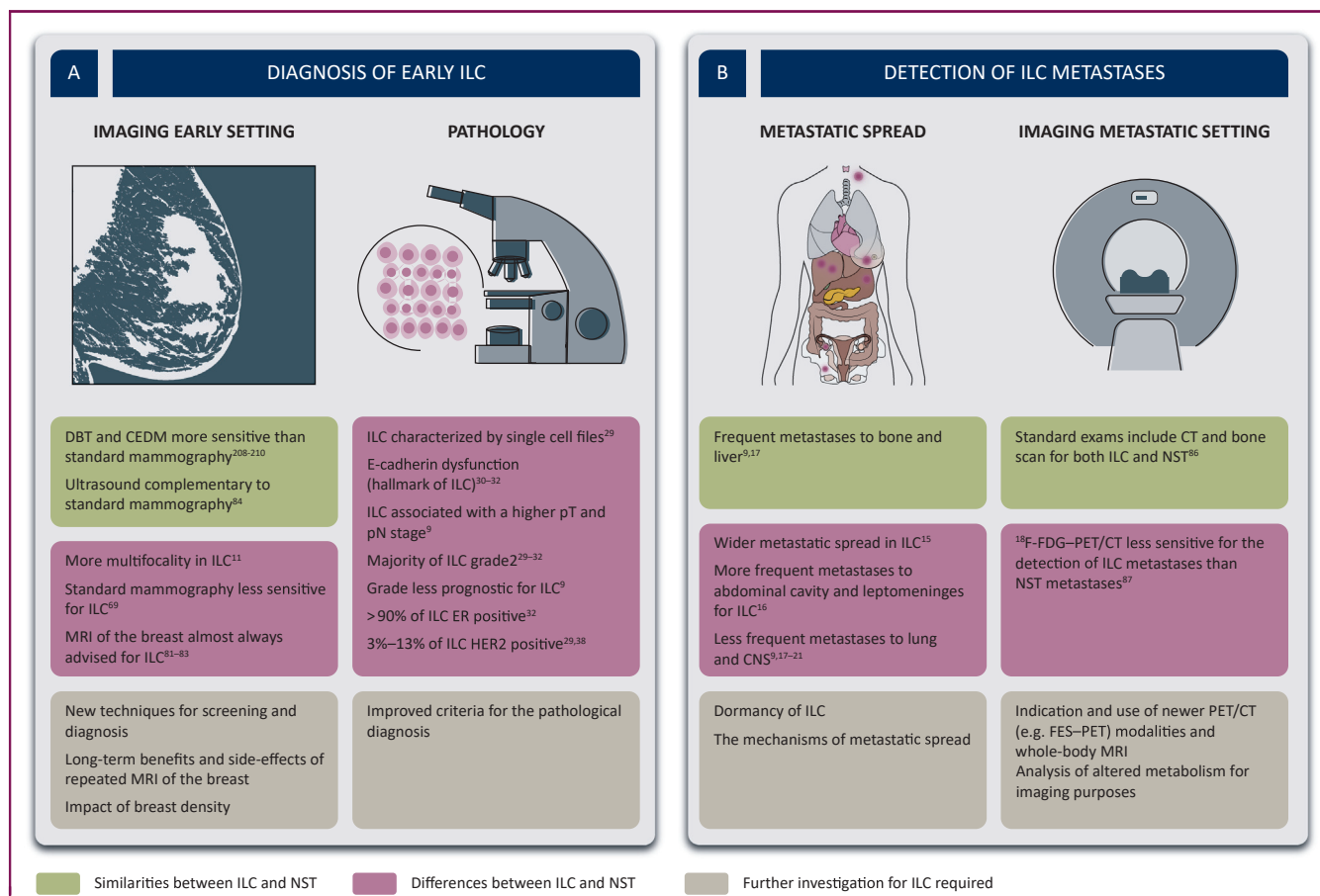


Figure 3. Diagnostic similarities and differences between patients with ILC and those with NST.

This figure shows the similarities between ILC and NST, the differences between ILC and NST and the aspects that require further investigation. (A) Diagnosis in the early setting. (B) Detection of metastases.

¹⁸F-FDG–PET/CT, [¹⁸F]2-fluoro-2-deoxy-D-glucose positron emission tomography/computed tomography; CECDM, contrast-enhanced digital mammography; CNS, central nervous system; CT, computed tomography; DBT, digital breast tomosynthesis; ER, estrogen receptor; FES, ¹⁸F-fluoroestradiol; HER2, human epidermal growth factor receptor 2; ILC, invasive lobular carcinoma; MRI, magnetic resonance imaging; NST, non-special type; pN, pathological nodal stage; pT, pathological tumour size (created with BioRender.com).

HER2 mutations.⁴² Preliminary results of prospective trials (SUMMIT—NCT01953926, MutHER trial, part 2—NCT03289039) targeting these mutations by second-generation HER2 tyrosine kinase inhibitors such as neratinib in combination with endocrine treatment show higher response in ILC than in NST (Figure 1, Supplementary Table S3, available at <https://doi.org/10.1016/j.annonc.2022.05.006>).^{61,169}

While in *HER2*-mutated non-small-cell lung cancer impressive response rates to the *HER2*-targeting ADC trastuzumab-deruxtecan were observed,¹⁷⁰ no data are available yet on *HER2*-targeting ADCs in *HER2*-non-amplified ILC. An increased frequency of *HER3* (*ERBB3*) mutations was reported in ILC as compared to NST; however, it is unknown

whether these *HER3*-mutated tumours could benefit from second-generation *HER2* tyrosine kinase inhibitors or ADCs targeting *HER3*.^{31,171}

To our knowledge, clinical data on the effectiveness of ICLs in ILC are limited. In the small KEYNOTE-28 study that evaluated pembrolizumab in heavily pre-treated ER-positive metastatic breast cancer, two out of the three responders were of ILC origin.¹⁷² In the GELATO trial (NCT03147040), patients with metastatic ILC are treated with carboplatin as immune induction for 12 weeks, followed by atezolizumab (anti-PD-L1), thereby inducing potential synergy between these agents and enhancement of the anticancer immune response. So far, 23 patients have received at least one cycle of atezolizumab (18 ER positive, 5 triple negative).

(A) Key concepts of ILC in the early setting; surgery was not included in this figure since it depends more on tumour and patient characteristics than on histological subtype. (B) Key concepts of ILC in the metastatic setting. Use of the combination of other drugs with endocrine treatment was not included in this figure but can be considered after first-line progression (e.g. alpelisib, everolimus). Additionally, PARP inhibition can be considered for patients with germline BRCA mutation. Additional novel agents can be considered in triple-negative metastatic ILC; however, since this is a minor subgroup of ILC, these were not included in the figure.

ADC, antibody-drug conjugate; HER2, human epidermal growth factor receptor 2; IHC, immunohistochemistry; ILC, invasive lobular carcinoma; MRI, magnetic resonance imaging; PARP, poly(ADP-ribose) polymerase; PET/CT, positron emission tomography/computed tomography; TMB, tumour mutational burden; TNBC, triple-negative breast cancer; WB-DWI/MRI, whole-body diffusion-weighted MRI (created with BioRender.com).

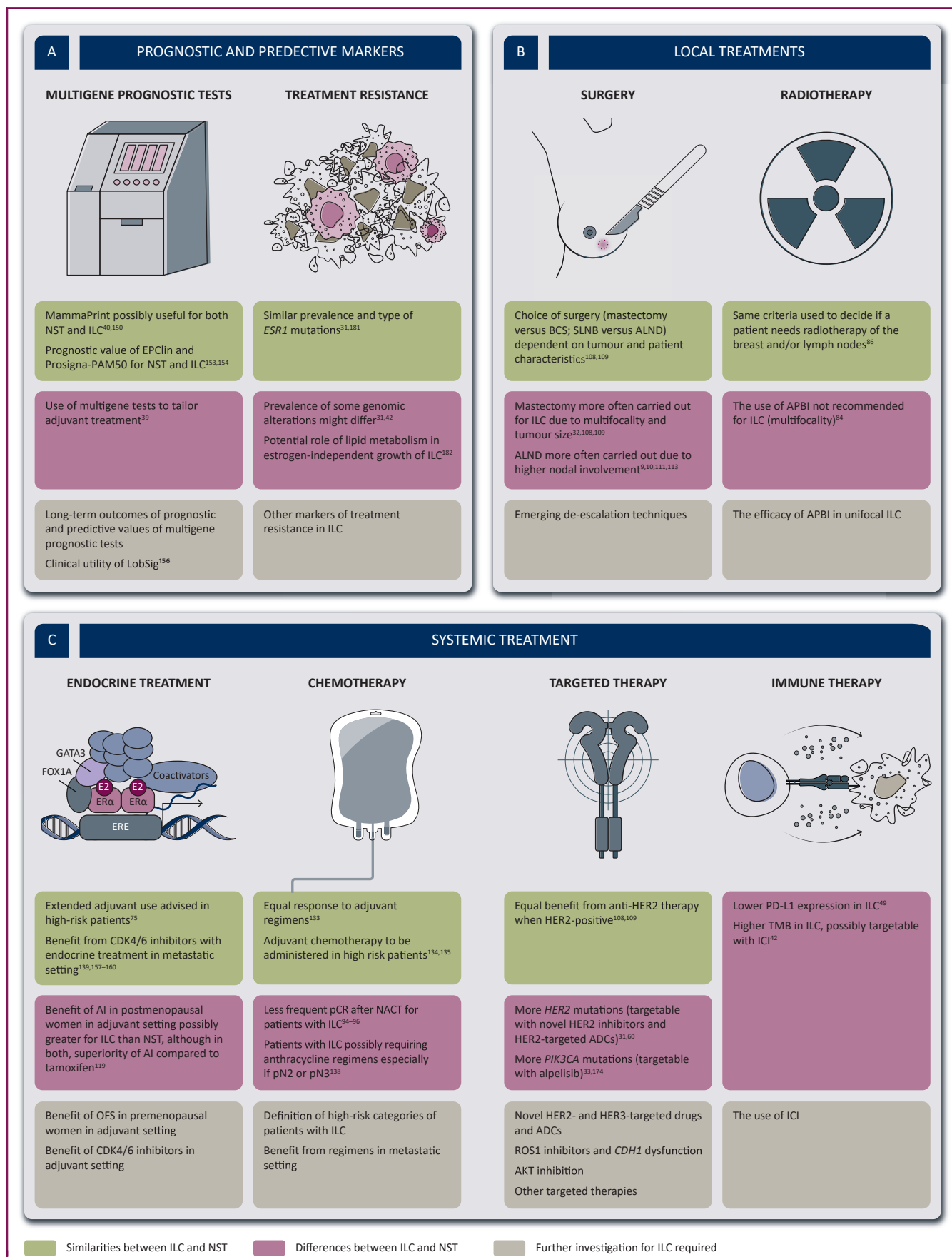


Figure 4. Similarities and differences concerning treatment and treatment markers between patients with ILC and those with NST.

Preliminary results are promising but response is mainly limited to triple-negative ILC.¹⁷³

Other treatment options include the targeting of the PI3K–AKT signalling pathway, since this is often activated in ILC.^{33,62} *PIK3CA* mutations form, after *CDH1* mutations, the second most common alterations in metastatic ILC, suggesting the possible utility of the PI3K inhibitor alpelisib.^{33,174} In the SOLAR-1 trial, it was shown that alpelisib combined with fulvestrant prolonged PFS in *PIK3CA*-mutated ER-positive breast cancer, but both the proportion of ILC patients and the efficacy in that group were not reported.¹⁷⁵ Similarly, the efficacy in ILC specifically has also not been reported in the Breast Cancer Trials of Oral Everolimus-2 (BOLERO-2), in which inhibition of mammalian target of rapamycin (mTOR) by everolimus, in combination with exemestane, has been shown to improve PFS but not OS in ER-positive breast cancer.^{176,177} Patients with ILC harbouring a germline *BRCA1/2* mutation might benefit from poly(ADP-ribose) polymerase inhibitors, although no specific subgroup analyses for ILC have been carried out to our knowledge.¹⁷⁸ An additional treatment option for metastatic triple-negative ILC is sacituzumab govitecan which targets trophoblast cell surface antigen 2, but it is not reported as to how many patients with ILC were included in the ASCENT trial.¹⁷⁹

MARKERS OF TREATMENT RESISTANCE IN THE METASTATIC SETTING

Exposure to endocrine treatment can lead to acquired endocrine resistance, which complicates treatment of metastatic ILC. The best-known mutation linked to endocrine resistance is the *ESR1* mutation.¹⁸⁰ Desmedt et al. did not see a difference in prevalence and type of *ESR1* mutations between ILC and NST.¹⁸¹ *NF1* mutations, which seem to occur more frequently in metastatic ILC, are mutually exclusive with *ESR1* mutations, and might be associated with endocrine resistance.⁵² *FOXA1* mutations, which are also associated with endocrine resistance, are more prevalent in ILC than in NST.³¹ Genomic analyses by Richard et al. comparing matched primary and metastatic ILC lesions have identified genomic alterations associated with endocrine resistance only present in metastatic but not the primary lesions, possibly suggestive of acquired resistance.⁴² Additionally, experimental data suggested that lipid metabolism may play a role in the estrogen-independent growth of ILC,¹⁸² and that fibroblast growth factor receptor 4 (*FGFR4*) overexpression/mutations¹⁸³ and *WNT4* signalling¹⁸⁴ could act as mediator of endocrine resistance. With regard to CDK4/6 inhibitors, mechanisms of resistance are now also increasingly being described.^{185,186} The acquired loss of *RB* and *P TEN* and alterations in *CCND1* seem to be associated with resistance to ribociclib.^{185,186} *P TEN* loss, numerically

slightly more prevalent in ILC as in NST (Table 1), is also linked to resistance to PI3K inhibitors like alpelisib.¹⁸⁵

Metastases are often difficult to biopsy; therefore, treatment resistance in patients with ILC is difficult to study. Analysis of circulating tumour DNA (ctDNA) may present a potential solution to overcome these issues. ctDNA has recently been investigated successfully in plasma or cerebrospinal fluid from patients with ILC.¹⁸⁷ To further investigate disease progression and treatment resistance, an autopsy programme called UPTIDER (NCT04531696) with a specific substudy focusing on ILC has been set up at the University Hospitals of Leuven.

ONGOING TRIALS AND FUTURE PERSPECTIVES

With the growing knowledge that ILC is an entity in many ways distinct from NST, new trials focusing more specifically on the treatment of patients with ILC slowly arise (Figure 1, Supplementary Table S3, available at <https://doi.org/10.1016/j.annonc.2022.05.006>).¹⁸⁸ This is much needed since recently it became evident that patients with ILC are often excluded from clinical trials in the metastatic setting.¹⁸⁹

Since most ILCs are ER positive, the ER signalling pathway represents a target of great interest, mainly in the early setting. Within the window of opportunity trial TBCRC037 (NCT02206984), the anti-proliferative effect of different endocrine treatments (tamoxifen versus anastrozole versus fulvestrant) administered in the window between diagnosis and primary surgery is evaluated. In the ALTERNATE trial (NCT01953588), anastrozole is compared to fulvestrant alone and to the combination of anastrozole with fulvestrant for both ILC and NST patients in the neoadjuvant setting. Preliminary results did not show any significant difference in intrinsic sensitivity to the different regimens.¹⁹⁰ The Palbociclib and Endocrine Therapy for Lobular Breast Cancer Preoperative Study (PELOPS) (NCT02764541) including both ILC and NST patients will look into the differences in response rates to tamoxifen plus CDK4/6 inhibition versus letrozole plus CDK4/6 inhibition.

Central to future clinical management may be interventions that target molecules or pathways downstream of E-cadherin.^{191,192} Because E-cadherin loss in ILC predisposes cancer cells towards growth factor receptor sensitivity,^{62,66,193} the small-molecule MET/ALK/ROS1 inhibitors such as crizotinib and entrectinib are currently being studied as synthetic lethal drugs in both the early and metastatic settings. Entrectinib in combination with letrozole is being investigated in patients with ILC in the neoadjuvant multicentre trial ROSALINE (NCT04551495), the primary endpoint being residual cancer burden at surgery. In the metastatic setting, crizotinib is investigated in the ROLo trial (NCT03620643), either in combination with fulvestrant in patients with ILC or as a single agent in patients

This figure shows the similarities between ILC and NST, the differences between ILC and NST and the aspects that require further investigation. (A) Prognostic and predictive markers guiding treatment. (B) Local treatment. (C) Systemic treatment (created with BioRender.com).

ADCs, antibody-drug conjugates; AI, aromatase inhibitor; ALND, axillary lymph node dissection; APBI, accelerated partial breast irradiation; BCS, breast-conserving surgery; HER2, human epidermal growth factor receptor 2; ICI, immune checkpoint inhibitors; ILC, invasive lobular carcinoma; NACT, neoadjuvant chemotherapy; NST, non-special type; OFS, ovarian function suppression; pCR, pathological complete remission; PD-L1, programmed death-ligand 1; SLNB, sentinel lymph node biopsy; TMB, tumour mutational burden.

with *CDH1*-mutated triple-negative breast cancer or diffuse gastric cancer.

Other possible treatment opportunities lie in the *HER2* and *HER3* mutations that are more often present in ILC than in NST, and in the investigation of ICI in patients with tumours presenting a high TMB or immune-rich characteristics, as described above.

Emerging explorative trials on ILC are setting the basis for future treatment strategies by uncovering new potential targets.¹⁸⁸ A number of preclinical studies have utilized models of *CDH1*-defective breast cancer to identify new vulnerabilities/targets that could be therapeutically applied to treat ILC. Genetic perturbation (RNA interference) screens have identified G protein-coupled receptors, ion channels, proteasomal subunits, BH3-only proteins, ubiquitinating enzymes and proteins such as Rock1 that control actomyosin contraction as synthetic lethal targets in *CDH1*-defective cells, when compared to *CDH1*-wild-type cells.^{36,193-195} Interestingly, insertional mutagenesis of genes such as *MYPT1*, *MYPT2*, *ASPP2* and *MYH9* that control actomyosin relaxation enhances ILC tumour formation in mice with a conditional *CDH1* mutation (*Wcre;Cdh1^{F/F};mTmG* mice).¹⁹⁶ Taken together with the *CDH1* synthetic lethality data, this suggests that modulation of actomyosin may underlie the development and progression of ILC and as such be a potentially rich source of therapeutic targets in this disease. It is also hypothesized that when patients with ILC develop endocrine resistance, new possible treatment strategies may involve the inhibition of bromodomain and extraterminal proteins and *FGFR1*.^{65,197,198} Additionally, mTOR, PI3K/AKT inhibition and IGF-1 inhibition have all been suggested as potential targets in ILC.^{66,199-202} Finally, since AR is often enriched in ILC, this pathway may also be of interest, especially in triple-negative ILC.^{44,203,204}

CONCLUSIONS AND PERSPECTIVES

ILC research and treatment faces many difficulties. ILC usually represents a small subgroup within clinical trials that is rarely separately analysed. Moreover, there is a concerning suboptimal degree of concordance between local and central pathology to define ILC, which is currently being further investigated by the pathology working group of the European Lobular Breast Cancer Consortium (ELBCC; www.elbcc.org).

The ILC subtype warrants differences in diagnostic and treatment strategies summarized in Figures 2-4. The pre-operative assessment of ILC comes with many challenges and requires the use of different complementary imaging techniques, like MRI and DBT of the breast in addition to the standard mammogram and ultrasound. Screening for metastases can be challenging, although new PET/CT techniques are emerging and expertise in WB-DWI/MRI is growing.

Treatment decisions in the early setting need to be made based on additional clinicopathological features. A significant benefit for the use of aromatase inhibition in postmenopausal women was already proven for ILC in the past,

although recent trials suggest similar findings for NST. The role of multigene prognostic tests in guiding adjuvant treatment in patients with ILC needs to be further evaluated. Although some multigene tests have prognostic potential in ILC, a predictive value to further guide treatment decisions is currently unknown. Chemotherapy seems to have less effect in ILC, although subgroups of patients with ILC, which need to be further defined, might still benefit from the addition of chemotherapy. In the future, a combination of molecular and biochemical/histological profiling may be the best way to classify ILC instead of their histological appearance only.

For most patients with metastatic ILC, endocrine treatment remains the most important pillar, in first line now with the addition of CDK4/6 inhibition. Key mechanisms underlying the disease aetiology and treatment resistance are currently being discovered but more research is needed. Liquid biopsies seem to hold a prognostic value towards ILC and their use in guiding treatment needs to be further evaluated. Furthermore, more insights arise regarding dormancy of ILC cells, which might reveal new treatment options in the future. Clinical trials focusing on ILC are emerging and collaborative efforts between clinicians, researchers and patient advocates are increasing,²⁰⁵ which hopefully enables more prospective clinical and translational research to provide the optimal treatment strategies for patients with ILC.

ACKNOWLEDGMENTS

KVB and MDS are funded by the KU Leuven Fund Nadine de Beaufort. TG is funded by FWO through a research fellowship. All authors are part of the European Lobular Breast Cancer Consortium (ELBCC) and the Lobsterpot COST Action (CA19138). The authors thank Anirudh Pabba for the technical assistance with the figures.

FUNDING

None declared.

DISCLOSURE

The authors have declared no conflicts of interest.

REFERENCES

- Sledge GW, Chagpar A, Perou C. Collective wisdom: lobular carcinoma of the breast. *Am Soc Clin Oncol Educ B*. 2016;35:18-21.
- Reed MEM, Kutasovic JR, Lakhani SR, Simpson PT. Invasive lobular carcinoma of the breast: morphology, biomarkers and 'omics. *Breast Cancer Res*. 2015;17:12.
- Li CI, Anderson BO, Porter P, Holt SK, Daling JR, Moe RE. Changing incidence rate of invasive lobular breast carcinoma among older women. *Cancer*. 2000;88:2561-2569.
- Kotsopoulos J, Chen WY, Gates MA, Tworoger SS, Hankinson SE, Rosner BA. Risk factors for ductal and lobular breast cancer: results from the nurses' health study. *Breast Cancer Res*. 2010;12:R106.
- Newcomer LM, Newcomb PA, Potter JD, et al. Postmenopausal hormone therapy and risk of breast cancer by histologic type (United States). *Cancer Causes Control*. 2003;14:225-233.

6. Li CI, Weiss NS, Stanford JL, Daling JR. Hormone replacement therapy in relation to risk of lobular and ductal breast carcinoma in middle-aged women. *Cancer*. 2000;88:2570-2577.
7. Biglia N, Mariani L, Sgro L, Mininanni P, Moggio G, Sismondi P. Increased incidence of lobular breast cancer in women treated with hormone replacement therapy: implications for diagnosis, surgical and medical treatment. *Endocr Relat Cancer*. 2007;14:549-567.
8. Li CI, Uribe DJ, Daling JR. Clinical characteristics of different histologic types of breast cancer. *Br J Cancer*. 2005;93:1046-1052.
9. Pestalozzi BC, Zahrieh D, Mallon E, et al. Distinct clinical and prognostic features of infiltrating lobular carcinoma of the breast: combined results of 15 International Breast Cancer Study Group clinical trials. *J Clin Oncol*. 2008;26:3006-3014.
10. Corona SP, Bortul M, Scomersi S, et al. Management of the axilla in breast cancer: outcome analysis in a series of ductal versus lobular invasive cancers. *Breast Cancer Res Treat*. 2020;180:735-745.
11. Biglia N, Maggiorotto F, Liberale V, et al. Clinical-pathologic features, long term-outcome and surgical treatment in a large series of patients with invasive lobular carcinoma (ILC) and invasive ductal carcinoma (IDC). *Eur J Surg Oncol*. 2013;39:455-460.
12. Mejdahl MK, Wohlfahrt J, Holm M, et al. Synchronous bilateral breast cancer: a nationwide study on histopathology and etiology. *Breast Cancer Res Treat*. 2020;182:229-238.
13. Adachi Y, Ishiguro J, Kotani H, et al. Comparison of clinical outcomes between luminal invasive ductal carcinoma and luminal invasive lobular carcinoma. *BMC Cancer*. 2016;16:248.
14. Timbres J, Moss C, Mera A, et al. Survival outcomes in invasive lobular carcinoma compared to oestrogen receptor-positive invasive ductal carcinoma. *Cancers*. 2021;13:3036.
15. Ferlicot S, Vincent-Salomon A, Médioni J, et al. Wide metastatic spreading in infiltrating lobular carcinoma of the breast. *Eur J Cancer*. 2004;40:336-341.
16. Vincent-Salomon A, Caly M, De Rycke Y, et al. Lobular phenotype related to occult-metastatic spread in axillary sentinel node and/or bone marrow in breast carcinoma. *Eur J Cancer*. 2009;45:1979-1986.
17. Mathew A, Rajagopal PS, Villgran V, et al. Distinct pattern of metastases in patients with invasive lobular carcinoma of the breast. *Geburtshilfe Frauenheilkd*. 2017;77:660-666.
18. Mollica L, Leli C, Puglisi S, Sardi S, Sottotetti F. Leptomeningeal carcinomatosis and breast cancer: a systematic review of current evidence on diagnosis, treatment and prognosis. *Drugs Context*. 2021;10:1-23.
19. Sastre-Garau X, Jouve M, Asselain B, et al. Infiltrating lobular carcinoma of the breast clinicopathologic analysis of 975 cases with reference to data on conservative therapy and metastatic patterns. *Cancer*. 1996;77:113-120.
20. He H, Gonzalez A, Robinson E, Yang WT. Distant metastatic disease manifestations in infiltrating lobular carcinoma of the breast. *AJR Am J Roentgenol*. 2014;202:1140-1148.
21. Tham YL, Sexton K, Kramer R, Hilsenbeck S, Elledge R. Primary breast cancer phenotypes associated with propensity for central nervous system metastases. *Cancer*. 2006;107:696-704.
22. Nasca PC, Liu S, Baptiste MS, Kwon CS, Jacobson H, Metzger BB. Alcohol consumption and breast cancer: estrogen receptor status and histology. *Am J Epidemiol*. 1994;140:980-988.
23. Feigelson HS, Patel AV, Teras LR, Gansler T, Thun MJ, Calle EE. Adult weight gain and histopathologic characteristics of breast cancer among postmenopausal women. *Cancer*. 2006;107:12-21.
24. Petridis C, Arora I, Shah V, et al. Frequency of pathogenic germline variants in CDH1, BRCA2, CHEK2, PALB2, BRCA1, and TP53 in sporadic lobular breast cancer. *Cancer Epidemiol Biomarkers Prev*. 2019;28:1162-1168.
25. Yadav S, Hu C, Nathanson KL, et al. Germline pathogenic variants in cancer predisposition genes among women with invasive lobular carcinoma of the breast. *J Clin Oncol*. 2021;39:3918-3926.
26. Mavaddat N, Barrowdale D, Andrulis IL, et al. Pathology of breast and ovarian cancers among BRCA1 and BRCA2 mutation carriers: results from the consortium of investigators of modifiers of BRCA1/2 (CIMBA). *Cancer Epidemiol Biomarkers Prev*. 2012;21:134-147.
27. Petridis C, Shinomiya I, Kohut K, et al. Germline CDH1 mutations in bilateral lobular carcinoma in situ. *Br J Cancer*. 2014;110:1053-1057.
28. Sawyer E, Roylance R, Petridis C, et al. Genetic predisposition to in situ and invasive lobular carcinoma of the breast. *PLoS Genet*. 2014;10:e1004285.
29. Tan PH, Ellis I, Allison K, et al. WHO Classification of Tumours Editorial Board. The 2019 World Health Organization classification of tumours of the breast. *Histopathology*. 2020;77:181-185.
30. De Schepper M. SABCS 2021 ePosters - results of a worldwide survey on the currently used histopathological diagnostic criteria for invasive lobular breast cancer (ILC). Available at <https://cattendee.abstractsonline.com/meeting/10462/Presentation/687>. Accessed June 5, 2022.
31. Desmedt C, Zoppi G, Gundem G, et al. Genomic characterization of primary invasive lobular breast cancer. *J Clin Oncol*. 2016;34:1872-1881.
32. Christgen M, Steinemann D, Kühnle E, et al. Lobular breast cancer: clinical, molecular and morphological characteristics. *Pathol Res Pract*. 2016;212:583-597.
33. Ciriello G, Gatz ML, Beck AH, et al. Comprehensive molecular portraits of invasive lobular breast cancer. *Cell*. 2015;163:506-519.
34. Tenhagen M, Klarenbeek S, Braumuller TM, et al. p120-Catenin is critical for the development of invasive lobular carcinoma in mice. *J Mammary Gland Biol Neoplasia*. 2016;21:81-88.
35. van De Ven RAH, Tenhagen M, Meuleman W, van Riel JGG, Schackmann RCJ, Derksen PWB. Nuclear p120-catenin regulates the anoikis resistance of mouse lobular breast cancer cells through Kaiso-dependent Wnt11 expression. *Dis Model Mech*. 2015;8:373-384.
36. Schackmann RCJ, van Amersfoort M, Haarhuis JHI, et al. Cytosolic p120-catenin regulates growth of metastatic lobular carcinoma through Rock1-mediated anoikis resistance. *J Clin Invest*. 2011;121:3176-3188.
37. Iorfida M, Maiorano E, Orvieto E, et al. Invasive lobular breast cancer: subtypes and outcome. *Breast Cancer Res Treat*. 2012;133:713-723.
38. Christgen M, Cserni G, Floris G, et al. Lobular breast cancer: histomorphology and different concepts of a special spectrum of tumors. *Cancers*. 2021;13:3695.
39. Christgen M, Gluz O, Harbeck N, et al. Differential impact of prognostic parameters in hormone receptor-positive lobular breast cancer. *Cancer*. 2020;126:4847-4858.
40. Metzger O, Cardoso F, Poncet C, et al. Clinical utility of MammaPrint testing in invasive lobular carcinoma: results from the MINDACT phase III trial. *Eur J Cancer*. 2020;138:S5-S6.
41. Christgen M, Kandt LD, Antonopoulos W, et al. Inter-observer agreement for the histological diagnosis of invasive lobular breast carcinoma. *J Pathol Clin Res*. 2022;8:191-205.
42. Richard F, Majaj S, Venet D, et al. Characterization of stromal tumor-infiltrating lymphocytes and genomic alterations in metastatic lobular breast cancer. *Clin Cancer Res*. 2020;26:6254-6265.
43. Conforti F, Pala L, Pagan E, et al. Biological and clinical features of triple negative invasive lobular carcinomas of the breast. Clinical outcome and actionable molecular alterations. *Breast*. 2021;59:94-101.
44. Bergeron A, MacGrogan G, Bertaut A, et al. Triple-negative breast lobular carcinoma: a luminal androgen receptor carcinoma with specific ESRRA mutations. *Mod Pathol*. 2021;34:1282-1296.
45. Modi S, Park H, Murthy RK, et al. Antitumor activity and safety of trastuzumab deruxtecan in patients with HER2-low-expressing advanced breast cancer: results from a phase Ib study. *J Clin Oncol*. 2020;38:1887-1896.
46. Mutai R, Barkana T, Moore A, et al. Prognostic impact of HER2-low expression in hormone receptor positive early breast cancer. *Breast*. 2021;60:62-69.
47. Schettini F, Chic N, Brasó-Maristany F, et al. Clinical, pathological, and PAM50 gene expression features of HER2-low breast cancer. *NPJ Breast Cancer*. 2021;7:1.
48. Desmedt C, Salgado R, Fornili M, et al. Immune infiltration in invasive lobular breast cancer. *J Natl Cancer Inst*. 2018;110:768-776.

49. Tille J, Vieira AF, Saint-Martin C, et al. Tumor-infiltrating lymphocytes are associated with poor prognosis in invasive lobular breast carcinoma. *Mod Pathol*. 2020;33:2198-2207.
50. Sobral-Leite M, van de Vijver K, Michaut M, et al. Assessment of PD-L1 expression across breast cancer molecular subtypes, in relation to mutation rate, BRCA1-like status, tumor-infiltrating immune cells and survival. *Oncoimmunology*. 2018;7:e1509820.
51. Michaut M, Chin SF, Majewski I, et al. Integration of genomic, transcriptomic and proteomic data identifies two biologically distinct subtypes of invasive lobular breast cancer. *Sci Rep*. 2016;6:18517.
52. Sokol ES, Feng YX, Jin DX, et al. Loss of function of NF1 is a mechanism of acquired resistance to endocrine therapy in lobular breast cancer. *Ann Oncol*. 2019;30:115-123.
53. Mateo J, Chakravarty D, Dienstmann R, et al. A framework to rank genomic alterations as targets for cancer precision medicine: the ESMO Scale for Clinical Actionability of molecular Targets (ESCAT). *Ann Oncol*. 2018;29:1895-1902.
54. McCart Reed AE, Foong S, Kutasovic JR, et al. The genomic landscape of lobular breast cancer. *Cancers (Basel)*. 2021;13:1950.
55. Razavi P, Chang MT, Xu G, et al. The genomic landscape of endocrine-resistant advanced breast cancers. *Cancer Cell*. 2018;34:427-438.
56. Pareja F, Ferrando L, Lee SSK, et al. The genomic landscape of metastatic histologic special types of invasive breast cancer. *NPJ Breast Cancer*. 2020;6:53.
57. Barroso-Sousa R, Jain E, Cohen O, et al. Prevalence and mutational determinants of high tumor mutation burden in breast cancer. *Ann Oncol*. 2020;31:387-394.
58. Sammons S, Elliott A, Force JM, et al. Genomic evaluation of tumor mutational burden-high (TMB-H) versus TMB-low (TMB-L) metastatic breast cancer to reveal unique mutational features. *J Clin Oncol*. 2021;39: 1091-1091.
59. AssessinG Efficacy of Carboplatin and ATezOlizumab in Metastatic Lobular Breast Cancer - Full Text View - ClinicalTrials.gov. Available at <https://clinicaltrials.gov/ct2/show/NCT03147040?cond=GELATO&draw=2&rank=1>. Accessed June 5, 2022.
60. Deniziaut G, Tille JC, Bidard FC, et al. ERBB2 mutations associated with solid variant of high-grade invasive lobular breast carcinomas. *Oncotarget*. 2016;7:73337-73346.
61. Ma CX, Luo J, Freedman RA, et al. The phase II MutHER study of neratinib alone and in combination with fulvestrant in HER2 mutated, non-amplified metastatic breast cancer. *Clin Cancer Res*. 2022;28: 1258-1267.
62. Teo K, Gómez-Cuadrado L, Tenhagen M, et al. E-cadherin loss induces targetable autocrine activation of growth factor signalling in lobular breast cancer. *Sci Rep*. 2018;8:15454.
63. Sreekumar S, Levine KM, Sikora MJ, et al. Differential regulation and targeting of estrogen receptor α turnover in invasive lobular breast carcinoma. *Endocrinology*. 2020:161.
64. Shackelford MT, Rao DM, Bordeaux EK, et al. Estrogen regulation of mTOR signaling and mitochondrial function in invasive lobular carcinoma cell lines requires WNT4. *Cancers (Basel)*. 2020;12: 2931.
65. Sikora MJ, Cooper KL, Bahreini A, et al. Invasive lobular carcinoma cell lines are characterized by unique estrogen-mediated gene expression patterns and altered tamoxifen response. *Cancer Res*. 2014;74:1463-1474.
66. Nagle AM, Levine KM, Tasdemir N, et al. Loss of E-cadherin enhances IGF1-IGF1R pathway activation and sensitizes breast cancers to anti-IGF1R/InsR inhibitors. *Clin Cancer Res*. 2018;24:5165-5177.
67. Sfmos G, Schipper K, Koorman T, et al. Atlas of lobular breast cancer models: challenges and strategic directions. *Cancers (Basel)*. 2021;13: 5396.
68. Johnson K, Sarma D, Hwang ES. Lobular breast cancer series: imaging. *Breast Cancer Res*. 2015;17:94.
69. Weaver O, Yang W. Imaging of breast cancers with predilection for nonmass pattern of growth: invasive lobular carcinoma and DCIS-does imaging capture it all? *Am J Roentgenol*. 2020;215: 1504-1511.
70. Berg WA, Gutierrez L, NessAiver MS, et al. Diagnostic accuracy of mammography, clinical examination, US, and MR imaging in preoperative assessment of breast cancer. *Radiology*. 2004;233:830-849.
71. Helvie MA. Digital mammography imaging: breast tomosynthesis and advanced applications. *Radiol Clin North Am*. 2010;48:917-929.
72. Niklason LT, Christian BT, Niklason LE, et al. Digital tomosynthesis in breast imaging. *Radiology*. 1997;205:399-406.
73. Jochelson M. Contrast-enhanced digital mammography. *Radiol Clin North Am*. 2014;52:609-616.
74. Butler RS, Venta LA, Wiley EL. Sonographic evaluation of infiltrating lobular carcinoma. *AJR Am J Roentgenol*. 1999;172:325-330.
75. Selinko VL, Middleton LP, Dempsey PJ. Role of sonography in diagnosing and staging invasive lobular carcinoma. *J Clin Ultrasound*. 2004;32:323-332.
76. Paramagul CP, Helvie MA, Adler DD. Invasive lobular carcinoma: sonographic appearance and role of sonography in improving diagnostic sensitivity. *Radiology*. 1995;195:231-234.
77. Bae MS, Moon WK, Chang JM, et al. Breast cancer detected with screening US: reasons for nondetection at mammography. *Radiology*. 2014;270:369-377.
78. Phalak KA, Milton DR, Yang WT, Bevers TB, Dogan BE. Supplemental ultrasound screening in patients with a history of lobular neoplasia. *Breast J*. 2019;25:250-256.
79. Mann RM. The effectiveness of MR imaging in the assessment of invasive lobular carcinoma of the breast. *Magn Reson Imaging Clin N Am*. 2010;18:259-276.
80. Selvi V, Nori J, Meattini I, et al. Role of magnetic resonance imaging in the preoperative staging and work-up of patients affected by invasive lobular carcinoma or invasive ductolobular carcinoma. *Biomed Res Int*. 2018;2018:1569060.
81. Mann RM, Hoogeveen YL, Blickman JG, Boetes C. MRI compared to conventional diagnostic work-up in the detection and evaluation of invasive lobular carcinoma of the breast: a review of existing literature. *Breast Cancer Res Treat*. 2008;107:1-14.
82. Fortune-Greeley AK, Wheeler SB, Meyer AM, et al. Preoperative breast MRI and surgical outcomes in elderly women with invasive ductal and lobular carcinoma: a population-based study. *Breast Cancer Res Treat*. 2014;143:203-212.
83. Ha SM, Chae EY, Cha JH, Kim HH, Shin HJ, Choi WJ. Breast MR imaging before surgery: outcomes in patients with invasive lobular carcinoma by using propensity score matching. *Radiology*. 2018;287:771-777.
84. Cardoso F, Kyriakides S, Ohno S, et al. Early breast cancer: ESMO Clinical Practice Guidelines for diagnosis, treatment and follow-up. *Ann Oncol*. 2019;30:1194-1220.
85. Swinnen J, Keupers M, Soens J, Lavens M, Postema S, van Ongeval C. Breast imaging surveillance after curative treatment for primary non-metastasised breast cancer in non-high-risk women: a systematic review. *Insights Imaging*. 2018;9:961-970.
86. Cardoso F, Paluch-Shimo S, Senkus E, et al. 5th ESO-ESMO international consensus guidelines for advanced breast cancer (ABC 5). *Ann Oncol*. 2020;31:1623-1649.
87. Hogan MP, Goldman DA, Dashevsky B, et al. Comparison of 18F-FDG PET/CT for systemic staging of newly diagnosed invasive lobular carcinoma versus invasive ductal carcinoma. *J Nucl Med*. 2015;56: 1674-1680.
88. Tade FI, Cohen MA, Styblo TM, et al. Anti-3-18F-FACBC (18F-Fluciclovine) PET/CT of breast cancer: an exploratory study. *J Nucl Med*. 2016;57:1357-1363.
89. Venema C, de Vries E, Glaudemans A, Poppema B, Hospers G, Schröder C. 18F-FES PET has added value in staging and therapy decision making in patients with disseminated lobular breast cancer. *Clin Nucl Med*. 2017;42:612-614.
90. Ulaner GA, Jhaveri K, Chandarlapaty S, et al. Head-to-head evaluation of 18F-FES and 18F-FDG PET/CT in metastatic invasive lobular breast cancer. *J Nucl Med*. 2021;62:326-331.
91. van Kruchten M, de Vries EGE, Brown M, et al. PET imaging of oestrogen receptors in patients with breast cancer. *Lancet Oncol*. 2013;14:e465-e475.

92. Zugni F, Ruju F, Pricolo P, et al. The added value of whole-body magnetic resonance imaging in the management of patients with advanced breast cancer. *PLoS One*. 2018;13:e0205251.
93. Straver ME, Th Rutgers EJ, Rodenhuis S, et al. The relevance of breast cancer subtypes in the outcome of neoadjuvant chemotherapy. *Ann Surg Oncol*. 2010;17:2411-2418.
94. Tsung K, Grobmyer SR, Tu C, et al. Neoadjuvant systemic therapy in invasive lobular breast cancer: is it indicated? *Am J Surg*. 2018;215:509-512.
95. Tubiana-Hulin M, Stevens D, Lasry S, et al. Response to neoadjuvant chemotherapy in lobular and ductal breast carcinomas: a retrospective study on 860 patients from one institution. *Ann Oncol*. 2006;17:1228-1233.
96. Petrelli F, Barni S. Response to neoadjuvant chemotherapy in ductal compared to lobular carcinoma of the breast: a meta-analysis of published trials including 1,764 lobular breast cancer. *Breast Cancer Res Treat*. 2013;142:227-235.
97. Lips EH, Mukhtar RA, Yau C, et al. Lobular histology and response to neoadjuvant chemotherapy in invasive breast cancer. *Breast Cancer Res Treat*. 2012;136:35-43.
98. Cocquyt VF, Blondeel PN, Depypere HT, et al. Different responses to preoperative chemotherapy for invasive lobular and invasive ductal breast carcinoma. *Eur J Surg Oncol*. 2003;29:361-367.
99. Delpech Y, Coutant C, Hsu L, et al. Clinical benefit from neoadjuvant chemotherapy in oestrogen receptor-positive invasive ductal and lobular carcinomas. *Br J Cancer*. 2013;108:285-291.
100. Thomas M, Kelly ED, Abraham J, Kruse M. Invasive lobular breast cancer: a review of pathogenesis, diagnosis, management, and future directions of early stage disease. *Semin Oncol*. 2019;46:121-132.
101. Yau C, Osdoit M, van der Noordaa M, et al. Residual cancer burden after neoadjuvant chemotherapy and long-term survival outcomes in breast cancer: a multicentre pooled analysis of 5161 patients. *Lancet Oncol*. 2022;23:149-160.
102. Dixon JM, Renshaw L, Dixon J, Thomas J. Invasive lobular carcinoma: response to neoadjuvant letrozole therapy. *Breast Cancer Res Treat*. 2011;130:871-877.
103. Thornton MJ, Williamson HV, Westbrook KE, et al. Neoadjuvant endocrine therapy versus neoadjuvant chemotherapy in node-positive invasive lobular carcinoma. *Ann Surg Oncol*. 2019;26:3166-3177.
104. Ma CX, Gao F, Luo J, et al. NeoPalAna: neoadjuvant palbociclib, a cyclin-dependent kinase 4/6 inhibitor, and anastrozole for clinical stage 2 or 3 estrogen receptor positive breast cancer. *Clin Cancer Res*. 2017;23:4055-4065.
105. Cottu P, D'Hondt V, Dureau S, et al. Letrozole and palbociclib versus chemotherapy as neoadjuvant therapy of high-risk luminal breast cancer. *Ann Oncol*. 2018;29:2334-2340.
106. Prat A, Saura C, Pascual T, et al. Ribociclib plus letrozole versus chemotherapy for postmenopausal women with hormone receptor-positive, HER2-negative, luminal B breast cancer (CORALLEN): an open-label, multicentre, randomised, phase 2 trial. *Lancet Oncol*. 2020;21:33-43.
107. Nanda R, Liu MC, Yau C, et al. Effect of pembrolizumab plus neoadjuvant chemotherapy on pathologic complete response in women with early-stage breast cancer: an analysis of the ongoing phase 2 adaptively randomized I-SPY2 trial. *JAMA Oncol*. 2020;6:676-684.
108. Wasif N, Maggard MA, Ko CY, Giuliano AE. Invasive lobular versus ductal breast cancer: a stage-matched comparison of outcomes. *Ann Surg Oncol*. 2010;17:1862-1869.
109. Luveta J, Parks RM, Heery DM, Cheung K-L, Johnston SJ. Invasive lobular breast cancer as a distinct disease: implications for therapeutic strategy. *Oncol Ther*. 2020;8:1-11.
110. Wang K, Zhu G-Q, Shi Y, Li ZY, Zhang X, Li HY. Long-term survival differences between T1-2 invasive lobular breast cancer and corresponding ductal carcinoma after breast-conserving surgery: a propensity-scored matched longitudinal cohort study. *Clin Breast Cancer*. 2018;19:e101-e115.
111. Van Wyhe RD, Caudle AS, Shaitelman SF, et al. A component of lobular carcinoma in clinically lymph node-negative patients predicts for an increased likelihood of upstaging to pathologic stage III breast cancer. *Adv Radiat Oncol*. 2018;3:252-257.
112. Vandorpe T, Smeets A, van Calster B, et al. Lobular and non-lobular breast cancers differ regarding axillary lymph node metastasis: a cross-sectional study on 4,292 consecutive patients. *Breast Cancer Res Treat*. 2011;128:429-435.
113. Guo R, Brabham CE, Fahrner-Scott K, et al. Accuracy of sentinel lymph node biopsy in invasive lobular carcinoma of the breast. *J Clin Oncol*. 2020;38.
114. Vo TN, Meric-Bernstam F, Yi M, et al. Outcomes of breast-conservation therapy for invasive lobular carcinoma are equivalent to those for invasive ductal carcinoma. *Am J Surg*. 2006;192:552-555.
115. Mills M, Russo NW, Fahey M, et al. Increased risk for ipsilateral breast tumor recurrence in invasive lobular carcinoma after accelerated partial breast irradiation brachytherapy. *Oncologist*. 2021;26:e1931-e1938.
116. Haviland J, Owen JR, Dewar JA, et al. The UK Standardisation of Breast Radiotherapy (START) trials of radiotherapy hypofractionation for treatment of early breast cancer: 10-year follow-up results of two randomised controlled trials. *Lancet Oncol*. 2013;14:1086-1094.
117. Brunt AM, Haviland JS, Wheatley DA, et al. Hypofractionated breast radiotherapy for 1 week versus 3 weeks (FAST-Forward): 5-year efficacy and late normal tissue effects results from a multicentre, non-inferiority, randomised, phase 3 trial. *Lancet*. 2020;395:1613-1626.
118. Stecklein SR, Shen X, Mitchell MP. Post-mastectomy radiation therapy for invasive lobular carcinoma: a comparative utilization and outcomes study. *Clin Breast Cancer*. 2016;16:319-326.
119. Metzger O, Giobbie-Hurder A, Mallon E, et al. Relative effectiveness of letrozole compared with tamoxifen for patients with lobular carcinoma in the BIG 1-98 trial. *J Clin Oncol*. 2015;33:2772-2779.
120. van De Water W, Fontein DBY, van Nes JGH, et al. Influence of semi-quantitative oestrogen receptor expression on adjuvant endocrine therapy efficacy in ductal and lobular breast cancer—a TEAM study analysis. *Eur J Cancer*. 2013;49:297-304.
121. Hills RK, Oesterreich S, Metzger O, et al. PD14-08: effectiveness of aromatase inhibitors versus tamoxifen in lobular compared to ductal carcinoma: individual patient data meta-analysis of 9328 women with central histopathology, and 7654 women with e-Cadherin status. *Cancer Res*. 2022;82:PD14-08.
122. Francis PA, Pagani O, Fleming GF, et al. Tailoring adjuvant endocrine therapy for premenopausal breast cancer. *N Engl J Med*. 2018;379:122-137.
123. Johnston SRD, Harbeck N, Hegg R, et al. Abemaciclib combined with endocrine therapy for the adjuvant treatment of HR+, HER2-, node-positive, high-risk, early breast cancer (monarchE). *J Clin Oncol*. 2020;38:3987-3998.
124. Mayer EL, Dueck AC, Martin M, et al. Palbociclib with adjuvant endocrine therapy in early breast cancer (PALLAS): interim analysis of a multicentre, open-label, randomised, phase 3 study. *Lancet Oncol*. 2021;22:212-222.
125. Loibl S, Marmé F, Martin M, et al. Palbociclib for residual high-risk invasive HR-positive and HER2-negative early breast cancer—the penelope-B trial. *J Clin Oncol*. 2021;39:1518-1530.
126. Loibl S, Furlanetto J. Integrating CDK4/6 inhibitors in the treatment of patients with early breast cancer. *Breast*. 2022;62(suppl 1):S70-S79.
127. Trapani D, Gandini S, Corti C, et al. Benefit of adjuvant chemotherapy in patients with lobular breast cancer: a systematic review of the literature and meta-analysis. *Cancer Treat Rev*. 2021;97:102205.
128. Chen XH, Zhang WW, Wang J, et al. 21-gene recurrence score and adjuvant chemotherapy decisions in patients with invasive lobular breast cancer. *Biomark Med*. 2019;13:83-93.
129. Hu G, Hu G, Zhang C, et al. Adjuvant chemotherapy could not bring survival benefit to HR-positive, HER2-negative, pT1b-c/NO-1/M0 invasive lobular carcinoma of the breast: a propensity score matching study based on SEER database. *BMC Cancer*. 2020;20:136.
130. Truin W, Voogd AC, Vreugdenhil G, van der Heiden-van der Loo M, Siesling S, Roumen RM. Effect of adjuvant chemotherapy in

- postmenopausal patients with invasive ductal versus lobular breast cancer. *Ann Oncol.* 2012;23:2859-2865.
131. Kizy S, Huang JL, Marmor S, Tuttle TM, Hui JYC. Impact of the 21-gene recurrence score on outcome in patients with invasive lobular carcinoma of the breast. *Breast Cancer Res Treat.* 2017;165:757-763.
 132. Yaghi M. SABCs 2021 ePosters - Does chemotherapy benefit patients with HR+/HER2- invasive lobular breast cancer? Available at <https://cattendee.abstractsonline.com/meeting/10462/presentation/638>. Accessed June 5, 2022.
 133. Gray R, Bradley R, Braybrooke J, Liu Z, Peto R. Increasing the dose intensity of chemotherapy by more frequent administration or sequential scheduling: a patient-level meta-analysis of 37298 women with early breast cancer in 26 randomised trials. *Lancet.* 2019;393:1440-1452.
 134. de Nonneville A, Jauffret C, Gonçalves A, et al. Adjuvant chemotherapy in lobular carcinoma of the breast: a clinicopathological score identifies high-risk patient with survival benefit. *Breast Cancer Res Treat.* 2019;175:379-387.
 135. Tamirisa N, Williamson HV, Thomas SM, et al. The impact of chemotherapy sequence on survival in node-positive invasive lobular carcinoma. *J Surg Oncol.* 2019;120:132-141.
 136. Nitz U, Gluz O, Clemens M, et al. West German study PlanB trial: adjuvant four cycles of epirubicin and cyclophosphamide plus docetaxel versus six cycles of docetaxel and cyclophosphamide in HER2-negative early breast cancer. *J Clin Oncol.* 2019;37:799-808.
 137. Jones S, Holmes FA, O'Shaughnessy J, et al. Docetaxel with cyclophosphamide is associated with an overall survival benefit compared with doxorubicin and cyclophosphamide: 7-year follow-up of us oncology research trial 9735. *J Clin Oncol.* 2009;27:1177-1183.
 138. de Gregorio A, Janni W, Friedl TWP, et al. The impact of anthracyclines in intermediate and high-risk HER2-negative early breast cancer-a pooled analysis of the randomised clinical trials PlanB and SUCCESS C. *Br J Cancer.* 2022. <https://doi.org/10.1038/s41416-021-01690-6>.
 139. Metzger-Filho O, Procter M, de Azambuja E, et al. Magnitude of trastuzumab benefit in patients with HER2-positive, invasive lobular breast carcinoma: results from the HERA trial. *J Clin Oncol.* 2013;31:1954-1960.
 140. Wang J, He ZY, Dong Y, Sun JY, Zhang WW, Wu SG. The distribution and outcomes of the 21-gene recurrence score in T1-T2N0 estrogen receptor-positive breast cancer with different histologic subtypes. *Front Genet.* 2018;9:638.
 141. Makower D, Qin J, Lin J, Xue X, Sparano JA. The 21-gene recurrence score in early non-ductal breast cancer: a National Cancer Database analysis. *NPJ Breast Cancer.* 2022;8:4.
 142. Conlon N, Ross DS, Howard J, Catalano JP, Dickler MN, Tan LK. Is there a role for Oncotype Dx testing in invasive lobular carcinoma? *Breast J.* 2015;21:514-519.
 143. Tsai ML, Lillemoe TJ, Finkelstein MJ, et al. Utility of Oncotype DX risk assessment in patients with invasive lobular carcinoma. *Clin Breast Cancer.* 2016;16:45-50.
 144. Felts JL, Zhu J, Han B, Smith SJ, Truica CI. An analysis of Oncotype DX recurrence scores and clinicopathologic characteristics in invasive lobular breast cancer. *Breast J.* 2017;23:677-686.
 145. Tadros AB, Wen HY, Morrow M. Breast cancers of special histologic subtypes are biologically diverse. *Ann Surg Oncol.* 2018;25:3158-3164.
 146. Bomeisl PE, Thompson CL, Harris LN, Gilmore HL. Comparison of Oncotype DX recurrence score by histologic types of breast carcinoma. *Arch Pathol Lab Med.* 2015;139:1546-1549.
 147. Wilson PC, Chagpar AB, Cicek AF, et al. Breast cancer histopathology is predictive of low-risk Oncotype Dx recurrence score. *Breast J.* 2018;24:976-980.
 148. Hanna MG, Bleiweiss JJ, Nayak A, Jaffer S. Correlation of Oncotype DX recurrence score with histomorphology and immunohistochemistry in over 500 patients. *Int J Breast Cancer.* 2017;2017:1257078.
 149. Beumer IJ, Persoon M, Witteveen A, et al. Prognostic value of mammaPrint® in invasive lobular breast cancer. *Biomark Insights.* 2016;11:139-146.
 150. Jenkins JA, Marmor S, Hui JYC, et al. The 70-gene signature test as a prognostic and predictive biomarker in patients with invasive lobular breast cancer. *Breast Cancer Res Treat.* 2022;191:401-407.
 151. Abel MK, Shui AM, Melisko M, et al. The incidence of discordant clinical and genomic risk in patients with invasive lobular or ductal carcinoma of the breast: a National Cancer Database Study. *NPJ Breast Cancer.* 2021;7:1-6.
 152. Lænkholm AV, Jensen MB, Eriksen JO, et al. Population-based study of prosigna-PAM50 and outcome among postmenopausal women with estrogen receptor-positive and HER2-negative operable invasive lobular or ductal breast cancer. *Clin Breast Cancer.* 2020;20:e423-e432.
 153. Sestak I, Filipits M, Buus R, et al. Prognostic value of endopredict in women with hormone receptor-positive, Her2-negative invasive lobular breast cancer. *Clin Cancer Res.* 2020;26:4682-4687.
 154. Nunes R, Sella T, Treuner K, et al. Prognostic utility of breast cancer index to stratify distant recurrence risk in invasive lobular carcinoma. *Clin Cancer Res.* 2021;27:5688-5696.
 155. Metzger-Filho O, Michiels S, Bertucci F, et al. Genomic grade adds prognostic value in invasive lobular carcinoma. *Ann Oncol.* 2013;24:377-384.
 156. McCart Reed AE, Lal S, Kutasovic JR, et al. LobSig is a multigene predictor of outcome in invasive lobular carcinoma. *NPJ Breast Cancer.* 2019;5:1-11.
 157. Sledge GW, Toi M, Neven P, et al. MONARCH 2: abemaciclib in combination with fulvestrant in women with HR+/HER2-advanced breast cancer who had progressed while receiving endocrine therapy. *J Clin Oncol.* 2017;35:2875-2884.
 158. Johnston S, Martin M, Di Leo A, et al. MONARCH 3 final PFS: a randomized study of abemaciclib as initial therapy for advanced breast cancer. *NPJ Breast Cancer.* 2019;5:5.
 159. Finn RS, Martin M, Rugo HS, et al. Palbociclib and letrozole in advanced breast cancer. *N Engl J Med.* 2016;375:1925-1936.
 160. Turner NC, Slamon DJ, Ro J, et al. Overall survival with palbociclib and fulvestrant in advanced breast cancer. *N Engl J Med.* 2018;379:1926-1936.
 161. Hortobagyi GN, Stemmer SM, Burris HA, et al. Updated results from MONALEESA-2, a phase III trial of first-line ribociclib plus letrozole versus placebo plus letrozole in hormone receptor-positive, HER2-negative advanced breast cancer. *Ann Oncol.* 2018;29:1541-1547.
 162. Slamon DJ, Neven P, Chia S, et al. Overall survival with ribociclib plus fulvestrant in advanced breast cancer. *N Engl J Med.* 2020;382:514-524.
 163. Im S-A, Lu Y-S, Bardia A, et al. Overall survival with ribociclib plus endocrine therapy in breast cancer. *N Engl J Med.* 2019;381:307-316.
 164. Cristofanilli M, Turner NC, Bondarenko I, et al. Fulvestrant plus palbociclib versus fulvestrant plus placebo for treatment of hormone-receptor-positive, HER2-negative metastatic breast cancer that progressed on previous endocrine therapy (PALOMA-3): final analysis of the multicentre, double-blind, phase 3 randomised controlled trial. *Lancet Oncol.* 2016;17:425-439.
 165. Gao JJ, Cheng J, Bloomquist E, et al. CDK4/6 inhibitor treatment for patients with hormone receptor-positive, HER2-negative, advanced or metastatic breast cancer: a US Food and Drug Administration pooled analysis. *Lancet Oncol.* 2020;21:250-260.
 166. Gao JJ, Cheng J, Prowell TM, et al. Overall survival in patients with hormone receptor-positive, HER2-negative, advanced or metastatic breast cancer treated with a cyclin-dependent kinase 4/6 inhibitor plus fulvestrant: a US Food and Drug Administration pooled analysis. *Lancet Oncol.* 2021;22:1573-1581.
 167. Pérez-García J, Cortés J, Metzger Filho O. Efficacy of single-agent chemotherapy for patients with advanced invasive lobular carcinoma: a pooled analysis from three clinical trials. *Oncologist.* 2019;24:1041-1047.
 168. Thijssen S, Wildiers H, Punie K, et al. Features of durable response and treatment efficacy for capecitabine monotherapy in advanced breast cancer: real-world evidence from a large single-centre cohort. *J Cancer Res Clin Oncol.* 2021;147:1041-1048.
 169. Jhaveri K, Park H, Waisman J, et al. Neratinib + fulvestrant + trastuzumab for hormone-receptor positive, HER2-mutant metastatic breast cancer, and neratinib + trastuzumab for metastatic triple-

- negative disease: latest updates from the SUMMIT trial. Available at <https://assets.onlineeventapp.com/utsabcsannual21/EventFiles/sabcs2021/PresentationFiles/Uploads/23148034/30855167/Jhaveri GS4-10.pdf>. Accessed June 5, 2022.
170. Li BT, Smit EF, Goto Y, et al. Trastuzumab deruxtecan in HER2-mutant non—small-cell lung cancer. *N Engl J Med*. 2021;386:241-251.
 171. Kiavue N, Cabel L, Melaabi S, et al. ERBB3 mutations in cancer: biological aspects, prevalence and therapeutics. *Oncogene*. 2020;39:487-502.
 172. Rugo HS, Delord JP, Im SA, et al. Safety and antitumor activity of pembrolizumab in patients with estrogen receptor-positive/ human epidermal growth factor receptor 2-negative advanced breast cancer 2018;24(12):2804-2811. Accessed June 5, 2022.
 173. Voorwerk L, Horlings H, Van Dongen M, et al. LBA3 - Atezolizumab with carboplatin as immune induction in metastatic lobular breast cancer: first results of the GELATO-trial. Available at <https://slide.ctimeingtech.com/play/7L2406w035j>. Accessed June 5, 2022.
 174. Lu YS, Lee KS, Chao T-Y, et al. A phase Ib study of alpelisib or buparlisib combined with tamoxifen plus goserelin in premenopausal women with HR-positive HER2-negative advanced breast cancer. *Clin Cancer Res*. 2021;27:408-417.
 175. André F, Ciruelos E, Rubovszky G, et al. Alpelisib for PIK3CA-mutated, hormone receptor—positive advanced breast cancer. *N Engl J Med*. 2019;380:1929-1940.
 176. Baselga J, Campone M, Piccart M, et al. Everolimus in postmenopausal hormone-receptor-positive advanced breast cancer abstract. *N Engl J Med*. 2011;366:520-529.
 177. Piccart M, Hortobagay GN, Campone M, et al. Everolimus plus exemestane for hormone-receptor-positive, human epidermal growth factor receptor-2-negative advanced breast cancer: overall survival results from BOLERO-2. *Ann Oncol*. 2014;25:2357-2362.
 178. Zimmer AS, Gillard M, Lipkowitz S, Lee JM. Update on PARP inhibitors in breast cancer. *Curr Treat Options Oncol*. 2018;19:21.
 179. Bardia A, Hurvitz SA, Tolaney SM, et al. Sacituzumab govitecan in metastatic triple-negative breast cancer. *N Engl J Med*. 2021;384:1529-1541.
 180. Jeselsohn R, Buchwalter G, De Angelis C, Brown M, Schiff R. ESR1 mutations—a mechanism for acquired endocrine resistance in breast cancer. *Nat Rev Clin Oncol*. 2015;12:573-583.
 181. Desmedt C, Pingitore J, Rothé F, et al. ESR1 mutations in metastatic lobular breast cancer patients. *NPJ Breast Cancer*. 2019;5:9.
 182. Du T, Sikora MJ, Levine KM, et al. Key regulators of lipid metabolism drive endocrine resistance in invasive lobular breast cancer. *Breast Cancer Res*. 2018;20:1-15.
 183. Levine KM, Priedigkeit N, Basudan A, et al. FGFR4 overexpression and hotspot mutations in metastatic ER+ breast cancer are enriched in the lobular subtype. *NPJ Breast Cancer*. 2019;5:19.
 184. Sikora MJ, Priedigkeit N, Basudan A, et al. WNT4 mediates estrogen receptor signaling and endocrine resistance in invasive lobular carcinoma cell lines. *Breast Cancer Res*. 2016;18:92.
 185. Costa C, Wang Y, Ly A, et al. PTEN loss mediates clinical cross-resistance to CDK4/6 and PI3K α inhibitors in breast cancer. *Cancer Discov*. 2020;10:72-85.
 186. Bardia A, Su F, Solovieff N, et al. Genomic profiling of premenopausal HR+ and HER2- metastatic breast cancer by circulating tumor DNA and association of genetic alterations with therapeutic response to endocrine therapy and ribociclib 2021;5:1408-1420.
 187. Bortolini Silveira A, Bidard F-C, Tanguy M-L, et al. Multimodal liquid biopsy for early monitoring and outcome prediction of chemotherapy in metastatic breast cancer. *NPJ Breast Cancer*. 2021;7:1-9.
 188. Mukhtar RA, Chien AJ. Invasive lobular carcinoma of the breast: ongoing trials, challenges, and future directions. *Curr Breast Cancer Rep*. 2021;13:164-170.
 189. Abel MK, Melisko ME, Rugo HS, et al. Decreased enrollment of patients with advanced lobular breast cancer compared to ductal breast cancer in interventional clinical trials. *J Clin Oncol*. 2021;39:1092.
 190. Ma CX, Suman VJ, Leitch AM, et al. ALTERNATE: neoadjuvant endocrine treatment (NET) approaches for clinical stage II or III estrogen receptor-positive HER2-negative breast cancer (ER+ HER2- BC) in postmenopausal (PM) women: Alliance A011106. *J Clin Oncol*. 2020;38:504.
 191. Droufakou S, Deshmane V, Roylance R, Hanby A, Tomlinson I, Hart IR. Multiple ways of silencing E-cadherin gene expression in lobular carcinoma of the breast. *Int J Cancer*. 2001;92:404-408.
 192. Bruner HC, Derksen PWB. Loss of E-cadherin-dependent cell-cell adhesion and the development and progression of cancer. *Cold Spring Harb Perspect Biol*. 2018;10:a029330.
 193. Bajrami I, Marlow R, van de Ven M, et al. E-cadherin/ROS1 inhibitor synthetic lethality in breast cancer. *Cancer Discov*. 2018;8:498-515.
 194. Telford B, Chen A, Beetham H, et al. Synthetic lethal screens identify vulnerabilities in GPCR signaling and cytoskeletal organization in E-cadherin-deficient cells. *Mol Cancer Ther*. 2015;14:1213-1223.
 195. Hornsveld M, Tenhagen M, van de Ven RA, et al. Restraining FOXO3-dependent transcriptional BMF activation underpins tumour growth and metastasis of E-cadherin-negative breast cancer. *Cell Death Differ*. 2016;23:1483-1492.
 196. Schipper K, Seinstra D, Drenth AP, et al. Rebalancing of actomyosin contractility enables mammary tumor formation upon loss of E-cadherin. *Nat Commun*. 2019;10:3800.
 197. Walsh L, Haley KE, Moran B, et al. BET inhibition as a rational therapeutic strategy for invasive lobular breast cancer. *Clin Cancer Res*. 2019;25:7139-7150.
 198. Sergio Reis-Filho J, Simpson PT, Turner NC, et al. FGFR1 emerges as a potential therapeutic target for lobular breast carcinomas. *Clin Cancer Res*. 2006;12:6652-6662.
 199. Klarenbeek S, Doornebal CW, Kas SM, et al. Response of metastatic mouse invasive lobular carcinoma to mTOR inhibition is partly mediated by the adaptive immune system. *Oncoimmunology*. 2020;9:1724049.
 200. Nakagawa S, Miki Y, Miyashita M, et al. Tumor microenvironment in invasive lobular carcinoma: possible therapeutic targets. *Breast Cancer Res Treat*. 2016;155:65-75.
 201. Godwin TD, Kelly ST, Brew TP, et al. E-cadherin-deficient cells have synthetic lethal vulnerabilities in plasma membrane organisation, dynamics and function. *Gastric Cancer*. 2019;22:273-286.
 202. Bougen-Zhukov N, Nouri Y, Godwin T, et al. Allosteric AKT inhibitors target synthetic lethal vulnerabilities in E-cadherin-deficient cells. *Cancers (Basel)*. 2019;11:1359.
 203. Riva C, Dainese E, Caprara G, et al. Immunohistochemical study of androgen receptors in breast carcinoma. Evidence of their frequent expression in lobular carcinoma. *Virchows Arch*. 2005;447:695-700.
 204. Taniguchi K, Takada S, Omori M, et al. Triple-negative pleomorphic lobular carcinoma and expression of androgen receptor: personal case series and review of the literature. *PLoS One*. 2020;15:e0235790.
 205. Pate L, Desmedt C, Metzger O, et al. How researchers, clinicians and patient advocates can accelerate lobular breast cancer research. *Cancers (Basel)*. 2021;13:3094.
 206. Condorelli R, Mosele F, Verret B, et al. Genomic alterations in breast cancer: level of evidence for actionability according to ESMO Scale for Clinical Actionability of molecular Targets (ESCAT). *Ann Oncol*. 2019;30:365-373.
 207. Cao L, Basudan A, Sikora MJ, et al. Frequent amplifications of ESR1, ERBB2 and MDM4 in primary invasive lobular breast carcinoma. *Cancer Lett*. 2019;461:21-30.
 208. Krammer J, Stepniwski K, Kaiser CG, et al. Value of additional digital breast tomosynthesis for preoperative staging of breast cancer in dense breasts. *Anticancer Res*. 2017;37:5255-5261.
 209. Amato F, Bicchieri G, Cirone D, et al. Preoperative loco-regional staging of invasive lobular carcinoma with contrast-enhanced digital mammography (CEDM). *Radiol Med*. 2019;124:1229-1237.
 210. Hogan MP, Amir T, Sevilmedu V, Sung J, Morris EA, Jochelson MS. Contrast-enhanced digital mammography screening for intermediate-risk women with a history of lobular neoplasia. *Am J Roentgenol*. 2021;2016:1486-1491.