

Journal of Nephropathology



Ameliorative impact of ezetimibe on gentamicin-induced kidney damage; A histopathological perspective study

Elham Emami¹, Ali Hasanpour Dehkordi², Ahmadreza Maghsoudi^{3*}, Hamid Nasri^{3,4,5*}, Alireza Vahedi⁶

¹Pediatric Nephrology Research Center (PNRC), Faculty of Medicine, Shahid Beheshti University of Medical Sciences, Emam Hosein hospital, Tehran, Iran

²Social Determinants of Health, Research Center, School of Allied Medical Sciences, Shahrekord University of Medical Sciences, Shahrekord, Iran

³Department of Internal Medicine, Isfahan University of Medical Sciences, Isfahan, Iran

⁴Department of Pathology, Nickan Research Institute, Isfahan, Iran

⁵Eurasian Nephropathology Society (ENPS), Moscow, Russia

⁶Breast Cancer Research Center, Motemed Cancer Institute, Tehran, Iran

ARTICLE INFO

Article type:
Original Article

Article history:
Received: 11 September 2021
Accepted: 20 December 2021
Published online: 10 January 2022

Keywords:
Gentamicin
Kidney damage
Ezetimibe

ABSTRACT

Introduction: Gentamicin, despite its beneficial effects, has significant nephrotoxic effects that are observed in 20% of the patients. Ezetimibe is recognized as an inhibitor of cholesterol absorption.

Objectives: The present study aimed to investigate the histopathological effects of ezetimibe on gentamicin-induced kidney damage.

Materials and Methods: Twenty male Wistar rats were randomly divided into five groups and treated as the following; group 1 (normal group), group 2 [gentamicin group, daily 80 mg/kg, intraperitoneal (i.p.) for seven days], group 3-5 (gentamicin 80 + ezetimibe at doses of 2.5, 12.5, and 37.5 mg/kg, respectively). Kidney sections were examined for histopathological parameters including vacuolization of the tubular renal cells, degeneration, necrosis, flattening of the tubular cells and debris in the tubular lumen.

Results: Gentamicin injection significantly induced histopathological alterations ($P < 0.05$). Ezetimibe therapy significantly decreased the levels of vacuolization, degeneration, necrosis, flattening of the tubular cells and debris in the nephrotoxic rats ($P < 0.05$).

Conclusion: The results illustrated that treatment with ezetimibe can improve kidney damage caused by gentamicin injection.

Implication for health policy/practice/research/medical education:

In an experimental study, we found that treatment with ezetimibe can improve kidney damage caused by gentamicin injection.

Please cite this paper as: Emami E, Hasanpour Dehkordi A, Maghsoudi A, Nasri H, Vahedi A. Ameliorative impact of ezetimibe on gentamicin-induced kidney damage; A histopathological perspective study. J Nephropathol. 2022;11(2):e17341. DOI: 10.34172/jnp.2022.17341.

Introduction

Kidney damage can be acute or chronic and is assessed with serum markers such as blood urea nitrogen (BUN) and creatinine levels as well as other biomarkers (1). Serum creatinine and blood urea have been reported to increase 7-10 days after the initiation of treatment with aminoglycosides (2).

Aminoglycoside antibiotics, such as gentamicin are administered to treat gram-negative bacterial infections (3). Gentamicin, despite its beneficial effects, has

significant nephrotoxic effects that are observed in 20% of the patients. The toxicity of gentamicin is associated with its accumulation in the renal cortex, especially in the proximal tubules, which induces apoptosis and necrosis in the epithelial cells (4,5). Despite the introduction of less nephrotoxic antibiotics against gram-negative microorganisms, gentamicin is still widely administered due to its low-cost and effectiveness (6). Therefore, a potential therapeutic approach to protect or reverse the effects of gentamicin-induced kidney damage would have

*Corresponding authors: Ahmadreza Maghsoudi, Email: ahmaghsoudi@med.mui.ac.ir, dr_maghsoudi_md@yahoo.com and Hamid Nasri, Email: hamidnasri@med.mui.ac.ir

significant clinical benefits.

The exact mechanism of gentamicin in the development of renal toxicity is unknown; however, reactive oxygen species (ROS) appear to be involved (7-11). The production of the renal cortical lipoperoxidation and hydrogen peroxide (H₂O₂) has been demonstrated to increase in gentamicin-treated mice (7, 8). According to studies, administration of antioxidant enzymes such as superoxide dismutase (SOD), glutathione peroxidase (GPx), glutathione reductase (GR) and catalase (CAT) recuperates the severity of gentamicin-induced renal damage. Kidney damage is also reduced by consuming dietary antioxidants, vitamin E and selenium (12,13).

Ezetimibe is an inhibitor of cholesterol absorption. It blocks intestinal absorption of cholesterol and phytosterols through its interaction with sterol transporters, detected as Niemann-Pick C1-like1 protein (NPC1L1) (14-16). In animal models, the uptake inhibition of intestinal cholesterol by ezetimibe leads to a decrease in cholesterol-retaining fat in chylomicrons; therefore, the amount of cholesterol that is transferred by chylomicron to the liver reduces (17). This leads to the rearrangement of hepatic low-density lipoprotein (LDL) receptors which, in turn, has been accompanied by an elevation in LDL-receptor presentation and to a reduction in LDL-cholesterol (18-20).

Objectives

The present study aimed to investigate the histopathological effects of ezetimibe on gentamicin-induced kidney damage.

Materials and Methods

Animals and study design

Twenty male Wistar rats weighing 200-250 g were used in the present study. The animals were kept in the Research Center of Medicinal Plants, Shahrekord University of Medical Sciences in a standard condition (temperature 21-25°C and 12-hour cycle of darkness and light) with access to water and food.

The rats were divided into five groups (n=4); group 1(normal group); received no drug. Group 2 received gentamicin at a dose of 80 mg/kg. Group 3 to 5 received gentamicin at a dose of 80 mg/kg and after a one-hour interval, ezetimibe at doses of 2.5, 12.5 and 37.5 mg/kg, respectively. Injections were administered intraperitoneally for seven days.

Histopathological examinations

Ultimately, the kidneys of the animals were isolated and kept in formalin for 12 hours and processed for histopathological examination. The 3 µm-thick paraffin tissues were stained with hematoxylin and eosin (H&E).

All samples were examined for histopathological parameters including vacuolization of the tubular renal cells, degeneration, necrosis, flattening of the tubular cells and debris in the tubular lumen.

Statistical analysis

All data were analyzed through one-way ANOVA and then the post hoc Tukey test using GraphPad Prism version 4.03 and expressed as the mean ± standard error (SE). $P < 0.05$ was considered statistically significant.

Results

According to the results demonstrated in Figure 1 (A-D), vacuolization, flattening, degeneration and necrosis in the group receiving gentamicin enhanced remarkably compared to the normal group ($P < 0.001$). The groups receiving ezetimibe had a significant decrease of the above histopathological parameters in all doses compared to the gentamicin group ($P < 0.001$).

Regarding the debris parameter (Figure 1E), a significant difference between the gentamicin group and the normal group was detected ($P < 0.01$). In addition, a significant decrease of debris parameter in the groups receiving

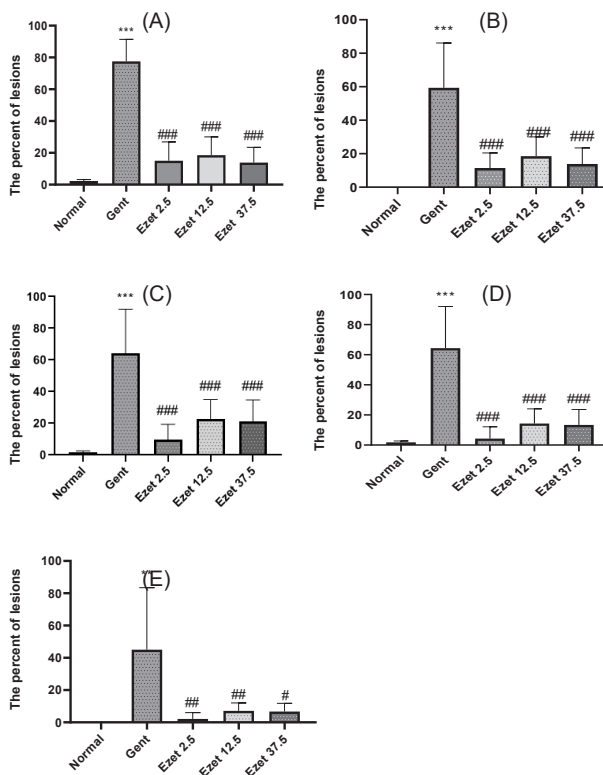


Figure 1. Comparison of vacuolization (A), flattening of the tubular cell (B), degeneration (C), necrosis (D), and debris (E) in the study groups (ezetimibe at doses of 2.5, 12.5 and 37.5 mg/kg). *** $P < 0.001$ compared to the normal group. # $P < 0.05$, ## $P < 0.01$ and ### $P < 0.001$ compared to the Gentamicin group. Gent: Gentamicin. Ezet: Ezetimibe.

ezetimibe at doses of 2.5, 12.5 ($P < 0.01$) and 37.5 mg/kg ($P < 0.05$) compared to the gentamicin group was revealed ($P < 0.05$).

Discussion

Comparison of the effects of gentamicin administration alone and in combination with ezetimibe at different doses of 2.5, 12.5, and 37.5 mg/kg showed that ezetimibe was able to effectively diminish the histopathological alterations caused by gentamicin.

Since hyperlipidemia, defined as an increase in total serum cholesterol and a decrease in high-density lipoprotein, leads to the development of renal failure; therefore, the use of hypocholesterolemic drugs can be advantageous in decreasing the cholesterol levels and subsequently, improving renal function (21-23).

Accumulation of gentamicin in the proximal tubular cells of the kidney leads to renal toxicity and injury to the brush border network (24,25). Renal toxicity is caused by the production and accumulation of free radicals in kidney tissue resulting in acute tubular necrosis, which leads to the abolition of creatinine clearance and impaired renal function (24-26). In our study, gentamicin disrupted kidney function and structure compared to the control group.

Ezetimibe, as a cholesterol-lowering drug, prevents the absorption of cholesterol by the small intestine and effectively declines plasma cholesterol levels (26, 27). The Niemann-Pick C1 (NPC1) gene is involved in the transfer of intracellular cholesterol and is the causative gene of NPC1 disorder, a rare autosomal recessive disease caused by the accumulation of free cholesterol in the cells (28).

Studies have confirmed that the NPC1L1 protein is an important site for intestinal cholesterol uptake and ezetimibe appears to inhibit cholesterol uptake; leading to a reduction in the diseases caused by this protein, such as ataxia, spasticity, seizures, hepatosplenomegaly and atherosclerosis. After being absorbed into enterocytes, cholesterol is esterified and packaged in the form of chylomicrons, which are absorbed by the receptors of the liver cells. Cholesterol is then secreted into the bile or packed in large amounts of LDL. By blocking the NPC1L1 receptor, ezetimibe reduces cholesterol in the enterocytes and leads to partial depletion of cholesterol in the hepatocytes (29,30).

In a study on the effects of ezetimibe on cholesterol treatment, Pandya et al concluded that treatment with ezetimibe resulted in a slight reduction in malonaldehyde and a significant reduction in SOD levels and subsequently, reduces oxidative stress and prevents the formation of free radicals. Their results showed that ezetimibe lowers cholesterol levels by increasing antioxidant activity and decreasing LDL (31).

Conclusion

Gentamicin causes kidney damage and toxicity and ezetimibe appears to counteract the effects of gentamicin. Based on the results, ezetimibe exerts its effects by lowering cholesterol, reducing free radicals and increasing the activity of antioxidants. It seems that the use of ezetimibe in combination with other drugs such as statins can increase its effects on improving renal failure.

Acknowledgments

Authors would like to thank Elham Bijad for statistical analysis.

Authors' contribution

Proposal preparing; HN. Animal lab supervision and headlining; AHD. First edit; EE and AV. ARM and HN both are corresponding authors who edited and finalized the paper equally. All authors read and signed the final paper.

Conflicts of interest

As one of the contributing authors to this study, HN acts as the Editor-in-Chief of the journal. It should be noted that his contribution to this journal has not influenced the peer-review process.

Ethical issues

This study was approved by the Ethics Committee of NIMAD (National Institute for Medical Research Development; <http://nimad.ac.ir>, in Iran; ethical code#IR.NIMAD.REC.1399.024). This study is a part of an investigation granted by NIMAD (Grant #972048). This investigation was also conducted according to the regulations of the Research Ethics Committee of Iranian Ethical Guidelines for the use of animals in research. Additionally, all animal experiments were in accordance with the protocols approved by the United States National Institutes of Health (NIH, 1978). Besides, ethical issues (including plagiarism, data fabrication, double publication) have been completely observed by the authors.

Funding/Support

This paper was a part of a research project was granted by NIMAD (<http://nimad.ac.ir>) from Iran (Grant #972048, ethical code #IR.NIMAD.REC.1399.024).

References

1. Pfaller W, Gstraunthaler G. Nephrotoxicity testing in vitro-what we know and what we need to know. *Environ Health Perspect.* 1998;106:559-69.
2. Sandhu J, Sehgal A, Gupta O, Singh A. Aminoglycoside nephrotoxicity revisited. *J Indian Acad Clin Med.*

- 2007;8:331-3.
3. Ali B. The effect of treatment with the medicinal plant *Rhazya stricta* decne on gentamicin nephrotoxicity in rats. *Phytomedicine*. 2002;9:385-9.
 4. Quiros Y, Vicente-Vicente L, Morales AI, López-Novoa JM, López-Hernández FJ. An integrative overview on the mechanisms underlying the renal tubular cytotoxicity of gentamicin. *Toxicol Sci*. 2011;119:245-56. doi: 10.1093/toxsci/kfq267.
 5. Nagai J, Takano M. Molecular aspects of renal handling of aminoglycosides and strategies for preventing the nephrotoxicity. *Drug Metab Pharmacokinet*. 2004;19:159-70.
 6. Edson RS, Terrell CL. The aminoglycosides. *Mayo Clin Proc*. 1999;74:519-28. doi: 10.4065/74.5.519.
 7. Guidet BR, Shah SV. In vivo generation of hydrogen peroxide by rat kidney cortex and glomeruli. *Am J Physiol Renal Physiol*. 1989;256:F158-F64.
 8. Nakajima T, Hishida A, Kato A. Mechanisms for protective effects of free radical scavengers on gentamicin-mediated nephropathy in rats. *Am J Physiol Renal Physiol*. 1994;266:F425-F31.
 9. Walker PD, Shah SV. Gentamicin enhanced production of hydrogen peroxide by renal cortical mitochondria. *Am J Physiol Renal Physiol*. 1987;253:C495-C9.
 10. Walker PD, Shah SV. Evidence suggesting a role for hydroxyl radical in gentamicin-induced acute renal failure in rats. *J Clin Invest*. 1988;81:334-41.
 11. Yang C-L, Du X-H, Han Y-X. Renal cortical mitochondria are the source of oxygen free radicals enhanced by gentamicin. *Ren Fail*. 1995;17:21-6.
 12. Ademuyiwa O, Ngaha E, Ubah F. Vitamin E and selenium in gentamicin nephrotoxicity. *Hum Exp Toxicol*. 1990;9:281-8.
 13. Maldonado PD, Barrera D, Medina-Campos ON, Hernández-Pando R, Ibarra-Rubio ME, Pedraza-Chaverri J. Aged garlic extract attenuates gentamicin induced renal damage and oxidative stress in rats. *Life Sci*. 2003;73:2543-56.
 14. Garcia-Calvo M, Lisnock J, Bull HG, Hawes BE, Burnett DA, Braun MP, et al. The target of Ezetimibe is Niemann-Pick C1-Like 1 (NPC1L1). *Proc Natl Acad Sci*. 2005;102:8132-7.
 15. Davis Jr HR, Zhu L-j, Hoos LM, Tetzloff G, Maguire M, Liu J, et al. Niemann-Pick C1 Like 1 (NPC1L1) is the intestinal phytosterol and cholesterol transporter and a key modulator of whole-body cholesterol homeostasis. *J Biol Chem*. 2004;279:33586-92.
 16. Lammert F, Wang DQ-H. New insights into the genetic regulation of intestinal cholesterol absorption. *Gastroenterology*. 2005;129:718-34.
 17. van Heek M, Compton DS, Davis HR. The cholesterol absorption inhibitor, ezetimibe, decreases diet-induced hypercholesterolemia in monkeys. *Eur J Pharmacol*. 2001;415:79-84.
 18. Bays H, Stein EA. Pharmacotherapy for dyslipidaemia—current therapies and future agents. *Expert Opin Pharmacother*. 2003;4:1901-38.
 19. Davis H, Compton D, Hoos L, Tetzloff G, editors. Ezetimibe reduces plasma cholesterol and inhibits the development of atherosclerosis in apo E knockout mice with and without LDL receptors. Philadelphia, PA: Lippincott Williams & Wilkins; 2000.
 20. Repa JJ, Turley SD, Quan G, Dietschy JM. Delineation of molecular changes in intrahepatic cholesterol metabolism resulting from diminished cholesterol absorption. *J Lipid Res*. 2005;46:779-89.
 21. Ishimitsu T, Ohno E, Ueno Y, Onoda S, Nagase A, Ohira T, et al. Effects of atorvastatin and ezetimibe on endothelial function in dyslipidemic patients with chronic kidney disease. *Clin Exp Nephrol*. 2014;18:704-10. doi: 10.1007/s10157-013-0904-7.
 22. Schaeffner ES, Kurth T, Curhan GC, Glynn RJ, Rexrode KM, Baigent C, et al. Cholesterol and the risk of renal dysfunction in apparently healthy men. *J Am Soc Nephrol*. 2003;14:2084-91.
 23. Mänttari M, Tiula E, Alikoski T, Manninen V. Effects of hypertension and dyslipidemia on the decline in renal function. *Hypertension*. 1995;26:670-5.
 24. Watanabe A, Nagai J, Adachi Y, Katsube T, Kitahara Y, Murakami T, et al. Targeted prevention of renal accumulation and toxicity of gentamicin by aminoglycoside binding receptor antagonists. *J Control Release*. 2004;95:423-33.
 25. Randjelovic P, Veljkovic S, Stojiljkovic N, Sokolovic D, Ilic I. Gentamicin nephrotoxicity in animals: Current knowledge and future perspectives. *EXCLI J*. 2017;16:388-399. doi: 10.17179/excli2017-165.
 26. Salen G, Von Bergmann K, Lütjohann Dt, Kwiterovich P, Kane J, Patel S, et al. Ezetimibe effectively reduces plasma plant sterols in patients with sitosterolemia. *Circulation*. 2004;109:966-71.
 27. Knopp RH, Gitter H, Truitt T, Bays H, Manion CV, Lipka LJ, et al. Effects of ezetimibe, a new cholesterol absorption inhibitor, on plasma lipids in patients with primary hypercholesterolemia. *Eur Heart J*. 2003;24:729-41. doi: 10.1016/s0195-668x(02)00807-2. PMID: 12713767.
 28. Davies JP, Levy B, Ioannou YA. Evidence for a Niemann–Pick C (NPC) gene family: identification and characterization of NPC1L1. *Genomics*. 2000;65:137-45.
 29. Huff MW, Pollex RL, Hegele RA. NPC1L1: evolution from pharmacological target to physiological sterol transporter. *Arterioscler Thromb Vasc Biol*. 2006;26:2433-8.
 30. Davis Jr HR, Hoos LM, Tetzloff G, Maguire M, Zhu L-j, Graziano MP, et al. Deficiency of Niemann-Pick C1 Like 1 prevents atherosclerosis in ApoE^{-/-} mice. *Arterioscler Thromb Vasc Biol*. 2007;27:841-9.
 31. Pandya N, Santani D, Jain S. Antioxidant activity of Ezetimibe in hypercholesterolemic rats. *Indian J Pharmacol*. 2006;38:205.