

Loma Linda University

TheScholarsRepository@LLU: Digital Archive of Research,  
Scholarship & Creative Works

---

Loma Linda University Electronic Theses, Dissertations & Projects

---

6-1993

## Soft Tissue Changes of the Lower Lip Following Isolated Mandibular Advancement Osteotomies

Ronald Roy A. Simus

Follow this and additional works at: <https://scholarsrepository.llu.edu/etd>



Part of the [Orthodontics and Orthodontology Commons](#)

---

### Recommended Citation

Simus, Ronald Roy A., "Soft Tissue Changes of the Lower Lip Following Isolated Mandibular Advancement Osteotomies" (1993). *Loma Linda University Electronic Theses, Dissertations & Projects*. 1629.  
<https://scholarsrepository.llu.edu/etd/1629>

This Thesis is brought to you for free and open access by TheScholarsRepository@LLU: Digital Archive of Research, Scholarship & Creative Works. It has been accepted for inclusion in Loma Linda University Electronic Theses, Dissertations & Projects by an authorized administrator of TheScholarsRepository@LLU: Digital Archive of Research, Scholarship & Creative Works. For more information, please contact [scholarsrepository@llu.edu](mailto:scholarsrepository@llu.edu).

**LOMA LINDA UNIVERSITY**

Graduate School

---

**SOFT TISSUE CHANGES OF THE LOWER LIP  
FOLLOWING ISOLATED MANDIBULAR  
ADVANCEMENT OSTEOTOMIES**

by

**Ronald Roy A. Simus, D.D.S.**

---

**A Thesis in Partial Fulfillment  
of the Requirements for the Degree Master of Science  
in Orthodontics**

---

**June 1993**


SOFT TISSUE CHANGES OF THE LOWER LIP  
FOLLOWING ISOLATED MANDIBULAR  
ADVANCEMENT OSTEOTOMIES


by


Ronald Roy A. Simus D.D.S.


The purpose of this study was to evaluate the soft tissue changes that occur following isolated mandibular advancement surgery. A sample of 70 non-growing patients were examined by tracing pre and post-operative radiographs. Then various landmarks were chosen and hand measured to determine hard and soft tissue changes. Significant correlations were found for many of the horizontal and vertical tissue landmarks and weaker correlations for all other landmarks. The decrease in the interlabial gap and the angular changes in the lower lip reflect the direction of surgical movement. The data from this study supports previous studies of smaller sample sizes and suggests a 1:1 soft to hard tissue ratio for rough clinical prediction in the chin and sublabial area. Reliability tests demonstrate the measurement technique to be accurate.

Each person whose signature appears below certifies that this thesis, in his opinion, is adequate in scope and quality as a thesis for the degree Master of Science.

  
\_\_\_\_\_, Chairman  
Joseph M. Caruso, Chairman, Department of Orthodontics

  
\_\_\_\_\_  
William J. Emmerson, Assistant Professor of Orthodontics

  
\_\_\_\_\_  
M. Toufic Jeiroudi, Program Director of Orthodontics

  
\_\_\_\_\_  
Timothy B. Welch, Department of Oral Surgery

## ACKNOWLEDGEMENTS

I would like to express my sincere appreciation to the following persons:

Dr. G. William Arnett, and his research assistant Nancy Christenson, who allowed us to utilize his office, staff, and patient records.

Dr. Grenneth Zimmerman for her help with the statistical analysis.

Dr. Joseph M. Caruso, Dr. William J. Emmerson, M. Toufic Jeiroudi, and Timothy B. Welch for advice and guidance on the planning and completion of this study.

## TABLE OF CONTENTS

I. Introduction.....	1
II. Materials and methods.....	8
III. Results.....	13
IV. Discussion.....	19
V. Summary.....	26
VI. References.....	28

## INTRODUCTION

As orthodontists, it is important that we have an understanding of surgical techniques along with the possibilities and limitations associated with surgical treatment. In order to establish treatment goals, guidelines are needed to help us in the treatment planning process, and definitive figures needed for accurate cephalometric prediction. Broadbent developed the cephalometer enabling the clinician to view the skeletal and dental characteristics of each patient. Ricketts then studied the anatomical landmarks he felt most beneficial in the study of orthodontics and came up with the Ricketts analysis. As Ricketts<sup>1</sup> then began to study growth prediction he realized that by establishing norms we could create a visual treatment objective and arrive at a definitive plan for treatment.

The importance of soft tissue prediction is apparent. The soft and hard tissues must be related so soft tissue profile can be judged and a determination of facial esthetics be made. Burstone<sup>2</sup> recognized the importance of the relation between soft tissue and its bony support. McNamara's<sup>3</sup> study of one hundred and twenty-five adult patients with what he believed had ideal facial and occlusal relationships supports the notion that there are limitless possibilities when thinking of the ideal face.

It is evident that if an orthodontist wishes to advise a patient on whether or not to pursue surgery, an idea of how the soft tissue

will appear after the procedure is an important problem that needs complete study. Studies have been done like that of Legan and Burstone<sup>4</sup> analyzing soft tissue before surgery. But more information is needed on how tissues will respond post-surgically.

### **MANDIBULAR SURGERY**

Researchers in the 1960's and 1970's discussed ways to correct mandibular discrepancies. Such researchers included Robinson,<sup>5-6</sup> et al, Fromm<sup>7</sup>, Bell and Dann<sup>8</sup>, Lines<sup>9</sup>, and Hershey<sup>10</sup>. In these studies it was found roughly that horizontal soft tissue to hard tissue response was 1:1 in the chin area, and 3:4 in the lower lip relative to the lower incisor, with either retraction or advancement mandibular surgery. There were, however, variations found in some individuals post-surgery.

### **COMBINATION SURGERY**

In many instances it became necessary to involve both the maxilla and the mandible for optimum treatment results. Many studies<sup>11-19</sup> were done in the 1970's and 1980's describing new surgical techniques. Treatments then became very complicated and resulted in greater difficulty in properly diagnosing and treatment planning of surgical cases. In turn a greater challenge arose in the actual orthodontic and surgical treatment, all having an effect on the overlying soft tissue esthetics.



## SOFT TISSUE PREDICTION

In 1957 Ricketts<sup>1</sup> study of growth addressed the notion of facial change accompanying growth both in the hard and soft tissues. It is obvious that we need to address the soft tissues as well as the hard tissues so we can predict how the face will look at the end of treatment. By this study Ricketts developed the VTO or visual treatment objective. However, it was of little use in surgical prediction because at this time not much was known about soft tissue movement relative to surgery.

Shortly thereafter Worms, Isaacson, and Seidel<sup>11</sup> published an article involving the profile analysis used before mandibular surgery. Then Fish and Epker<sup>20</sup> introduced a method for soft tissue prediction using surgical-orthodontic cephalometric prediction tracing. First they positioned the bones in the area they expected the bones to be following surgery. Then the soft tissue of the lips and chin were done according to basic ratios they found manifest in their own patients after surgery. The results of the soft tissue tracing were still left up to the feel of the clinician rather than using a definitive method with specific figures.

Then in 1985 Wolford, Hilliard, and Dugan published a book entitled Surgical Treatment Objective or STO. This book provided tables of ratios on hard and soft tissue change following various different types of surgical procedures. This enabled the clinician to make a prediction based on definitive data from a set table of

figures, thus adding continuity to soft tissue prediction. Proffit and White<sup>21</sup> have very recently released another method for surgical treatment prediction. This study has not yet been published.

Now, the state of the art is the use of computerized treatment prediction, and video imaging systems. These systems are simple to use and very quick to operate. The clinician takes an image of the patient and superimposes a digitized tracing over top of the patients profile. The bony structures can be altered and the computer will alter the soft tissue profile automatically. This enables the clinician to view the surgical change instantaneously and make alterations in treatment in order to arrive at optimal treatment diagnosis.

A draw back of this method is that the data used for the program was compiled from a very small sample and may not be completely accurate especially for significant amounts of surgical correction. The clinician should be careful in showing the patient these images in the event that the surgery may not render the same end results. For this reason it is necessary that we have more research data dedicated to soft tissue changes following orthognathic surgery.

## **PURPOSE**

The purpose of the proposed research study is to further evaluate soft tissue changes that occur after orthognathic surgery. In this present study we limited our interest to the tissue changes

related only to the lower lip after mandibular advancement without genioplasty.

## **OBJECTIVE**

This study was aimed at providing the orthodontist and oral surgeon with data for more accurate prediction of soft-tissue changes after orthodontic and surgical treatment. Lateral cephalometric head films were examined and analyzed. Hopefully, this information will enable us to make more accurate treatment predictions. Furthermore, the data from this study may be utilized for additional research into the treatment and results of mandibular surgery (refer to Tables 1 and 2).

## **NULL HYPOTHESIS**

There are no soft tissue changes of the lower lip following mandibular advancement surgery.

---

**Table 1.** Listing of measured cephalometric landmarks (Refer to Fig. 1)

---

<b>ANS-</b>	Anterior nasal spine.
<b>Columella (Cm)</b>	- The most anterior point on the columella of the nose.
<b>Gnathion (Gn)</b>	- The most anterior inferior point on the chin.
<b>Incision inferius (Ii)</b>	- The incisal edge of the crown of the most anterior mandibular central incisor.
<b>Incision superius (Is)</b>	- The incisal edge of the crown of the most anterior maxillary central incisor.
<b>Infradentale (In)</b>	- The point where the mandibular dental alveolus contacts the labial surface of the mandibular central incisor in the midsagittal plane.
<b>Labrale inferius (Li)</b>	- The most anterior point on the lower lip.
<b>Labrale superius (Ls)</b>	- The most anterior point on the upper lip.
<b>Lower lip mucosa (LLM)</b>	- Point on the lower lip mucosa directly opposite the vermillion border.
<b>Lower lip vermillion (LV)</b>	- The lower most point on the vermillion border of the lower lip.
<b>Menton (Me)</b>	- The most inferior point on the bony chin.
<b>PNS</b>	- Posterior nasal spine.
<b>Pogonion (Po)</b>	- The most anterior point on the bony chin.
<b>Pronasale (Pn)</b>	- The most anterior point on the nose.
<b>Prosthion (Pr)</b>	- The point where the maxillary dental alveolus contacts the labial surface of the maxillary central incisor in the midsagittal plane.
<b>S point (Sp)</b>	- The point at which the curvature of the nasal septum in the midsagittal plane reverses direction.
<b>Soft tissue A (A')</b>	- The point of greatest concavity on the anterior border of the upper lip between subnasale and labrale superius.
<b>Soft tissue B (B')</b>	- The point of greatest concavity on the anterior border of the lower lip between labrale inferius and soft pogonion.
<b>Soft tissue pogonion (Po')</b>	- The most anterior point of the soft tissue chin.
<b>Stomion inferius (Si)</b>	- Most superior point of the lower lip.
<b>Stomion superius (Ss)</b>	- The most inferior point on the vermillion border of the upper lip.
<b>Subnasale (Sn)</b>	- The point at which the nasal septum merges with the upper cutaneous lip in the midsagittal plane.
<b>Subspinale (A)</b>	- The point of greatest concavity on anterior border of the premaxilla between ANS and Pr in the midsagittal plane.
<b>Supramentale (B)</b>	- The deepest point in the midsagittal plane between infradentale and pogonion.
<b>Supra pogonion (Pm)</b>	- The point at which the curvature of the bony chin, in the midsagittal plane between subspinale and pogonion, reverses direction.
<b>Upper incisor apex (UIA)</b>	- Neurovascular opening in the root tip of the maxillary central incisors.
<b>Lower incisor apes (LIA)</b>	- Neurovascular opening in the root tope of the mandibular central incisors.

---

---

**Table 2.** Listing of additional measurements and angles

- Interincisal angle*** - The angle between the long axis of the upper and lower incisor.
- Interlabial gap*** - The distance between stomion superius and stomion inferius.
- Mandibular incisor to mandibular plane angle*** - The angle between the long axis of the lower incisor and the mandibular plane.
- Mandibular plane angle*** - The angle between S-Na and Go-Gn.
- Mandibular sulcus angle*** - The angle of the lower lip between Li-B'-Po'.
- Maxillary incisor to S-Na angle*** - The angle between the long axis of the upper incisor and S-Na.
- Maxillary incisor to palatal plane angle*** - The angle between the long axis of the upper incisor and the palatal plane.
- Maxillary sulcus angle*** - The angle of the upper lip between Sn-A'-Ls.
- Nasal length*** - The distance between columella and subnasale.
- Nasolabial angle*** - The angle between the base of the nose and the upper lip as measured from Cm-Sn-Ls.
- Occlusal plane angle*** - The angle of the occlusal plane to S-Na.
- Overbite*** - The distance between incision superius and incision inferius in a vertical direction.
- Overjet*** - The distance between incision superius and incision inferius in a horizontal direction.
- Palatal plane angle*** - The angle of the palatal plane to S-Na.
- Profile angle*** - The angle measured between G-Sn-Po'. Angles <180° are positive.
- Upper lip to Sn-Po'*** - The distance between labrale superius and a line from Sn to Po'.
- Lower lip to Sn-Po'*** - The distance between labrale inferius and a line from Sn to Po'.
- Upper lip thickness*** - The distance between prosthion and labrale superius.
- Lower lip thickness*** - The distance between lower lip mucosa and lower lip vermillion.
-

## METHODS AND MATERIALS

In this study we investigated the long term soft tissue changes of the lower lip following isolated mandibular advancement surgery. The sample consisted of 70 non-growing patients, all of which have undergone mandibular advancement surgery. The average pre-operative age was 27.6, post-operative 29.7 years, resulting in a 2.1 year average span between radiographs. These cases were randomly selected from the files at the Center for Corrective Jaw Surgery, Santa Barbara, California. All the surgical procedures were performed by either Dr. William Arnett or Dr. James Tamborello. Patient selection was limited to those patients that underwent isolated mandibular advancement surgery.

The records consisted of two lateral cephalometric radiographs for each patient. All the films will be taken with the lips apart posture to avoid any chance of lip strain.<sup>22</sup> The radiographs included immediate pre-surgical film and one post-surgical film taken at least six months after the surgery. An immediate post-surgical radiograph is not necessary in this study because most of the tooth movement has already been accomplished prior to surgery and only minor tooth movements not affecting the soft tissue profile will be made. Also, the inflammation associated with the soft tissues following surgery would mean that the data gained at this point would not be valuable for study. The radiographs used in this study were all taken using the same machine to ensure consistency.

The preoperative and postoperative cephalograms were hand traced by one individual. The hand tracing will allow the evaluation of the lower lip outside that of just numbers. Of these points only, those associated with the soft tissues of the lower lip will be followed. The points are as follows: Pr, Is, Ss, Si, Po', S, Na, LLM, Li, LLS, B, In, Ii, LIA, B, Pn, Po, Gn, And Me (Refer to fig. 1).

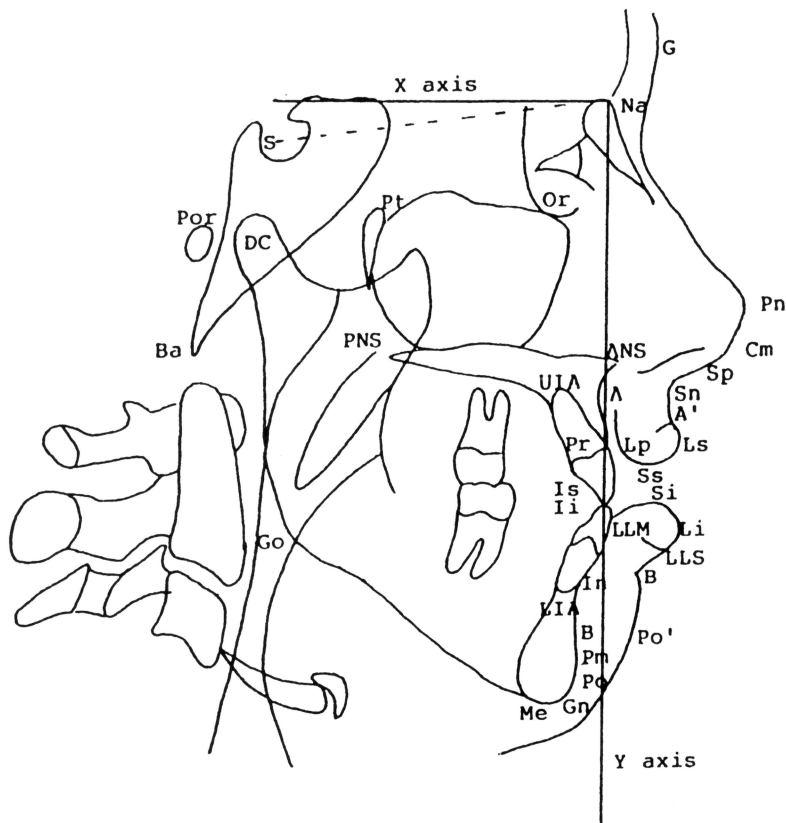


Fig. 1 Cephalometric landmarks and reference planes

From these points the following parameters were evaluated:

<u>Angular</u>	<u>Verticle</u>	<u>Horizontal</u>
Li-B'-Po'	B-B'	LLM-Li
Md 1 to S-Na	B'-Po'	LLM-B'
	Ss-Si	B-Po'
	Li-B	LIA-B'
	Si-B	LIA-Po'
	Po-Li	Ii-Li
	Po-Si	B'-Po'
	Si-II	Li to Pn-Po'

Horizontal and vertical reference lines were constructed in order to accurately evaluate surgery induced changes and have them remain stable throughout all surgical and orthodontic procedures. Bamrind and Franz<sup>25</sup> found two points to be highly reliable in their study. These points will be used relative to the movement of all the other points. The lines will be done as follows: the points Na and S will be traced on all patients. Like Browns<sup>23</sup> study we used a second horizontal line 7 degrees from the first which will be denoted as the axis line. Then we constructed a third vertical line perpendicular to this X axis line denoting the Y axis line. All points located to the right of this line will be given a positive value. All points located to



the left of this line will be given a negative value. In this study all points will be located below the X axis and will be considered positive values. From these lines all points could then be evaluated for change produced solely by the surgical procedure (see Fig. 2).

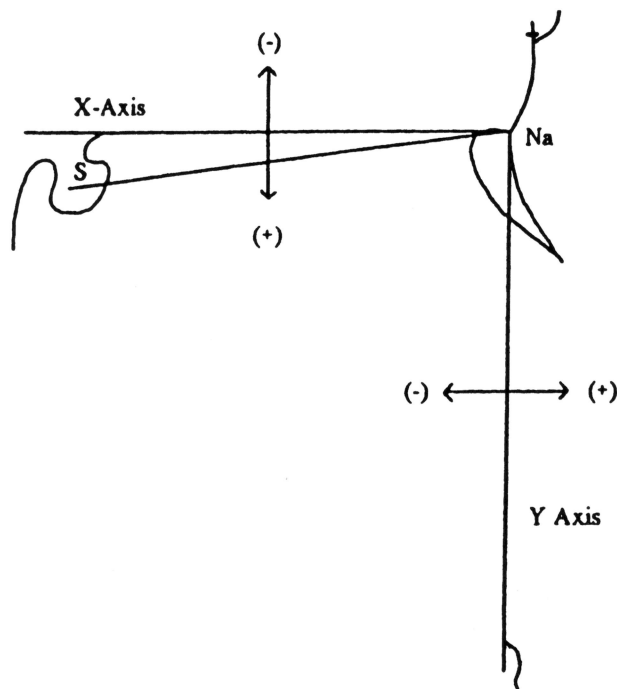


Fig. 2 Value designation for the constructed reference lines

In each case pre-operative cephalogram was traced first and landmarks clearly marked. Then immediately the post-operative cephalogram and tracing acetate were then overlaid on top of the pre-operative tracing and the post-operative landmarks were then identified and marked. The rest of the post-operative tracing was then completed. By this method, theoretically, the reference points

could be identified with greater consistency, and a resultant more accurate tracing, and point identification.

All tracings were done by the one individual, and all points and angles were measured and recorded by this same individual.

Reliability tests were also done in this study to verify the repeatability of the hand measurements. After all 70 cases were hand traced by one individual, the same person hand measured all the variables on both pre-operative (T-1) and post-operative (T-2) cephalograms and recorded them. Then, 15 cases were chosen at random and remeasured a second time. A reliability test (paired t-test) was then used to check the consistency of the measurements recorded by the individual. Any measurement less than 0.05 was considered statistically accurate. By hand tracing and measuring the cephalograms we hope to eliminate any error caused by the computer digitized method of measure.

## RESULTS

Ratios for all tissue movements following isolated mandibular advancements osteotomy procedures are presented in Tables 3-5 along with their correlations and standard error measurements.

In the horizontal direction the mean advancement of the mandible at B-point was about 5.2mm. This mandibular advancement produced a reduction of the interlabial gap an average of 1mm. This interlabial gap reduction, however, was not statistically significant and subject to great individual variability. In Table 3 and Fig. 3, labrale inferioris (Li) was found to follow lower lip mucosa (LLM) in around a 0.65:1 ratio with a very significant degree of correlation ( $p < .001$ ). Other ratios of horizontal tissue movement include soft tissue B (B') to lower lip mucosa (LLM) was approximately 0.95:1, soft tissue pogonion (Po') to supra mentale (B) was around 1.1:1, Incision inferioris (Ii) to labrale inferioris (Li) was .47:1, and soft tissue pogonion (Po') to soft tissue B (B') resulted in around a 0.85:1 ratio, all of which also have a very significant degree of correlation ( $p < .001$ ). Soft tissue pogonion (Po') to lower incisor apices (LIA) showed around a 1.1:1 ratio with of marginal degree of significance of 0.1073.

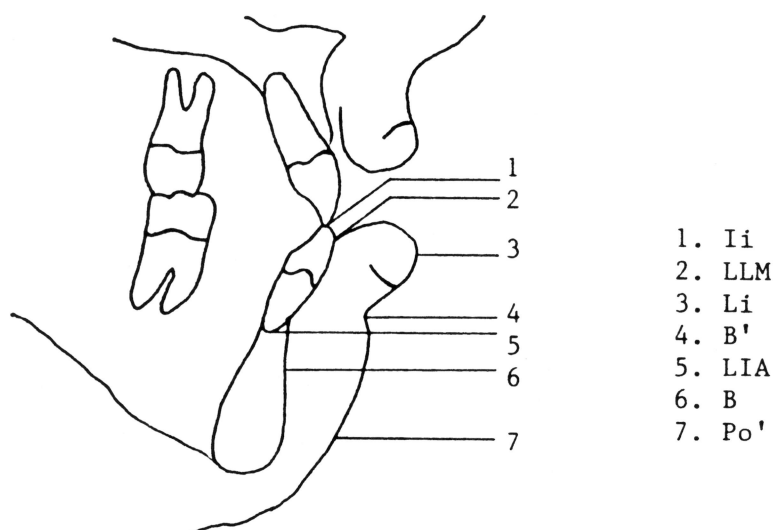
Also in the horizontal direction labrali inferioris (Li) relative to a line drawn between pronasale (Pn) and soft tissue pogonion (Po'), it was found that the lower lip became 2mm more retrusive relative

to the line and labrale inferius (Li) which was very significant ( $p < .001$ ), (refer to Fig. 4).

**Table 3**

Ratios of horizontal tissue movement for mandibular advancements

Ratios Mean Change	Mean	Standard Error	Correlation Coefficient	Significance
LLM:Li	0.643	0.150	0.477	<.001
LLM:B'	0.939	0.211	0.509	<.001
B:Po'	1.284	0.775	0.824	<.001
LIA:Po'	1.129	0.097	0.194	0.107
Ii:Li	0.649	0.190	0.470	<.001
B:Po'	0.854	0.115	0.558	<.001



**Fig. 3** Horizontal hard and soft tissue landmarks

In the vertical direction at soft tissue B (B') to supramentale (B) the ratio was around 0.95:1, soft tissue pogonion (Po') to soft tissue B (B') was approximately 0.85:1, supramentale (B) to stomion inferius (Si) was 0.17:1, incision inferius (Ii) to stomion inferius (Si) was -0.14:1. All four of these ratios were found to be very significant ( $p < .001$ ). Stomion inferius (Si) to pogonion was 0.14:1, supramentle (B) to labrale inferius (Li) was -0.03:1, and labrale inferius (Li) to pogonion was -0.2:1. The significance of these ratios was calculated to be  $p = 0.04$ ,  $0.12$ , and  $0.5$  respectively (refer to Table 4 and Fig. 5).

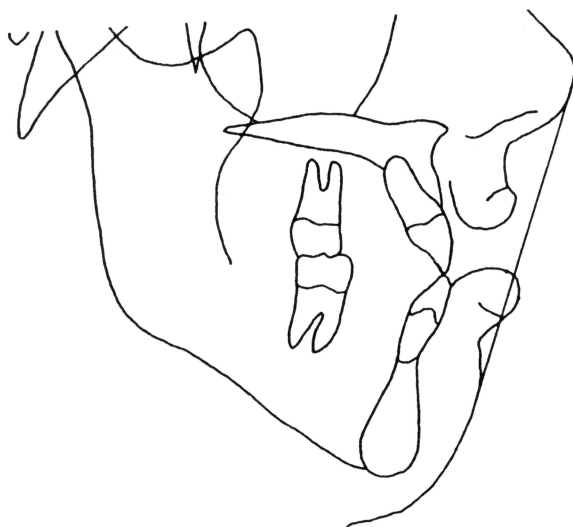

Fig. 4 Lower lip to esthetic plane

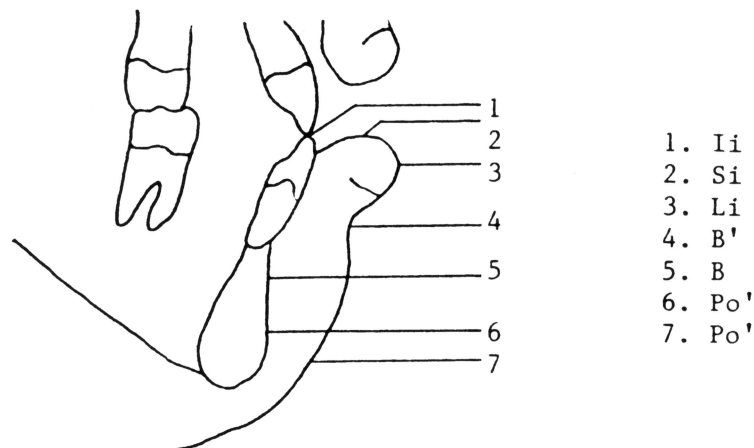
Also, in this study certain angular measurements were taken and these results are recorded in Table 5 (also refer to Fig. 6). It was found that the lower lip to chin (Li-B'-Po') angulation opened about

13 degrees. The mandibular incisor angulation also changed from 51 to about 55 degrees, which means the incisor became four degrees more upright relative to Sella-Nasion.

**Table 4**

Ratios of vertical tissue movement for mandibular advancements

Ratios Mean change	Mean	Standard Error	Correlation Coefficient	Significance
B:B'	0.954	0.220	0.546	<.001
B':Po'	0.854	0.247	0.627	<.001
Li:B	-0.0313	0.328	0.187	0.122
Si:B	0.172	0.384	0.390	<.001
Po:Li	-0.2084	0.255	0.090	0.460
Po:Si	0.141	0.177	0.248	0.039
Si:Ii	-0.136	0.263	0.451	<.001



**Fig. 5** Verticle hard and soft tissue landmarks.

Angular measurements:  
Mandibular advancement surgery  
N=70

Angle	Pre-operative		Postoperative		
	Mean	Std. Deviation	Mean	Std. Deviation	Mean Change
1. Li-B'-Po'	116.1	11.7	129.4	9.8	13.3
2. Md. 1 to S-Na	50.8	7.7	54.8	6.9	3.9

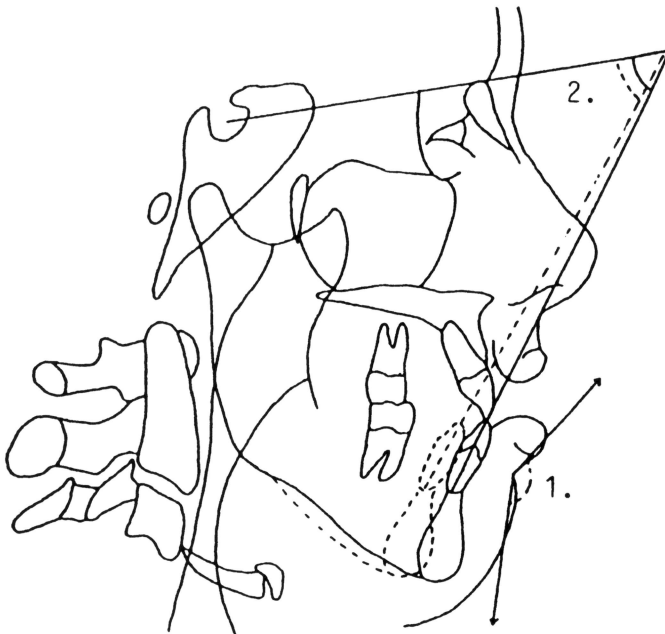


Fig. 6 Angular hard and soft tissue landmarks

A test of reliability was conducted and of all the variables that were measured by doing a repeated measures analysis on 15 cases chosen at random. There was 1 variable shown to have a significant

deviation (  $p \Rightarrow .005$ ) that was measured in the study. This variable was Po', and this deviation was .4mm, which may or may not be labelled clinically significant. The rest of the measurements showed a high degree of reliability (C.V. < .05). The additional points that did show variability were not used in the study (refer to Table 6).

Table 6  
Frequency of measurement variability  
N=15 cases

Range of variability	Frequency	Percentage
C.V. < .01	43	70
.05 > C.V. > .01	16	26
C.V. > .05	3	4
Totals	62	100.0



## DISCUSSION

It is apparent that patients are becoming more dentally aware. They expect us, as orthodontists and oral surgeons, to provide them with detailed information with regards to the expected outcome of treatment. These expectations include the dental results following orthodontic treatment, and the esthetic results for those patients undergoing jaw corrective surgery. Patients want to know before they agree to surgery how they are going to look after the surgery is complete.

By studying an isolated group of mandibular advancement cases we eliminate other surgical variables that other surgeries may introduce into this particular the study. A patient study group of 70 cases is large enough to make adequate determinations on how the soft and hard tissues respond to a given degree of mandibular advancement. We selected a number of anatomical reference points but only certain points were chosen for study. However, the given data may be used for other such projects in the future.

Although the number of cases studied in this paper is high, it must be remembered that individual variation always plays a part in the out come of such studies. Individuals respond differently to surgery, however, it is likely that most of these variations will be compensated for by other results on the other end of the patient pool. In other words we cannot guarantee exact results to our patients, but we can give them a good idea as to the expected results

made in accordance with past experiences with similar patients that presented much like themselves.

## HORIZONTAL MOVEMENT

The horizontal group turned out to be very reliable and significance was very high. All the reference points, except for one, showed significant correlations ( $p < .001$ ) with slight variations in the correlation coefficients ( $r = .047-.082$ ). The one measurement that did show less significance is that of lower incisor apex (LIA) to soft tissue pogonion (Po'), however, showing the lesser amount of standard error (S.E.=0.097) than that of the other horizontal measurements.

When comparing this study to some other studies in the same area there were some similarities in results. Talbot<sup>26</sup> showed there to be a 1:1 hard to soft tissue movement of inferior labial sulcus (B point) to soft tissue pogonion (Po') and hard tissue pogonion vectors. Similarly we found a nearly 1:1 ratio of inferior labial sulcus to soft tissue pogonion.

Lines and Steinhauser found that the lower incisal edge (Ii) to labrale inferioris (Li) changed in the horizontal direction by a 0.677/1mm ratio<sup>9</sup>. We found this same change of lower incisor edge to labrale inferioris to be 0.649/1, which shows great similarity in results. Lines and Steinhauser found basically a 1:1 soft tissue to hard tissue pogonion (Po/Po') vector in the chin area. Similarly we found supramentale (B point) to soft tissue pogonion (Po'), and

lower incisor apes (LIA) to soft tissue pogonion (Po') to be a nearly 1:1 ratio. This clearly demonstrates a 1:1 relationship between the soft and hard tissue landmarks of the lower chin and sublabial area.

Associated soft tissue changes of soft tissue B (B') to soft tissue pogonion (Po'), lower lip mucosa (LLM) to soft tissue B (B'), and lower lip mucosa (LLM) to labrale inferius (Li) shows a similarity in the degree of soft tissue change associated with mandibular advancement. However, one point is worth mentioning. It seems that the more inferior the soft tissue structure is, the greater amount of horizontal change is evident relative to the hard tissue structure. This may be due to the fact that the more inferior soft tissue structures at the chin area are contiguous with the mandibular hard tissue support directly joined by connective tissue and periosteum, whereas the lip has a lingual mucosal surface that is freely movable.

## **VERTICLE MOVEMENT**

The vertical movement group showed a lesser degree of significance than the horizontal group but a relatively consistent degree of standard error (S.E.=0.18-0.38). This difference in significance may be a result of individual variation within the group.

The changes at hard to soft tissue supramentale (B:B') were significant at a close to 1:1 ratio. This is to be expected because there is a periosteal interface between these two points more or less joining them together, and resulting in the soft tissue

mimicking the movements of the underlying hard tissue because of their close vertical relationship. In contrast hard and soft tissue landmarks that are farther from each other in a vertical dimension show less similarity in the amount of associated vertical change. For example Stomion inferius (Si) to supramentale (B) has a 0.017:1 relationship, demonstrating that there is a difference in the amount of vertical change between the two landmarks when doing a mandibular advancement osteotomy.

This is also true for the lower incisor tip (Ii) with respect to the stomion inferius (Si). Both structures are associated with the movement and change of the mandible, but in a vertical direction the lower lip is probably more influenced by the mandibular hard tissues than the incisor. The lower incisor could be intruded or extruded during orthodontics for leveling with little to no relative change in a vertical dimension of the soft tissue.

Comparing relative movement of two soft tissue landmarks soft tissue B (B') and soft tissue pogonion (Po') there was a 0.85:1 relationship. There was less vertical change in soft tissue B than there was in soft tissue pogonion. Again, as in the horizontal direction, there may be a relationship between the vertical position of the landmark relative to the superior structures that are not being directly changed in position as a result of surgery due to their underlying support.

## ANGULAR MEASUREMENTS

There were two angular measurements calculated in this study. The first related to the lower lip to chin soft tissue angulation (LI-B-Po') opened up from 116 degrees to 129 degrees is indicative of an improvement in the lower lip eversion and inability to create a proper oral seal pre-surgically. Then post-surgically the advancement of the mandible bring the soft tissue forward into harmony with the upper lip eliminating some of the sublabial contracture.

The other angular change was manifest in the angulation of the lower incisor relative to Sella-Nasion which from 51 degrees pre-operatively to 55 degrees post-operatively. This change in incisor angulation is probably due to the auto-rotation of the mandible that occurs in the advancement procedure. Also, a number of mandibular advancement cases have an associated open-bite component that also allows for extra auto-rotation in the surgical correction of the class II skeleton (refer to fig. 6).

This may also be a result of either deliberate orthodontic uprighting, or physiologic uprighting due to equilibration of physiological forces more harmonious with normal function. This harmony may include less tongue pressure forcing the incisor forward because there is more space for the tongue. Also, more pressure lingually by the lower lip because of its increased lower lip angulation and the contact with upper incisor teeth may also

have had an effect. It is likely that it is a combination of both orthodontic and physiologic forces.

### **COMPOSITE PATIENT**

In order to represent the collective movement of the patients measured in this study a composite was created based on the collective ratios taken in the horizontal and vertical directions. The mean advancement at B pt. was used to calculate the bony change in a horizontal direction, and B pt. was also used in a vertical dimension to represent vertical hard tissue change. The soft tissue was manipulated according to the data found in this study. One can see from the drawing that the general movement of the lower jaw is in a forward direction. There is more soft tissue advancement in the forward plane in the chin and sublabial area than in the lower lip. The lower incisor uprights, and the interlabial gap decreases. Generally there is smoother and more pleasing lower lip to chin soft tissue contour, with less relative lower lip eversion (see Fig. 7).

### **RELIABILITY TESTS**

The repeated measures test conducted on 15 randomly selected cases were conducted in order to insure that there was accuracy in the measurement technique, and consistency in the operators methods. The results of the reliability tests supported the high degree of accuracy in the measurement of these 70 cases. Bamrind and Franz<sup>25</sup> showed hand tracing to be highly accurate. Also, by

tracing the pre-operative and post-operative radiographs in succession and overlaying the two radiographs when locating the reference landmarks also insures a greater degree of consistency for the reference plane. However, soft tissue pogonion (Po') showed the most variability from pre to post surgical measurement demonstrating that this point (Po') may not be a good reference point for future study.

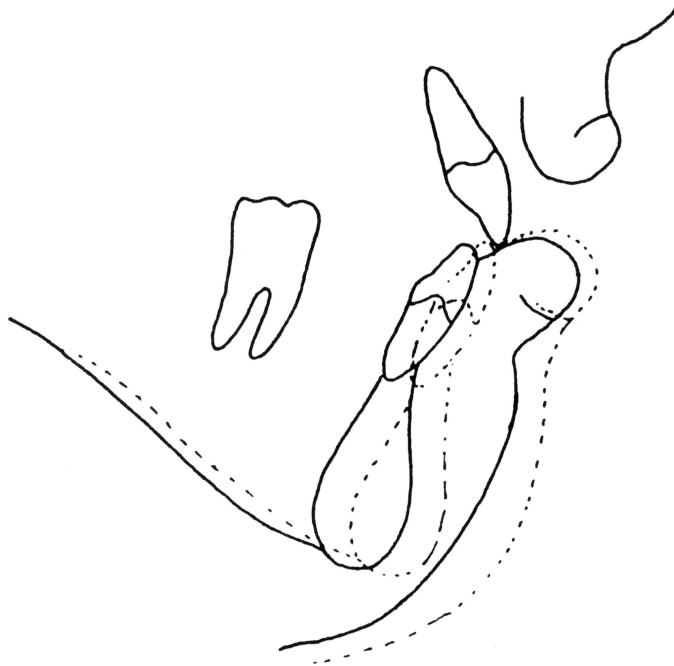


Fig. 7 Composite patient profile showing mean hard and soft tissue change

## SUMMARY

In this study seventy patients that had mandibular advancement osteotomies were studied. In each case a pre-surgical and post-surgical radiograph was traced, and then certain anatomical landmarks were located and recorded. This enabled us to establish a data base that we could draw from in our study. The calculations on our data base was done on computer to evaluate certain hard and soft tissue landmarks. Ratios were established for the horizontal and vertical measurements, angular measurements were compared, and a linear horizontal measurement was also done. The following conclusions were made from the data collected:

- 1) Significant correlations existed for certain vertical and horizontal tissue ratios. These include LLM:Li, LLM:B', B:Po' Ii:Li, and B':Po' in the horizontal direction and B:B', B':Po', Si:B, and Si:Ii in the vertical direction.
- 2) Weaker correlations existed for all other movements in the horizontal and vertical dimension.
- 3) The interlabial gap was seen to decrease following mandibular advancement surgery.
- 4) Angular changes to the lower lip and chin reflect the type and direction of surgical movement.
- 5) Angular changes in the lower incisor reflect post-surgical orthodontic movement, and auto-rotational change as a result of surgical correction of both mandibular retrognathia and open-bite correction.



- 6) Linear change in the lower lip is indicative of the degree and direction of the surgical correction.
- 7) Reliability tests demonstrated that the measurement technique was accurate (96% C.V. <.05).
- 8) The statistical deviation is most likely the result of individual variation amongst the sample.
- 9) From the data it is fair to say that a surgeon or an orthodontist could extrapolate a visual treatment objective with relative accuracy using standard 1:1 soft to hard tissue relations for rough clinical predictions. By the same token a pre-surgical cephalogram could be used to do a post-surgical VTO.
- 10) The data from this study supports previous studies of smaller sample sizes, so the need to do studies with larger sample sizes is not necessary.
- 11) As professionals, it should be noted that this type of research gives us perimeters from which we can better predict the treatment results of our patients. However, it must be remembered that there is a certain degree of individual variation both in the surgical technique and skill of the surgeon, and the individual response of the patient to surgery.

## REFERENCES

1. Ricketts, R.M.: Planning treatment on the basis of the facial pattern and an estimate of growth, part 1, Angle Orthod. 1957; 27:14
2. Burstone, C.J.: Integumental Profile, AM J Orthod 1959;44:1-25
3. McNamara, J.A., Ellis, E.: Cephalometric analysis of untreated adults with ideal facial and occlusal relationships. Internat J of Adult Orthod 1988;3:284.
4. Legan, H.L., Burstone, C.J.: Soft tissue cephalometric analysis for orthognathic surgery, J Oral Surgery 1980;38:744-751
5. Robinson, W.W., Speidel, T.M., Isaacson, R.J. , Worms,T.W.: Soft tissue profile changes produced by reduction of mandibular prognathism. Angle Orthod 1971;41:227
6. Robinson, W.W. et al: Soft tissue profile change produced by reduction of mandibular prognathism. Angle Orthod. 1972;42:227
7. Fromm, B., Lundberg ,M.: The soft tissue profile before and after surgical correction of mandibular protrusion. Acta Orthod Scand 1972;28:157
8. Bell, W.H., Dann ,J.J.: Correction of dentofacial deformities by surgery in the anterior part of the jaws: a study of stability and soft tissue changes. Am J Orthod 1973;64:162
9. Lines, P.A., Steinhauser , E.W.,: Soft tissue changes in relation to movement of hard structures in orthodontic surgery: A preliminary report. J Oral Surgery 1974;32:891

10. Hershey, H.J., Smith, J.H.: Soft tissue profile change associated with surgical correction of the prognathic mandible. *Am J Orthod.* 1974;65:483
11. Worms, F. W.: Surgical orthodontic treatment plan: Profile analysis and mandibular surgery, *Angle Orthod.* 1976; 46: 1-25
12. Epker, B.N., Fish, L.C.: The surgical-orthodontic correction of class III skeletal open-bite. *Am J Orthod.* 1978;73:601
13. Epker, B.N., Fish, L.C.: Surgical-orthodontic correction of vertical maxillary excess. *Am J. Orthod* 1978;73:241
14. Bell, W.H., Jacobs, J.D.: Combined orthodontic-surgical correction of moderate mandibular deficiency. *Am J Orthod* 1979;75:481
15. Engle, G.S., Quan, R.E., Chaconas, S.J.: Soft-tissue change as a result of maxillary surgery: A preliminary report. *Am J Orthod* 1979;75:291
16. Bell, W.H., Proffit, W.R., and White, R.P.: Surgical correction of dentofacial deformities. Philadelphia, 1980, W.B. Saunders Co.
17. Radney, L.J., Jacobs, J.D.: Soft-tissue changes associated with surgical total maxillary intrusion. *Am J Ortho* 1981;80:191
18. Bell, W., Jacobs, J., Quejada, J.: Simultaneously repositioning of the maxilla, mandible, and chin. Treatment planning and analysis of soft tissues. *Am J Orthod* 1986;89:28
19. Epker, B.N., Fish, L.C.: Dentofacial deformities: Integrated orthodontic and surgical correction, Philadelphia, 1986, the C.V. Mosby Co.

20. Fish, L.C., Epker, B.N.: Surgical-orthodontic cephalometric prediction tracing. *Am J Orthod* 1980;14:36
21. Proffit, W.R., White, R.P.: Surgical-orthodontic treatment, St. Louis, 1991, Mosby Year Book, Inc.
22. Burstone, C.J.: Lip posture and its significance in treatment planning. *Am J Orthod* 1967;53:262
23. Brown, Douglas M.: Cephalometric analysis of soft tissue profile change associated with orthodontic and orthognathic surgery: a long term study. Unpublished thesis. Loma Linda University 1991
24. Steuer, I.: The cranial base for superimposition of lateral cephalometric radiographs. *Am J Orthod* 1972;61:493
25. Bamrind, S., Franz, R.C.: The reliability of headfilm measurements, 1. Landmark identification. *Am J Orthod* 1971;60:111.
26. Talbot, J.P.: Soft tissue response to mandibular advancement surgery, thesis for master of science in dentistry degree, University of Kentucky, 1975.