

University of Groningen

Dupilumab in a child with severe atopic dermatitis and severe asthma

Poelhekkens, Mila; Rosenberg, Fieke M.; Oldhoff, Jantje M.; Romeijn, Geertruida L.E.; Wijdh, Robert H.J.; Bocca-Tjeertes, Inger F.A.; Schuttelaar, Marie L.A.

Published in:
International journal of dermatology

DOI:
[10.1111/ijd.16259](https://doi.org/10.1111/ijd.16259)

IMPORTANT NOTE: You are advised to consult the publisher's version (publisher's PDF) if you wish to cite from it. Please check the document version below.

Document Version
Publisher's PDF, also known as Version of record

Publication date:
2022

[Link to publication in University of Groningen/UMCG research database](#)

Citation for published version (APA):

Poelhekkens, M., Rosenberg, F. M., Oldhoff, J. M., Romeijn, G. L. E., Wijdh, R. H. J., Bocca-Tjeertes, I. F. A., & Schuttelaar, M. L. A. (2022). Dupilumab in a child with severe atopic dermatitis and severe asthma: a rare case with severe limbic and exercise-induced anaphylaxis. *International journal of dermatology*, 61(10), e400-e401. <https://doi.org/10.1111/ijd.16259>

Copyright

Other than for strictly personal use, it is not permitted to download or to forward/distribute the text or part of it without the consent of the author(s) and/or copyright holder(s), unless the work is under an open content license (like Creative Commons).

The publication may also be distributed here under the terms of Article 25fa of the Dutch Copyright Act, indicated by the "Taverne" license. More information can be found on the University of Groningen website: <https://www.rug.nl/library/open-access/self-archiving-pure/taverne-amendment>.

Take-down policy

If you believe that this document breaches copyright please contact us providing details, and we will remove access to the work immediately and investigate your claim.

Downloaded from the University of Groningen/UMCG research database (Pure): <http://www.rug.nl/research/portal>. For technical reasons the number of authors shown on this cover page is limited to 10 maximum.

Correspondence

Dupilumab in a child with severe atopic dermatitis and severe asthma—a rare case with severe limbitis and exercise-induced anaphylaxis

Dear Editor,

Dupilumab is a safe and effective treatment in children from 6 to 11 years old with severe atopic dermatitis (AD), which is insufficiently controlled with topical therapy.¹ We present a child with severe AD and atopic comorbidities who showed rapid improvement of AD under dupilumab treatment. However, he developed limbitis, hypereosinophilia, and anaphylaxis. This case report shows it is essential to monitor severe atopic children who are treated with dupilumab for conjunctivitis and eosinophilia.

An 11-year-old boy with severe refractory AD started dupilumab treatment. He suffered from multiple atopic comorbidities, including food allergies with anaphylaxis to cow's milk protein and peanuts, moderate to severe allergic asthma, and allergic rhinitis, treated with beclomethasone/formoterol, ciclesonide, montelukast, antihistamines, azelastine-fluticasone, as well as prednisolone during exacerbations.

After 4 weeks of dupilumab treatment, the Eczema Area and Severity Index (EASI) score improved significantly from 28 to 0.5, and lung function showed an improvement of the Forced Expiratory Volume (FEV1) of 7% pre- and post-bronchial dilatation. After 8 weeks, the patient developed mild conjunctivitis and eosinophilia of $2.66 \times 10^9/L$ (normal: $0.05\text{--}0.50 \times 10^9/L$). Therefore, the next dupilumab administration was postponed for 2 weeks, after which the eosinophil count decreased ($2.02 \times 10^9/L$). The conjunctivitis was treated with dexamethasone eye drops. However, after the dupilumab administration, the eosinophil count increased again to a level of $2.92 \times 10^9/L$, and the patient developed oral allergies as well as urticaria to food products normally tolerated: bread, strawberries, apples, mandarins, and potatoes. Moreover, he developed severe palpebral and bulbar conjunctivitis with limbitis in both eyes, without limbal stem cell deficiency (Fig. 1). Given the severity of the limbitis, dupilumab was discontinued after 20 weeks. Notably, after discontinuation, the allergic symptoms did not resolve. Three weeks after the discontinuation of dupilumab, the patient had an anaphylactic reaction with generalized urticaria, angioedema, and wheezing after biking to school during the pollen season, which the patient does regularly without complaints. He was treated with intramuscular adrenaline and intravenous clemastin and hydrocortisone after which the eosinophils dropped to $1.14 \times 10^9/L$. Simultaneously, the new oral allergies resolved.

Our patient developed eosinophilia with oral allergies and urticaria to food previously tolerated under dupilumab

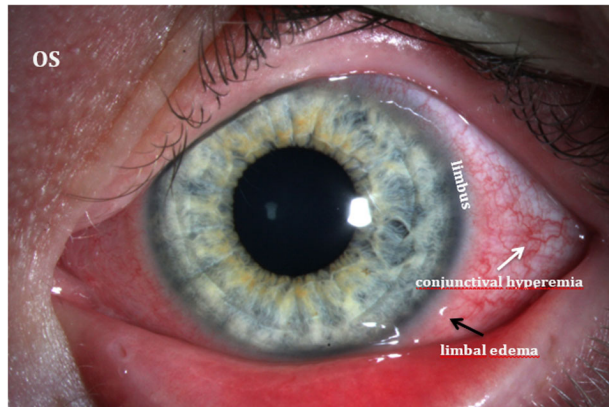


Figure 1 The eye of the patient with limbal edema visualized. This figure shows the left eye of the patient. The limbus is specified, the conjunctival hyperemia is indicated with the white arrow and limbal edema with the black arrow

treatment. Transient eosinophilia was seen in previous trials in AD, asthma, and chronic sinusitis patients.² A possible explanation is the blockage of IL-4 and IL-13-induced migration of eosinophils from serum to tissue, with accumulation in the serum as a result.² It has been suggested that eosinophilia is associated with elevated IgE, mast cell, and basophil levels, which play an important role in allergic reactions.³ Exercise-induced IgE-mediated anaphylaxis is well known, especially in wheat.⁴ In our patient, there was no relation with food intake but there was with exposure to pollen. Given the associations with eosinophilia and mediators that play an important role in allergic reactions, the hypereosinophilia induced by dupilumab may have caused hypersensitivity to food products and eventually caused an IgE-mediated exercise-induced anaphylaxis triggered by pollen.

Furthermore, our patient developed severe conjunctivitis with limbitis. Conjunctivitis is the most common side effect of dupilumab and is mostly mild.¹ Severe eye symptoms, like limbal involvement, are described in adults but not yet in children.¹ However, it is essential to recognize conjunctivitis with limbal involvement early, since it can lead to limbal stem cell deficiency, which can lead to permanent visual loss.⁵

In conclusion, although dupilumab is a very effective treatment for AD, it is essential to monitor severe atopic children for eosinophilia with possible associated symptoms. Furthermore, early recognition of conjunctivitis is essential to prevent limbal involvement and to ensure intervention.

2 Correspondence

Mila Poelheken¹, MD
Fieke M. Rosenberg¹, MD
Jantje M. Oldhof¹, MD, PhD
Geertruida L. E. Romeijn¹, BSc
Robert H. J. Wijdh^{1,2}, MD
Inger F. A. Bocca-Tjeertes³, MD, PhD
Marie L. A. Schuttelaar^{1*}, MD, PhD

¹Department of Dermatology, University Medical Center Groningen, University of Groningen, Groningen, The Netherlands

²Department of Ophthalmology, University Medical Center Groningen, University of Groningen, Groningen, The Netherlands

³Department of Pediatric Pulmonology and Allergology, University Medical Center Groningen, University of Groningen, Groningen, The Netherlands
*E-mail: m.l.a.schuttelaar@umcg.nl

Funding source: None.

Conflict of interest: The authors have no conflict of interest to declare.

doi: 10.1111/ijd.16259

References

- 1 Paller AS, Siegfried EC, Thaçi D, *et al.* Efficacy and safety of dupilumab with concomitant topical corticosteroids in children 6 to 11 years old with severe atopic dermatitis: a randomized, double-blinded, placebo-controlled phase 3 trial [published correction appears in *J Am Acad Dermatol*. 2021 Jan;84(1):230]. *J Am Acad Dermatol* 2020; **83**(5): 1282–1293.
- 2 Wollenberg A, Beck LA, Blauvelt A, *et al.* Laboratory safety of dupilumab in moderate-to-severe atopic dermatitis: results from three phase III trials (LIBERTY AD SOLO 1, LIBERTY AD SOLO 2, LIBERTY AD CHRONOS). *Br J Dermatol* 2020; **182**(5): 1120–1135.
- 3 Leiferman KM, Peters MS. Eosinophil-related disease and the skin. *J Allergy Clin Immunol Pract* 2018; **6**(5): 1462–1482.e6.
- 4 Giannetti MP. Exercise-induced anaphylaxis: literature review and recent updates. *Curr Allergy Asthma Rep* 2018; **18**(12): 72.
- 5 Mehta U, Farid M. Dupilumab induced limbal stem cell deficiency. *Int Med Case Rep J* 2021; **14**: 275–278.