



# Fishhook Ingestion by the Red-eared Slider, *Trachemys scripta elegans* (Wied 1839), in the Pecos River, New Mexico, USA

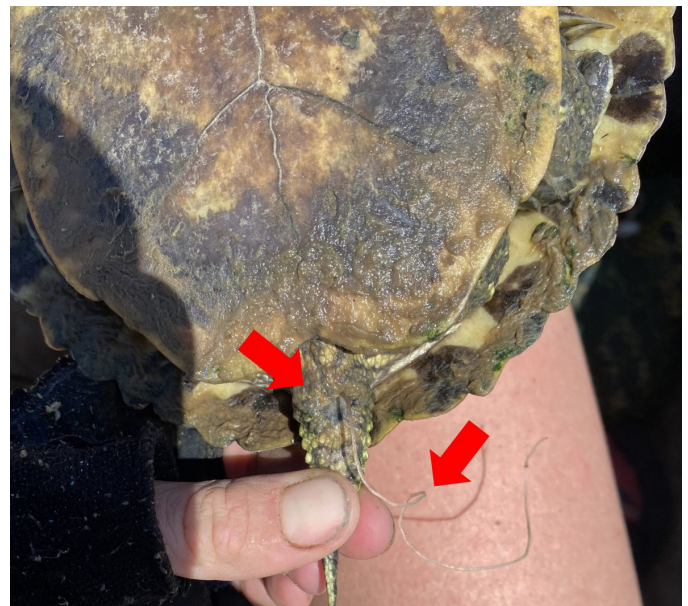
Laramie B. Mahan, Sierra N. Shoemaker, and Ivana Mali

Department of Biology, Eastern New Mexico University, Portales, New Mexico 88130, USA (laramiebmaahan@gmail.com)

The Red-eared Slider (*Trachemys scripta elegans*; Wied 1839) is a medium-sized freshwater emydid turtle native to certain portions of the Midwest, Southeast, and Southwest (i.e., eastern New Mexico and Texas) United States of America (USA) and Northeast Mexico (Ernst and Lovich 2009). This turtle is considered one of the top 100 most invasive species in the world (Lowe et al. 2000), and introductions have allowed this species to spread throughout all original 48 states and Hawaii in the USA, and to all continents excluding Antarctica (Lowe et al. 2000; Ernst and Lovich, 2009). As a generalist species, *T. s. elegans* is globally listed as a species of least concern (van Dijk et al. 2011). The species is omnivorous, with an opportunistic diet of various plant and animal matter (Degenhardt et al. 1996; Ernst and Lovich 2009). Like many freshwater turtle species, *T. s. elegans* are opportunistic scavengers, making them more susceptible to bycatch due to recreational and/or commercial fishing (Steen et al. 2014).

Fishhook ingestion by turtles has been documented for both freshwater and marine species (Valente et al. 2007; Steen et al. 2014; Swimmer et al. 2014; Steen and Robinson 2017; Browne et al. 2020; Vecchioni et al. 2020). However, there is little information available about the extent to which accidental bycatch impacts turtle populations and survival rates (Browne et al. 2020), or how such injuries could affect the reproductive success of adult females. Steen and Robinson (2017) indicate that recreational fishing can result in negative pressures on freshwater turtle populations in the USA, with species- and population-specific mortality rates of turtles ranging from 1–11%. In areas where recreational fishing is common, bycatch and fishhook ingestion may be a source of additive mortality, cumulatively contributing to deaths (both anthropogenic and natural [e.g., consumption by native predators, extreme weather conditions, bacterial infection, age, etc.; Brooks et al. 1990]) and subsequently leading to population declines (Hyland 2002; Steen and Robinson 2017; Browne et al. 2020). When ingested, fishhooks can perforate

portions of the gastrointestinal tract of turtles, resulting in various consequences including cellulitis, peritonitis, stricture formations, and tearing (Hyland 2002; Valente et al. 2007; Di Bello et al. 2013). Fishhook injuries in freshwater turtle species including *T. s. elegans*, Spiny Softshell Turtles (*Apalone spinifer emoryi*) and the state-threatened Rio Grande Cooter (*Pseudemys gorzugi*) have been documented on tributaries of the lower Pecos River in New Mexico, USA (Waldon et al. 2017; Suriyamongkol et al. 2019; Mahan et al. 2020). The lower Pecos River system is one of the most anthropogenically altered rivers in the USA (Jensen et al. 2006), with several studies attributing declines of fish and mussel populations to profound anthropogenic changes (e.g., dam construction, channelization, irrigation, etc.; Linam and Kleinsasser 1996; Cheek and Taylor 2015; Randklev et al. 2018). The increased



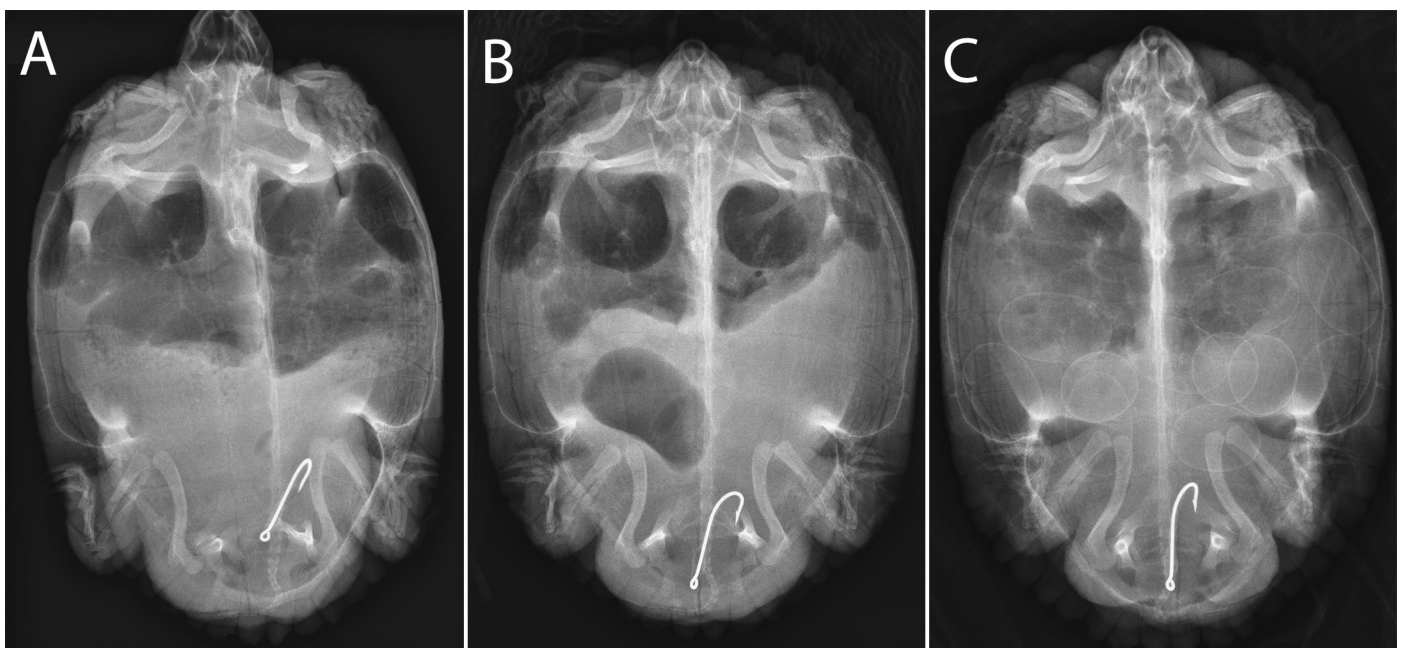
**Fig. 1.** Fishing line protruding from the cloaca of an adult female Red-eared Slider (*Trachemys scripta elegans*) captured via hoop-net trap on 20 May 2021 on the Pecos River in Eddy County, New Mexico, USA. Photograph by Laramie B. Mahan.

prevalence of these recreationally-caused injuries coupled with significant alterations along this river system could pose serious threats to the freshwater turtle populations in this region.

On 20 May 2021, we surveyed for freshwater turtles along a 680-m stretch of the Pecos River in Eddy County, New Mexico (32.40785°N, -104.17969°W; WGS 84). For each hard-shelled turtle captured, we took standard measurements following method D in Iverson and Lewis (2018): mass (g), carapace length (CL), carapace width (CW), plastron length (PL), plastron width (PW), and body depth (BD). During the survey, we captured an adult female *T. s. elegans* (CL 223 mm) with a fishing line protruding from the cloaca (Fig. 1). Upon taking measurements, the turtle was given a unique marking number (Cagle 1939) using a Dremel® 8200 cordless rotary tool (Robert Bosch Tool Corporation, Racine, WI, USA). The turtle was then transported to Desert Willow Wildlife Rehabilitation Center in Carlsbad, New Mexico, USA for dorsoventral radiograph imaging to determine the position of the fishhook. The X-ray revealed that the fishhook had traveled through the gastrointestinal tract (Fig. 2A). Due to the position of the fishhook, it was determined that a safe surgical removal was unlikely, so the turtle remained at the facility for weekly monitoring. On 27 May 2021, a new X-ray showed the fishhook had traveled further down towards the cloaca (Fig. 2B), but the hook remained in an unsafe position for extraction. On 28 June 2021, more radiograph imagery revealed the position of the fishhook had not changed, but the turtle contained approximately 11 shelled eggs (Fig.

2C). The turtle was then placed in a plastic children's pool filled with water and sand, so the progress of egg development could be continuously monitored. On 9 August 2021, the turtle deposited approximately 7 eggs into the pool. All but one of these eggs were crushed, and the single intact egg was transported to an incubator. It is unknown whether the unviable eggs were crushed in the pool or during deposition. The remaining four eggs were deposited on 24 August 2021, two of which had soft indentations, one was cracked, and one was intact. The intact egg was also placed into the incubator. Final X-rays revealed no additional eggs, and the turtle was released into a pond at the facility for permanent monitoring. Both of the eggs placed into the incubator eventually proved to be non-viable and were discarded.

Freshwater turtles are amongst the most threatened vertebrate taxa (Lovich et al. 2018) and are particularly vulnerable to declines given their long-lived and slow-maturing nature (Browne et al. 2020). Fishhook ingestion by turtles could potentially be a source of additive mortality and may contribute to population declines (Hyland 2002; Steen and Robinson 2017). Fishhook ingestion resulting in hook movement into the lower digestive tract has been documented in sea turtles (Valente et al. 2007; Di Bello et al. 2013; Swimmer et al. 2014) and the ingestion of monofilament fishing line has been reported for Snapping Turtles (*Chelydra serpentina*; Borkowski 1997). Turtles with ingested fishhooks attached to monofilament line protruding from the cloaca or mouth have lower chances of survival than injuries where only the hook is present (Franchini et al. 2018). Moreover, while the mono-



**Fig. 2.** (A) Dorsoventral radiograph image of a fishhook lodged in the body cavity of a Red-eared Slider (*Trachemys scripta elegans*) captured on 20 May 2021 in the Pecos River, Eddy County, New Mexico USA; (B) dorsoventral radiograph image showing the progress of the fishhook through the cloaca of the Red-eared Slider one week after capture; (C) dorsoventral radiograph image of an adult female Red-eared Slider (*Trachemys scripta elegans*) that ingested a fishhook and which containing approximately 11 shelled eggs. Images provided by Desert Willow Wildlife Rehabilitation Center.



filament line will pass through the digestive tract and exit the cloaca, the hook may become lodged, potentially piercing the intestinal wall or the stomach of the turtle (Di Bello et al. 2013). To the best of our knowledge, this is the first report of *T. s. elegans* depositing eggs with this type of fishhook injury. Though the turtle appears to be active and relatively unharmed, there is cause for concern given the condition of the deposited eggs. However, observing the deposition of eggs may help determine if the eggs are being damaged at the time of expulsion. At this time, there is no evidence of damage to the specimen's digestive tract, however, there is a threat of perforation if hook movement persists. Research is needed to assess how the successful passage of eggs through the cloaca, given the fishhook prevalence, may affect egg viability. Further monitoring of this turtle will also help determine how this type of fishhook injury will affect long-term health.

### Acknowledgements

We thank Dr. Samantha R. Uhrig and Desert Willow Wildlife Rehabilitation Center in Carlsbad, New Mexico, USA, for the radiograph images and patient records of the turtle; and private landowners for river access. We also thank the National Fish and Wildlife Fund and New Mexico Water Resources Research Institute for funding. Field work was conducted in compliance with New Mexico Department of Game and Fish Scientific Research Permit (#3621). Research was also approved by the Eastern New Mexico University Institutional Animal Care and Use Committee (2019-0226-01A1).

### Literature Cited

- Borkowski, R. 1997. Lead poisoning and intestinal perforations in a snapping turtle (*Chelydra serpentina*) due to fishing gear ingestion. *Journal of Zoo and Wildlife Medicine* 28: 109–113.
- Brooks, R.J., G.P. Brown, and D.A. Galbraith. 1990. Effects of a sudden increase in natural mortality of adults on a population of the common snapping turtle (*Chelydra serpentina*). *Canadian Journal of Zoology* 69: 1314–1320. <https://doi.org/10.1139/z91-185>.
- Browne, C.L., S.A. Sullivan, and D.F. McAlpine. 2020. Freshwater turtle by-catch from angling in New Brunswick, Canada. *The Canadian Field-Naturalist* 134: 222–230. <https://doi.org/10.22621/cfn.v134i3.2437>.
- Cagle, F.R. 1939. A system of marking turtles for future identification. *Copeia* 1939: 170–173.
- Cheek, C.A. and C.M. Taylor. 2015. Salinity and geomorphology drive long-term changes to local and regional fish assemblage attributes in the lower Pecos River, Texas. *Ecology of Freshwater Fish* 25: 340–351. <https://doi.org/10.1111/eff.12214>.
- Degenhardt, W.G., C.W. Painter, and A.H. Price. 1996. *Amphibians and Reptiles of New Mexico*. 1st ed. University of New Mexico Press.
- Di Bello, A., C. Valastro, D. Freggi, O.R. Lai, G. Crescenzo, and D. Franchini. 2013. Surgical treatment of injuries caused by fishing gear in the intracoelomic digestive tract of sea turtles. *Diseases of Aquatic Organisms* 106: 93–102. <https://doi.org/10.3354/dao02641>.
- Ernst, C.H. and J.E. Lovich. 2009. *Turtles of the United States and Canada*. Second Edition. The Johns Hopkins University Press, Baltimore, Maryland, USA.
- Franchini, D., C. Valastro, S. Ciccarelli, F. Caprio, D. Lenoci, and A. Di Bello. 2018. Ultrasonic detection of ingested fishing lines in loggerheads (*Caretta caretta*). *Journal of Wildlife Diseases* 54: 680–690. <https://doi.org/10.7589/2017-12-302>.
- Hyland, R.J. 2002. Surgical removal of a fish hook from the oesophagus of a turtle. *Australian Veterinary Journal* 80: 54–56. <https://doi.org/10.1111/j.1751-0813.2002.tb12047.x>.
- Iverson, J.B. and E.L. Lewis. 2018. How to measure a turtle. *Herpetological Review* 49: 453–460.
- Jensen, R., W. Hatler, M. Mecke, C. Hart. 2006. The influences of human activities on the water of the Pecos River Basin of Texas: a brief overview. Technical Report SR-2006-03. Texas Water Resources Institute.
- Linam, G.W. and L.J. Kleinsasser. 1996. Relationship between fishes and water quality in the Pecos River, Texas. Report No. 9. Texas Parks and Wildlife Department.
- Lovich, J.E., J.R. Ennen, M. Agha, and J.W. Gibbons. 2018. Where have all the turtles gone, and why does it matter? *BioScience* 68: 771–781. <https://doi.org/10.1093/biosci/biy095>.
- Lowe, S., M. Brown, S. Doudjelas, and M. De Poorter. 2000. 100 of the world's invasive alien species. A selection from the global invasive species database. *IUCN invasive species specialist group*. Updated Version 2004.
- Mahan, L.B., V. Ortega-Berno, T. Suriyamongkol, and I. Mali. 2020. *Chelydra serpentina* (Snapping Turtle), *Trachemys scripta* (Pond slider), and *Apalone spinifera* (Spiny Softshell Turtle). Anthropogenic damage. *Herpetological Review* 51: 827–828.
- Randklev, C.R., T. Miller, M. Hart, J. Morton, N.A. Johnson, K. Show, K. Inoue, E.T. Tsakiris, S. Oetker, R. Smith, C. Robertson, R. Lopez. 2018. A semi-arid river in distress: contributing factors and recovery solutions for three imperiled freshwater mussels (Family Unionidae) endemic to the Rio Grande Basin in North America. *Science of the Total Environment* 631–632: 733–744. <https://doi.org/10.1016/j.scitotenv.2018.03.032>.
- Steen, D.A., B.C. Hopkins, J.U. Van Dyke, and W.A. Hopkins. 2014. Prevalence of ingested fish hooks in freshwater turtles from five rivers in the southeastern United States. *PLoS ONE* 9: e91368. <https://doi.org/10.1371/journal.pone.0091368>.
- Steen D.A. and O.J. Robinson Jr. 2017. Estimating freshwater turtle mortality rates and population declines following hook ingestion. *Conservation Biology* 31: 1333–1339. <https://doi.org/10.1111/cobi.12926>.
- Suriyamongkol, S., K.J. Waldon, and I. Mali. 2019. *Trachemys scripta* (Red-eared Slider) and *Pseudemys gorzugi* (Rio Grande Cooter). Fish hook ingestion and shooting. *Herpetological Review* 50: 776–777.
- Swimmer, Y., C. Empey Campora, L. Mcnaughton, M. Musyl, and M. Parga. 2014. Post-release mortality estimates of loggerhead sea turtles (*Caretta caretta*) caught in pelagic longline fisheries based on satellite data and hooking location. *Aquatic Conservation: Marine and Freshwater Ecosystems* 24: 498–510. <https://doi.org/10.1002/aqc.2396>.
- Valente, A.L.S., R. Velarde, I. Marco, S. Lavin, and F. Alegre. 2007. Fishhook lesions in loggerhead sea turtles. *Journal of Wildlife Diseases* 43: 737–741. <https://doi.org/10.7589/0090-3558-43.4.737>.
- van Dijk, P.P., J. Harding, and G.A. Hammerson. 2011. *Trachemys scripta* (errata version published in 2016). *The IUCN Red List of Threatened Species* 2011: e.T22028A97429935. <https://dx.doi.org/10.2305/IUCN.UK.2011-1.RLTS.T22028A9347395.en>.
- Vecchioni, L., A. Cicerone, R. Scardino, V. Ariza, M. Arculeo, and F. Marrone. 2020. Sicilians are not easily hooked! First assessment of the impact of recreational fishing on the endemic Sicilian pond turtle *Emys trinacris* (Testudines, Emydidae). *Herpetology Notes* 13: 795–800.
- Waldon, K.J., A.W. Letter, and I. Mali. 2017. *Pseudemys gorzugi* (Rio Grande Cooter). Ingested fish hook. *Herpetological Review* 48: 837.