

## Ureteral Inguinal Herniation

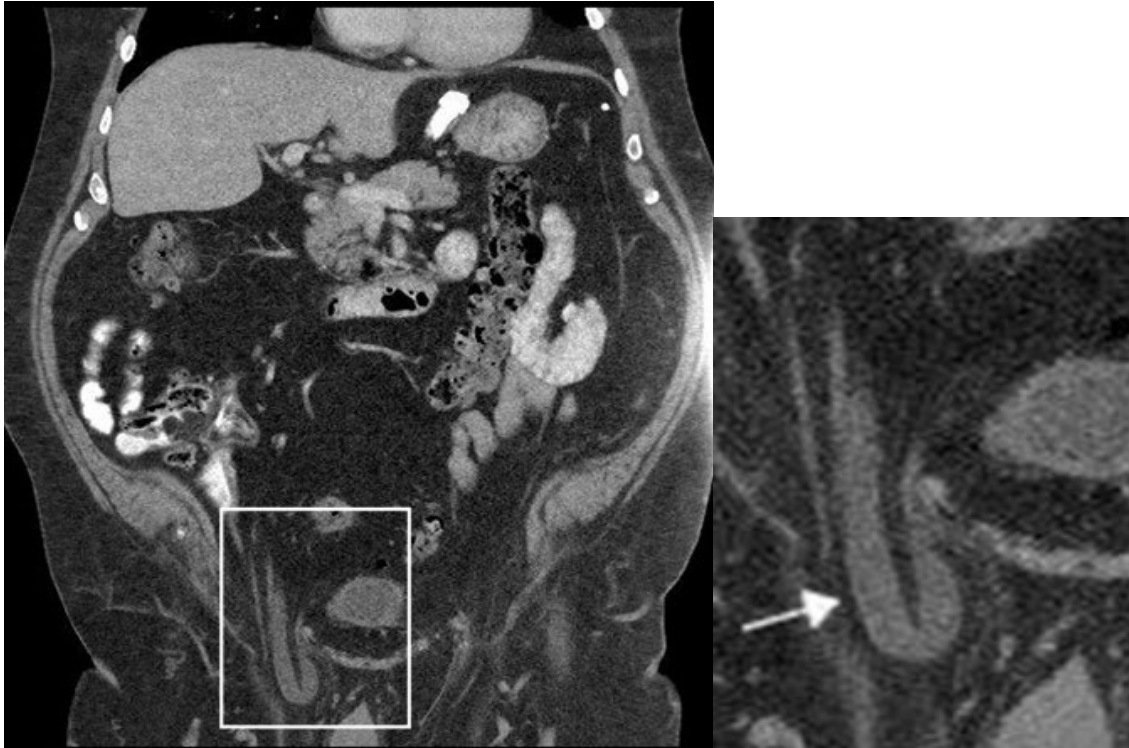
Robert T. Tung, M.D.<sup>1</sup>, Johannes Heyns, M.D.<sup>2</sup>

Department of Veterans Affairs, Eastern Kansas HealthCare System, Topeka, KS

<sup>1</sup>Medicine Service

<sup>2</sup>Radiology Service

Received April 30, 2022; Accepted for publication June 1, 2022; Published online Aug. 22, 2022  
<https://doi.org/10.17161/kjm.voll5.17961>



### CASE DESCRIPTION

Abdominal computed tomography (CT) was obtained in a patient for evaluation of a colon mass. The CT showed a slight dilatation of the right renal pelvis with no hydronephrosis, but inguinal herniation of the right ureter, which was dilated to 7 mm and looped inside the inguinal hernia with enlarged insert on the left (highlighted in the Figure within the white box and shown to the right). The arrow in the Figure insert points to the herniated and dilated right ureter.

### DISCUSSION

A hernia is defined as a protrusion or bulge of an organ or a part of an organ through the body wall that normally contains it. Groin hernias include inguinal and femoral hernias with a prevalence of 5-10% in the U.S.,<sup>1</sup> among them 96% are inguinal and 4% femoral hernia.<sup>2</sup>

The inguinal canal is lined by the aponeuroses of the abdominal oblique musculature, running from the deep (internal) inguinal ring to the superficial (external) ring. The internal ring is formed by an opening in the transversalis fascia while the superficial ring is formed by a gap in the external oblique aponeurosis. The canal contains the ilioinguinal nerve as well as the spermatic cord in males and round ligament in females.

The groin hernias can be classified according to the anatomic location of the abdominal wall defect into indirect inguinal, direct inguinal, and femoral hernias.<sup>3,4</sup>

- Indirect inguinal hernia is the most common type of groin hernia in both males and females.<sup>5</sup> It protrudes through the deep inguinal ring and inguinal canal.
- Direct inguinal hernia accounts for 30-40% of groin hernias in the male and 14-21% in the female.<sup>5</sup> It protrudes through an area of weakness in the transversalis fascia, the Hesselbach's triangle (defined laterally to rectus abdominis, medially to the inferior epigastric vessels and above the inguinal ligament).
- Femoral hernia represents less than 10% of all groin hernias.<sup>6</sup> They are located inferior to the inguinal ligament and protrude through the femoral ring, which is medial to the femoral vein and lateral to the lacunar ligament. The femoral ring can widen and become patulous with aging and following injury.

Groin hernias have a variety of clinical presentations from a benign finding of a bulge in groin region on routine physical examination to serious complications including acute intestinal obstruction as the result of incarcerated hernias. Inguinal herniation of the ureters is a rare phenomenon. It was first described by Leroux in 1880 as an autopsy finding.<sup>7</sup> The first preoperative diagnosis was achieved in 1937 using intravenous pyelography.<sup>8</sup> Since then, only isolated cases or small series have been reported in the literature.<sup>9,10</sup> Ureteral inguinal hernias are predominantly indirect rather than direct (80% vs. 20%). It is classified in two anatomical variants. The para-peritoneal type (80%) is defined by a loop of ureter that slides with a peritoneal sac into the hernia. This usually is acquired and has been associated with kidney transplants. The less common type (20%) is extra-peritoneal herniation of the ureter, which is thought to be congenital and caused by failure of ureter to separate from the mesonephric duct during development, resulting in the ureter being pulled along with testis as it descends into the scrotum.<sup>11</sup>

Ureteral herniation is usually an asymptomatic urological finding, often diagnosed incidentally by imaging evaluation of unrelated medical condition as in this case or by direct observation intraoperatively during surgical inguinal hernia repair.<sup>11</sup> Complications associated are uncommon, including ureteral obstruction/uropathy or inadvertent damage to the ureter during inguinal hernia repair.<sup>12</sup>

Awareness of this uncommon condition is important in evaluation of patients with obstructive uropathy and during surgical repair of inguinal hernia to prevent inadvertent damage to the ureter.

## REFERENCES

- <sup>1</sup> Kingsnorth A, LeBlanc K. Hernias: Inguinal and incisional. *Lancet* 2003; 362(9395):1561-1571. PMID: 14615114.
- <sup>2</sup> Rutkow IM, Robbins AW. Demographic, classificatory, and socioeconomic aspects of hernia repair in the United States. *Surg Clin North Am* 1993; 73(3):413-426. PMID: 8497793.
- <sup>3</sup> Zollinger RM Jr. An updated traditional classification of inguinal hernias. *Hernia* 2004; 8(4):318-322. PMID: 15221644.
- <sup>4</sup> Miserez M, Alexandre JH, Campanelli G, et al. The European hernia society groin hernia classification simple and easy to remember. *Hernia* 2007; 11(2):113-116. PMID: 17353992.
- <sup>5</sup> Koch A, Edwards A, Haapaniemi S, Nordin P, Kald A. Prospective evaluation of 6895 groin hernia repairs in women. *Br J Surg* 2005; 92(12):1553-1558. PMID: 16187268.
- <sup>6</sup> Dahlstrand U, Wollert S, Nordin P, Sandblom G, Gunnarsson U. Emergency femoral hernia repair: A study based on a national register. *Ann Surg* 2009; 249(4):672-676. PMID: 19300219.
- <sup>7</sup> Pasquale MD, Shabahang M, Evans SE. Obstructive uropathy secondary to massive inguinoscrotal bladder hernia. *J Urol* 1993; 150(6):1906-1908. PMID 8230533.
- <sup>8</sup> Giuly J, François GF, Giuly D, Leroux C, Nguyen-Cat RR. Intrascrotal hernia of the ureter and fatty hernia. *Hernia* 2003; 7(1):47-49. PMID: 12612799.
- <sup>9</sup> Allam ES, Johnson DY, Grewal SG, Johnson FE. Inguinoscrotal herniation of the ureter: Description of five cases. *Int J Surg Case Rep* 2015; 14:160-163. PMID: 26280912.
- <sup>10</sup> Oruç MT, Akbulut Z, Ozozan O, Coşkun F. Urological findings in inguinal hernia: A case report and review of the literature. *Hernia* 2004; 8(1):76-79. PMID: 13680305.
- <sup>11</sup> Falidas E, Gourgiotis S, Veloudis G, Exarchou E, Vlachos K, Villias C. Asymptomatic extraperitoneal inguinoscrotal hernia involving ureter: A case presentation and review of the literature. *J Nat Sci Biol Med* 2015; 6(Suppl 1):S153-S155. PMID: 26604607.
- <sup>12</sup> Hwang C, Miller F, Dalton DP, Hartz WH. Accidental ureteral ligation during an inguinal hernia repair of a patient with crossed fused renal ectopia. *Clin Imag* 2002; 26(5):306-308. PMID: 12213362.

*Keywords: ureteral diseases, inguinal hernia, computed tomography*