



AALBORG UNIVERSITY
DENMARK

Aalborg Universitet

Patients with VEXAS diagnosed in a Danish tertiary rheumatology setting have highly elevated inflammatory markers, macrocytic anaemia and negative autoimmune biomarkers

Rasch, Mads Nyhuus Bendix; Szabados, Fruzsina; Jensen, Jens Magnus Bernth; Nielsen, Kirstine Overgaard; Hauge, Ellen-Margrethe; Troldborg, Anne

Published in:
RMD Open

DOI (link to publication from Publisher):
[10.1136/rmdopen-2022-002492](https://doi.org/10.1136/rmdopen-2022-002492)

Creative Commons License
CC BY-NC 4.0

Publication date:
2022

Document Version
Publisher's PDF, also known as Version of record

[Link to publication from Aalborg University](#)

Citation for published version (APA):

Rasch, M. N. B., Szabados, F., Jensen, J. M. B., Nielsen, K. O., Hauge, E-M., & Troldborg, A. (2022). Patients with VEXAS diagnosed in a Danish tertiary rheumatology setting have highly elevated inflammatory markers, macrocytic anaemia and negative autoimmune biomarkers. *RMD Open*, 8(2), [e002492]. <https://doi.org/10.1136/rmdopen-2022-002492>


General rights

Copyright and moral rights for the publications made accessible in the public portal are retained by the authors and/or other copyright owners and it is a condition of accessing publications that users recognise and abide by the legal requirements associated with these rights.

- Users may download and print one copy of any publication from the public portal for the purpose of private study or research.
- You may not further distribute the material or use it for any profit-making activity or commercial gain
- You may freely distribute the URL identifying the publication in the public portal -

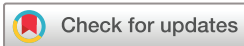SHORT REPORT

Patients with VEXAS diagnosed in a Danish tertiary rheumatology setting have highly elevated inflammatory markers, macrocytic anaemia and negative autoimmune biomarkers

Mads Nyhuus Bendix Rasch,¹ Fruzsina Szabados,² Jens Magnus Bernth Jensen,^{3,4} Kirstine Overgaard Nielsen,³ Ellen-Margrethe Hauge,^{1,5} Anne Trolborg^{1,6} 

To cite: Rasch MNB, Szabados F, Jensen JMB, *et al.* Patients with VEXAS diagnosed in a Danish tertiary rheumatology setting have highly elevated inflammatory markers, macrocytic anaemia and negative autoimmune biomarkers. *RMD Open* 2022;**8**:e002492. doi:10.1136/rmdopen-2022-002492

Received 7 June 2022
Accepted 23 August 2022



© Author(s) (or their employer(s)) 2022. Re-use permitted under CC BY-NC. No commercial re-use. See rights and permissions. Published by BMJ.

¹Rheumatology, Aarhus University Hospital, Aarhus, Denmark

²Rheumatology, Sygehus Vendsyssel i Hjørring, Hjørring, Nordjylland, Denmark

³Clinical Immunology, Aarhus University Hospital, Aarhus, Denmark

⁴Molecular Medicine, Aarhus University Hospital, Aarhus, Denmark

⁵Department of Clinical Medicine, Aarhus University, Aarhus, Denmark

⁶Biomedicine, Aarhus University, Aarhus, Denmark

Correspondence to

Dr Anne Trolborg;
annetrol@rm.dk

ABSTRACT

Background Vacuoles, E1 enzyme, X-linked, autoinflammatory, somatic (VEXAS) is an autoinflammatory condition with overlapping features of rheumatology and haematology caused by somatic mutations in the *UBA1* gene. Patients present with highly variable symptoms and their path towards diagnosis are often complicated and characterised by extensive examinations. It is, therefore, pivotal that clinicians become familiar with the clinical presentation of VEXAS to advance identification of patients with the disease.

Objectives We aimed to (1) characterise patients diagnosed with VEXAS in a tertiary rheumatology referral centre, (2) identify common rheumatological biomarkers that may distinguish VEXAS from other rheumatic diseases and (3) suggest which clinical findings should motivate genetic testing for VEXAS.

Methods Patients were identified and diagnosed at the department of Rheumatology, Aarhus University Hospital (AUH), Denmark. Blood samples were examined for VEXAS-associated *UBA1* variants by Sanger sequencing at the department of Clinical Immunology, AUH. Clinical and biochemical data were retrieved from the hospital electronic patient chart.

Results Eleven male patients with clinical suspicion of VEXAS underwent sequencing. Five of these carried known VEXAS-associated variants. Median age at diagnosis was 84 (75–87) years. All patients had significantly elevated inflammatory markers with a median C-reactive protein (CRP) of 297 (196–386) mg/L and macrocytic anaemia. None of the patients presented common biomarkers for autoimmunity.

Conclusion Danish patients with VEXAS syndrome are men with persistent inflammation, constitutional symptoms and heterogeneous clinical presentations. Shared features for all patients in this study were highly elevated inflammatory markers, macrocytic anaemia and negative autoimmune biomarkers.

WHAT IS ALREADY KNOWN ON THIS TOPIC

⇒ The clinical presentation of vacuoles, E1 enzyme, X-linked, autoinflammatory, somatic (VEXAS) varies considerably between patients. International consensus on which symptoms should lead to genetic testing for VEXAS is lacking.

WHAT THIS STUDY ADDS

⇒ The study shows that patients referred to the rheumatology clinic that are later diagnosed with VEXAS have negative autoimmune biomarkers. This could be an important supplement in the differentiation between the systemic autoimmune diseases and VEXAS.

⇒ The study suggests an algorithm for which symptoms should motivate referral to genetic testing for VEXAS.

HOW THIS STUDY MIGHT AFFECT RESEARCH, PRACTICE OR POLICY

⇒ A prompt diagnosis of VEXAS is pivotal to avoid unnecessary clinical testing and procedures prior to diagnosis.

⇒ An algorithm based on common clinical features of VEXAS will lead to an immediate diagnosis of patients and avoid unnecessary testing of patients, who do not have VEXAS.

INTRODUCTION

Vacuoles, E1 enzyme, X-linked, autoinflammatory, somatic (VEXAS) was described in December 2020.¹ The acronym VEXAS stands for: vacuoles (characteristic finding in cell cytoplasm in the bone marrow); E1 enzyme (the defective enzyme due to gene variation); X, the gene variant is found on the X chromosome; autoinflammation (most patients have persistent, uncontrollable inflammation);

somatic (the gene variant is not congenital but occurs de novo in the myeloid cell line).

It is characteristic that patients with VEXAS present with severe inflammation, rheumatological symptoms and haematological symptoms within the myelodysplastic syndromes (MDS) spectrum.

The most common rheumatological VEXAS symptoms are arthritis, cutaneous vasculitis, chondritis, erythema nodosum, eye affection and/or neutrophil dermatosis.^{2,3}

The most common haematological manifestations are macrocytic anaemia and lymphopenia. Thrombopenia and neutropenia are typically seen in patients where VEXAS progresses to MDS.⁴ In addition to rheumatological and haematological symptoms, thrombosis is a recurrent and severe manifestation in approximately 35% of patients.²

The mutations leading to VEXAS are located in the *UBA1* gene. *UBA1* encodes the E1 enzyme, which initiates ubiquitinylation. Ubiquitinylation is a post-translational protein modification essential for regulating several intracellular processes, including degradation of proteins.⁵ The VEXAS-associated variants hamper E1 function and thereby impedes ubiquitinylation in the affected cells, which causes accumulation of proteins and uncontrolled inflammation.⁶

With knowledge of variants associated with VEXAS syndrome, it is now possible to identify patients with VEXAS with simple Sanger sequencing of a small region of the *UBA1* gene.

Our primary objective was to characterise patients diagnosed with VEXAS in a tertiary Danish rheumatology referral centre. Secondly, identify common biomarkers that facilitates separation of VEXAS from other rheumatic diseases. Third, we propose which major and minor clinical features that should motivate genetic testing for variants in the *UBA1* gene.

METHODS

Patients

The study included patients referred to or followed at the rheumatology department at Aarhus University Hospital, Denmark, between December 2020 and December 2021 with a suspected diagnosis of VEXAS. Clinical and biochemical data were obtained from the hospital's electronic patient chart. All patients gave informed consent to genetic testing and inclusion in this study.

As the study was considered a quality control study, no ethics permission was required by the Regional Committee on Health Ethics. Patient consent and approval from the hospital quality control department were obtained.

Sanger sequencing

VEXAS is associated with several variants in a relatively restricted part of *UBA1* spanning a sequence length of no more than 100 nucleotides.^{1,2,7} An international standard

for the genetic diagnosis of VEXAS has so far not been defined.

We used Sanger sequencing. Peripheral venous blood was withdrawn from patients, and DNA was purified and analysed at the Department of Clinical Immunology, Aarhus University Hospital.

The assay covered the hitherto-reported VEXAS-associated variants in/at exon 3 (NM_003334.4: c.118–1G>C, c.121A>C/G and c.122T>C og c.167C>T). PCR amplification and sequencing of exon 3 in the *UBA1* gene was performed following standard procedures using the primers 5'-AAGCCGGTTCTAACTGCTC-3' and 5'-CAGTGCCCTGGTCATGTAGG-3'.

RESULTS

Eleven male patients with a clinical suspicion of VEXAS underwent sequencing.

Five of these patients were found to carry VEXAS-associated variants. The variants and clinical features are summarised in [table 1](#). The median age at diagnosis was 84 (75–87) years, and symptoms had, on average, been present 22 months (IQR 20–40) prior to the diagnosis. All five patients had significantly elevated markers of inflammation: median C-reactive protein (CRP) 297 (196–386) mg/L,

IL-2-receptor 3472 (1893–3660) kU/L and ferritin 1561 (1228–3680) µg/L and presented with macrocytic anaemia. None of the patients was positive for autoimmune biomarkers like antinuclear antibodies (ANA), anticitrullinated protein antibody (ACPA), myeloperoxidase (MPO) or proteinase-3 (PR3) antineutrophil cytoplasmic antibody (ANCA).

Treatment

Case 1 was initially treated with IVIG 0.4 mg/kg for 5 days every 4 weeks in combination with secukinumab 300 mg/4 weeks. We were not able to taper prednisolone below 15 mg/day without disease flares, and the patient died of heart failure 14 months after diagnosis. Case 2 started on methotrexate and prednisolone. Because of recurrent infections, the patient was switched to anakinra. The patient is in remission and prednisolone has been tapered to 5 mg/day. Case 3 was treated with high-dose prednisolone in combination with anakinra 100 mg/day. Because of lacking response with ongoing disease and kidney failure, anakinra was increased to 200 mg/day. On patient request, treatment was stopped and patient died 14 days later, 4 months after diagnosis. Case 4 is in remission on secukinumab 150 mg/4 weeks in combination with prednisolone, which has now been tapered to 8.25 mg/day. Case 5 was severely sick at the time of diagnosis and declined treatment apart from prednisolone. Case 5 died 2 months after diagnosis.

Clinical features that may motivate genetic testing for VEXAS

International consensus on which findings should prompt genetic testing for VEXAS is not established. However, based on the available literature, the largest case study

Table 1 Clinical characteristics, treatment and biochemical characteristics of included VEXAS patients

	Case 1	Case 2	Case 3	Case 4	Case 5	Total n (%) or median (IQR)
Clinical characteristics						
Age at diagnosis	73	89	77	84	85	84 (75–87)
Initial symptoms	Skin rash, elevated CRP, thrombophlebitis and constitutional symptoms	Abdominal pain, fever, elevated CRP	Chondritis of the ear, arthritis and Raynauds	Fever, elevated CRP, constitutional symptoms	Constitutional symptoms, elevated CRP	
Time from symptom onset till diagnosis (months)	18	21	47	30	22	22 (20–40)
Dead	+	-	+	-	+	3 (60)
<i>UBA1</i> variant	c.122 T>C p.Met41Thr	c.122 T>C p.Met41Thr	c.122 T>C p.Met41Thr	c.121 A>C p.Met41Leu	c.118-1 G>Cp. (splice)	
Macrocytic anaemia	+	+	+	+	+	5 (100)
Constitutional symptoms*	+	+	+	+	+	5 (100)
Vasculitis	+	+	+	-	+	4 (80) (skin, leukocytoclastic)
Chondritis	-	-	+	-	+	2 (40) (ear, bilateral)
Ocular inflammation	-	-	+	-	-	1 (20)
Arthritis	+	-	+	+	-	3 (60)
Lung involvement	+	+	+	+	+	5 (100) (bilateral infiltrates, biopsy with organising pneumonia)
Proteinuria (U-albumin, mg/L)	-	+	+	-	+	3 (60) (208) (4887) amyloidosis and haemodialysis
Thrombosis	+	-	-	+	-	2 (40) (superficial thrombophlebitis+DVT) (a.brachiocephalica+cerebral infarction)
BM vacuoles	-	+	+	NA	-	2/4 (50)
Treatment						
Glucocorticoids	+	+	+	+	+	
Treatments	SKM, IVIG	MTX, AKA	AKA	MTX, SKM	-	

Continued

Table 1 Continued

	Case 1	Case 2	Case 3	Case 4	Case 5	Total n (%) or median (IQR)
Biochemical characteristics						
CRP (max, mg/mL)	+ (335)	+ (436)	+ (220)	+ (172)	+ (297)	5 (100) (297 (196-386))
Ferritin (max, µg/L)	1200	4670	2690	1256	1561	1561 (1228-3680)
IL-2 rec (max, kU/L)	+ (3472)	+ (3480)	+ (2144)	+ (1642)	+ (3840)	5 (100) 3472 (1893-3660)
M-comp	+	-	-	-	+	2 (40)
ANA	-	-	-	-	-	0 (0)
PR3 ANCA	-	-	-	-	-	0 (0)
MPO ANCA	-	-	-	-	-	0 (0)
ACPA	NA	-	-	-	NA	0 (0)
IgM-RF	-	-	+ (36)	+ (12)	-	2 (40)

*Constitutional symptoms (fever, night sweats, weight loss).
ACPA, anti-citrullinated protein antibody; AKA, anakinra; ANA, anti-nuclear antibodies; BM, bone marrow; CRP, C-reactive protein; DMARD, disease modifying anti-rheumatic drugs; IL-2-rec, interleukin-2-receptor; IVIG, intravenous immunoglobulin; MPO, myeloperoxidase; MTX, methotrexate; NA, not available; PR3-ANCA, proteinase-3 anti-cytoplasmatic antibody; SKM, Secukinumab.

Box 1 Suggested clinical features that should prompt genetic testing for variants in the *UBA1* gene. The absence of the two major manifestations should lead the clinician to consider other diagnosis than VEXAS.

Major manifestations:

1. Macrocytic anaemia and
2. Unexplained, ongoing inflammation (malignancy and infections have been ruled out).

Minor manifestations:

3. One or more of the following manifestations:
 - Skin changes.
 - Arthritis.
 - Fever.
 - Weight loss.
 - Eye involvement.
 - Chondritis.
 - Pulmonary infiltrates.
 - Thromboses (including superficial).
 - Cytopenias (MDS-like).
 - Adenopathy.

presented on VEXAS,² and our own experiences with patients with VEXAS, we would currently suggest genetic testing for VEXAS in patients who present with the clinical data listed in **box 1**. Most patients are men, however, if the relevant symptoms are present, female gender does not exclude VEXAS.

DISCUSSION

Patients with VEXAS diagnosed in a tertiary Danish rheumatology referral centre—the first year after description of the syndrome—were all elderly male patients with macrocytic anaemia, severe inflammation and negative autoantibodies (ANA, ACPA, MPO-ANCA and PR3-ANCA).

In our case series, autoimmune markers typically related to connective tissue diseases (ANA), small vessel vasculitis (PR3-ANCA and MPO-ANCA) or rheumatoid arthritis (ACPA) were not detected in any patients with VEXAS-associated variants. The presence of autoimmune biomarkers has not been systematically reported in previous reports of VEXAS patients; however, there has been reports of ANCA-positive patients with VEXAS as well as patients with antiphospholipid antibodies.⁸ Thus, the lack of autoantibodies in the present case series, should not lead to premature conclusions of negative autoimmune biomarkers in VEXAS.

The strategy for VEXAS treatment so far reflects the specialty managing the treatment.^{9 10} In haematology, treatment with cytostatics (eg, azacitidine) has been used to reduce the disease-causing cell clone. In rheumatology, treatment with antibodies against tumour necrotising factor alpha, interleukin-1 (IL-1), iIL-6, IL-17 or janus kinase inhibition has been attempted to decrease the disease-associated inflammation.

International treatment guidelines for VEXAS have not been established. Universal to the published cases on VEXAS treatment is that the disease is refractory to most medications. Glucocorticoids attenuate the inflammatory activity, which was also the case in the cases presented here; however, the disease often requires sustained therapy at high doses, and flares are seen with tapering.^{2 11} In our case series, two cases were brought to remission with glucocorticoids in combination with anakinra or secukinumab.

Successful allogeneic haematopoietic stem cell transplantation has been performed in patients with VEXAS,^{12 13} but the procedure is not established as a primary treatment option for patients.¹³ We still need to appreciate how to select the eligible patients and many questions remain regarding the management of conditions that may be unique to patients with VEXAS.⁹

Future treatment of VEXAS may include new approaches. The somatic variant in autologous cells might be corrected back to the healthy allele with CRISPR/Cas9 or other gene-editing tools. Such approaches have not been attempted yet but hold exciting perspectives and may offer an alternative for patients too fragile for allogeneic transplantation.

During the inclusion period, no women with a phenotype corresponding to VEXAS were encountered. *UBA1* is located on the X chromosome but is not subject to X inactivation.¹⁴ VEXAS has only been described in four women, who all had only one functional X chromosome.^{15–18} Three women had acquired monosomy-X (functional X-monosomy) because of age-related mosaicism,^{15–17 19} and one woman had Turner syndrome (congenital monosomy X, 45, X0 karyotype).¹⁸ VEXAS has not been observed in women with two functional X chromosomes, suggesting that a healthy allele is sufficient to protect against VEXAS. This explains why VEXAS in essence affects men.

The average age of patients in this case series was higher than in previous reports.^{1–3} It is well known that somatic mutations occur more frequently with age.²⁰ However, the average higher age observed here is more likely due to chance because of the low number of cases.

Our proposed algorithm for selecting patients for VEXAS-testing/diagnostics is intended to avoid excessive genetic testing for VEXAS. There are no international recommendations regarding the diagnosis. Based on the current literature, the largest case study presented on VEXAS,² and our own experience, we expect that the proposed criteria are probably sensitive and specific for identifying VEXAS. This has to be validated prospectively in several and larger cohorts. Furthermore, it must be kept in mind that VEXAS is a new disease entity, and the phenotype is still expanding. Therefore, the suggested clinical features may change as evidence accumulates on the VEXAS syndrome.

We report the first report on Danish patients with VEXAS. Patients are men with persistent inflammation, constitutional symptoms and a heterogeneous clinical

presentation. Common features for all patients in this case series were highly elevated inflammatory markers, macrocytic anaemia and negative autoimmune biomarkers.

Twitter Anne Trolborg @TrolborgAnne

Acknowledgements The authors would like to acknowledge the patients for participation in the study.

Contributors AT, MNBR, FS and E-MH designed the study. JMBJ and KON designed the assays and performed the analysis. MNBR and FS included patients and obtained consent. MNBR and AT wrote the first manuscript, which was read, corrected, adjusted and approved by all co-authors.

Funding The authors have not declared a specific grant for this research from any funding agency in the public, commercial or not-for-profit sectors.

Competing interests None declared.

Patient consent for publication Consent obtained directly from patient(s).

Ethics approval This study involves human participants and was approved by Aarhus University Hospital (Institutional Board). Participants gave informed consent to participate in the study before taking part.

Provenance and peer review Not commissioned; externally peer reviewed.

Open access This is an open access article distributed in accordance with the Creative Commons Attribution Non Commercial (CC BY-NC 4.0) license, which permits others to distribute, remix, adapt, build upon this work non-commercially, and license their derivative works on different terms, provided the original work is properly cited, appropriate credit is given, any changes made indicated, and the use is non-commercial. See: <http://creativecommons.org/licenses/by-nc/4.0/>.

ORCID iD

Anne Trolborg <http://orcid.org/0000-0002-9501-1268>

REFERENCES

- 1 Beck DB, Ferrada MA, Sikora KA, *et al*. Somatic Mutations in *UBA1* and Severe Adult-Onset Autoinflammatory Disease. *N Engl J Med* 2020;383:2628–38.
- 2 Geogin-Lavielle S, Terrier B, Guedon AF, *et al*. Further characterization of clinical and laboratory features in VEXAS syndrome: large-scale analysis of a multicentre case series of 116 French patients. *Br J Dermatol* 2022;186:564–74.
- 3 Ferrada MA, Sikora KA, Luo Y, *et al*. Somatic mutations in *UBA1* define a distinct subset of relapsing polychondritis patients with VEXAS. *Arthritis Rheumatol* 2021;73:1886–95.
- 4 Obiorah IE, Patel BA, Groarke EM, *et al*. Benign and malignant hematologic manifestations in patients with VEXAS syndrome due to somatic mutations in *UBA1*. *Blood Adv* 2021;5:3203–15.
- 5 Glickman MH, Ciechanover A. The ubiquitin-proteasome proteolytic pathway: destruction for the sake of construction. *Physiol Rev* 2002;82:373–428.
- 6 Navid F, Colbert RA. Causes and consequences of endoplasmic reticulum stress in rheumatic disease. *Nat Rev Rheumatol* 2017;13:25–40.
- 7 Poulter JA, Collins JC, Cargo C, *et al*. Novel somatic mutations in *UBA1* as a cause of VEXAS syndrome. *Blood* 2021;137:3676–81.
- 8 Muratore F, Marvisi C, Castrignanò P, *et al*. VEXAS syndrome: a case series from a single-center cohort of Italian patients with vasculitis. *Arthritis Rheumatol* 2022;74:665–70.
- 9 Heiblig M, Patel BA, Groarke EM, *et al*. Toward a pathophysiology inspired treatment of VEXAS syndrome. *Semin Hematol* 2021;58:239–46.
- 10 Bourbon E, Heiblig M, Gerfaud Valentin M, *et al*. Therapeutic options in VEXAS syndrome: insights from a retrospective series. *Blood* 2021;137:3682–4.
- 11 Koster MJ, Kourelis T, Reichard KK, *et al*. Clinical heterogeneity of the VEXAS syndrome: a case series. *Mayo Clin Proc* 2021;96:2653–9.
- 12 Diarra A, Duployez N, Fournier E, *et al*. Successful allogeneic hematopoietic stem cell transplantation in patients with VEXAS syndrome: a 2-center experience. *Blood Adv* 2022;6:998–1003.
- 13 Loschi M, Roux C, Sudaka I, *et al*. Allogeneic stem cell transplantation as a curative therapeutic approach for VEXAS syndrome: a case report. *Bone Marrow Transplant* 2022;57:315–8.
- 14 Carrel L, Clemson CM, Dunn JM, *et al*. X inactivation analysis and DNA methylation studies of the ubiquitin activating enzyme E1 and PCTAIRE-1 genes in human and mouse. *Hum Mol Genet* 1996;5:391–401.
- 15 Arlet J-B, Terrier B, Kosmider O. Mutant *UBA1* and severe adult-onset autoinflammatory disease. *N Engl J Med* 2021;22:2163.
- 16 Tsuchida N, Kunishita Y, Uchiyama Y, *et al*. Pathogenic *UBA1* variants associated with VEXAS syndrome in Japanese patients with relapsing polychondritis. *Ann Rheum Dis* 2021;80:1057–61.
- 17 Barba T, Jamilloux Y, Durel C-A, *et al*. VEXAS syndrome in a woman. *Rheumatology* 2021;60:e402–3.
- 18 Stubbins RJ, McGinnis E, Johal B, *et al*. VEXAS syndrome in a female patient with constitutional 45,X (Turner syndrome). *Haematologica* 2022;107:1011–3.
- 19 Machiela MJ, Zhou W, Karlins E, *et al*. Female chromosome X mosaicism is age-related and preferentially affects the inactivated X chromosome. *Nat Commun* 2016;7:11843.
- 20 Milholland B, Auton A, Suh Y, *et al*. Age-related somatic mutations in the cancer genome. *Oncotarget* 2015;6:24627–35.