



Aalborg Universitet

AALBORG UNIVERSITY
DENMARK

Disrupted white matter integrity in the brain of type 1 diabetes is associated with peripheral neuropathy and abnormal brain metabolites

Muthulingam, Janusiya Anajan; Brock, Christina; Hansen, Tine Maria; Drewes, Asbjørn Mohr; Brock, Birgitte; Frøkjær, Jens Brøndum

Published in:
Journal of Diabetes and its Complications

DOI (link to publication from Publisher):
[10.1016/j.jdiacomp.2022.108267](https://doi.org/10.1016/j.jdiacomp.2022.108267)

Creative Commons License
CC BY 4.0

Publication date:
2022

Document Version
Publisher's PDF, also known as Version of record

[Link to publication from Aalborg University](#)

Citation for published version (APA):

Muthulingam, J. A., Brock, C., Hansen, T. M., Drewes, A. M., Brock, B., & Frøkjær, J. B. (2022). Disrupted white matter integrity in the brain of type 1 diabetes is associated with peripheral neuropathy and abnormal brain metabolites. *Journal of Diabetes and its Complications*, 36(9), [108267]. <https://doi.org/10.1016/j.jdiacomp.2022.108267>

General rights

Copyright and moral rights for the publications made accessible in the public portal are retained by the authors and/or other copyright owners and it is a condition of accessing publications that users recognise and abide by the legal requirements associated with these rights.

- Users may download and print one copy of any publication from the public portal for the purpose of private study or research.
- You may not further distribute the material or use it for any profit-making activity or commercial gain
- You may freely distribute the URL identifying the publication in the public portal -

Take down policy

If you believe that this document breaches copyright please contact us at vbn@aub.aau.dk providing details, and we will remove access to the work immediately and investigate your claim.



Contents lists available at ScienceDirect

Journal of Diabetes and Its Complications

journal homepage: www.elsevier.com/locate/jdiacomp

Disrupted white matter integrity in the brain of type 1 diabetes is associated with peripheral neuropathy and abnormal brain metabolites

Janusiya Anajan Muthulingam^a, Christina Brock^{b,d}, Tine Maria Hansen^{a,b},
Asbjørn Mohr Drewes^{b,c}, Birgitte Brock^e, Jens Brøndum Frøkjær^{a,b,*}

^a Mech-Sense, Department of Radiology, Aalborg University Hospital, Aalborg, Denmark

^b Department of Clinical Medicine, Aalborg University, Aalborg, Denmark

^c Centre for Pancreatic Diseases, Department of Gastroenterology & Hepatology, Aalborg University Hospital, Aalborg, Denmark

^d Mech-Sense, Department of Gastroenterology and Hepatology, Aalborg University Hospital, Aalborg, Denmark

^e Steno Diabetes Center Copenhagen, Niels Steensens Vej 2, 2820 Gentofte, Denmark

ARTICLE INFO

Keywords:

Diabetic peripheral neuropathy
Diffusion tensor imaging
Magnetic resonance imaging
N-acetylaspartate: type 1 diabetes mellitus

ABSTRACT

Aims: We aimed to quantify microstructural white matter abnormalities using magnetic resonance imaging and examine their associations with 1) brain metabolite and volumes and 2) clinical diabetes-specific characteristics and complications in adults with type 1 diabetes mellitus (T1DM) and distal symmetric peripheral neuropathy (DSPN).

Methods: Diffusion tensor images (DTI) obtained from 46 adults with T1DM and DSPN and 28 healthy controls were analyzed using tract-based spatial statistics and were then associated with 1) brain metabolites and volumes and 2) diabetes-specific clinical characteristics (incl. HbA_{1c}, diabetes duration, level of retinopathy, nerve conduction assessment).

Results: Adults with T1DM and DSPN had reduced whole-brain FA skeleton ($P = 0.018$), most prominently in the inferior longitudinal fasciculus and retrolenticular internal capsule ($P < 0.001$). Reduced fractional anisotropy (FA) was associated with lower parietal N-acetylaspartate/creatinine metabolite ratio ($r = 0.399$, $P = 0.006$), brain volumes ($P \leq 0.002$), diabetes duration ($r = -0.495$, $P < 0.001$) and sural nerve amplitude ($r = 0.296$, $P = 0.046$). Additionally, FA was reduced in the subgroup with concomitant proliferative retinopathy compared to non-proliferative retinopathy ($P = 0.03$). No association was observed between FA and HbA_{1c}.

Conclusions: This hypothesis-generating study provided that altered white matter microstructural abnormalities in T1DM with DSPN were associated with reduced metabolites central for neuronal communications and diabetes complications, indicating that peripheral neuropathic complications are often accompanied by central neuropathy.

1. Introduction

Distal symmetric peripheral neuropathy (DSPN) is a severe and common complication of diabetes mellitus¹ manifesting with sensory and motor loss of the peripheral nerves in the feet and hands, causing painful or painless disturbances.² The pathophysiology behind diabetic DSPN is multifactorial, with metabolic, vascular, oxidative, and immune-mediated damage of the neurons or glia cells thought to be the main contributing factors.³

Recent evidence suggests that alterations in the central nervous system (CNS) play a crucial role in the symptoms associated with

diabetic DSPN. Using magnetic resonance imaging (MRI), reduced total gray matter volume,^{4,5} decreased level of the cerebral metabolite N-acetylaspartate/creatinine (NAA/cre) central for neuronal communications,⁶ thalamic atrophy,⁷ altered functional connectivity of the thalamus, as well as functional abnormalities including thalamic neuronal dysfunction,⁸ have been demonstrated in type 1 diabetes (T1DM) with DSPN. Furthermore, adults with DSPN have increased peripheral gray matter volume loss localized to regions involved with somatosensory perception⁵ compared with subjects without DSPN.

In contrast to conventional brain MRI, advanced neuroimaging techniques such as diffusion tensor imaging (DTI) reveal microstructural

* Corresponding author at: Mech-Sense, Department of Radiology, Aalborg University Hospital, P.O. Box 365, DK-9100 Aalborg, Denmark.

E-mail address: jebf@dcm.aau.dk (J.B. Frøkjær).

<https://doi.org/10.1016/j.jdiacomp.2022.108267>

Received 25 January 2022; Received in revised form 23 May 2022; Accepted 13 July 2022

Available online 16 July 2022

1056-8727/© 2022 The Authors. This is an open access article under the CC BY license (<http://creativecommons.org/licenses/by/4.0/>).

alterations, particularly involving white matter tracts.⁹ DTI quantitatively measures the motion of water molecules within the brain tissues. The fractional anisotropy (FA) index, in which the value varies between 0 and 1, is the primary metric for evaluating the diffusivity of water molecules in the white matter microstructure.¹⁰ FA has been shown to be sensitive to changes in myelination and axonal integrity, and reduced FA has been observed in several brain disorders, i.e., multiple sclerosis and diabetes. Thus, lower FA is associated with loss of microstructural integrity and neurodegeneration,¹¹ while a high mean diffusivity indicates broad cellular damages, including edema and necrosis.¹²

To our best knowledge, nine DTI studies have been conducted on T1DM, demonstrating brain microstructural changes and their relationship with cognitive functions and metabolic profile.⁹ A reduction of FA in T1DM compared to healthy controls was consistently demonstrated in several brain regions.⁹ Additionally, some DTI studies suggested that longer disease duration and increased HbA_{1c} values correlated with the severity of white matter microstructural abnormalities.⁹ While these studies focused on HbA_{1c} and disease duration, less attention has been paid to the association between microstructural and functional changes in the brain. Similarly, diabetes complications such as peripheral nerve function and retinopathy, a marker of general microangiopathy, have received little attention in relation to microstructural white matter changes. In addition to peripheral neuropathy, retinopathy is another common microvascular long-term complication of T1DM, that has been shown to be associated with brain structure^{13,14} and cerebral metabolites,⁶ although the relationship between the development of white matter changes and microangiopathy is not well established. Furthermore, considering the frequently reported changes with peripheral axonal loss and reduction in myelinated fiber density in DSPN^{15–17} as well as structural, functional, and metabolic brain alterations, a comprehensive assessment of microstructural DTI and MRI spectroscopy would bring valuable insights into the mechanisms driving and maintaining DSPN. Thus, the overall aim of this study was to address these knowledge gaps.

We hypothesized that adults with T1DM and DSPN have reduced FA in widespread white matter brain regions compared to healthy controls and that other types of cerebral characteristics (brain volumes and brain metabolites) were correlated to microstructural white matter alterations as well as diabetes-specific clinical characteristics. Therefore, this explorative study aimed to investigate MRI diffusion parameters using a whole-brain tract-based spatial statistics approach to 1) determine microstructural white matter changes in adults with T1DM and DSPN, and 2) explore the associations with a) other MRI brain characteristics and b) clinical diabetes-specific characteristics (HbA_{1c}, disease duration, level of retinopathy, and nerve conduction assessment).

2. Subjects, materials, and methods

2.1. Study population

Forty-eight adults with T1DM and DSPN and 28 healthy controls were enrolled from the outpatient clinic at the Department of Endocrinology, Aalborg University Hospital, Denmark, as part of another trial assessing the effect of liraglutide to treat diabetic neuropathy and was conducted at Aalborg University Hospital from 2014 to 2017 (EudraCT 2013-004375-12). Hence, this study was based on secondary analyses. The diagnosis of DSPN was made according to the Toronto Diabetic Neuropathy Expert Group,¹⁸ based on a neurophysiological assessment of the larger axons of the lower extremities. Inclusion criteria were as follows: age ≥ 18 years, verified diagnosis of T1DM for a minimum of two years (HbA_{1c} ≥ 48 mmol/mol (≥ 6.5 %)), stable treatment, confirmed DSPN as outlined above, and body mass index (BMI) ≥ 22 kg/m².

Healthy controls were age and sex-matched in the study and were obtained from an established dataset (N-20090008 approved by the North Denmark Region Committee on Health Research Ethics). Before

inclusion, all controls were clinically screened to confirm a healthy status without any relevant CNS-related diseases, medication, or diabetes.

All participants gave written, informed consent before inclusion. Ethical approvals were granted by The North Denmark Region Committee on Health Research Ethics (N-20130077, N-20090008) and registered with clinicaltrials.gov (ref NCT02138045). The study was conducted in accordance with the Declaration of Helsinki.

2.2. Assessment of diabetes-specific clinical characteristics

Routine clinical chemistry, such as HbA_{1c}, was analyzed at the Department of Clinical Biochemistry, Aalborg University Hospital. Information on demographics (age, sex, disease duration, body mass index, and age of diabetes onset) was obtained from the clinical records. The current glucose level was measured on the day of MRI scanning. All participants completed a structured neurophysiological examination to determine the severity of peripheral neuronal function of the lower extremities. Specifically, the included peripheral nerve conduction study measurements were a) amplitude and nerve conduction velocity of the sural nerve and b) amplitude and latency of the tibial nerve. In the case of an unmeasurable value, the value before the lowest detected value was assigned.⁶ A photograph of the right retina was conducted and graded by a specialist at the Department of Ophthalmology, Aalborg University Hospital, to assess the severity and grade of diabetic retinopathy.¹⁹

2.3. MRI data acquisition

The brain MRI scans were carried out at the Department of Radiology, Aalborg University, not longer than 1 month apart from the neurophysiological assessment. Imaging data were obtained on a 3 T MRI scanner (Signa HDxt; General Electrics, Milwaukee, WI, USA) equipped with an 8-channel phased-array head coil. For each participant, a high resolution 3-dimensional T1-weighted structural image was acquired, lasting 5.5 min. Following parameters were used for the structural scan: echo time 3.6 ms, repetition time 9.0 ms, 150 slices, the field of view 250 mm, flip angle 14 degrees, resolution 0.78×0.78 mm, matrix size 320×320 , slice thickness 1 mm, full head coverage, no gap. Based on this T1-weighted scan, volumetric alterations were reported by T.M. Hansen et al. 2021,⁴ from which the brain volumes were extracted for the below-mentioned explorative correlation analyses.

A DTI scan was conducted with the following parameters: repetition time 9000 ms, and the minimum echo time was used to achieve the highest image quality with the shortest time [range: 90.2–109.8 ms], 36 contiguous slices; field of view 307×307 mm, matrix size 128×128 , spatial resolution $1.88 \times 1.88 \times 2.6$ mm, directions 32.

In addition to the DTI scan, all participants completed proton magnetic resonance spectroscopy (H-MRS) in the parietal region, including the sensorimotor fiber tracts, to investigate white matter cerebral metabolites. The voxel of interest was positioned in the parietal cortex ($15 \times 15 \times 50$ mm) contralateral to the side of the dominant hand. These data have been published,¹⁹ in which the parietal *N*-acetylaspartate/creatinine (NAA/cre) ratio metabolite values were extracted for explorative correlation analyses.

2.4. DTI analysis

DTI data preprocessing and analysis were carried out using FMRIB Software Library (FSL) software, version 5.0.6 (fsl.fmrib.ox.ac.uk/fsl/fslwiki). In brief, the DTI scans were visually inspected, then FSL's brain extraction tool (BET) was used for brain extraction.²⁰ Next, FSL's eddy current correction was used to correct distortions and motion artifacts. Afterward, the FA and mean diffusivity maps were obtained by fitting a diffusion tensor model to each voxel using DTIfit.^{21,22}

Whole-brain TBSS analysis was performed at group level between

adults with T1DM and DSPN and healthy controls in FSL.^{21,22} The FMRIB58 FA 1 mm standard space template image was the registration target for each subject's FA image. Each subjects' FA images were then aligned into standard $1 \times 1 \times 1$ mm Montreal Neurological Institute 152 space using the nonlinear registration tool FNIRT, merged into a single 4D image. Next, the mean FA volume was estimated and thinned to generate the mean FA skeleton (representing the major white matter nerve fiber tracts). The mean FA skeleton was thresholded at 0.2. Each subject's aligned FA images were projected onto this skeleton, and the resulting skeletonized FA data were fed into the voxel-wise nonparametric permutation tests.²³ To investigate group differences in FA, a nonparametric permutation-based inference tool called randomize was used. The number of permutations was set to 5000, and the threshold-free cluster enhancement option to correct multiple comparisons was chosen. Voxel-wise statistics on skeletonized FA were conducted between groups using a series of unpaired two-sample *t*-tests. The resulting significant TFCE-corrected *P*-value statistical maps were thresholded at 0.99 (corresponding to $P = 0.01$).

Overall, TBSS-analyses resulted in whole-brain mean FA, whole-brain mean FA skeleton, whole-brain mean diffusivity, and regional voxel-wise FA statistical image.

2.5. Statistical analyses for demographic and clinical data

All statistical analyses for demographical data were performed in SPSS software. Unpaired *t*-tests were performed to examine whether groups differed in age, BMI, and brain metabolites, while a chi-squared test was used for sex. Univariate tests (one-way ANCOVA) were used to compare differences in brain volume between groups controlling for age and total intracranial volume as covariates.

Similarly, one-way ANCOVAs were used to compare differences in whole-brain FA skeleton values, whole-brain mean FA and mean diffusivity, and the significant regional clusters between groups adjusting for age and sex. For this purpose, age and sex were set as covariates and group as a fixed factor.

For the explorative analyses, Pearson correlation analyses and Spearman correlation analyses were carried out to examine the association between the whole-brain mean FA skeleton and a) other cerebral characteristics (gray and white matter volumes, parietal metabolites), and b) diabetes-specific clinical characteristics (nerve conduction measurements, HbA_{1c}, diabetes duration). Finally, analysis of variance (ANOVA) was performed to determine differences in whole-brain mean FA skeleton between the sub-groups with proliferative retinopathy/non-proliferative retinopathy and healthy controls.

The significance level for the comparisons was set to 0.05.

3. Results

3.1. Subjects

Two adults with T1DM did not complete the diffusion tensor imaging scans, leaving 46 adults with T1DM and confirmed DSPN (37 men, 49.9 ± 8.4 years) and 28 healthy controls (17 men, 49.9 ± 11.9 years) for the statistical analyses with complete MRI scans. Baseline demographics are provided in Table 1, where some of the data have previously been published in papers focusing on GLP-1 intervention (liraglutide) on neurophysiological measures,²⁴ gastrointestinal transit,²⁵ and cerebral metabolite alterations.¹⁹ The groups did not differ in sex and age, but BMI was increased in adults with T1DM as compared with healthy controls ($P < 0.001$). Brain volumes and MR-spectroscopy data derived from the previous papers are also presented in Table 1.

3.2. Whole-brain TBSS analyses

At the whole-brain level, TBSS analyses revealed group differences in whole-brain mean FA skeleton ($P_{\text{TFCE corrected}} = 0.018$), whole-brain

Table 1

Demographic and clinical characteristics of adults with type 1 diabetes mellitus (T1DM) and healthy controls.

	T1DM and DSPN (n = 46)	Healthy controls (n = 28)	P-value
Age (years)	49.9 (8.4)	46.9 (11.9)	0.9
Sex (M/F)	37/9	17/11	0.064
BMI (kg/m ²)	28.3 (4.5)	24.6 (2.6)	<0.001
Duration of diabetes (years)	32.1 (9.5)	–	
HbA _{1c} (mmol/mol)	66.0 (10.4)	–	
HbA _{1c} (%)	8.2 (0.9)	–	
Current glucose level (mmol/L)	8.5 (3.7)	–	
Age of onset (years)	17.8 (9.0)	–	
Sural amplitude (μV)	2.5 (2.3)	–	
Sural velocity (m/s)	37.9 (7.1)	–	
Tibial amplitude (mV)	3.9 (3.3)	–	
Tibial latency (ms)	4.5 (1.1)	–	
Retinopathy level, n (%)			
No retinopathy	0	–	
Non-proliferative retinopathy	31 (67.4)	–	
Proliferative retinopathy	15 (32.6)	–	
Pain level, n (%)			
Non-painful	35 (76.1)	–	
Painful DSPN	11 (23.9)	–	
Brain volumes*			
Gray matter volume (mL)	626.1 (4.1) 560.0 (4.9)	642.0 (5.2) 574.0 (6.3)	0.02 0.08
White matter volume (mL)			
Magnetic resonance spectroscopy	1.46 (0.15)	1.61 (0.20)	0.001
Parietal NAA/cre ratio			

Data are expressed as mean (standard deviation) unless otherwise stated. * adjusted for age, total intracranial volume and presented as mean \pm standard error of the mean. Group differences were tested by the independent *t*-test for continuous variables and the chi-square test for the categorical variable. Abbreviation: DSPN: Distal symmetric peripheral neuropathy. T1DM: type 1 diabetes mellitus. BMI: body mass index.

mean FA ($P_{\text{TFCE corrected}} = 0.026$), and whole-brain mean diffusivity ($P_{\text{TFCE corrected}} = 0.043$), see Table 2.

At the regional level, whole-brain voxel-wise analysis of the white matter skeleton showed that adults with T1DM and DSPN had reduced FA values in a large cluster with right retrolenticular internal capsule ($P_{\text{TFCE corrected}} < 0.001$) and in a large cluster with left inferior longitudinal fasciculus ($P_{\text{TFCE corrected}} < 0.001$). See Table 2. Both clusters also covered the following regions: left anterior thalamic radiation, left superior longitudinal fasciculus, right optic radiation, internal capsule, right anterior corona radiata, posterior thalamic radiation, and left corticospinal tract. See Figs. 1 and 2.

Regional FA was not increased in adults with T1DM and DSPN compared to healthy controls ($P > 0.05$).

3.3. White matter correlation to other cerebral characteristics

In the T1DM group, a positive association was observed between the parietal metabolite NAA/cre and the whole-brain mean FA skeleton ($r = 0.399$, $P = 0.006$). The two significant regional clusters shown in Table 2 were also positively associated to NAA/cre: FA of left inferior longitudinal fasciculus ($r = 0.414$, $P = 0.004$) and FA of the right retrolenticular internal capsule ($r = 0.385$, $P = 0.008$). See Table 3 and Fig. 3.

Moreover, for T1DM, positive associations were found between whole-brain mean FA skeleton and brain volumes (relative GMV: $r = 0.455$, $P = 0.002$ and relative WMV: $r = 0.692$, $P < 0.001$). The significant regional clusters (Table 2) were also positively associated to the brain volumes: FA of the left inferior longitudinal fasciculus (relative GMV: $r = 0.402$, $P = 0.006$ and relative WMV: $r = 0.622$, $P < 0.001$) and FA of the right retrolenticular internal capsule (relative GMV: $r = 0.410$,

Table 2
Detailed information FA alterations in adults with type 1 diabetes relative to healthy controls.

		Raw values		P-value	Adjusted mean (SE)		P-value
Whole-brain level		T1DM	Control		T1DM	Control	
FA skeleton		0.44 (0.03)	0.45 (0.02)	0.018	0.44 (0.004)	0.45 (0.005)	0.018
FA		0.27 (0.02)	0.28 (0.01)	0.037	0.27 (0.002)	0.28 (0.003)	0.026
MD (mm ² /s)		7.7 × 10 ⁻⁴ (7.0 × 10 ⁻⁵)	7.4 × 10 ⁻⁴ (3.0 × 10 ⁻⁵)	0.034	1.0 × 10 ⁻³ (7.4 × 10 ⁻⁶)	1.0 × 10 ⁻³ (9.5 × 10 ⁻⁶)	0.043
Regional level							
Cluster Index	Voxel size	MAX	MNI atlas coordinates (location of maximum Z-value) X Y Z			Corresponding white matter tract	
2	12,984	0.993	37	-29	0	Retrolenticular internal capsule r (optic radiation)	0.52 (0.003) 0.55 (0.002) <0.001
1	11,926	0.991	-24	-69	27	inferior longitudinal fasciculus L	0.53 (0.03) 0.56 (0.02) <0.001

Data are expressed as mean (standard deviation) unless otherwise stated. Group differences were tested by GLM univariate analysis (ANCOVA). Significant clusters of voxels were calculated by the tract-based spatial statistics analysis of FA values in adults with T1DM and confirmed distal symmetric peripheral neuropathy while adjusting for age and sex after the threshold free cluster enhancement (TFCE)-correction for multiple comparisons at P < 0.01. The anatomical locations of each cluster were determined based on John Hopkins University DT-based white matter atlas. MNI: Montreal Neurological Institute. L: left. R: Right. SD: standard deviation. SE.: Standard error. T1DM: type 1 diabetes mellitus. FA: fractional anisotropy. MD: mean diffusivity.

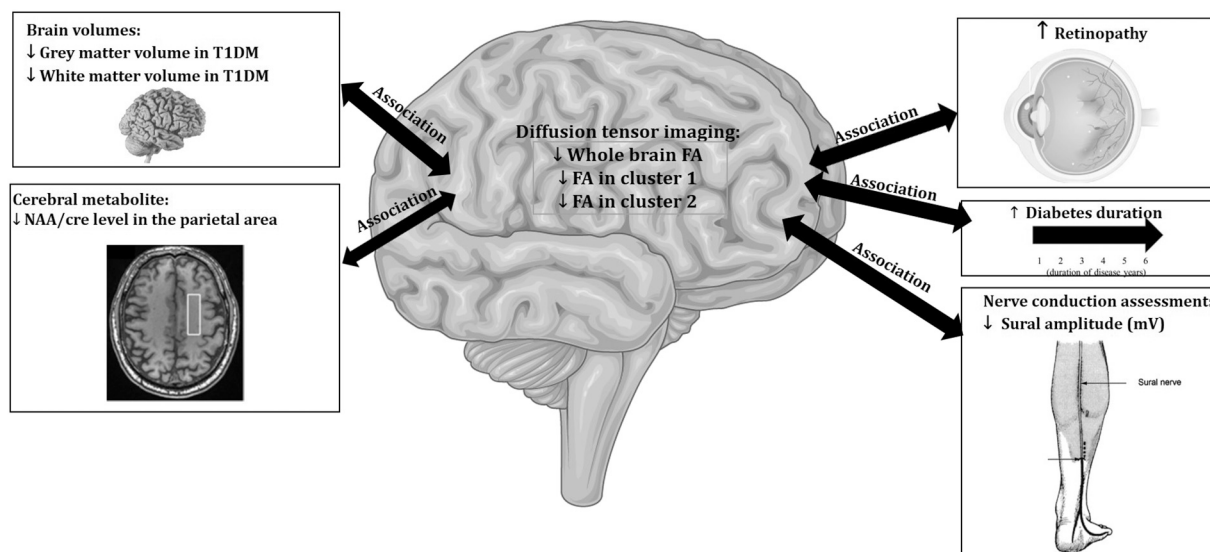


Fig. 1. Overview of the main findings. Cluster 1: left inferior longitudinal fasciculus. Cluster 2: right retrolenticular internal capsule.

P = 0.005 and relative WMV: r = 0.598, P < 0.001). See Table 3 and Fig. 1.

3.4. White matter correlation to the diabetes-specific clinical characteristics

The duration of diabetes was negatively associated with whole-brain mean FA skeleton (r = -0.495, P < 0.001), and the two significant regional clusters: FA of the left inferior longitudinal fasciculus (r = -0.484, P = 0.001) and FA of the right retrolenticular internal capsule (r = -0.486, P = 0.001). See Table 3.

Furthermore, there was a positive association between the whole-brain mean FA skeleton and the sural nerve amplitude (r = 0.296, P = 0.046). The two significant regional clusters were also associated with the sural nerve amplitude: FA of the left inferior longitudinal fasciculus

(r = 0.301 P = 0.042) and FA of the right retrolenticular internal capsule (r = 0.298 P = 0.044). No associations were found between the FA estimates and the tibial nerve measurements, sural nerve velocity, and HbA_{1c}. See Table 3.

Reduced whole-brain mean FA skeleton was observed in subgroups with proliferative retinopathy (mean ± SD: 0.42 ± 0.04) and non-proliferative retinopathy (0.44 ± 0.02) compared with healthy controls (0.45 ± 0.01) (overall P = 0.004), see Fig. 4 including post-hoc P-values.

Overview of all main findings is presented in Fig. 1.

4. Discussion

To the best of our knowledge, this is the first study in adults with T1DM and confirmed distal symmetric peripheral neuropathy aiming to

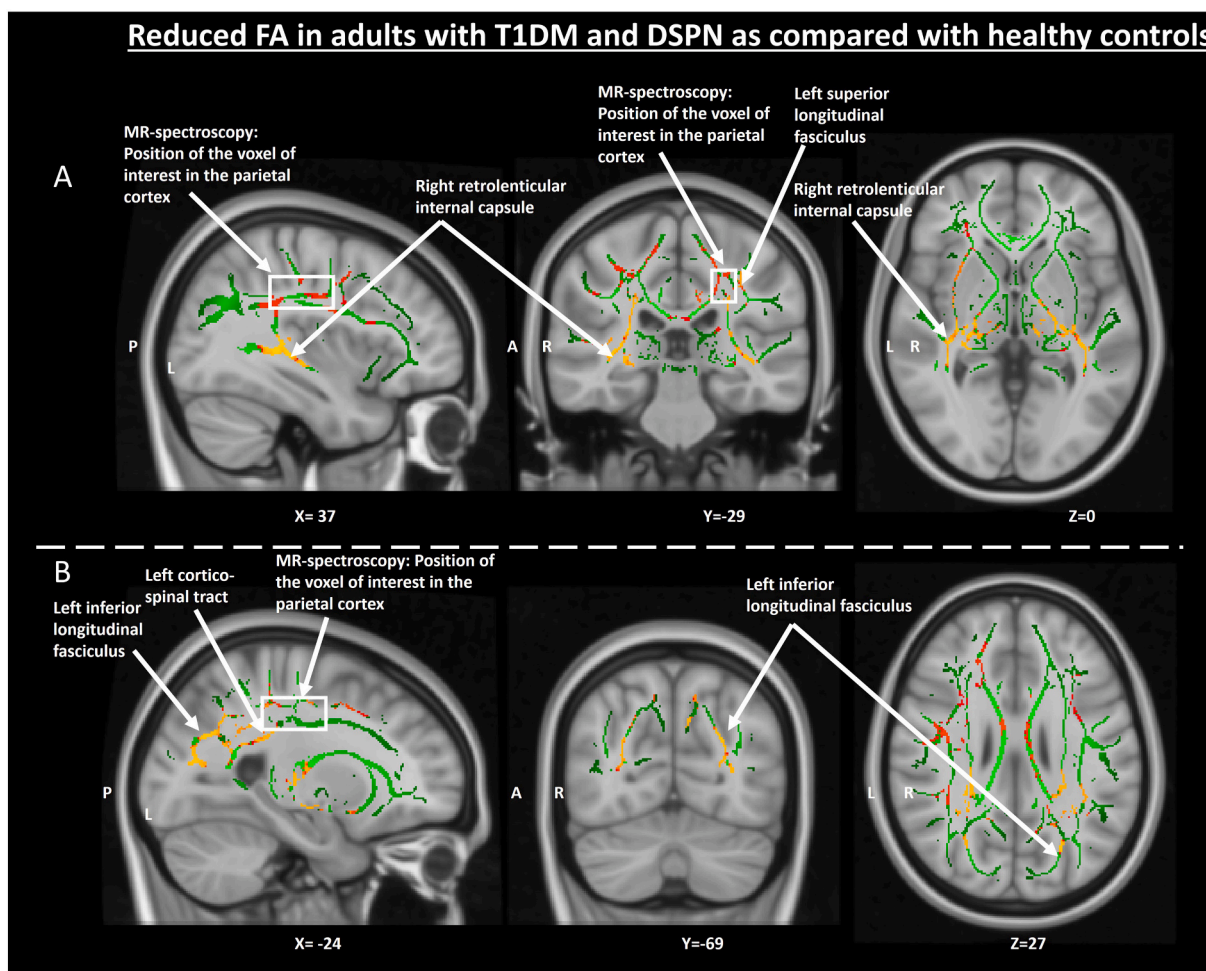


Fig. 2. Whole-brain tract-based spatial statistic (TBSS) analyses revealed significantly reduced FA in diabetes patients compared with healthy controls —representative slices from tract-based spatial statistical analysis, showing main white matter tract map with green. Red represented the white matter fiber bundle skeleton area with decreased fractional anisotropy value.

Table 3

Association between FA and a) other brain characteristics and 2) diabetes-specific clinical characteristics.

Correlation analyses	Whole-brain FA skeleton	FA - Right retrolenticular internal capsule	FA - left inferior longitudinal fasciculus
Cerebral metabolites and volumes			
Parietal NAA/cre*	R = 0.399 p = 0.006	R = 0.385 P = 0.008	R = 0.414 P = 0.004
Relative GMV	R = 0.455 P = 0.002	R = 0.410 P = 0.005	R = 0.402 P = 0.006
Relative WMV	R = 0.692 P < 0.001	R = 0.598 P < 0.001	R = 0.622 P < 0.001
Diabetes-specific clinical characteristics			
Duration of diabetes*	R = -0.495 P < 0.001	R = -0.486 P = 0.001	R = -0.484 P = 0.001
Sural nerve amplitude	R = 0.296 P = 0.046	R = 0.298 P = 0.044	R = 0.301 P = 0.042
HbA _{1c}	P > 0.05	P > 0.05	P > 0.05

FA: fractional anisotropy. GMV: gray matter volume. WMV: white matter volume. *Spearman correlation test – the remaining correlation analyses were based on Pearson correlation.

investigate microstructural white matter brain alterations in relation to other MRI-based cerebral findings and diabetes-specific clinical characteristics. Firstly, the study demonstrated global deficits in

microstructural white matter integrity measured by mean fractional anisotropy of the entire brain and relevant white matter regions. Secondly, associations between white matter integrity and parietal metabolite NAA/cre level and brain volumes were observed. Thirdly, positive associations were seen between white matter integrity and the sural nerve amplitude, and negative associations between white matter integrity and diabetes duration. Finally, reduced microstructural integrity was seen in proliferative retinopathy compared with non-proliferative retinopathy. These findings indicate that alterations of the cerebral white matter together with volumetric and metabolic brain changes may be essential in diabetic neuropathy, given that peripheral neuropathic complications seem to be accompanied by central neuropathy.

4.1. Whole-brain white matter alterations

Our findings are in line with previous studies reporting reduced FA in the anterior and posterior thalamic radiation, superior longitudinal fasciculus, optic radiation, internal capsule, anterior corona radiata, corticospinal tract, inferior longitudinal fasciculus, and retrolenticular internal capsule.⁹ Notably, as also found in our study, FA of the corticospinal tract has consistently been reported to decrease in both type-1 and type-2 diabetes,^{26,27} demonstrating decreased microstructural integrity, which is indicative of neuronal loss and/or demyelination. In general, the corticospinal tract is one of the major neuronal pathways controlling voluntary motor movements. A growing body of evidence

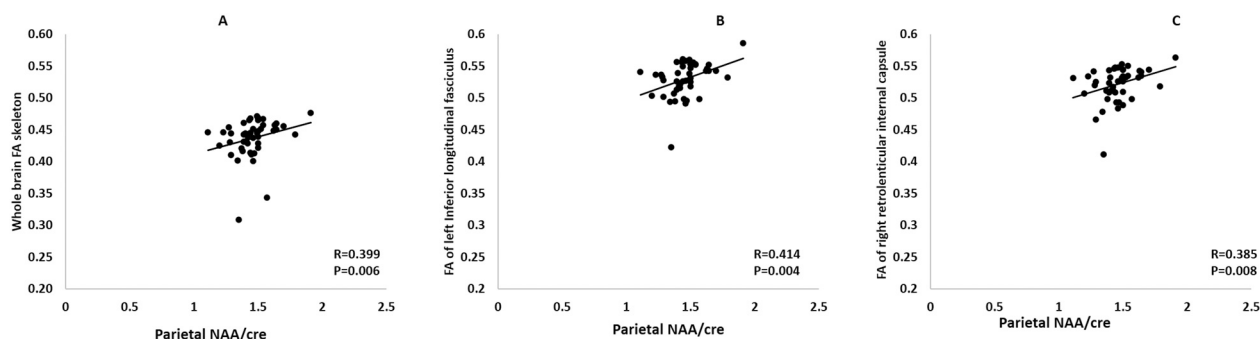


Fig. 3. The association between microstructural white matter changes and the cerebral characteristics in adults with T1DM.

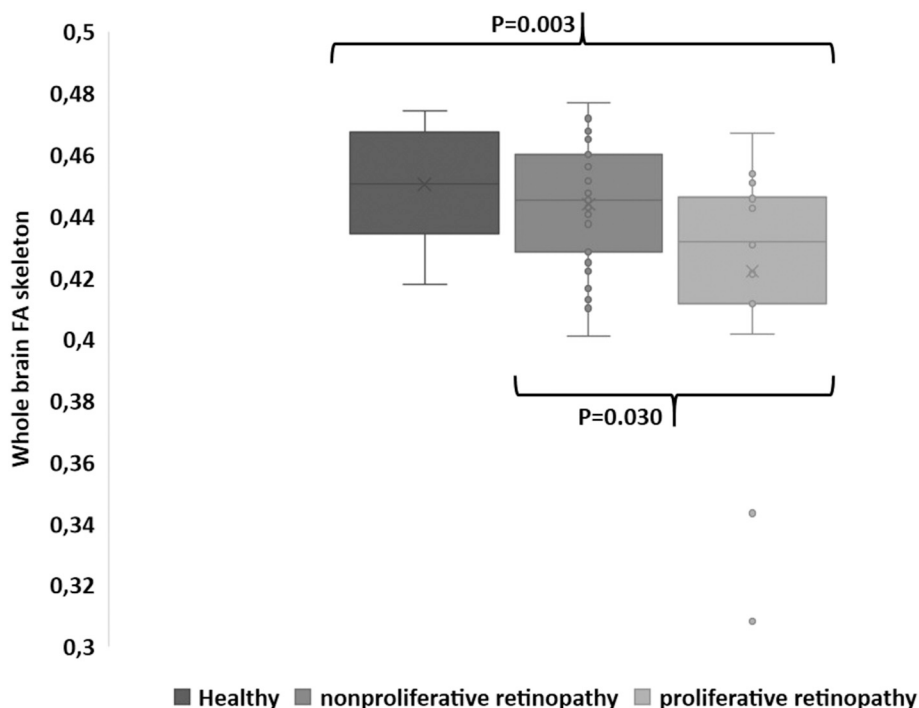


Fig. 4. Boxplot of whole-brain mean FA skeleton in healthy controls (n = 28), adults with diabetes, confirmed DSPN and non-proliferative retinopathy (n = 31), and adults with diabetes and DSPN and proliferative retinopathy (n = 15). The top and bottom of each box represent the first and the third quartiles (interquartile range), and the band inside the box represents the median value in each group.

shows that people with long-term diabetes and symmetrical polyneuropathy develop motor dysfunctions, i.e., increased risk of falling, altered gait and balance, and increased body sway. Thus, the axonal impairment in the corticospinal tract,²⁸ likely caused by hyperglycemic fluctuations, may exacerbate existing motor dysfunctions due combined negative impact of diabetes on peripheral nerves and sensorimotor regions in the brain.²⁷

To support our findings, previous studies have demonstrated changes in the optic radiation and superior longitudinal fasciculus in T1DM using the DTI technique.^{9,29} It is generally accepted that hyperglycemia is known to increase the risk of brain tissue damage or dysfunction by a metabolism-dependent cascade such as hyperglycemia-induced oxidative stress. Previous DTI studies suggested that the microstructural white matter alterations could alternatively be due to other glycolysis-independent biological factors that are changed simultaneously with severe hyperglycemic episodes.⁹ Thus, it would have strengthened the study if we had registered episodes of severe hyperglycemia, as this could have explained altered white matter integrity in optic radiation and superior longitudinal fasciculus. Likewise, the majority of DTI studies in T1DM have demonstrated white matter alterations in the

thalamocortical tract, whose primary function is to relay sensory inputs from the thalamus to the cerebral cortex,⁹ which is also in accordance with our findings. Taken together, we suggest that the involvement of the microstructural white matter is increasingly being involved as part of the DSPN. However, it remains unknown whether the brain alterations are independent or occur simultaneously with damage in the peripheral nerves. Also, to definitively conclude whether the microstructural white matter alterations are due to diabetes itself or to diabetic neuropathy, a diabetic group without DSPN should be included in the future studies. More research in larger longitudinal studies of improved phenotyped subgroups is needed to establish the causality.

4.2. Relationship between FA and cerebral characteristics

DTI combined with brain volume has been investigated in adults with type 2 diabetes, demonstrating white matter abnormalities in the corticospinal tract and thalamocortical projecting fibers with gray matter volume loss, suggesting impaired motor and somatosensory transmission.³⁰ Similarly, another study confirmed that the severity of microstructural changes correlated with volume loss in the occipital

cortex in T1DM.³¹ However, to our best knowledge, the combination of DTI and MR proton spectroscopy has mainly been overlooked¹ although, MR proton spectroscopy provides valuable information into neuronal function. To address this knowledge gap, we combined DTI and MR spectroscopy, revealing a strong correlation between parietal NAA/cre and FA values of 1) whole-brain skeleton, 2) microstructural white matter inferior longitudinal fasciculus, and 3) white matter retrolenticular internal capsule. The parietal spectroscopy region was located in the white matter, consisting of identifiable tracts such as posterior corona radiata, which previous studies showed lower FA in T1DM.³² N-acetylaspartate is thought to be a marker of neuronal functionality and density. At the same time, creatinine is involved in neuronal energy metabolism and tends to be maintained at a relatively constant level. Thus, creatinine is used as a convenient internal standard regarding ratio calculations. Our previous study showed that parietal metabolic alterations in the central nervous system in T1DM with DSPN were associated with peripheral neuropathy severity, grade of retinopathy, and disease duration, implicating that the parietal white matter is primarily involved in diabetes and diabetic neuropathy.⁶ A possible mechanism by which low NAA/cre level could relate to reduced FA draws from the observations of decreased levels of NAA, which have been interpreted to indicate neuronal/axonal loss or compromised neuronal metabolism. Thus, decreased NAA may be related to demyelination of the axons in the white matter of T1DM, given that NAA-derived acetate is required for some proportion of myelin lipid synthesis during axonal myelination.³³

4.3. Relationship between FA and diabetes-specific clinical characteristics

We found a correlation between the duration of diabetes and FA at both the whole-brain level and in the two significant regions (inferior longitudinal fasciculus and retrolenticular internal capsule). Our findings are comparable with Ahmed et al.,³² who reported an inverse relationship between the duration of disease and lower FA in the optic radiation. This suggests that the duration of diabetes and associated glycemic fluctuations (both long-term hypo- and hyperglycemic events that are not necessarily reflected in the 3 months measure (HbA_{1c})) influence the occurrence of microstructural white matter alterations.

Alterations of the sensory nerve amplitude have been shown to be the most sensitive and reliable predictor of DSPN.³⁰ Furthermore, in adults with T1DM and DSPN, our group has shown an association between NAA/cre in the parietal region (the white matter tracts, i.e., posterior corona radiata pass through) and thalamic structural loss and dysfunction.⁶ It is, however, unknown whether these measures are associated with the presence of DSPN, i.e., are central neuronal functionality a product of altered afferent transmission caused by DSPN, or is the presence of DSPN caused by altered central processing.^{6,34} Furthermore, it has been suggested that there is dynamic plasticity of the brain in patients suffering from DSPN, driven by neuropathic processes.³⁵ In support of these findings, the present study indicates that white matter integrity is correlated to peripheral sural nerve amplitude, suggesting a link between the severity of DSPN and loss of axonal density in the CNS. Overall, the association between the white matter changes in the brain and peripheral nerve damage supports the emerging recognition of diabetic neuropathy being, at least partly, a disease that affects the entire nervous system.

Our current findings in relation to retinopathy are comparable with other studies. We showed decreased FA of white matter tracts in the subgroup with proliferative retinopathy, characterized with neovascularization, as compared with the subgroup with non-proliferative retinopathy. Similarly, van Duinkerken et al. reported a widespread reduction of FA in T1DM patients with and without microangiopathy compared to healthy controls.³⁶ The presence of retinopathy is a marker for microangiopathy. It has been associated with the white matter tract changes but has also been associated with other structural changes in the brain, such as atrophy of the right inferior frontal gyrus and right

occipital lobe.^{9,14} Thus, it seems that microvascular complications may be linked to the impairment of white matter tracts.

4.4. Limitations

There are several limitations of this study. Firstly, this is a cross-sectional study, which does not allow interpretation of causation, and consequently, the associations such as between FA and the amplitude of the sural nerve need further clarification in future longitudinal studies. Secondly, there may have been selection bias, given that all adults with T1DM on average had >30 years of T1DM, which permits several glucose fluctuations compared to newly diagnosed patients. Thirdly, a control group with T1DM and without neuropathy should be investigated in future studies to identify more precisely the diabetes effect per se versus a generic effect of neuropathy on the brain. Furthermore, from our cross-sectional study, it is uncertain whether the observed brain changes are due to diabetes per se, the presence of diabetic neuropathy, microangiopathy leading to proliferative retinopathy or a combination of all the factors. Therefore, our findings should be interpreted with caution given that our results only have provided preliminary evidence of white matter microstructural changes in this particular group of individuals with diabetes and DSPN compared to healthy controls.

Fourthly, considering recent advances in DTI methodology, the use of a 3 T MRI scanner with 32 directions could have limited the data quality. Thus, future studies are encouraged to use more directions, i.e., 64 directions, to achieve better data quality. Lastly, it is important to bear in mind, that we did not correct for age and sex directly in the TBSS analysis, however, we did adjust for those relevant covariates after performing the TBSS analyses using ANCOVA, which is also a recognized method used in several studies.^{37–39} For the purpose of transparency, the unadjusted values are also presented in Table 2. Also, the explorative correlation analyses should be interpreted cautiously due to small sample size. Indeed, a larger sample size could be preferable to obtain more robust findings and multivariate analyses exploring the relative contribution of the different factors driving the brain FA changes. Taken together, with these limitations, it is hard to conclude whether the brain findings are related to diabetes per se, the presence of diabetic neuropathy, microangiopathy, or a combination of both diabetic neuropathy and microangiopathy, although this hypothesis-generating study provides explorative evidence for future research.

5. Conclusions

Our study is novel in adults with T1DM and confirmed distal symmetric peripheral neuropathy, and we were able to investigate microstructural white matter tracts in combination with peripheral nerve conduction testing and multiple MRI techniques such as volumetric brain and magnetic resonance spectroscopy. Our findings have provided preliminary evidence revealing the multifactorial and complex synergistic mechanisms underlying T1DM DSPN, which concomitantly involve white matter and neuronal metabolic alterations in the central nervous system as a central feature of diabetic neuropathy.

Sources of financial support

The work was supported by the Novo Nordisk Scandinavia AS: Empowering Industry and Research EIR Northern Jutland. C.B. received funding from the Talent Programme, Aalborg University. JAM was supported by the Independent Research Fund Denmark (DFF-7016-00073).

CRediT authorship contribution statement

Study design and original idea: AMD, CB, TMH, BB, and JBF. Data collection: JBF, CB, JAM and TMH. Drafting of the manuscript: JAM, JBF, BB, and CB. AMD, JAM, CB, and JBF contributed to the

manuscript's literature search preparation and critical revisions regarding important intellectual content. All authors have approved the final manuscript.

Declaration of competing interest

The authors declare no conflicts of interest

Acknowledgments

K.K. Jensen, Department of Radiology, Aalborg University Hospital, Aalborg Denmark, is acknowledged for his assistance in MRI data collection.

References

- Tesfaye S, Sloan G. Involvement of the central nervous system in diabetic distal symmetrical polyneuropathy. *J Xiangya Med*. 2021;6:2020–2022. <https://doi.org/10.21037/jxym.2020.02.03>.
- Nissen TD, Meldgaard T, Nedergaard RW, et al. Peripheral, synaptic and central neuronal transmission is affected in type 1 diabetes. *J Diabetes Complications*. 2020; 34, 107614. <https://doi.org/10.1016/j.jdiacomp.2020.107614>.
- Drewes AM, Søfteland E, Dimcevski G, et al. Brain changes in diabetes mellitus patients with gastrointestinal symptoms. *World J Diabetes*. 2016;7:14–26. <https://doi.org/10.4239/wjd.v7.i2.14>.
- Hansen TM, Muthulingam JA, Brock B, et al. Reduced gray matter brain volume and cortical thickness in adults with type 1 diabetes and neuropathy. *Neurosci Res*. 2022; 176:66–72. <https://doi.org/10.1016/j.neures.2021.10.002>.
- Selvarajah D, Wilkinson ID, Maxwell M, et al. Magnetic resonance neuroimaging study of brain structural differences in diabetic peripheral neuropathy. *Diabetes Care*. 2019;33:323–328. <https://doi.org/10.2337/dc13-2610>.
- Hansen TM, Brock B, Juhl A, et al. Brain spectroscopy reveals that N-acetylaspartate is associated to peripheral sensorimotor neuropathy in type 1 diabetes. *J Diabetes Complications*. 2019;33:323–328. <https://doi.org/10.1016/j.jdiacomp.2018.12.016>.
- Hansen TM, Frokjær JB, Selvarajah D, et al. Reduced thalamic volume and metabolites in type 1 diabetes with polyneuropathy. *Exp Clin Endocrinol Diabetes*. Published online. 2022;130:327–334. <https://doi.org/10.1055/a-1347-2579>.
- Selvarajah D, Wilkinson ID, Emery CJ, et al. Thalamic neuronal dysfunction and chronic sensorimotor distal symmetrical polyneuropathy in patients with type 1 diabetes mellitus. *Diabetologia*. 2008;51:2088–2092. <https://doi.org/10.1007/s00125-008-1139-0>.
- Alotaibi A, Tench C, Stevenson R, et al. Investigating brain microstructural alterations in type 1 and type 2 diabetes using diffusion tensor imaging: a systematic review. *Brain Sci*. 2021;11:1–22. <https://doi.org/10.3390/brainsci11020140>.
- Tournier J-D, Mori S, Leemans A, Morgan RH, Reson M, Author M. Diffusion tensor imaging and beyond NIH public access author manuscript. *Magn Reson Med*. 2011; 65:1532–1556. <https://doi.org/10.1002/mrm.22924>.
- Boretius S, Escher A, Dallenga T, et al. Assessment of lesion pathology in a new animal model of MS by multiparametric MRI and DTI. *Neuroimage*. 2012;59: 2678–2688. <https://doi.org/10.1016/j.neuroimage.2011.08.051>.
- Zhang Y, Burock MA. Diffusion tensor imaging in Parkinson's disease and parkinsonian syndrome: a systematic review. *Front Neurol*. 2020;11:1091. <https://doi.org/10.3389/fneur.2020.531993>.
- Musen G, Lyoo IK, Sparks CR, et al. Effects of type 1 diabetes on gray matter density as measured by voxel-based morphometry. *Diabetes*. 2006;55:326–333. <https://doi.org/10.2337/diabetes.55.02.06.db05-0520>.
- Wessels AM, Simsek S, Remijnse PL, et al. Voxel-based morphometry demonstrates reduced grey matter density on brain MRI in patients with diabetic retinopathy. *Diabetologia*. 2006;49:2474–2480. <https://doi.org/10.1007/s00125-006-0283-7>.
- Selvarajah D, Wilkinson ID, Gandhi R, Griffiths PD, Tesfaye S. Microvascular perfusion abnormalities of the thalamus in painful but not painless diabetic polyneuropathy: a clue to the pathogenesis of pain in type 1 diabetes. *Diabetes Care*. 2011;34:718–720. <https://doi.org/10.2337/dc10-1550>.
- Said G, Baudoin D, Toyooka K. Sensory loss, pains, motor deficit and axonal regeneration in length-dependent diabetic polyneuropathy. *J Neurol*. 2008;255: 1693. <https://doi.org/10.1007/s00415-008-0999-z>.
- Selvarajah D, Wilkinson ID, Davies J, Gandhi R, Tesfaye S. Central nervous system involvement in diabetic neuropathy. *Curr Diab Rep*. 2011;11:310–322. <https://doi.org/10.1007/s11892-011-0205-z>.
- Tesfaye S, Boulton AJM, Dyck PJ, et al. Diabetic neuropathies: update on definitions, diagnostic criteria, estimation of severity, and treatments. *Diabetes Care*. 2010;33. <https://doi.org/10.2337/dc10-1303>, 2285 LP - 2293.
- Hansen TM, Brock B, Juhl A, et al. Brain spectroscopy reveals that N-acetylaspartate is associated to peripheral sensorimotor neuropathy in type 1 diabetes. *J Diabetes Complications*. 2019;33:323–328. <https://doi.org/10.1016/j.jdiacomp.2018.12.016>.
- Smith SM. Fast robust automated brain extraction. *Hum Brain Mapp*. 2002;17: 143–155. <https://doi.org/10.1002/hbm.10062>.
- Smith SM, Smith SM, Johansen-berg H, et al. Acquisition and voxelwise analysis of multi-subject diffusion data with tract-based spatial statistics. *Nat Protoc*. 2007;2: 499–503. <https://doi.org/10.1038/nprot.2007.45>.
- Smith SM, Jenkinson M, Johansen-Berg H, et al. Tract-based spatial statistics: voxelwise analysis of multi-subject diffusion data. *Neuroimage*. 2006;31:1487–1505. <https://doi.org/10.1016/j.neuroimage.2006.02.024>.
- Winkler AM, Ridgway GR, Webster MA, Smith SM, Nichols TE. Permutation inference for the general linear model. *Neuroimage*. 2014;92:381–397. <https://doi.org/10.1016/j.neuroimage.2014.01.060>.
- Brock C, Hansen CS, Karmisholt J, et al. Liraglutide treatment reduced interleukin-6 in adults with type 1 diabetes but did not improve established autonomic or polyneuropathy. *Br J Clin Pharmacol*. 2019;85:2512–2523. <https://doi.org/10.1111/bcp.14063>.
- Farmer AD, Pedersen AG, Brock B, et al. Type 1 diabetic patients with peripheral neuropathy have pan-enteric prolongation of gastrointestinal transit times and an altered caecal pH profile. *Diabetologia*. 2017;60:709–718. <https://doi.org/10.1007/s00125-016-4199-6>.
- van Bloemendaal L, Ijzerman RG, ten Kulve JS, et al. Alterations in white matter volume and integrity in obesity and type 2 diabetes. *Metab Brain Dis*. 2016;31: 621–629. <https://doi.org/10.1007/s11011-016-9792-3>.
- Ferris JK, Inglis JT, Madden KM, Boyd LA. Brain and body: a review of central nervous system contributions to movement impairments in diabetes. *Diabetes*. 2020; 69:3–11. <https://doi.org/10.2337/db19-0321>.
- Muramatsu K. Diabetes mellitus-related dysfunction of the motor system. *Int J Mol Sci*. 2020;21:7485. <https://doi.org/10.3390/ijms21207485>.
- Franc DT, Kodl CT, Mueller BA, Muetzel RL, Lim KO, Seaquist ER. High connectivity between reduced cortical thickness and disrupted white matter tracts in long-standing type 1 diabetes. *Diabetes*. 2011;60:315–319. <https://doi.org/10.2337/db10-0598>.
- Zhang Y, Qu M, Yi X, et al. Sensorimotor and pain-related alterations of the gray matter and white matter in type 2 diabetic patients with peripheral neuropathy. *Hum Brain Mapp*. 2020;41:710–725. <https://doi.org/10.1002/hbm.24834>.
- Kodl CT, Franc DT, Rao JP, et al. Diffusion tensor imaging identifies deficits in white matter microstructure in subjects with type 1 diabetes that correlate with reduced neurocognitive function. *Diabetes*. 2008;57:3083–3089. <https://doi.org/10.2337/db08-0724>.
- Ahmed HH, Azzam HME, Farid SM, Abdelmaksoud AA, Rassem IMM. Neurocognitive profile and diffusion tensor imaging in pediatric patients with type 1 diabetes mellitus. *Middle East Curr Psychiatry*. 2014;21:205–211. <https://doi.org/10.1097/01.XME.0000452987.08165.69>.
- Moffett JR, Ross B, Arun P, Madhavarao CN, Nambodiri AMA. N-acetylaspartate in the CNS: from neurodiagnostics to neurobiology. *Prog Neurobiol*. 2007;81:89–131. <https://doi.org/10.1016/j.pneurobio.2006.12.003>.
- Tesfaye S, Selvarajah D, Gandhi R, et al. Diabetic peripheral neuropathy may not be as its name suggests: evidence from magnetic resonance imaging. *Pain*. 2016;157: S72–S80. <https://doi.org/10.1097/j.pain.0000000000000465>.
- Selvarajah D, Wilkinson ID, Fang F, et al. Structural and functional abnormalities of the primary somatosensory cortex in diabetic peripheral neuropathy: a multimodal MRI study. *Diabetes*. 2019;68:796–806. <https://doi.org/10.2337/db18-0509>.
- Van Duinkerken E, Schoonheim MM, Ijzerman RG, et al. Diffusion tensor imaging in type 1 diabetes: decreased white matter integrity relates to cognitive functions. *Diabetologia*. 2012;55:1218–1220. <https://doi.org/10.1007/s00125-012-2488-2>.
- Hudkins M, O'Neill J, Tobias MC, Bartzokis G, London ED. Cigarette smoking and white matter microstructure. *Psychopharmacology (Berl)*. 2012;221:285–295. <https://doi.org/10.1007/s00213-011-2621-9>.
- Cui Y, Tang T-Y, Lu C-Q, et al. Abnormal cingulum bundle induced by type 2 diabetes mellitus: a diffusion tensor tractography study. *Front Aging Neurosci*. 2020;12: 594198. <https://www.frontiersin.org/article/10.3389/fnagi.2020.594198>.
- Muthulingam J, Haas S, Hansen TM, et al. Microstructural white matter brain abnormalities in patients with idiopathic fecal incontinence. *Neurogastroenterol Motil*. 2018;30. <https://doi.org/10.1111/nmo.13164>.