



**AALBORG UNIVERSITY**  
DENMARK

**Aalborg Universitet**

## **Prolonged APTT and autoimmune overt hypothyroidism identified postpartum: a case report**

Lundgaard, Maja Hjelm ; Carlé, Allan; Christiansen, Ulla Birgitte; Sørensen, Anne; Kristensen, Søren Risom; Andersen, Stine Linding

*Published in:*  
European Thyroid Journal

*DOI (link to publication from Publisher):*  
[10.1530/ETJ-22-0109](https://doi.org/10.1530/ETJ-22-0109)

*Creative Commons License*  
CC BY-NC-ND 4.0

*Publication date:*  
2022

*Document Version*  
Publisher's PDF, also known as Version of record

[Link to publication from Aalborg University](#)

*Citation for published version (APA):*  
Lundgaard, M. H., Carlé, A., Christiansen, U. B., Sørensen, A., Kristensen, S. R., & Andersen, S. L. (2022). Prolonged APTT and autoimmune overt hypothyroidism identified postpartum: a case report. *European Thyroid Journal*, 11(4), [e220109]. <https://doi.org/10.1530/ETJ-22-0109>

### **General rights**

Copyright and moral rights for the publications made accessible in the public portal are retained by the authors and/or other copyright owners and it is a condition of accessing publications that users recognise and abide by the legal requirements associated with these rights.

- Users may download and print one copy of any publication from the public portal for the purpose of private study or research.
- You may not further distribute the material or use it for any profit-making activity or commercial gain
- You may freely distribute the URL identifying the publication in the public portal -

### **Take down policy**

If you believe that this document breaches copyright please contact us at [vbn@aub.aau.dk](mailto:vbn@aub.aau.dk) providing details, and we will remove access to the work immediately and investigate your claim.

## CASE REPORT

# Prolonged APTT and autoimmune overt hypothyroidism identified postpartum: a case report

Maja Hjelm Lundgaard<sup>1</sup>, Allan Carlé<sup>2,3</sup>, Ulla Birgitte Christiansen<sup>4</sup>, Anne Sørensen<sup>2,4</sup>, Søren Risom Kristensen<sup>1,2</sup> and Stine Linding Andersen<sup>1,2</sup>

<sup>1</sup>Department of Clinical Biochemistry, Aalborg University Hospital, Aalborg, Denmark

<sup>2</sup>Department of Clinical Medicine, Aalborg University, Aalborg, Denmark

<sup>3</sup>Department of Endocrinology, Aalborg University Hospital, Aalborg, Denmark

<sup>4</sup>Department of Gynaecology and Obstetrics, Aalborg University Hospital, Aalborg, Denmark

Correspondence should be addressed to S L Andersen: [stine.a@rn.dk](mailto:stine.a@rn.dk)

## Abstract

**Introduction:** Thyroid disorders have been linked to abnormalities in the coagulation system, and a hypocoagulant state has been proposed in hypothyroidism. The assessment of thyroid function is, however, not routinely recommended as part of the assessment for coagulation disorders.

**Case presentation:** We present a 32-year-old woman who had no history of thyroid disease and who recently gave birth preterm because of severe preeclampsia and intrauterine growth restriction. Due to severe placental dysfunction, she underwent a routine biochemical assessment of the coagulation system 6 months postpartum, and a prolonged activated partial thromboplastin time (APTT) (43 s) was identified along with a low level of coagulation factor VIII (0.44 IU/mL), and a low level of von Willebrand factor (vWF) antigen (0.35 IU/mL), vWF activity (0.38 IU/mL) as well as reduced generation of thrombin. The assessment of thyroid function in the patient identified autoimmune, overt hypothyroidism with a thyroid-stimulating hormone (TSH) concentration of 139 mIU/L, low levels of the peripheral thyroid hormones (total thyroxine: 43 nmol/L, total triiodothyronine: 0.9 nmol/L), and high levels of thyroid peroxidase antibodies (296 U/mL) as well as thyroglobulin antibodies (927 U/mL).

**Conclusion:** In this case, prolonged APTT provided a diagnostic clue for the assessment of thyroid function in a young woman with a recent history of severe placental dysfunction. The identification of autoimmune, overt hypothyroidism emphasizes that measurement of TSH may be of clinical importance in cases of unexplained prolonged APTT or other biochemical signs of abnormalities in the coagulation system.

## Key Words

- ▶ coagulation
- ▶ placenta
- ▶ thyroid
- ▶ TSH
- ▶ von Willebrand factor

## Established facts

- Hypothyroidism has been associated with alterations of the coagulation system suggesting a hypocoagulant state.
- At present, measurement of thyroid-stimulating hormone is not routinely recommended as part of the assessment for coagulation disorders.

## Novel insights

- In this case, biochemical assessment of the coagulation system was routinely performed following a pregnancy complicated by severe placental dysfunction.
- Overt hypothyroidism of autoimmune origin was identified secondary to prolonged activated partial thromboplastin time (APTT) postpartum along with low levels of coagulation factor VIII, von Willebrand factor, and thrombin generation.
- Measurement of thyroid-stimulating hormone may be considered in cases of unexplained prolonged APTT.

## Introduction

A possible link between thyroid disease and abnormalities of the coagulation system has long been considered (1). From some of the earliest observations in the 1960s and later literature reviews, it generally appears that hyperthyroidism and hypothyroidism show opposite associations with the coagulation system. Thus, hyperthyroidism has predominantly been associated with a hypercoagulant state and a higher risk of venous thromboembolic events, whereas hypothyroidism has been associated with a hypocoagulant state and a higher risk of bleeding episodes (1, 2, 3, 4). Concerning hypothyroidism and the impact of low levels of thyroid hormones, original investigations have mainly described prolonged activated partial thromboplastin time (APTT) along with a decrease in the level of coagulation factor VIII and von Willebrand factor (vWF) (5, 6). Particularly, a higher prevalence of acquired von Willebrand disease (AvWD) in these patients has been reported and discussed (7). Despite these observational findings indicating an association between thyroid disease and abnormalities of the coagulation system, no routine recommendations exist on the assessment of thyroid function as part of testing for thrombophilia or assessment of bleeding disorders (8, 9). Likewise, it is not generally recommended to assess coagulation function in patients with thyroid disease (10, 11).

We present a young, female patient who was diagnosed with severe overt hypothyroidism postpartum. The diagnostic clue for the assessment of thyroid function in this patient came across because unexplained prolonged APTT was identified during the testing for thrombophilia after severe pregnancy complications.

## Case presentation

A 32-year-old woman was referred to routine outpatient testing for thrombophilia 6 months postpartum in the Department of Clinical Biochemistry because she had

suffered from severe placental dysfunction in her recent pregnancy. Her reproductive history revealed that she was gravida 3, para 2. Thus, she recently gave birth to her second child and had a history of one previous uncomplicated pregnancy and one spontaneous abortion. She had no history of thyroid or other autoimmune diseases, and she received no current medication. She took iron supplements and multivitamins. In her family, two cases of goiter were reported among grandparents, but no other family cases of thyroid disease were described, and she had no family history of venous thrombosis or bleeding disorders. She was of normal weight with a BMI of 22 kg/m<sup>2</sup>.

In the most recent pregnancy, she perceived a decrease in fetal movement in the 35th week of gestation (34 full weeks + 6 days) without any other obvious signs of disease. She was referred to the Department of Obstetrics where she was found to have severe hypertension and proteinuria consistent with a diagnosis of severe preeclampsia. Ultrasound examination revealed pronounced fetal growth restriction (36% below the expected for gestational age), normal fetal movements, normal fetal Doppler flow measurements, and normal amount of amniotic fluid. Due to severe hypertension, resistant to antihypertensive treatment, and the development of maternal symptoms of preeclampsia, she underwent a subacute caesarean section the following day. The surgical procedure was uncomplicated and a healthy liveborn boy was delivered with a birth weight of 1810 g. There was no excessive postpartum bleeding. Placental dysfunction was confirmed by the postnatal histological examination demonstrating maternal and fetal vascular malperfusion and abnormal low weight.

Maternal testing for thrombophilia 6 months postpartum identified no biochemical signs of hereditary thrombophilia (Table 1) and no elevated titers of antiphospholipid antibodies, including beta-2-Glycoprotein 1-Ab (IgM and IgG), Cardiolipin-Ab (IgM and IgG), and lupus anticoagulant. However, the APTT turned out to be prolonged (Table 1). Additional analyses

were performed in the local laboratory to explain the finding of a prolonged APTT. A mixing study of patient plasma and normal plasma led to a normalization of APTT indicating a coagulation factor deficiency and excluding the presence of lupus anticoagulant in the patient or antibodies as part of acquired hemophilia. In line with this conclusion, subsequent analysis revealed a decreased level of coagulation factor VIII (Table 1).

Since the patient had no history or ongoing symptoms of bleeding, the biochemical findings were unexpected. Considering the literature on the association between thyroid disease and disorders of the coagulation system (4), we speculated on any underlying thyroid disease in the patient. She never previously had thyroid function tested, and the decision was made to extend the biochemical evaluation with the measurement of thyroid-stimulating hormone (TSH). Results revealed an elevated plasma level of TSH (>100 mIU/L). Simultaneous measurements of total thyroxine (T4) as well as total triiodothyronine (T3) showed that the plasma levels of both peripheral thyroid hormones in the patient were low (Table 2). The findings were compatible with a diagnosis of severe hypothyroidism. The patient was immediately referred to the Department of Endocrinology and treatment with Levothyroxine was initiated (50 µg per day). The endocrine examination indicated that the patient in retrospect had symptoms of tiredness and hair loss during the last 3 months, but no other specific symptoms or obvious signs of hypothyroidism and no clinical signs of goiter. Assessment of thyroid autoantibodies showed markedly elevated thyroid peroxidase antibodies (TPO-Ab) as well as elevated thyroglobulin antibodies (Tg-Ab) (Table 2) indicating that the etiology of hypothyroidism in this patient was most likely autoimmune. TSH-receptor antibodies were not detected in the patient (Table 2).

After a diagnosis of hypothyroidism was made, a link between undiagnosed and untreated severe thyroid function abnormality in the patient and the abnormalities observed in the coagulation system was hypothesized. To extend these findings, measurements of vWF and thrombin generation were performed using stored plasma from the initial assessment. These analyses discovered low concentration and activity of vWF in the patient which combined with the low level of coagulation factor VIII indicated a hypocoagulant state. Furthermore, results of the thrombin generation assay showed an endogenous thrombin potential (ETP) at the lower end and the peak height was low (Table 1) indicating a reduced generation of thrombin and a hypocoagulant state.

At follow-up 3 and 6 months after the diagnosis of hypothyroidism was made, treatment with levothyroxine (50 µg per day) was unaltered. Biochemical assessment revealed improvement in patient thyroid function and TSH as well as T4 and T3 were within the reference ranges at 6 months follow-up (Table 2). The coagulation parameters (APTT, vWf, and coagulation factor VIII) improved during the follow-up (Table 1). Thrombin generation also increased from baseline to 6 months follow-up (Fig. 1) with normalization of ETP as well as the peak height (Table 1).

Written informed consent for publication of the clinical detail was obtained from the patient.

## Discussion

This case illustrates the diagnosis of autoimmune, overt hypothyroidism in a young woman identified postpartum because the biochemical finding of prolonged APTT provided a diagnostic clue to assess her thyroid function. The biochemical findings which suggest a hypocoagulant state in the patient are compatible with previous reports (1, 2, 3, 4). We specifically observed a prolonged APTT and low levels of coagulation factor VIII and vWF as well as reduced generation of thrombin at the time of diagnosis of severe hypothyroidism. The patient had no symptoms or signs of a bleeding disorder, but coagulation testing was routinely performed 6 months postpartum because she had suffered from severe placental dysfunction in her recent pregnancy. Our patient had markedly elevated TSH at diagnosis consistent with overt hypothyroidism at a young age (12). Gullu *et al.* followed 15 patients with overt and subclinical hypothyroidism, respectively, and found that the association with the factors of the coagulation system depends on the degree of hypothyroidism (5). Thus, overt hypothyroidism showed the most pronounced prolongation of APTT and the most pronounced decrease in coagulation factor VIII and vWF compared to healthy controls. Similarly, but less pronounced, alterations were seen in cases of subclinical hypothyroidism. Irrespective of the severity of hypothyroidism or the degree of alterations in the coagulation system, treatment with levothyroxine improved the coagulation parameters in both groups in this study when evaluated 3 months after euthyroidism (5). Stuijver *et al.* consecutively included 48 patients with overt hypothyroidism and found prolonged APTT and low levels of vWf as well as reduced generation of thrombin at baseline which was restored with euthyroidism during a median follow-up of 5 months (6). We repeated the measurement

**Table 1** Biochemical assessment of the coagulation system.

	Unit	Reference interval	Patient results			Change (%)
			Initial	3 months	6 months	Initial to 6 months
Activated partial thromboplastin time <sup>a</sup> (APTT)	s	22–38	43	39	39	–9.3
International normalized ratio <sup>a</sup> (INR)		<1.2	1.0	–	–	–
Fibrinogen <sup>a</sup>	µmol/L	5.0–11	7.0	–	–	–
Fibrin D-dimer <sup>a</sup>	mg FEU/L	<0.50	0.54	–	–	–
Antithrombin (enz.) <sup>a,b</sup>	IU/mL	0.80–1.20	1.12	–	–	–
Protein C (enz.) <sup>a,b</sup>	IU/mL	0.70–1.40	1.17	–	–	–
Protein S, free antigen (imm.) <sup>a,c</sup>	IU/mL	0.55–1.20	0.86	–	–	–
Coagulation factor VIII <sup>a,d</sup>	IU/mL	0.60–1.60	0.44	0.51	0.52	+18.2
von Willebrand factor (imm.) <sup>c,e</sup>	IU/mL	0.55–1.40	0.35	0.37	0.42	+20.0
von Willebrand factor (GPIbA) <sup>e,f</sup>	IU/mL	0.47–1.59	0.38	0.38	0.42	+10.5
Thrombin generation <sup>g</sup>						
Endogenous thrombin potential (ETP)	nM*min	928–1640	949	–	1179	+24.2
Peak height	nM	120–306	94	–	141	+50.0

<sup>a</sup>Citrate plasma samples analyzed using ACL TOP 500/550 (Instrumentation Laboratory, Werfen, North America). <sup>b</sup>Enz.: Enzymatic activity assays (Instrumentation Laboratory, Werfen, North America). <sup>c</sup>Imm.: Immunological assays (Instrumentation Laboratory, Werfen, North America). <sup>d</sup>Clot-based method (Instrumentation Laboratory, Werfen, North America). <sup>e</sup>Citrate plasma sample analyzed using Sysmex CS 2100i (Siemens Healthineers, Marburg, Germany). <sup>f</sup>vWF:GPIbA activity assay (Siemens Healthineers, Marburg, Germany). <sup>g</sup>Thrombin Generation Assay using ST Genesia (Diagnostica Stago, Asnieres sur Seine, France).

of APTT, coagulation factor VIII, and vWF in our patient after 3 and 6 months of levothyroxine treatment, and TSH was within the reference range at 6 months follow-up. Changes toward normalization were seen for APTT, factor VIII, and vWF. Furthermore, the improvement of the coagulation status with treatment was emphasized by the investigation of thrombin generation (13) which increased substantially during 6 months of follow-up. Overall, the relative changes seen in the coagulation parameters during follow-up in our patient were at the same magnitude as previously described in a cohort of patients in the study by Stuijver *et al.* (6). Coagulation factor VIII as well as vWF remained below the lower reference limit in our patient even after 6 months of follow-up. It is possible that a longer period of euthyroidism is needed for complete restoration of the coagulation parameters. Notably, general lower levels of coagulations factor VIII as well as vWF are described in individuals with ABO blood group type O (14),

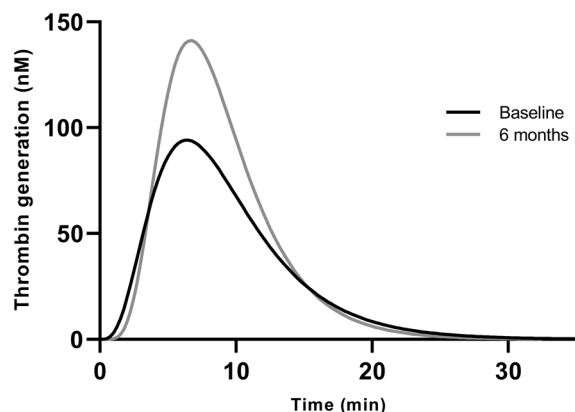
which was the case in our patient. Thus, the individual patient level for these parameters may be constitutively below the population reference limit. In line with our patient, the patients in the study by Gullu *et al.* had no symptoms of bleeding despite biochemical abnormalities of the coagulation analyses (5). However, in a systematic review on the association between hypothyroidism and AvWD, mucocutaneous bleeding episodes were described in a substantial number of patients (7).

Our patient was diagnosed with hypothyroidism 6 months postpartum and she never previously had her thyroid function tested. The postpartum period is a known risk factor for the onset of thyroid disease and the risk increases with increasing parity (15). The patient had elevated levels of TPO-Ab and Tg-Ab, which suggest an autoimmune origin of hypothyroidism developed. Notably, no obvious signs of hypothyroidism were reported, and general hypothyroid symptoms such as tiredness

**Table 2** Biochemical assessment of thyroid function.

	Unit	Reference interval	Patient results		
			Initial	3 months	6 months
Thyroid-stimulating hormone (TSH) <sup>a</sup>	mIU/L	0.30–4.5	139	8.9	3.9
Total thyroxine (T4) <sup>a</sup>	nmol/L	60–140	43	111	115
Total triiodothyronine (T3) <sup>a</sup>	nmol/L	1.1–2.5	0.9	1.6	1.5
Thyroid peroxidase antibodies (TPO-Ab) <sup>b</sup>	U/mL	<60	296	–	56
Thyroglobulin antibodies (Tg-Ab) <sup>b</sup>	U/mL	<60	927	–	329
TSH-receptor antibodies (TRAb) <sup>c</sup>	IU/L	<1.0	<0.3	–	–

<sup>a</sup>Lithium-heparin plasma samples analyzed using Cobas 8000 (Roche Diagnostics, Basel, Switzerland). <sup>b</sup>Serum samples analyzed using Kryptor-Compact (ThermoFisher Diagnostics, Hennigsdorf, Germany). <sup>c</sup>Serum sample analyzed using a RIA (BRAHMS TRAK Human, Berlin, Germany).

**Figure 1**

Patient results of the thrombin generation assay at baseline and at 6 months follow-up.

and hair loss may be justified by other explanations when recently giving birth (16). Thus, the threshold for assessment of thyroid function in postpartum women should be low. In our patient, treatment was ongoing at 6 months follow-up, and only time, duration, and the future need for treatment can tell if her hypothyroidism is part of postpartum thyroiditis or chronic autoimmune hypothyroidism (17).

The clinical and histological evidence of severe placental dysfunction led to the assessment for any coagulation disorder in our patient. It is debatable whether such testing should be performed and whether the assessment should focus on hereditary thrombophilia or antiphospholipid antibodies alone (18). In our clinic, patients with severe placental dysfunction including severe preeclampsia are referred for assessment of coagulation function and the assessment includes a broad range of coagulation parameters. Our patient did not have elevated titers of antiphospholipid antibodies and no hereditary thrombophilia was found. It was the isolated finding of a prolonged APTT that was unexplained and subsequently led to the assessment of thyroid function. The abnormalities observed in specific coagulation parameters in our case are in line with the findings reported in the literature and seem to support a hypocoagulant state in hypothyroid individuals. More evidence is needed to inform the debate on any routine assessment of thyroid function in relation to coagulation disorders and vice versa. However, the combined evidence from the literature and our report may favor the assessment of thyroid function in cases of unexplained biochemical coagulation abnormalities, in particular the assessment of TSH in the case of prolonged APTT of unknown origin.

#### Declaration of interest

The authors declare that there is no conflict of interest that could be perceived as prejudicing the impartiality of this case report.

#### Funding

This work did not receive any specific grant from any funding agency in the public, commercial, or not-for-profit sector.

#### Author contribution statement

M H L and S L A conceptualized the study and wrote the first draft of the manuscript. All authors critically reviewed and commented on the manuscript and approved the final version of the manuscript.

#### References

- 1 Simone JV, Abildgaard CF & Schulman I. Blood coagulation in thyroid dysfunction. *New England Journal of Medicine* 1965 **273** 1057–1061. (<https://doi.org/10.1056/NEJM196511112732001>)
- 2 Squizzato A, Romualdi E, Büller HR & Gerdes VEA. Clinical review: thyroid dysfunction and effects on coagulation and fibrinolysis: a systematic review. *Journal of Clinical Endocrinology and Metabolism* 2007 **92** 2415–2420. (<https://doi.org/10.1210/jc.2007-0199>)
- 3 Elbers LPB, Fliers E & Cannegieter SC. The influence of thyroid function on the coagulation system and its clinical consequences. *Journal of Thrombosis and Haemostasis* 2018 **16** 634–645. (<https://doi.org/10.1111/jth.13970>)
- 4 Andersen SL, Nielsen KK & Kristensen SR. The interrelationship between pregnancy, venous thromboembolism, and thyroid disease: a hypothesis-generating review. *Thyroid Research* 2021 **14** 12. (<https://doi.org/10.1186/s13044-021-00102-4>)
- 5 Gullu S, Sav H & Kamel N. Effects of levothyroxine treatment on biochemical and hemostasis parameters in patients with hypothyroidism. *European Journal of Endocrinology* 2005 **152** 355–361. (<https://doi.org/10.1530/eje.1.01857>)
- 6 Stuijver DJF, Piantanida E, Zaane B Van, Galli L, Romualdi E, Tanda ML, Meijers JCM, Büller HR, Gerdes VEA & Squizzato A. Acquired von Willebrand syndrome in patients with overt hypothyroidism: a prospective cohort study. *Haemophilia* 2014 **20** 326–332. (<https://doi.org/10.1111/hae.12275>)
- 7 Manfredi E, Van B, Gerdes VEA, Brandjes DPM & Squizzato A. Hypothyroidism and acquired von Willebrand's syndrome: a systematic review. *Haemophilia* 2008 **14** 423–433. (<https://doi.org/10.1111/j.1365-2516.2007.01642.x>)
- 8 Connors JM. Thrombophilia testing and venous thrombosis. *New England Journal of Medicine* 2017 **377** 1177–1187. (<https://doi.org/10.1056/NEJMra1700365>)
- 9 James PD, Connell NT, Ameer B, Paola J Di, Eikenboom J, Giraud N, Haberichter S, Jacobs-Pratt V, Konkle B, McLintock C, *et al.* ASH ISTH NHF WFH 2021 guidelines on the diagnosis of von Willebrand disease. *Blood Advances* 2021 **5** 280–300. (<https://doi.org/10.1182/bloodadvances.2020003265>)
- 10 Pearce SHS, Brabant G, Duntas LH, Monzani F, Peeters RP, Razvi S & Wemeau JL. 2013 ETA guideline: management of subclinical hypothyroidism. *European Thyroid Journal* 2014 **2** 215–228. (<https://doi.org/10.1159/000356507>)
- 11 Biondi B, Bartalena L, Cooper DS, Hegedüs L, Laurberg P & Kahaly GJ. The 2015 European Thyroid Association guidelines on diagnosis and treatment of endogenous subclinical hyperthyroidism. *European Thyroid Journal* 2015 **4** 149–163. (<https://doi.org/10.1159/000438750>)

- 12 Carlé A, Laurberg P, Pedersen IB, Perrild H, Ovesen L, Rasmussen LB, Jorgensen T & Knudsen N. Age modifies the pituitary TSH response to thyroid failure. *Thyroid* 2007 **17** 139–144. (<https://doi.org/10.1089/thy.2006.0191>)
- 13 Kristensen SR, Nybo J & Pedersen S. Thrombin generation measured on ST Genesis, a new platform in the coagulation routine lab: assessment of analytical and between-subject variation. *Research and Practice in Thrombosis and Haemostasis* 2022 **6** 1–8. (<https://doi.org/10.1002/rth2.12654>)
- 14 O'Donnell J & Laffan MA. The relationship between ABO blood group, factor VIII and von Willebrand factor. *Transfusion Medicine* 2001 **11** 343–351. (<https://doi.org/10.1046/j.1365-3148.2001.00315.x>)
- 15 Carle A, Pedersen IB, Knudsen N, Perrild H, Ovesen L, Rasmussen LB & Laurberg P. Development of autoimmune overt hypothyroidism is highly associated with live births and induced abortions but only in premenopausal women. *Journal of Clinical Endocrinology and Metabolism* 2014 **99** 2241–2249. (<https://doi.org/10.1210/jc.2013-4474>)
- 16 Carle A, Pedersen IB, Knudsen N, Perrild H, Ovesen L, Andersen S & Laurberg P. Hypothyroid symptoms fail to predict thyroid insufficiency in old people: A population-based case-control study. *American Journal of Medicine* 2016 **129** 1082–1092. (<https://doi.org/10.1016/j.amjmed.2016.06.013>)
- 17 Alexander EK, Pearce EN, Brent GA, Brown RS, Chen H, Dosiou C, Grobman WA, Laurberg P, Lazarus JH, Mandel SJ, *et al.* 2017 Guidelines of the American Thyroid Association for the diagnosis and management of thyroid disease during pregnancy and the postpartum. *Thyroid* 2017 **27** 315–389. (<https://doi.org/10.1089/thy.2016.0457>)
- 18 Arachchilage DRJ & Makris M. Inherited thrombophilia and pregnancy complications: should we test? *Seminars in Thrombosis and Hemostasis* 2019 **45** 50–60. (<https://doi.org/10.1055/s-0038-1657782>)

Received in final form 10 June 2022

Accepted 27 June 2022

Accepted Manuscript published online 28 June 2022

