



# Which one will you choose; open, laparoscopic, or robotic transduodenal ampullectomy?: a case report

Dawn Jung<sup>1,2</sup>, Ji Eun Jung<sup>1</sup>, Chang Moo Kang<sup>1,2</sup>

<sup>1</sup>Division of Hepatobiliary and Pancreatic Surgery, Department of Surgery, Yonsei University College of Medicine, Seoul, Korea

<sup>2</sup>Pancreatobiliary Cancer Center, Yonsei Cancer Center, Severance Hospital, Seoul, Korea

Transduodenal ampullectomy (TDA) is the treatment of choice for large premalignant lesions of the ampulla of Vater (AoV). With the development of surgical techniques, various methods, including the open, laparoscopic, and robotic approaches, for performing TDA have emerged. Herein, we report four consecutive cases treated with open, laparoscopic, and robotic TDA, with technical pitfalls and future perspectives of TDA in treating premalignant lesions of the AoV. The surgical techniques and principles for TDA were the same regardless of the surgical approaches. After surgery, none of the patients showed any abnormal findings or complications, except for digestive problems. All these surgical approaches are appropriate for patients requiring TDA; however, minimally invasive TDA, particularly the robotic approach is ideal. Considering the surgical complexity of TDA, the robotic approach is considered to be effective.

**Keywords:** Ampulla of Vater, Duodenal neoplasms, Laparoscopy, Robotic surgical procedures

**Received** March 21, 2022

**Revised** May 2, 2022

**Accepted** May 12, 2022

### Corresponding author

Chang Moo Kang

Division of Hepatobiliary and Pancreatic Surgery, Department of Surgery, Yonsei University College of Medicine, 50-1 Yonsei-ro, Seodaemun-gu, Seoul 03722, Korea

Tel: +82-2-2228-1004

Fax: +82-2-313-8289

E-mail: cmkang@yuhs.ac

ORCID:

<https://orcid.org/0000-0002-5382-4658>

This is an Open Access article distributed under the terms of the Creative Commons Attribution Non-Commercial License (<http://creativecommons.org/licenses/by-nc/4.0/>) which permits unrestricted non-commercial use, distribution, and reproduction in any medium, provided the original work is properly cited.

Copyright © The Korean Society of Endo-Laparoscopic & Robotic Surgery.

## INTRODUCTION

Pancreatoduodenectomy (PD) is the treatment of choice for ampulla of Vater (AoV) cancer. Although the incidence of lymph node metastasis is approximately 47% [1], and it is associated with poor prognostic biologic behavior, the curative resection of AoV cancer shows the most favorable long-term oncologic outcome by radical pancreatectomy among periampullary cancers [2,3].

What about premalignant lesions of the AoV? With the advancement in experiences and technologies of endoscopy, endoscopic papillectomy (EP) is a safe treatment modality for premalignant lesions of the AoV area. EP is usually attempted for tumors with no malignancy potential and has been confirmed benign by prior biopsy of tumors (<4.5 cm in diameter). The suc-

cess rate of EP in the AoV area is 61% to 92%, and the recurrence rate is 0% to 33%. Complications of EP include pancreatitis in approximately 8% to 12% of cases and bleeding in 2% to 7% of cases. Perforation occurs in approximately 2% to 4% of cases, and in rare cases, mortality (0.3%–7%) may also occur [4]. In clinical practice, patients with potentially residual ampullary lesions after EP are common. Transduodenal ampullectomy (TDA) was reserved for such patients.

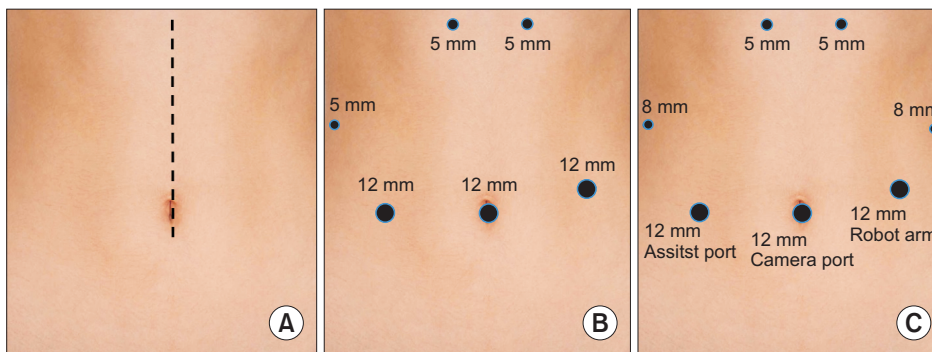
Generally, TDA is thought to be less aggressive and function-preserving surgery compared with PD; however, it still involves complex surgical processes, such as septoplasty for common channel formation between the bile and pancreatic ducts and common channel duodenal implantation. Therefore, it is typically performed using an open procedure. In theory, patients with

potential indications for TDA are expected to have long-term survival, and a minimally invasive approach would be ideal, as long as the appropriate surgical technique and skills are available. Herein, we report four consecutive cases treated with open, laparoscopic, and robotic approaches of TDA with its technical pitfalls and future perspectives for treating premalignant lesions of AoV.

### CASE REPORT

The surgical techniques and principles of TDA are the same, regardless of the surgical approaches. After exposure of the pancreaticoduodenal unit from the retroperitoneum, identification of AoV lesions is necessary because the duodenostomy site should be determined for an appropriate surgical approach to the AoV area. In the open approach (Fig. 1A), a small catheter was introduced into the AoV through the cystic duct, which could be easily identified by palpating the tip of the catheter on the duo-

denal wall. In contrast, in the laparoscopic (Fig. 1B) and robotic approaches (Fig. 1C), the effectiveness of palpation was limited, and intraoperative ultrasound to detect the previous endoscopic retrograde biliary drainage catheter or preoperatively placed endoscopic clips near the AoV could be applied to define the exact duodenal opening site. After identifying the AoV lesions, several stay sutures (4–0 absorbable) with sufficient healthy mucosal margins were placed for effective traction of the ampullary lesion. In procedure, we did not inject saline into the mucosa, and electrocautery was applied to resect the AoV for identifying the bile and pancreatic ducts to resect the whole layer of lesion. After complete resection of the AoV with the bile and pancreatic ducts, several sutures (6–0 absorbable) were placed for a septoplasty to allow the separate bile and pancreatic ducts into a common channel. And mount the stent by fixing it to the bile and pancreatic ducts. Finally, the duodenal mucosa was approximated to the common channel to complete the duodenal implantation of the common channel. After repairing the duodenostomy site, two



**Fig. 1.** Site of incision while performing transduodenal ampullectomy. (A) Open approach, (B) laparoscopic approach, and (C) robotic approach.

**Table 1.** Summary of the four consecutive cases of transduodenal ampullectomy

Parameters	Transduodenal ampullectomy case			
	Open	Laparoscopic	Robotic 1	Robotic 2
Age (yr)	70	60	64	59
Sex	Male	Female	Male	Male
Diagnosis	AoV adenoma	AoV carcinoma <i>in situ</i>	AoV carcinoma <i>in situ</i>	AoV tubular adenoma
Tumor size (cm)	3.0	1.4	1.0	2.5
Previous procedure	None	ERBD insertion	None	None
Determining duodenostomy site, localization of AoV	Catheter insertion through cystic duct and palpation	Previous ERBD catheter indentation	Preoperative endoscopic clipping around AoV and IIOUS detection	Preoperative endoscopic clipping around AoV and IIOUS detection
Operation time (min)	166	296	346	311
Estimated blood loss (mL)	70	100	50	100
Complication	None	Vomiting	Vomiting	None
Length of hospital stay (day)	10	15	8	9

AoV, ampulla of Vater; ERBD, endoscopic retrograde biliary drainage; IIOUS, intraoperative ultrasonography.

**Table 2.** Postoperative pain score according to the time period

Postoperative day	Pain score <sup>a)</sup>			
	Open	Laparoscopic	Robotic 1	Robotic 2
1	8	8	7	7
2	7	7	5	5
3	9	6	5	5
5	7	6	3	5
7	5	5	3	3
9	3	3		3
11	3	3		

<sup>a)</sup>Numerical Pain Intensity Scale.

silastic drains were placed before the external wound closure. Lymph node dissection was not performed because the risk of morbidity increased due to a larger dissection in TDA. None of the patients showed abnormal postoperative findings (Table 1). In the laparoscopic case, the hospital stay was prolonged due to vomiting, but in other cases, there were no other special complications. The pain index appeared to be better for the robot cases (Table 2); however, it was difficult to compare it as a subjective index for each patient.

## DISCUSSION

Compared with PD, the surgical extent of TDA is limited; hence, it is thought to be an appropriate surgical option for treating premalignant lesions of AoV. Therefore, preoperative endoscopic ultrasonography and intraoperative frozen section test should be routinely performed to confirm the diagnosis and depth of lesion invasion before performing TDA. All four patients performed this study and had reported premalignancy pathology in postoperative pathologic diagnosis, indicating that accurate patient selection is important for TDA.

Fortunately, there are no advanced T stage cases. But even in advanced cases, according to a Korean multicenter study, there was no difference in prognosis between PD and TDA when Tis and T1 stages were reported [5]. With advances in laparoscopic skills and experience, several reports have demonstrated the technical feasibility and safety of TDA [6,7]. However, TDA usually requires an open approach due to complicated surgical procedures; consequently, minimally invasive approaches to TDA are rarely reported.

Several rationales exist for minimally invasive TDA for premalignant lesions of the AoV. First, the surgical extent of TDA is limited compared to the external wound for the open approach. It can benefit from a minimally invasive approach because the dissection-induced injury is smaller than access-induced injury.

Second, long-term survival is expected for these patients. Quality of life should be considered to minimize cosmetic complications.

As shown in the present cases, an accurate suturing technique not only for creating a common channel between the small bile and pancreatic ducts but also for its implantation surrounding the folded duodenal mucosa is critical to complete the TDA. The laparoscopic approach is appropriate yet difficult for this surgical procedure. Based on three consecutive experiences of TDA for premalignant lesions of AoV, we believe that the robotic approach makes it much easier to complete these complicated and delicate surgical procedures. The wrist-like function of the surgical instruments and the stable three-dimensional magnified operation field provided by the robotic surgical system are thought to be useful. In the present cases, the operation time of the robot cases is longer than other approaches, which can be explained by the existence of docking time and the learning curve, and there is a sufficient possibility that the operation time will be shorter.

However, applying the robotic surgical system as a routine practice is difficult because of the high cost of robotic surgery. Recently, the Ministry of Food and Drug Safety in Korea approved the clinical use of Revo-i (the Korean robotic surgical system; Meerecompany Inc., Seoul, Korea) in minimally invasive surgery [8,9]. In addition, several international companies are actively involved in robotic surgical system development [10]. A day where patients would take advantage of robotic TDA with much available cost is believed to arrive soon.

In summary, we are living in an era intermingled with different surgical TDA approaches, including open, laparoscopic, and robotic systems. Currently, these surgical approaches are appropriate for patients requiring TDA; however, minimally invasive TDA, particularly using the robotic approach, is ideal. Considering the surgical complexity of TDA, robotic TDA is considered to be effective. Further clinical applications of robotic TDA are expected to increase in the near future.

## NOTES

### Ethical statements

This study was approved by Institutional Review Board of Yonsei University College of Medicine with a waiver of informed consent (No. 4-2022-0102).

### Authors' contributions

Conceptualization: CMK

Formal analysis: JEJ

Investigation: JEJ

Methodology: DJ

Project administration: CMK

Writing—original draft: DJ

Writing—review & editing: All authors

All authors read and approved the final manuscript.

### Conflict of interest

All authors have no conflicts of interest to declare.

### Funding/support

None.

### ORCID

Dawn Jung, <https://orcid.org/0000-0002-2467-6043>

Ji Eun Jung, <https://orcid.org/0000-0002-4672-152X>

Chang Moo Kang, <https://orcid.org/0000-0002-5382-4658>

## REFERENCES

1. Sierzega M, Nowak K, Kulig J, Matyja A, Nowak W, Popiela T. Lymph node involvement in ampullary cancer: the importance of the number, ratio, and location of metastatic nodes. *J Surg Oncol* 2009; 100:19-24.
2. Yeo CJ, Sohn TA, Cameron JL, Hruban RH, Lillemoe KD, Pitt HA. Periampullary adenocarcinoma: analysis of 5-year survivors. *Ann Surg* 1998;227:821-831.
3. Howe JR, Klimstra DS, Moccia RD, Conlon KC, Brennan MF. Factors predictive of survival in ampullary carcinoma. *Ann Surg* 1998;228:87-94.
4. Cheng CL, Sherman S, Fogel EL, et al. Endoscopic snare papillectomy for tumors of the duodenal papillae. *Gastrointest Endosc* 2004;60:757-764.
5. Hong SS, Han SS, Kwon W, et al. Comparison of oncologic outcomes between transduodenal ampullectomy and pancreatoduodenectomy in ampulla of Vater cancer: Korean multicenter study. *Cancers (Basel)* 2021;13:2038.
6. Downs-Canner S, Van der Vliet WJ, Thoolen SJ, et al. Robotic surgery for benign duodenal tumors. *J Gastrointest Surg* 2015;19:306-312.
7. Ahn KS, Han HS, Yoon YS, Cho JY, Khalikulov K. Laparoscopic transduodenal ampullectomy for benign ampullary tumors. *J Laparoendosc Adv Surg Tech A* 2010;20:59-63.
8. Kang I, Hwang HK, Lee WJ, Kang CM. First experience of pancreaticoduodenectomy using Revo-i in a patient with insulinoma. *Ann Hepatobiliary Pancreat Surg* 2020;24:104-108.
9. Lim JH, Lee WJ, Choi SH, Kang CM. Cholecystectomy using the Revo-i robotic surgical system from Korea: the first clinical study. *Updates Surg* 2021;73:1029-1035.
10. Peters BS, Armijo PR, Krause C, Choudhury SA, Oleynikov D. Review of emerging surgical robotic technology. *Surg Endosc* 2018;32: 1636-1655.