

1-1-2015

## The Management of Uterine Leiomyomas

George A. Vilos  
george.vilos@lhsc.on.ca

Catherine Allaire

Philippe Yves Laberge

Nicholas Leyland

Angelos G. Vilos  
angelos.vilos@lhsc.on.ca

*See next page for additional authors*

Follow this and additional works at: <https://ir.lib.uwo.ca/paedpub>

---

### Citation of this paper:

Vilos, George A.; Allaire, Catherine; Laberge, Philippe Yves; Leyland, Nicholas; Vilos, Angelos G.; Murji, Ally; and Chen, Innie, "The Management of Uterine Leiomyomas" (2015). *Paediatrics Publications*. 2637.  
<https://ir.lib.uwo.ca/paedpub/2637>

---

**Authors**

George A. Vilos, Catherine Allaire, Philippe Yves Laberge, Nicholas Leyland, Angelos G. Vilos, Ally Murji, and Innie Chen

# The Management of Uterine Leiomyomas

This clinical practice guideline has been prepared by the Uterine Leiomyomas Working Group, reviewed by the Clinical Practice Gynaecology, Reproductive Endocrinology & Infertility, and Family Physician Advisory Committees, and approved by the Executive and Board of the Society of Obstetricians and Gynaecologists of Canada.

## PRINCIPAL AUTHORS

George A. Vilos, MD, London ON  
 Catherine Allaire, MD, Vancouver BC  
 Philippe-Yves Laberge, MD, Quebec QC  
 Nicholas Leyland, MD, MHCM, Hamilton ON

## SPECIAL CONTRIBUTORS

Angelos G. Vilos, MD, London, ON  
 Ally Murji, MD, MPH, Toronto, ON  
 Innie Chen, MD, Ottawa, ON

Disclosure statements have been received from all contributors.

The literature searches and bibliographic support for this guideline were undertaken by Becky Skidmore, Medical Research Analyst, Society of Obstetricians and Gynaecologists of Canada.

## Abstract

**Objectives:** The aim of this guideline is to provide clinicians with an understanding of the pathophysiology, prevalence, and clinical significance of myomata and the best evidence available on treatment modalities.

**Options:** The areas of clinical practice considered in formulating this guideline were assessment, medical treatments, conservative treatments of myolysis, selective uterine artery occlusion, and surgical alternatives including myomectomy and hysterectomy. The risk-to-benefit ratio must be examined individually by the woman and her health care provider.

**Key Words:** Myoma, leiomyoma, fibroid, myomectomy, uterine artery embolization, hysterectomy, heavy menstrual bleeding, menorrhagia

**Outcomes:** Implementation of this guideline should optimize the decision-making process of women and their health care providers in proceeding with further investigation or therapy for uterine leiomyomas, having considered the disease process and available treatment options, and reviewed the risks and anticipated benefits.

**Evidence:** Published literature was retrieved through searches of PubMed, CINAHL, and Cochrane Systematic Reviews in February 2013, using appropriate controlled vocabulary (uterine fibroids, myoma, leiomyoma, myomectomy, myolysis, heavy menstrual bleeding, and menorrhagia) and key words (myoma, leiomyoma, fibroid, myomectomy, uterine artery embolization, hysterectomy, heavy menstrual bleeding, menorrhagia). The reference lists of articles identified were also searched for other relevant publications. Results were restricted to systematic reviews, randomized control trials/controlled clinical trials, and observational studies. There were no date limits but results were limited to English or French language materials. Searches were updated on a regular basis and incorporated in the guideline to January 2014. Grey (unpublished) literature was identified through searching the websites of health technology assessment and health technology-related agencies, clinical practice guideline collections, and national and international medical specialty societies.

**Benefits, Harms, and Costs:** The majority of fibroids are asymptomatic and require no intervention or further investigations. For symptomatic fibroids such as those causing menstrual abnormalities (e.g. heavy, irregular, and prolonged uterine bleeding), iron deficiency anemia, or bulk symptoms (e.g., pelvic pressure/pain, obstructive symptoms), hysterectomy is a definitive solution. However, it is not the preferred solution for women who wish to preserve fertility and/or their uterus. The selected treatment should be directed towards an improvement in symptomatology and quality of life. The cost of the therapy to the health care system and to women with fibroids must be interpreted in the context of the cost of untreated disease conditions and the cost of ongoing or repeat investigative or treatment modalities.

**Values:** The quality of evidence in this document was rated using the criteria described in the Report of the Canadian Task Force on Preventive Health Care (Table 1).

J Obstet Gynaecol Can 2015;37(2):157–178

This document reflects emerging clinical and scientific advances on the date issued and is subject to change. The information should not be construed as dictating an exclusive course of treatment or procedure to be followed. Local institutions can dictate amendments to these opinions. They should be well documented if modified at the local level. None of these contents may be reproduced in any form without prior written permission of the SOGC.

**Table 1. Key to evidence statements and grading of recommendations, using the ranking of the Canadian Task Force on Preventive Health Care**

Quality of evidence assessment*	Classification of recommendations†
I: Evidence obtained from at least one properly randomized controlled trial	A. There is good evidence to recommend the clinical preventive action
II-1: Evidence from well-designed controlled trials without randomization	B. There is fair evidence to recommend the clinical preventive action
II-2: Evidence from well-designed cohort (prospective or retrospective) or case-control studies, preferably from more than one centre or research group	C. The existing evidence is conflicting and does not allow to make a recommendation for or against use of the clinical preventive action; however, other factors may influence decision-making
II-3: Evidence obtained from comparisons between times or places with or without the intervention. Dramatic results in uncontrolled experiments (such as the results of treatment with penicillin in the 1940s) could also be included in this category	D. There is fair evidence to recommend against the clinical preventive action
III: Opinions of respected authorities, based on clinical experience, descriptive studies, or reports of expert committees	E. There is good evidence to recommend against the clinical preventive action
	L. There is insufficient evidence (in quantity or quality) to make a recommendation; however, other factors may influence decision-making

\*The quality of evidence reported in here has been adapted from The Evaluation of Evidence criteria described in the Canadian Task Force on Preventive Health Care.<sup>204</sup>

†Recommendations included in these guidelines have been adapted from the Classification of Recommendations criteria described in the Canadian Task Force on Preventive Health Care.<sup>204</sup>

**Summary Statements**

1. Uterine fibroids are common, appearing in 70% of women by age 50; the 20% to 50% that are symptomatic have considerable social and economic impact in Canada. (II-3)
2. The presence of uterine fibroids can lead to a variety of clinical challenges. (III)
3. Concern about possible complications related to fibroids in pregnancy is not an indication for myomectomy except in women who have had a previous pregnancy with complications related to these fibroids. (III)
4. Women who have fibroids detected in pregnancy may require additional maternal and fetal surveillance. (II-2)
5. Effective medical treatments for women with abnormal uterine bleeding associated with uterine fibroids include the levonorgestrel intrauterine system, (I) gonadotropin-releasing hormone analogues, (I) selective progesterone receptor modulators, (I) oral contraceptives, (II-2) progestins, (II-2) and danazol. (II-2)
6. Effective medical treatments for women with bulk symptoms associated with fibroids include selective progesterone receptor modulators and gonadotropin-releasing hormone analogues. (I)
7. Hysterectomy is the most effective treatment for symptomatic uterine fibroids. (III)
8. Myomectomy is an option for women who wish to preserve their uterus or enhance fertility, but carries the potential for further intervention. (II-2)
9. Of the conservative interventional treatments currently available, uterine artery embolization has the longest track record and has been shown to be effective in properly selected patients. (II-3)
10. Newer focused energy delivery methods are promising but lack long-term data. (III)
2. Treatment of women with uterine leiomyomas must be individualized based on symptomatology, size and location of fibroids, age, need and desire of the patient to preserve fertility or the uterus, the availability of therapy, and the experience of the therapist. (III-B)
3. In women who do not wish to preserve fertility and/or their uterus and who have been counselled regarding the alternatives and risks, hysterectomy by the least invasive approach possible may be offered as the definitive treatment for symptomatic uterine fibroids and is associated with a high level of satisfaction. (II-2A)
4. Hysteroscopic myomectomy should be considered first-line conservative surgical therapy for the management of symptomatic intracavitary fibroids. (II-3A)
5. Surgical planning for myomectomy should be based on mapping the location, size, and number of fibroids with the help of appropriate imaging. (III-A)
6. When morcellation is necessary to remove the specimen, the patient should be informed about possible risks and complications, including the fact that in rare cases fibroid(s) may contain unexpected malignancy and that laparoscopic power morcellation may spread the cancer, potentially worsening their prognosis. (III-B)
7. Anemia should be corrected prior to proceeding with elective surgery. (II-2A) Selective progesterone receptor modulators and gonadotropin-releasing hormone analogues are effective at correcting anemia and should be considered preoperatively in anemic patients. (I-A)
8. Use of vasopressin, bupivacaine and epinephrine, misoprostol, peri-cervical tourniquet, or gelatin-thrombin matrix reduce blood loss at myomectomy and should be considered. (I-A)
9. Uterine artery occlusion by embolization or surgical methods may be offered to selected women with symptomatic uterine fibroids who wish to preserve their uterus. Women choosing uterine artery occlusion for the treatment of fibroids should be counselled regarding possible risks, including the likelihood that fecundity and pregnancy may be impacted. (II-3A)

**Recommendations**

1. Women with asymptomatic fibroids should be reassured that there is no evidence to substantiate major concern about malignancy and that hysterectomy is not indicated. (III-D)

10. In women who present with acute uterine bleeding associated with uterine fibroids, conservative management with estrogens, selective progesterone receptor modulators, antifibrinolytics, Foley catheter tamponade, and/or operative hysteroscopic intervention may be considered, but hysterectomy may become necessary in some cases. In centres where available, intervention by uterine artery embolization may be considered. (III-B)

## INTRODUCTION

### Clinical Importance of Uterine Fibroids

The terms fibroid, myoma, and leiomyoma are synonymous and are the commonest gynaecological tumours, with a prevalence of 70% to 80% in women who have reached the age of 50.<sup>1</sup> In 95 061 US nurses, aged 25 to 44 years, the incidence was 8.9/1000 for white women and 30.9/1000 for black women.<sup>2</sup> The prevalence increases with age, peaking in women in their 40s. A hysterectomy study has found leiomyomas in 77% of uterine specimens.<sup>3</sup>

In many women, myomas may be asymptomatic and are diagnosed incidentally on clinical examination or imaging. However, myomas can cause significant morbidity including menstrual abnormalities (e.g. heavy, irregular, and prolonged uterine bleeding), iron deficiency anemia, bulk symptoms (e.g. pelvic pressure/pain, obstructive symptoms), and fertility issues. Symptomatic fibroids have a considerable

impact on women's quality of life as well as their productivity: in one survey of more than 21 000 women from 8 different countries, including 2500 from Canada, these symptoms had a negative impact on sexual life (43%), performance at work (28%), and relationship, and family (27%).<sup>4-6</sup>

Of 11 880 screened Canadian women, aged 20 to 49 years, 12.0% indicated they had been diagnosed with uterine fibroids, including 3.2% reporting current fibroids. Those with moderate to severe fibroid symptoms experienced a significantly heavier burden of illness, with lost productivity and reduced QoL.<sup>7</sup>

Uterine fibroids are currently the most common indication for hysterectomy worldwide, and in Canada they account for 30% of all hysterectomies, the second most common surgery for women after Caesarean section.<sup>8</sup> Hysterectomy is associated with significant morbidity, mortality, and economic burden on the health care system,<sup>9-10</sup> and 1 in 4 Canadian women over age 45 have had a hysterectomy.<sup>8</sup> The social and economic impact of uterine fibroids is therefore considerable.

### Summary Statement

1. Uterine fibroids are common, appearing in 70% of women by age 50; the 20% to 50% that are symptomatic have considerable social and economic impact in Canada. (II-3)

## ABBREVIATIONS

AAGL	American Association of Gynecologic Laparoscopists
AUB	abnormal uterine bleeding
EA	endometrial ablation
ER $\alpha$	estrogen receptor alpha
FDA	United States Food and Drug Administration
FIGO	International Federation of Gynecology and Obstetrics
GnRH	gonadotropin-releasing hormone
HRT	hormone replacement therapy
LNG-IUS	levonorgestrel intrauterine system
MRg-FUS	magnetic resonance-guided focused ultrasound
MRI	magnetic resonance imaging
NETA	norethindrone acetate
PR	progesterone receptor
QoL	quality of life
RF	radio frequency
RFVTA	radio frequency volumetric thermal ablation
SERM	selective estrogen receptor modulator
SPRM	selective progesterone receptor modulator
UAE	uterine artery embolization
UAO	uterine artery occlusion
UPA	ulipristal acetate

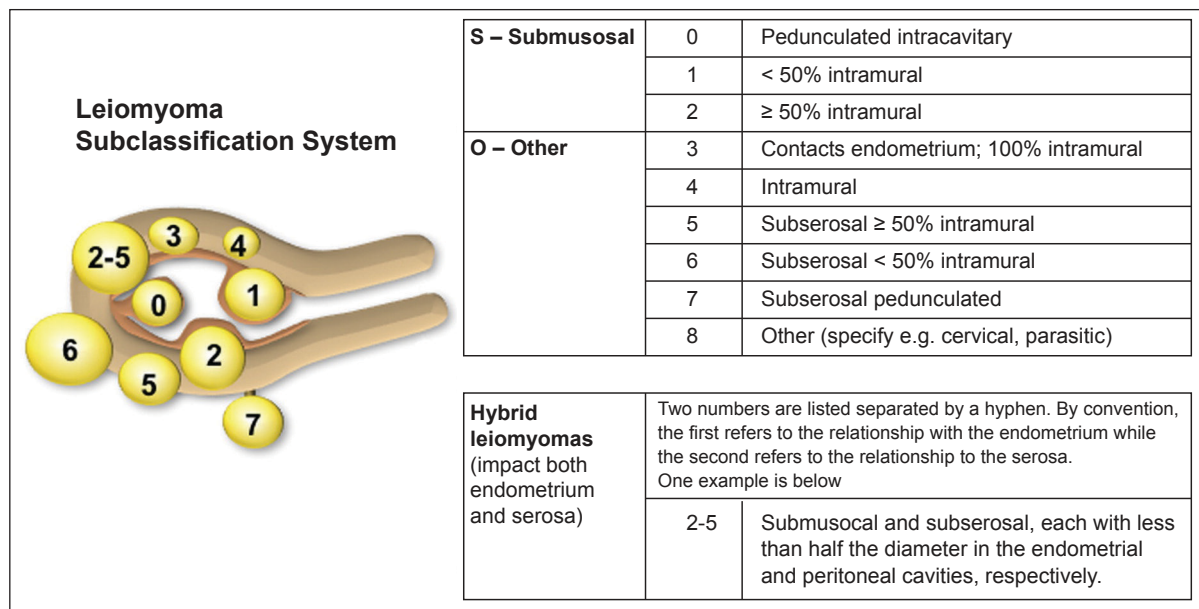
### Pathophysiology of Myomas

Uterine fibroids are monoclonal tumours that arise from the uterine smooth muscle tissue (i.e. the myometrium). They are benign neoplasms composed of disordered "myofibroblasts" buried in abundant quantities of extracellular matrix that accounts for a substantial portion of tumour volume. The initiating events for fibroid genesis remain speculative.

The cells proliferate at a modest rate and their growth is dependant on the ovarian steroids estrogen and progesterone and therefore most fibroids shrink after menopause. The biologically potent estrogen estradiol induces the production of PR by means of ER- $\alpha$ . PR is essential for the response of fibroid tissue to progesterone secreted by the ovaries. Progesterone and PR are indispensable to tumour growth, increasing cell proliferation and survival and enhancing extracellular matrix formation. In the absence of progesterone and PR, estrogen and ER- $\alpha$  are not sufficient for fibroid growth.<sup>11</sup>

Myomas can be single or multiple and can vary in size, location, and perfusion. Myomas are commonly classified into 3 subgroups based on their location: subserosal (projecting outside the uterus), intramural (within the

Figure 1. The FIGO leiomyoma subclassification system<sup>12</sup>



myometrium), and or submucosal (projecting into the cavity of the uterus). A newer, more detailed classification system has been devised and advocated by FIGO (Figure 1).<sup>12</sup>

Recognized risk factors for development of uterine fibroids include nulliparity, early menarche, increased frequency of menses, history of dysmenorrhea, family history of uterine fibroids, African descent, obesity, and age (peak incidence at 40 to 50). Clinical conditions that seem to increase risk of fibroids include hypertension and diabetes.<sup>13</sup>

**Clinical Presentation**

The presence of uterine fibroids can lead to various clinical challenges. The need for and choice of intervention must be individualized to the clinical situation.

The most common symptom of uterine leiomyoma is AUB. In a published series of myomectomies, 30% of women suffered from heavy menstrual bleeding.<sup>14-15</sup> The mechanism of leiomyoma-associated AUB is unknown. Increased endometrial surface area, vascular dysregulation, and interference with endometrial hemostasis have been offered as possible explanations.<sup>16</sup> Clinicians with patients presenting with AUB should refer to the SOGC clinical practice guideline on the management of AUB.<sup>17</sup>

Pelvic pain is rare with fibroids and usually signifies degeneration, torsion, or possibly associated adenomyosis and/or endometriosis. Pelvic pressure, bowel dysfunction, and bladder symptoms such as urinary frequency and urgency may be present with larger fibroids. Urinary symptoms should be investigated prior to surgical

management of fibroids to exclude other possible causes.<sup>15</sup> In the postmenopausal woman presenting with new onset of pain and/or bleeding in new or existing fibroids, leiomyosarcoma should be considered.<sup>18</sup>

**Fibroids and Fertility**

A new SOGC guideline on the management of uterine fibroids in women with otherwise unexplained infertility will be published in the spring of 2015.<sup>19</sup>

**Fibroids in Pregnancy**

Estimates of the prevalence of fibroids in pregnancy vary depending on the quality of the ultrasound study and the race and age of the women being studied. A recent ultrasound study found the prevalence to be 18% in African-American women, 8% in white women, and 10% in Hispanic women.<sup>20</sup>

Most ultrasound studies found that fibroids remain the same size or become smaller during pregnancy.<sup>21-23</sup> In a 2011 report, 171 pregnant women with fibroids were followed by serial ultrasound. Postpartum, 36% of women had no identifiable fibroid and 79% of remaining fibroids had decreased in size.<sup>24</sup> One study reported an increase in myoma size during pregnancy.<sup>25</sup>

Several large retrospective studies of ultrasounds and medical records of pregnant women have reported on the impact of fibroids on pregnancy outcomes.<sup>26-30</sup> A 2008 meta-analysis found an overall increased risk of malpresentation (OR 2.9; 95% CI 2.6 to 3.2), Caesarean delivery (OR 3.7; 95% CI 3.5 to 3.9), and preterm delivery

(OR 1.5; 95% CI 1.3 to 1.7).<sup>31</sup> In 2010, a study including 72 000 pregnancies reported significant differences in odds ratios for placenta previa, abruption, premature rupture of membranes, preterm birth < 34 weeks, and intrauterine fetal death, but the differences were all < 2%, which would not be considered clinically relevant.<sup>32</sup> It would seem that women with fibroids, especially large ones, merit close obstetrical follow-up but are likely to have a good outcome.

Traditional teaching has been that myomectomy, other than for symptomatic pedunculated fibroids, should not be performed in pregnant women because of the increased risk of uncontrolled bleeding. However, a number of case series report good outcomes after myomectomy performed during pregnancy or at the time of Caesarian section, therefore it can be considered as an option if clinically necessary.<sup>33–36</sup>

## Concerns about Malignancy

### Leiomyosarcomas

In clinical practice, the mere finding of pelvic tumours in symptomatic or asymptomatic women may raise the concern of malignancy in both patients and health care providers. In a review of 6815 patients who underwent myomectomy between 1950 and 1993, only 18 patients (0.26%) had leiomyosarcomas. In the subpopulation of women whose masses had grown rapidly, the prevalence was the same at 0.27%.<sup>37</sup> Based on this evidence, rapid growth of a fibroid does not seem to be a predictor of leiomyosarcoma. However postmenopausal growth or onset of symptoms should carry a higher index of suspicion for malignancy.

Other case series have estimated the incidence of leiomyosarcoma at 0.22% to 0.49%, although in women in their 6th decade it may rise to 1% of hysterectomy specimens.<sup>37,38</sup> Most recent reviews are consistent with older studies and estimate that in women undergoing surgery for fibroids approximately 1 in 400 (0.25%) is at risk of having a leiomyosarcoma.<sup>39</sup>

Although incidental uterine leiomyosarcomas have been encountered during routine resectoscopic myomectomy,<sup>40</sup> their incidence appears to be lower than that reported following hysterectomy (0.13%).<sup>41</sup> Whether leiomyosarcomas develop from leiomyomas or arise independently is not known. The challenge lies in the fact that leiomyomas and leiomyosarcomas cannot reliably be distinguished clinically or by any imaging technique.

### Smooth muscle tumours of uncertain malignant potential

Morphologically, there exists a spectrum of uterine smooth muscle tumours with conventionally well-defined histologic criteria and predictable clinical outcomes at

the 2 extremes, leiomyomas and leiomyosarcomas. The spectrum includes several variants with unusual features showing various combinations and permutations of 3 histologic criteria including nuclear atypia, mitotic index, and zonal necrosis that may indicate malignancy.

Frequently, these variants pose diagnostic challenges because they exhibit some features of malignancy but do not meet full criteria and therefore cannot be clearly interpreted and classified as either benign or malignant. Furthermore, the behavioural and clinical outcomes associated with some of these variants have not yet been elucidated. This uncertainty frequently leads to therapeutic dilemmas, especially when the diagnosis is made in myomectomy specimens from women who wish to maintain or enhance their fertility. In 2003, the World Health Organization labelled these tumours “smooth muscle tumours of uncertain malignant potential” (STUMP).<sup>42,43</sup>

### Other malignancies

Other uterine malignancies such as cervical cancer and endometrial cancer may be present and contribute to AUB; these should be ruled out by appropriate evaluation and screening.

### Summary Statements

2. The presence of uterine fibroids can lead to a variety of clinical challenges. (III)
3. Concern about possible complications related to fibroids in pregnancy is not an indication for myomectomy except in women who have had a previous pregnancy with complications related to these fibroids. (III)
4. Women who have fibroids detected in pregnancy may require additional maternal and fetal surveillance. (II-2)

### Recommendation

1. Women with asymptomatic fibroids should be reassured that there is no evidence to substantiate major concern about malignancy and that hysterectomy is not indicated. (III-D)

### Evaluation

On physical examination, an enlarged, mobile uterus (correlating to a weight of approximately 300 g or 12 weeks of pregnancy) with irregular contour is consistent with fibroids.

Ultrasonography (transabdominal, transvaginal, contrast sonohysterography) is the most widely used modality because of its availability, ease of use, and cost-effectiveness. It is particularly helpful to assess myoma growth and the

adnexae if these cannot be palpated separately with confidence.<sup>44</sup> Contrast infusion saline or gel sonography and 2D and 3D sonohysterography are very accurate diagnostic procedures to detect submucosal lesions, all with sensitivity and specificity of 98% to 100%.<sup>45,46</sup> In women with large fibroids, diagnostic imaging occasionally demonstrates hydronephrosis, the clinical significance of which is unknown. Complete ureteric obstruction is extremely rare.<sup>47</sup>

CT is of limited value in delineating the location of myomas relative to the endometrium or myometrium.<sup>48</sup> MRI is the most accurate modality in assessing the adnexae<sup>49</sup> and the uterus because it provides information on the size, location, number, and perfusion of leiomyomas as well as the presence of other uterine pathology including adenomyosis and/or adenomyoma.<sup>50–52</sup>

### Treatment

The majority of uterine leiomyomas are asymptomatic and will not require therapy. However, 20% to 50% are clinically symptomatic, causing AUB, iron deficiency anemia, bulk effects, and/or reproductive issues,<sup>53</sup> and may require treatment. Treatment of women with uterine leiomyomas must be individualized, based on symptomatology, the size and location of fibroids, age, the needs and desires of the patient for preservation of fertility or the uterus, the availability of therapy, and the experience of the therapist.

Symptomatic uterine fibroids may be treated medically, surgically, or with a combination of both (Figure 2).

### Expectant Management

Prospective imaging studies indicate that 3% to 7% of untreated fibroids in premenopausal women regress over 6 months to 3 years.<sup>54,55</sup> Most women experience shrinkage of fibroids and relief of symptoms at menopause; therefore, depending on the severity of their symptoms, women who are approaching menopause may choose to wait for the onset of menopause before deciding on treatment. Postmenopausal hormone replacement therapy is not contraindicated in the presence of fibroids and does not lead to the development of new fibroids, although it may be associated with some myoma growth, which may in turn lead to clinical symptoms.<sup>56,57</sup>

## MEDICAL MANAGEMENT

Until recently, medical management options for uterine leiomyomas have been of limited value because of their moderate efficacy and/or associated adverse effects. Novel therapies at the receptor and gene levels have emerged or are undergoing investigation and may eventually offer better long-term management options.<sup>58</sup>

Because estrogen upregulation of both ERs and PRs during the follicular phase is followed by progesterone-induced mitogenesis during the luteal phase, all hormonal therapies to control uterine bleeding aim to regulate the effect of these 2 gonadal steroids.

### Oral Contraceptives

There is no evidence that low-dose oral contraceptives cause benign fibroids to grow, thus uterine fibroids are not a contraindication to their use. Oral contraceptives are effective in reducing menstrual bleeding in the short-term and may prevent the development of uterine fibroids.<sup>59</sup>

### Progestins/Levonorgestrel Intrauterine System

Progestogens are natural or synthetic progestational hormones which may potentially have dual actions on fibroid growth. While the natural hormone progesterone augments epidermal growth factor, which stimulates fibroid growth, it also inhibits insulin-like growth factor-1, which may inhibit growth.<sup>60</sup> Progestogens also down-regulate both estrogen and progesterone receptors in fibroids, which may act as another mechanism in modulating fibroid biology and growth.<sup>61</sup> Both natural progesterone and synthetic progestins cause endometrial atrophy, which has the potential to decrease menstrual blood loss in women with fibroids.

One study concluded that the LNG-IUS significantly reduces menstrual blood loss and uterine volume in women with menorrhagia, with and without fibroids, while it does not significantly reduce fibroid volume.<sup>62</sup> Another RCT found that although the rate of treatment failure was similar in both groups, the LNG-IUS was more effective in reducing menstrual blood loss than combined oral contraceptives in women with fibroid-related menorrhagia.<sup>59</sup>

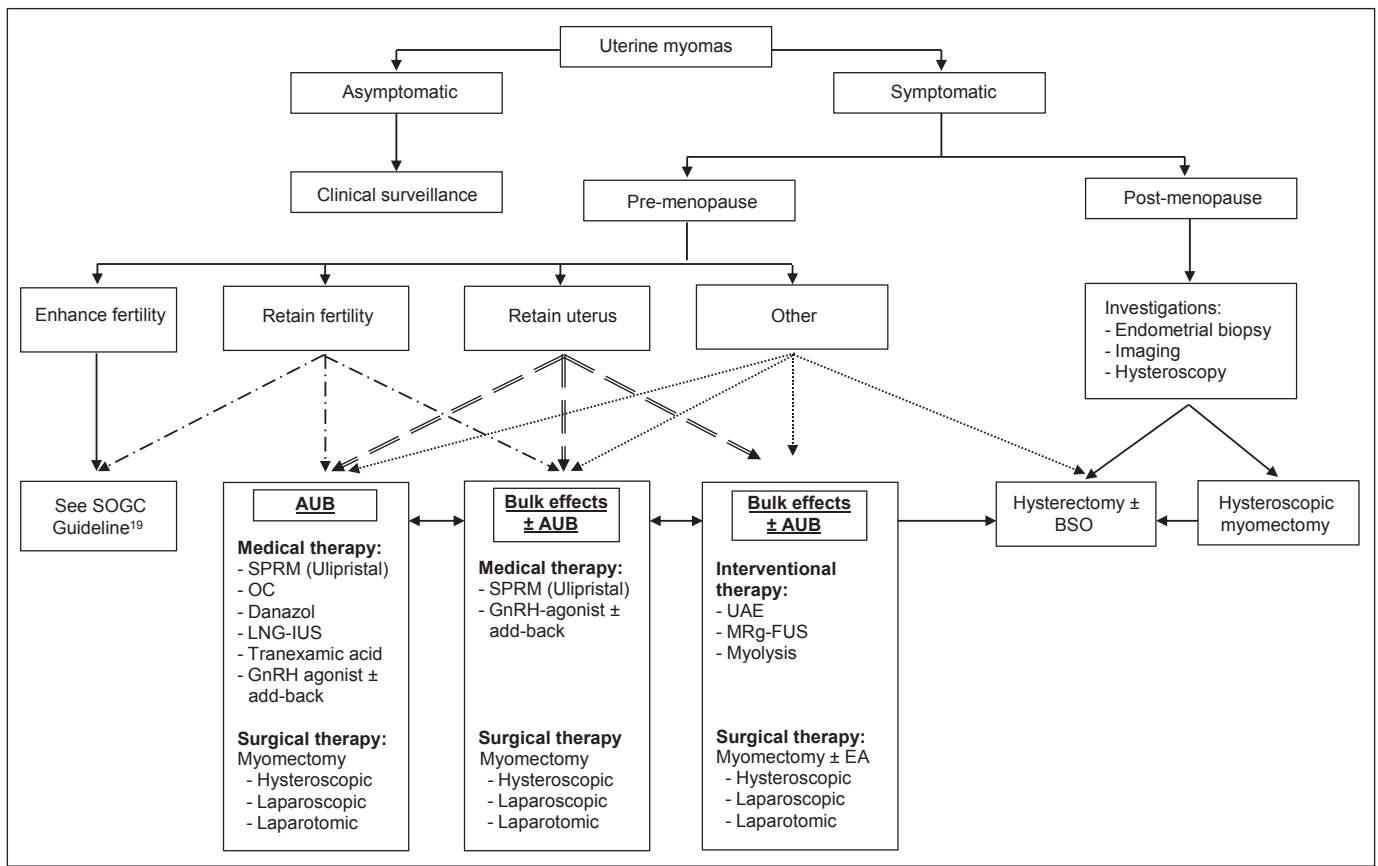
A systematic review reported on both oral progestogens and the LNG-IUS for the treatment of leiomyomas. The authors found that the oral progestogen lynestrenol was not as effective as leuprolin in reducing uterine fibroid size at 16 weeks,<sup>63</sup> and they concluded that evidence was lacking to support the use of progestogens for treating premenopausal women with uterine fibroids.<sup>64</sup>

### Gonadotropin-Releasing Hormone Agonists

GnRH agonists are available in nasal spray, subcutaneous injections, and slow-release injections. In general, fibroids may be expected to shrink by up to 50% of their initial volume within 3 months of therapy. However, GnRH agonist treatment is restricted to a 3- to 6-month interval, following which regrowth of fibroids usually occurs within 12 weeks. Prolonged use of GnRH agonists with estrogen add-back therapy requires investigation. However, there is



Figure 2. Algorithm for the management of uterine myomas



BSO: bilateral salpingo-oophorectomy; MRg-FUS: Magnetic resonance-guided focused ultrasound; OC: oral contraceptives

evidence that progestin add-back negatively impacts the effectiveness of GnRH agonists on fibroid size.<sup>65,66</sup>

GnRH agonists are useful preoperatively to shrink fibroids and to reduce anemia related to uterine bleeding.<sup>47,67</sup>

### Gonadotropin-Releasing Hormone Antagonists

While GnRH agonists work by down-regulation and desensitization of the GnRH receptors, GnRH antagonists work via the classical competitive blockage mechanism. The main advantage of using GnRH antagonists is their lack of the initial “flare” effect seen with GnRH agonist stimulation and supraphysiological amounts of follicle stimulating hormone, luteinizing hormone, and estradiol, and hence have a much shorter onset of action and treatment period.<sup>68,69</sup>

The use of GnRH antagonists as a treatment for fibroids requires further evaluation.

### Androgens (Danazol)

Danazol is chemically related to 17- $\alpha$  ethinyl testosterone. It competes with natural androgens, progesterone, and

glucocorticoids in receptor binding and acts at different levels of the hypothalamic-pituitary-ovarian-uterine axis. Aside from its androgenic effects, it also lowers estrogen levels by suppressing gonadotropin secretion at the levels of the hypothalamus and inhibits ovarian steroidogenesis.<sup>70</sup>

Danazol has been associated with a reduction in volume of fibroids in the order of 20% to 25%.<sup>71</sup> Although the use of danazol for the shrinkage of uterine fibroids has been described in cohort studies, a systematic review did not find any randomized trials comparing its efficacy with placebo or other treatments.<sup>72</sup>

Although the long-term response to danazol is modest, it may offer an advantage in reducing myoma associated heavy menstrual bleeding.<sup>71</sup>

### Aromatase Inhibitors (Letrozole)

Myometrial cultured cells overexpress aromatase P450 and synthesize sufficient estradiol to accelerate their own cell growth. Aromatase inhibitors may serve to block the aromatase activity and growth of leiomyomata.<sup>73</sup>

Letrozole, an aromatase inhibitor, inhibits the conversion of androgen into estrogen. In a systematic review, only one trial involving 70 participants was included. Significantly fewer women reported hot flushes in the letrozole group than in the GnRH agonist group (0/33 vs. 26/27,  $P < 0.05$ ). Use of letrozole reduced fibroid volume by 46% and use of a GnRH agonist by 32% after 12 weeks of treatment, although these results were not statistically significant. The authors concluded that the evidence is currently insufficient to support the use of aromatase inhibitor drugs in the treatment of women with uterine fibroids.<sup>74</sup>

### Estrogen Receptor Antagonists (Fulvestrant)

The estrogen receptor antagonist fulvestrant promotes degradation and down-regulation of estrogen receptors.<sup>75</sup> However, fulvestrant was not as effective as the GnRH agonist goserelin in reducing fibroid and uterine volume and in inducing amenorrhea.<sup>76</sup>

### Selective Estrogen Receptor Modulators

SERMs are nonsteroidal drugs that bind to estrogen receptors and may act as agonists or antagonists to produce tissue-specific effects. They are generally used for treating and preventing recurrence of estrogen receptor positive breast cancers. Tamoxifen has agonist properties on the uterus, but raloxifene is the most studied SERM for treatment of leiomyomata.<sup>77,78</sup> Given the conflicted and limited data regarding the use of raloxifene alone, it is difficult to ascertain its true effect on uterine fibroids, though it may be a useful adjunct to a GnRH agonist in inducing fibroid shrinkage.

### Selective Progesterone Receptor Modulators

Compared with the myometrium, fibroids overexpress estrogen and progesterone receptors,<sup>79</sup> and there is “cross-talk” between ER and PR.<sup>80</sup> It has been shown that fibroids grow primarily during the secretory phase of the menstrual cycle,<sup>81,82</sup> and exogenous progesterone increases mitotic activity and cellularity in fibroids.<sup>83</sup>

In a randomized trial of a GnRH analogue plus add-back therapy with progestin alone versus progestin plus estrogen, the authors reported that, in most instances, the add-back progestin alone (but not the progestin plus estrogen) negated the effects of the GnRH analogue on fibroid volume reduction.<sup>84</sup> Progesterone is therefore essential for fibroid growth, and these observations have stimulated research for the development of progesterone antagonist and/or SPRM drugs. SPRMs are progesterone receptor ligands that have agonist, antagonist, partial, or mixed effects on progesterone target tissues.<sup>85</sup>

While mifepristone is thought to have almost pure antagonistic properties, other SPRMs such as ulipristal acetate exhibit mixed agonist and antagonist properties. Though the exact mechanisms of this new class of medications are still being studied, several studies have evaluated their effectiveness in the shrinkage of fibroids and control of menstrual bleeding symptoms. While several other SPRMs are currently under investigation, here we present the evidence for SPRMs that have been studied in randomized controlled trials.

### Mifepristone

Mifepristone (RU-486) is a progesterone receptor modulator that has almost pure antagonistic properties and may directly decrease the PR in the myometrium and leiomyoma. Though the exact mechanism for myoma size reduction is unclear, a 2013 meta-analysis of 11 RCTs involving 780 premenopausal women with symptomatic leiomyomas concluded that mifepristone significantly reduced uterine and leiomyoma volume and alleviated leioma-related symptoms. The authors recommended 2.5 mg daily for 3 to 6 months as the optimum treatment. There is insufficient evidence that mifepristone treatment led to atypical endometrial hyperplasia.<sup>86</sup>

### Ulipristal acetate

UPA is an SPRM that also exhibits antiproliferative effects on leiomyoma cells and the endometrium.<sup>87</sup> One RCT that investigated the effects of UPA versus placebo before surgical treatment of symptomatic fibroids showed a reduction in myoma volume with 13 weeks of 5 mg and 10 mg of UPA of 21.2% and 12.3%, respectively, while the placebo group had a median 3% growth of myoma volume ( $P < 0.01$ ).<sup>88</sup> Patients also experienced significant decreased uterine bleeding symptoms with treatment.

In a parallel RCT, UPA appeared to be no less effective than leuprolide acetate in controlling heavy menstrual bleeding: 90% of the 5 mg group and 98% of the 10 mg group experienced controlled bleeding symptoms versus 89% of the leuprolide acetate group. Median time to amenorrhea was 7 days, 5 days, and 21 days for the 5 mg, 10 mg, and leuprolide acetate groups, respectively ( $P < 0.001$  for 10 mg vs. leuprolide acetate). However, in terms of uterine volumes, the 47% reduction in the leuprolide acetate group was significantly greater than the reductions of 20% in the 5 mg group and 22% in the 10 mg group. No differences were seen in hemoglobin at the end of the treatment period. Vasomotor symptoms were experienced in 11% of the 5 mg and 10% of the 10 mg groups versus 40% of the leuprolide acetate group ( $P < 0.001$ ).<sup>89</sup>

Novel PRM-associated endometrial changes have been noticed with the SPRM class of drugs and appear to be benign and fully reversible.<sup>89</sup> These changes may be

confused with endometrial hyperplasia by a pathologist who is not informed that the patient received UPA treatment or who has not been updated on the potential effect of UPA on the endometrium. It is important that the pathologist be aware of the use and effects of UPA.

A recent study investigated the efficacy and safety of UPA for long-term treatment of symptomatic uterine fibroids by repeated intermittent 3-month open-label UPA courses (10 mg daily), each followed by randomized double-blind 10-day courses of NETA 10 mg daily or placebo. The study concluded that NETA did not affect fibroid volume or endometrial histology, and repeated 3-month UPA courses effectively and safely controlled bleeding and shrunk fibroids in patients with symptomatic fibroids.<sup>90</sup> Fibroid volume reduction in patients receiving UPA also appears to be maintained in the majority of patients for 6 months after the end of treatment.<sup>88</sup>

### Summary Statements

5. Effective medical treatments for women with abnormal uterine bleeding associated with uterine fibroids include the levonorgestrel intrauterine system, (I) gonadotropin-releasing hormone analogues, (I) selective progesterone receptor modulators, (I) oral contraceptives, (II-2) progestins, (II-2) and danazol. (II-2)
6. Effective medical treatments for women with bulk symptoms associated with fibroids include selective progesterone receptor modulators and gonadotropin-releasing hormone analogues. (I)

### Recommendation

2. Treatment of women with uterine leiomyomas must be individualized based on symptomatology, size and location of fibroids, age, need and desire of the patient to preserve fertility or the uterus, the availability of therapy, and the experience of the therapist. (III-B)

## SURGICAL THERAPIES

### Hysterectomy

In women who have completed childbearing, hysterectomy is indicated as a permanent solution for symptomatic leiomyomas. The only indications for hysterectomy in a woman with completely asymptomatic fibroids are enlarging fibroids after menopause without HRT, which raises concerns of leiomyosarcoma, even though it remains very rare.<sup>91,92</sup> Women with asymptomatic fibroids should be reassured that there is no evidence to substantiate concern about malignancy, and that hysterectomy is not indicated.

Hysterectomy need not be recommended as a prophylaxis

against increased operative morbidity associated with future growth.<sup>93</sup>

### Type of hysterectomy

The choice and type of hysterectomy, whether it is performed by abdominal, laparoscopic, or vaginal route, should be based on surgeon's training, experience, and comfort and on clinical practice guidelines.<sup>93</sup> The least invasive approach feasible should be used.

The advantages of abdominal supracervical or total hysterectomy are questionable, as randomized trials have demonstrated no differences in sexual and urinary function outcomes in women treated with the 2 procedures. However, there may be less blood loss and complications associated with supracervical hysterectomy.<sup>94-96</sup>

### Summary Statement

7. Hysterectomy is the most effective treatment for symptomatic uterine fibroids. (III)

### Myomectomy

Myomectomy is an alternative to hysterectomy for women who wish to retain their uterus, regardless of their fertility desire. Removal of fibroids should be considered if they are thought to be associated with heavy menstrual bleeding, pelvic pain and/or pressure symptoms, and in some cases reproductive issues.<sup>19</sup>

Although myomectomy allows preservation of the uterus, there is a higher risk of blood loss and greater operative time with myomectomy than with hysterectomy, although the risk of ureteric injury may be decreased with myomectomy. Fibroids have a 15% recurrence rate and 10% of women undergoing a myomectomy will eventually require hysterectomy within 5 to 10 years.<sup>97</sup> Risk of recurrence is associated with age, preoperative number of fibroids, uterine size, associated disease, and childbirth after myomectomy.<sup>98</sup> Five years following laparoscopic myomectomy, the cumulative probability of recurrence (new or unremoved fibroids) in women who subsequently gave birth was 42%. In those who did not give birth, it was 55%.<sup>99</sup>

Women should be counselled about the risks of requiring a hysterectomy at the time of a planned myomectomy. This would depend on the intraoperative findings and the course of the surgery. Hysterectomy remains the treatment of choice for the vast majority of women who require a surgical solution.<sup>93</sup>

### Surgical planning

Myomectomy can be performed according to the number, size, and location of fibroids by laparotomy, mini-laparotomy, laparoscopy, hysteroscopy, or a combination of

these.<sup>100</sup> Surgical planning should be based on an accurate mapping of the location, size, and number of fibroids with preoperative imaging. It is particularly important to identify the presence and size of the submucosal component to myomas as this may affect the approach taken.

### Summary Statement

8. Myomectomy is an option for women who wish to preserve their uterus or enhance fertility, but carries the risk of requiring further intervention. (II-2)

### Hysteroscopic myomectomy

An AAGL practice guideline for the diagnosis and management of submucous leiomyomas was published in 2012.<sup>101</sup>

Hysteroscopic myomectomy has been shown to be effective for treatment of AUB in 5 series involving 1422 women. Failure rates ranged from 14.5% to 30% at 3 to 4 years' follow-up.<sup>102</sup> It should be considered as first-line conservative surgical therapy for the management of symptomatic intracavitary fibroids. In general, submucous myomas (types 0, I, and II) up to 4 to 5 cm in diameter can be removed hysteroscopically by experienced surgeons. Type II myomas are more likely to require a 2-staged procedure than types 0 and I because of the risk of excessive fluid absorption and uterine perforation, and caution should be used particularly with those with less than 5 mm thickness between the fibroid and the uterine serosa.<sup>103,104</sup>

### Myomectomy plus endometrial ablation

When the main symptom is heavy menstrual bleeding, consideration should be given to concomitant EA at the time of transcervical resection of myoma when preservation of fertility is not desired. A cohort study showed a higher success rate in controlling bleeding when ablation was added to myomectomy.<sup>105</sup>

In selecting patients for transcervical resection of myoma, it is important to consider other factors that increase the risk of needing subsequent surgery. Women in whom myomectomy results in a normal uterus without residual myomas are at a low risk of requiring further treatment. Predictors of an increased risk for additional treatment include the presence of multiple myomas, large intramural or subserous myomas, adenomyosis, and young age at the time of treatment.<sup>106–108</sup>

Perforation of the uterus can occur with uterine sounding, dilation, or use of the resectoscope. The preoperative use of laminaria or misoprostol decreases the force needed for cervical dilation and reduces the risk of perforation. If perforation occurs with mechanical instruments and no visceral injury is suspected the patient can be observed expectantly. Laparoscopy should be considered if there is

a large defect or heavy bleeding. If perforation occurs with an activated electrode, until proven otherwise a visceral or vascular injury should be assumed, and laparoscopy or laparotomy is recommended.<sup>109,110</sup>

Excessive fluid absorption is another potential risk. An AAGL practice guideline for the management of hysteroscopic distending media was published in 2013.<sup>111</sup> The use of the lowest distention pressure necessary for good visualization and the careful selection of the safest distending medium will lower the risks and sequelae of excessive fluid absorption.<sup>110</sup>

Burns to the vulva, vagina, and cervix from stray electrical current during resectoscopic procedures have been documented.<sup>112–114</sup>

### Laparoscopic myomectomy

The benefits of the laparoscopic approach are well known and have been found superior to laparotomic myomectomy in terms of less blood loss, diminished postoperative pain, fewer overall complications, faster recovery, and significant cosmetic advantage.<sup>115–118</sup> However, laparoscopic myomectomy usually takes longer to accomplish and requires extra training, surgical expertise, and specialized equipment. The size or the number of fibroids that can be removed by laparoscopy seem to be limited only by the surgeon's experience and technique.<sup>119</sup> Multilayer suturing may be challenging, as may the identification and excision of smaller fibroids. Laparoscopic removal of larger fibroids in more difficult locations such as in the lower segment or at the cervical junction may present more risk of complications such as profuse bleeding; in those cases an open approach may be preferable. Consideration should also be given to the prolonged operative time required with the laparoscopic approach when faced with cases of very large (> 10 cm) or multiple leiomyomas; in these cases a myomectomy by laparotomy may be more appropriate.

Injuries can occur with laparoscopic entry, and their occurrence should be minimized by following good surgical principles and the recommendations in the SOGC clinical practice guideline on laparoscopic entry.<sup>120</sup> A prospective study reported that the short-term morbidity of laparoscopic myomectomy was similar to that of laparoscopic hysterectomy.<sup>121</sup>

Uterine scar integrity and rupture following laparoscopic myomectomy have not been fully evaluated. Uterine rupture during subsequent pregnancy seems to be a rare event and its possibility should not systematically preclude a trial of vaginal delivery.<sup>122–124</sup> However,

because of the relatively poor quality of available evidence, close follow-up should be exercised in all cases. Uterine rupture during pregnancy after myomectomy has been reported to possibly be linked to the absence of multilayer closure in cases of deep intramural leiomyoma or to the excessive use of electrosurgical energy.<sup>125,126</sup> Some indirect evidence based on MRI assessment of myometrial repair after Caesarian section suggests that a waiting period of 6 months between myomectomy and subsequent pregnancy would allow for optimal tissue repair of the myometrium.<sup>127</sup>

A meta-analysis of 6 randomized controlled trials from 1996 to 2007 concluded that rates of major complications, pregnancy rates and outcomes, and myoma recurrence in laparoscopic and laparotomic myomectomy were comparable.<sup>115</sup> Two RCTs on laparoscopic versus laparotomic myomectomy reported pregnancy rates of 54% and 57%, respectively.<sup>128,129</sup>

### Mini-laparotomy

Mini-laparotomy, used as an alternative to laparoscopy, has the proposed advantage of easier suturing of the myometrium while providing a less invasive approach than conventional laparotomy. A randomized study of laparoscopic versus mini-laparotomic myomectomy reported lower decline in hemoglobin, reduced postoperative ileus and pain, and shorter hospitalization in the laparoscopy group.<sup>117</sup>

Mini-laparotomy can also be used in laparoscopically assisted mini-laparotomy. In one study, 51 women were randomized to open myomectomy, mini-laparotomy, or laparoscopically-assisted mini-laparotomy. The latter 2 approaches were associated with decreased postoperative pain and less blood loss than myomectomy by laparotomy.<sup>100</sup> In another prospective study of 116 patients, a shorter uterine incision was found in the laparoscopically assisted myomectomy, but the estimated blood loss was greater. Complications and postoperative return to normal activities were comparable between the groups.<sup>130</sup>

### Robotic assisted laparoscopy

Robotic assisted gynaecological surgery has increased exponentially in popularity in the last decade. Up to 9.5% of hysterectomies were done with the assistance of the robot in a retrospective U.S. cohort of 264 758 cases.<sup>131</sup> However, robotic assisted myomectomy was associated in one study with greater blood loss than standard laparoscopic myomectomy.<sup>132</sup> This, along with other well-designed studies that consistently show a longer operative time,<sup>133</sup> prompted the AAGL to state that at this time robotic surgery offers no significant advantage

in benign gynaecological surgery and is more costly than conventional laparoscopic surgery.<sup>134</sup>

### Specimen morcellation

Because laparoscopic hysterectomy and myomectomy often requires morcellation of the specimen, complications related to this step may occur, including vascular or visceral trauma with the use of a mechanical rotating blade.<sup>135</sup> Furthermore, morcellation can lead to dissemination of leiomyoma chips leading to parasitic leiomyomas (leiomyomatosis) or dissemination of incidental leiomyosarcoma.<sup>136-144</sup>

The currently available evidence indicates that one in 400 women undergoing surgery for fibroids is at risk of having a leiomyosarcoma.<sup>39</sup> According to the American Cancer Society's surveillance, epidemiology, and end results data, 5-year survival for leiomyosarcoma is 60% for stage I, 35% for stage II, 22% for stage III, and 15% for stage IV.<sup>145</sup>

An increased rate of recurrence and lower rate of survival following morcellation of a uterine sarcoma has been reported in several studies, implying that morcellation results in the upstaging of the disease. In cases of myomectomy, the initial steps of the procedure, including uterine incision and myoma manipulation and enucleation, are likely to spread and upstage the disease prior to myoma extraction by any method of morcellation.

These findings reinforce the need for careful preoperative assessment of patients and consideration of using enclosed morcellation techniques if feasible. For laparoscopic morcellation, spillage may be minimized by placing the specimen in a bag and using the mechanical morcellator inside the bag. However use of a bag may limit visualization and has not been well studied. For larger specimens, a mini-laparotomy with or without use of self-retaining retractor can be performed and the specimen be morcellated mechanically or with a scalpel blade within a bag. If the specimen is delivered vaginally and requires morcellation, again a bag can be used to enclose it to minimize spillage.

In light of concerns over morcellation of unsuspected leiomyosarcomas, the FDA issued a warning about laparoscopic power morcellation in April 2014. This prompted Health Canada (May 2014) to make the following recommendations to health-care professionals treating women with uterine fibroids<sup>146</sup>:

- Recognize the prevalence of unsuspected uterine sarcoma in patients under consideration for hysterectomy or myomectomy for the treatment of uterine fibroids.
- Consider the treatment alternatives for women with symptomatic uterine fibroids and review these options

**Table 2. Summary of recommendations regarding uterine morcellation**

**Society of Gynecologic Oncology (December 2013)<sup>147</sup>**

The use of power morcellator is generally contraindicated in the presence of documented or highly suspected malignancy, and it may be inadvisable in premalignant conditions or risk-reducing surgery.

No reliable method is currently available to differentiate benign from malignant leiomyomas (leiomyosarcomas or endometrial stromal sarcomas) before they are removed. Furthermore, these diseases offer an extremely poor prognosis even when specimens are removed intact.

Patients and doctors should communicate about the risks, benefits, and alternatives of all procedures so that a patient is able to make an informed and voluntary decision about accepting or declining medical care.

**American Association of Gynecologic Laparoscopists (April 2014)<sup>148</sup>**

Most women with uterine cancer can be diagnosed prior to surgical intervention.

Between 1 in 400 and 1 in 1000 women who undergo hysterectomy for presumed benign uterine myomas will be diagnosed with uterine leiomyosarcoma.

The prognosis of patients with uterine leiomyosarcoma is universally poor and may be worsened in the setting of power morcellation.

**American College of Obstetricians and Gynecologists (May 2014)<sup>149</sup>**

Recommend comprehensive patient counselling and including the following points in consent:

There is a risk of inadvertent uterine leiomyosarcoma diagnosis when a myomectomy/hysterectomy is being performed for a benign leiomyoma (2:1000)

Morcellation will increase peritoneal dissemination if uterine leiomyosarcoma is diagnosed and may worsen patients' prognosis.

Minimally invasive surgical approach does decrease perioperative risks to the patient.

**U.S. Food and Drug Administration (April 2014)<sup>150</sup>**

1 in 350 women undergoing hysterectomy or myomectomy for the treatment of fibroids is found to have an unsuspected uterine cancer.

Laparoscopic power morcellation poses a risk of spreading unsuspected cancerous tissue, notably uterine sarcomas, beyond the uterus.

The FDA discourages the use of laparoscopic power morcellation during hysterectomy or myomectomy for uterine fibroids

with each prospective surgical patient. Apart from a laparoscopic approach, alternative surgical procedures exist that do not require electric morcellation and potential tissue spread to the peritoneal cavity. Also, some surgeons and centres may recommend closed morcellation in a bag as a way to reduce the risk of inadvertent spread of uterine tissue.

- Be aware and inform patients that laparoscopic electric morcellation of unsuspected uterine sarcoma during hysterectomy or myomectomy may disseminate the disease and negatively impact prognosis.

Numerous societies have responded to the FDA warning with very thorough reviews and discussion of the issue (Table 2).<sup>147-150</sup>

**Recommendations**

3. In women who do not wish to preserve fertility and/or their uterus and who have been counselled

- regarding the alternatives and risks, hysterectomy by the least invasive approach possible may be offered as the definitive treatment for symptomatic uterine fibroids and is associated with a high level of satisfaction. (II-2A)
4. Hysteroscopic myomectomy should be considered first-line conservative surgical therapy for the management of symptomatic intracavitary fibroids. (II-3A)
5. Surgical planning for myomectomy should be based on mapping the location, size, and number of fibroids with the help of appropriate imaging. (III-A)
6. When morcellation is necessary to remove the specimen, the patient should be informed about possible risks and complications, including the fact that in rare cases fibroid(s) may contain unexpected malignancy and that laparoscopic power morcellation may spread the cancer, potentially worsening their prognosis. (III-B)

### Pre-operative Evaluation and Adjuncts

Prior to proceeding with surgery for fibroids, appropriate evaluation and patient preparation, including correction of anemia and shrinkage of fibroid and uterine volume, are of paramount importance since preoperative anemia and uterine size can have a significant bearing on surgical outcomes. A recent large study reported that preoperative anemia, even to a mild degree, is independently associated with an increased risk of 30-day morbidity and mortality in patients undergoing major non-cardiac surgery.<sup>151</sup>

For preoperative treatment, a variety of pharmacological agents have been shown to be safe and effective. Iron should be provided in the presence of anemia together with preoperative adjuncts to correct the anemia.

### GnRH agonists

A Cochrane review showed significant improvement with GnRH agonist over placebo or no treatment in preoperative hemoglobin and hematocrit and in reduction of uterine and myoma volumes.<sup>152</sup> Compared with no treatment prior to hysterectomy, GnRH agonists reduce intraoperative bleeding and operative time, increase postoperative hemoglobin and haematocrit values, and decrease postoperative complications and length of hospital stay. They also increase the proportion of hysterectomies performed vaginally rather than abdominally and decrease the proportion of vertical incisions compared with no treatment.<sup>152</sup>

In a 2001 systematic review and meta-analysis, when GnRH agonists were used prior to myomectomy, intraoperative bleeding and rates of vertical incisions were also reduced, while postoperative hemoglobin was slightly increased. However, patients treated with GnRH agonists were more likely to have recurrence of fibroids at 6 months after myomectomy compared to no treatment. No differences were seen in rates of postoperative complications. No differences were seen in rates of blood transfusion for either type of surgery.<sup>153</sup> A 2011 systematic review of GnRH-a showed no reduction in operative time but did show decreased intraoperative blood loss.<sup>154</sup> However there is controversy over the ability to dissect myomas from myometrium after exposure to GnRH agonist.<sup>155</sup>

A double-blind, placebo-controlled trial of GnRH agonist prior to hysteroscopic myomectomy found no differences in the number of complete fibroid resections, operative times, or amounts of fluid absorbed.<sup>156</sup>

### Ulipristal acetate

The 2 RCTs mentioned previously have shown the effectiveness of 3 months' treatment to correct anemia and reduce uterine fibroid size.<sup>89,90</sup> There were no surgical

parameters reported in these studies and surgical experience is variable.

### Intraoperative Adjuncts

A number of intraoperative adjuncts have been used in an effort to reduce blood loss and improve surgical outcomes in leiomyoma surgery.

### Misoprostol

Misoprostol is a prostaglandin E1 analogue which reduces uterine blood flow, increases myometrial contractions, and has potential to reduce blood loss during uterine surgery.<sup>156</sup> The evidence for misoprostol as an adjunct for hysterectomy is limited and conflicting. In one randomized trial, no benefit was observed in the use of misoprostol alone for abdominal hysterectomy, but misoprostol 400 µg by rectum combined with intravenous oxytocin (10 U/hour) in women undergoing laparoscopically assisted vaginal hysterectomy was found to significantly improve operative outcomes compared with placebo.<sup>156</sup>

Placebo-controlled randomized studies have shown that a single dose of misoprostol 400 µg given vaginally 1 hour prior<sup>157</sup> or rectally 30 minutes prior<sup>158</sup> to abdominal myomectomy resulted in a statistically significant reduction in operative time,<sup>157</sup> operative blood loss, postoperative hemoglobin drop, and need for postoperative blood transfusion.<sup>157,158</sup> No differences were observed in length of hospital stay.<sup>157</sup>

The role of misoprostol for cervical priming before operative hysteroscopy has also been reported, though not all patients in this study had fibroids as the indication for surgery. The authors found that the misoprostol group had significantly smaller initial dilation estimated by Hegar dilator, less need for surgical dilation, shorter time for cervical dilation to Hegar 9, shorter operative time, and fewer occurrences of cervical lacerations than the placebo group. Though not statistically significant, there were also fewer instances of false passages (1.4% vs 6.3%) and perforations (0% vs. 2.5%) observed.<sup>159</sup>

### Oxytocin

While recent evidence suggests the presence of oxytocin receptors in uterine myomas,<sup>160</sup> the evidence for its use as an intraoperative adjunct is somewhat conflicting.

One study of women undergoing laparoscopically assisted vaginal hysterectomy indicated reduced blood loss and transfusion rates with intraoperative 20 U of oxytocin in 1000 mL of saline solution running at 40 µg/min compared to saline placebo. No differences were seen in postoperative complications and length of stay.<sup>161</sup>

For myomectomy, a systematic review of 2 randomized trials that compared intraoperative oxytocin against placebo for operative outcomes at myomectomy did not suggest a benefit for operative bleeding, although the pooled numbers may be difficult to interpret due to the significant heterogeneity between the 2 trials.<sup>162</sup>

### Vasopressin

Vasopressin is a naturally occurring hormone that can cause vascular spasm and uterine muscle contraction, and hence has the potential to prevent bleeding during uterine surgery. As there have been several reports of cardiovascular collapse following intra-myometrial injection of vasopressin, caution should be taken to ensure proper dilution and clean communication with the anaesthesiologist.<sup>163</sup>

One randomized trial of women undergoing abdominal hysterectomy for uterine fibroids found that injection of 5 mL of 10 U in 10 mL of normal saline 1 cm medial to the uterine vessels bilaterally decreased total blood loss by approximately 40%. No differences were seen in postoperative hemoglobin, need for transfusion, or operative time.<sup>164</sup>

In a systematic review of interventions to reduce hemorrhage during myomectomy,<sup>162</sup> 2 trials comparing vasopressin to placebo showed a pooled mean difference of 298.7 mL in blood loss.<sup>165,166</sup> No statistical differences were seen in need for blood transfusion, duration of surgery, duration of hospital stay, postoperative adhesions, or pregnancy rates at 1 year after myomectomy.

Two trials compared vasopressin to tourniquets in myomectomy. In one trial, dilute vasopressin (20 units in 20 mL saline injected prior to uterine incision) had effects comparable to mechanical vascular occlusion (Penrose drain tourniquet and vascular clamps at the infundibulopelvic ligament) with respect to blood loss, postoperative morbidity, and transfusion requirements.<sup>166</sup> In contrast, another study reported less blood loss in the vasopressin (20 U in 20 mL) group than in the tourniquet group (512.7 ± 400 mL) ( $P = 0.036$ ). However, no statistically significant differences were seen in the hemoglobin drop, number of transfusions, intraoperative blood pressure, or highest postoperative pulse and temperature.<sup>166</sup>

A recent study compared intraoperative bleeding during laparoscopic myomectomy using dilute vasopressin (6 U in 20 mL) with Roeder knot loop ligation at the base of the fibroid with use of vasopressin alone and with placebo. Blood loss in the placebo (mean ± SD, 363.7 ± 147.8 mL) and vasopressin only (224.4 ± 131.2 mL) groups was significantly reduced by the addition of loop ligation at the base of the myoma (58.7 ± 27.5 mL).<sup>167</sup>

### Bupivacaine and epinephrine

In one study on laparoscopic myomectomy, the use of bupivacaine (50 mL of 0.25%) and epinephrine (0.5 mL of 1 mg/mL) was significantly more effective than placebo in reducing intraoperative bleeding, total operative time, myoma enucleation time, and subjective surgical difficulty as measured on a 1 to 10 visual analogue scale. Analgesic requirement was also reduced in the bupivacaine group ( $P < 0.05$  for all comparisons). No differences in blood pressure or heart rate were observed.<sup>168</sup>

### Antifibrinolytics

Tranexamic acid is a synthetic derivative of lysine with antifibrinolytic activity that has been used to reduce blood loss and need for blood transfusion in surgical procedures.<sup>169</sup> However, only 1 trial has studied its effect during abdominal myomectomy using intravenous tranexamic acid (10 mg/kg patient body weight to a maximum of 1 g) given 15 minutes before skin incision versus placebo. The trial did show average reduced blood loss of 243 mL, but did not reach the authors' level of clinical significance (250 mL).<sup>170</sup>

### Gelatin-thrombin matrix

Gelatin-thrombin matrix is a hemostatic sealant with bovine derived gelatin and thrombin components. In contrast to fibrin glue, gelatin-thrombin matrix is hydrophilic and adheres well to wet tissue. When applied to tissue, the large concentration of thrombin and gelatin can result in rapid hemostasis, which may be useful in gynaecologic surgery.<sup>162</sup>

In one randomized study, application of the gelatin-thrombin matrix to the site of uterine bleeding resulted in less intraoperative and postoperative blood loss than no application during abdominal myomectomy.<sup>162</sup> Five of 25 (20%) patients in the control group required a blood transfusion, while none in the treatment group were transfused ( $P < 0.001$ ).

### Intraoperative Uterine Artery Occlusion

Another option is to perform UAO by laparoscopy at the time of myomectomy, although the benefit seems controversial. In one study comparing laparoscopic myomectomy with or without UAO, blood loss did not differ significantly and operating time was slightly longer when UAO was performed.<sup>171</sup> In another study, the mean operative time was significantly longer (107 minutes vs. 93 minutes;  $P = 0.03$ ), but there was less intraoperative blood loss (84 mL vs. 137 mL;  $P < 0.001$ ) in the UAO group, with no blood transfusions.<sup>172</sup>

### Peri-cervical tourniquet

In 2 trials, occlusion of the uterine artery with or without occlusion of the ovarian arteries significantly reduced



blood loss during myomectomy and the need for blood transfusion.<sup>173,174</sup>

### Anti-adhesion barriers

After the completion of myomectomy, application of anti-adhesion barriers has been proposed and there is evidence of significant reduction in adhesion formation with some of them.<sup>175-177</sup> However, none of these adjuncts has demonstrated an improvement in fertility and pregnancy outcomes.

#### Recommendations

7. Anemia should be corrected prior to proceeding with elective surgery. (II-2A). Selective progesterone receptor modulators and gonadotropin-releasing hormone analogues are effective at correcting anemia and should be considered preoperatively in anemic patients. (I-A)
8. Use of vasopressin, bupivacaine and epinephrine, misoprostol, peri-cervical tourniquet, or gelatin-thrombin matrix reduce blood loss at myomectomy and should be considered. (I-A)

## OTHER CONSERVATIVE TREATMENTS

### Uterine Artery Embolization

An SOGC clinical practice guideline on UAE has been published,<sup>178</sup> and an up-to-date-review of UAE to treat uterine fibroids is included in the upcoming SOGC guideline.<sup>19</sup> UAE is a procedure carried out by interventional radiologists and consists of injecting an occluding agent into one or both uterine arteries. First described in 1995, it has become one of the most common alternative conservative therapies offered to women with symptomatic uterine fibroids. The procedure is minimally invasive and performed with the patient awake, but it is associated with significant immediate post-procedure discomfort, although recovery and return to function are rapid. Very large uteri (over 20 weeks) may not have a clinically significant response. Single submucosal fibroids or subserosal fibroids may respond better to surgery than UAE.

Though successful pregnancies have been reported following UAE,<sup>179</sup> an RCT comparing UAE to myomectomy showed that pregnancy rates were lower and miscarriage rates higher following UAE.<sup>180</sup> This option is still best reserved for women who do not desire future pregnancy.

A 2013 review and meta-analysis reported on complications and re-intervention of UAE for symptomatic uterine fibroids. Common complications were vaginal discharge and fever (4.0%), bilateral UAE

failure (4.0%), and postembolization syndrome (2.9%). The study concluded that overall, UAE has a significantly lower rate of major complications relative to surgery, but it comes at the cost of increased risk of re-intervention in the future.<sup>181</sup>

Educating patients about the rate and types of complications of UAE versus surgery, as well as the potential for reintervention, should help the patient and clinician come to a reasoned decision.

#### Recommendation

9. Uterine artery occlusion by embolization or surgical methods may be offered to selected women with symptomatic uterine fibroids who wish to preserve their uterus. Women choosing uterine artery occlusion for the treatment of fibroids should be counselled regarding possible risks, including the likelihood that fecundity and pregnancy outcomes. (II-3A)

### Focused Energy Delivery Systems

A number of focused energy delivery systems have been tested in the past decade including those based upon radiofrequency electricity, supercooled cryoprobes, and most recently, MRg-FUS or high frequency ultrasound guided transcatheter focused ultrasound ablation.<sup>182-185</sup>

A major disadvantage of all systems and techniques used to desiccate or ablate fibroids may be that they treat one fibroid at a time and they target the centre of fibroids, while fibroids have been shown to grow mostly from their periphery.<sup>186</sup>

These technologies are relatively new and although many are promising, they often lack long-term data, which interferes with our ability to present all risks and benefits with assurance. Ongoing research and data collection are required to assess the relative merit of newer options as the technology continues to expand.

### MR-guided focused ultrasound

The ExAblate 2000 (InSightec Inc., Haifa, Israel) was the first clinical MRg-FUS system approved by the FDA for treating uterine fibroids. Case series for MRg-FUS ranging from 51 to 359 patients have been published and short-term efficacy is adequate, but complications such as skin burns have occurred in up to 7% of patients and at least one bowel perforation was reported.<sup>182,187,188</sup> Disadvantages of the MRg-FUS system include high exclusion rate, requirement of an MR machine, prolonged time (minutes to several hours), treatment of 1 fibroid at a time, and ablation of fibroids centrally, while fibroids seem to grow peripherally.

## Radiofrequency myolysis

A new development in laparoscopic myolysis involves delivering of RF energy to myomas under ultrasonic guidance in an attempt to desiccate them directly. The Acessa RFVTA system by Hault Medical has been approved for fibroid treatment in Canada. Mapping of myomas is performed by laparoscopic and ultrasound visualization. When a myoma is targeted for ablation, the RF probe is inserted percutaneously under laparoscopic guidance through a 2-mm skin incision. A recent multicentre trial concluded that RFVTA of myomas is well tolerated and results in rapid recovery, high patient satisfaction, improved quality of life, and effective symptom relief.<sup>189</sup> Total mean fibroid volume was reduced by 45.1% and mean blood loss by 38.3% at 12 months post-procedure. Disadvantages of the Hault System include the requirement of laparoscopy and concomitant use of ultrasound, additional percutaneous skin incision(s), its treatment of 1 fibroid at a time (< 8 cm diameter), and its ablation of fibroids centrally while fibroids grow peripherally.

### Summary Statements

9. Of the conservative interventional treatments currently available, uterine artery embolization has the longest track record and has been shown to be effective in properly selected patients. (II-3)
10. Newer focused energy delivery methods are promising but lack long-term data. (III)

## SPECIAL CONSIDERATIONS

### Acute Uterine Bleeding

Acute uterine bleeding unrelated to pregnancy has been defined as that which is sufficient in volume, in the opinion of the treating clinician, to require urgent or emergent intervention.<sup>190</sup> Women with fibroids may present with acute intraperitoneal or vaginal hemorrhage, which can become life-threatening on rare occasions. Since acute uterine bleeding may or may not be associated with leiomyomas, the approach to investigation and treatment should be the same.<sup>45</sup>

Endometrial biopsy and sonographic and hysteroscopic evaluation of the uterine cavity may be limited because of patient instability, excessive bleeding, and/or blood clots. Although the evidence is very limited, after resuscitation is initiated and other causes of bleeding are ruled out by history, physical examination, and preliminary imaging, the usual approach used for acute uterine bleeding should be for uterine hemorrhage associated with fibroids.<sup>17,191,192</sup>

Only a few treatments used for acute bleeding have been studied in the context of uterine fibroids.

Tranexamic acid, 1 g intravenously over 10 minutes or orally, 3 times daily for 5 to 7 days, has also been shown to be relatively effective when used to treat heavy menstrual bleeding in patients with fibroids.<sup>193–195</sup> There is no evidence that tranexamic acid increases the incidence of thromboembolic disease, even when used in women at high risk. The risk of thromboembolism is less than 1%.<sup>196,197</sup>

Of all the hormonal options available for women with fibroids, ulipristal acetate has the most rapid documented onset of action and control of bleeding, with 80% of women achieving a pictorial blood assessment chart score < 75 within 7 days. However in the published studies, the treatment was initiated at onset of regular menses, and the results may not be applicable to intermenstrual bleeding or acute hemorrhage.<sup>198</sup>

Placement of an intrauterine Foley catheter has been described as a method to temporize bleeding until hormonal/medical therapies can take effect. The Foley balloon is left inflated for 1 to 48 hours depending on a number of factors, including the suspected cause of the bleeding.<sup>199,200</sup>

Occasionally, fibroids are found prolapsing through the cervix and their removal (myoma extraction) will usually stop the bleeding. Submucous fibroids may bleed heavily and some may prolapse through the cervix after initiation of GnRH agonist therapy or treatment by uterine fibroid embolization.<sup>201</sup>

There are case reports of emergency EA to control acute uterine bleeding.<sup>202,203</sup> EA and hysteroscopic myomectomy of submucous fibroids associated with bleeding is an option, but may be technically difficult due to poor visualization. If the woman does not respond to conservative measures, UAE can be performed if it is readily available. In cases where the bleeding is severe and not responsive to any of these measures, an emergency hysterectomy may need to be performed.

### Recommendation

10. In women who present with acute uterine bleeding associated with uterine fibroids, conservative management with estrogens, selective progesterone receptor modulators, antifibrinolytics, Foley catheter tamponade, and/or operative hysteroscopic intervention may be considered, but hysterectomy may become necessary in some cases. In centres where available, intervention by uterine artery embolization may be considered. (III-B)

## REFERENCES

- Day Baird D, Dunson DB, Hill MC, Cousins D, Schectman JM. High cumulative incidence of uterine leiomyoma in black and white women: ultrasound evidence. *Am J Obstet Gynecol* 2003;188:100–7.
- Marshall LM, Spiegelman D, Barbieri RL, Goldman MB, Manson JE, Colditz GA, et al. Variation in the incidence of uterine leiomyoma among premenopausal women by age and race. *Obstet Gynecol* 1997;90:967–73.
- Cramer SF, Patel A. The frequency of uterine leiomyomas. *Am J Clin Pathol* 1990;94:435–8.
- Zimmermann A, Bernuit D, Gerlinger C, Schaefer M, Geppert K. Prevalence, symptoms and management of uterine fibroids: an international internet-based survey of 21,746 women. *BMC Womens Health* 2012;12:6 (26 March 2012). Available at: <http://www.biomedcentral.com/1472-6874/12/6>. Accessed on November 10, 2014.
- Downes E, Sikirica V, Gilabert-Estelles J, Bolge SC, Dodd SL, Maroulis C, et al. The burden of uterine fibroids in five European countries. *Eur J Obstet Gynecol Reprod Biol* 2010;152:96–102.
- Pritts EA, Parker WH, Olive DL. Fibroids and infertility: an updated systematic review of the evidence. *Fertil Steril* 2009;91:1215–23.
- Vilos GA, Vilos A, Ferrazzi S. Symptomatic uterine fibroids (UFs) are common in premenopausal Canadian women and lead to reduced quality of life (QoL) across multiple domains. *J Obstet Gynecol Can* 2014;36(6 Suppl 1):S26. [abstract]
- Canadian Institute for Health Information, Statistics Canada. Health indicators. Ottawa: CIHI; 2010. Available at: [https://secure.cihi.ca/free\\_products/Healthindicators2010\\_en.pdf](https://secure.cihi.ca/free_products/Healthindicators2010_en.pdf). Accessed on November 10, 2014.
- Boyd LR, Novesky AP, Curtin JP. Effect of surgical volume on route of hysterectomy and short-term morbidity. *Obstet Gynecol* 2010;116:909–15.
- Clark-Pearson DL, Geller EL. Complications of hysterectomy. *Obstet Gynecol* 2013;121:654–73.
- Bulun SE. Uterine fibroids. *N Engl J Med* 2013;369:1344–55.
- Munro MG, Critchley HO, Broder MS, Fraser IS. The FIGO Classification System (“PALM-COEIN”) for causes of abnormal uterine bleeding in non-gravid women in the reproductive years, including guidelines for clinical investigation. *Int J Gynaecol Obstet* 2011;113:3–13.
- Flake GP, Andersen J, Dixon D. Etiology and pathophysiology of uterine leiomyomas; a review. *Environ Health Perspect* 2003;111:1037–54.
- Buttram VC, Reiter RC. Uterine leiomyomata: etiology, symptomatology and management. *Fertil Steril* 1981;36:433–45.
- Lumsden MA, Wallace EM. Clinical presentation of uterine fibroids. *Baillieres Clin Obstet Gynaecol* 1998;12:177–95.
- Miura S, Khan KN, Kitajima M, Hiraki K, Moriyama S, Masuzaki H, et al. Differential infiltration of macrophages and prostaglandin by different uterine leiomyomas. *Hum Reprod* 2006;21:2545–54.
- Singh S, Best C, Dunn S, Leyland N, Wolfman W; Society of Obstetrics and Gynaecology Canada Clinical Practice – Gynaecology Committee. Abnormal uterine bleeding in pre-menopausal women. SOGC Clinical Practice Guidelines, No. 292, May 2013. *J Obstet Gynaecol Can* 2013;35(5 Suppl 1):473–9.
- Schwartz LB, Diamond MP, Schwartz PE. Leiomyosarcomas: clinical presentation. *Am J Obstet Gynecol* 1993;168(1 Pt 1):180–3.
- Carranza-Mamane B, Havelock J, Hemmings R; Society of Obstetrics and Gynaecology Canada Reproductive Endocrinology and Infertility Committee. The management of uterine fibroids in women with otherwise unexplained infertility. SOGC Clinical Practice Guidelines. *J Obstet Gynaecol Can* 2015 (in press).
- Laughlin SK, Baird DD, Savitz DA, Herring AH, Hartmann KE. Prevalence of uterine leiomyomas in the first trimester of pregnancy: an ultrasound-screening study. *Obstet Gynecol* 2009;113:630–5.
- Muram D, Gillieson M, Walters JH. Myomas of the uterus in pregnancy: ultrasonographic follow-up. *Am J Obstet Gynecol* 1980;138:16–9.
- Neiger R, Sonek JD, Croom CS, Ventolini G. Pregnancy-related changes in the size of uterine leiomyomas. *J Reprod Med* 2006;51:671–4.
- Hammoud AO, Asaad R, Berman J, Treadwell MC, Blackwell S, Diamond MP. Volume change of uterine myomas during pregnancy: do myomas really grow? *J Minim Invasive Gynecol* 2006;13:386–90.
- Laughlin SK, Herrings AH, Savitz DA, Olsham AF, Fielding JR, Hartman KE, et al. Pregnancy-related fibroid reduction. *Fertil Steril* 2010;94:2421–3.
- De Vivo A, Mancuso A, Giacobbe A, Savasta LM, De Dominicis R, Dugo N, et al. Uterine myomas during pregnancy: a longitudinal sonographic study. *Ultrasound Obstet Gynecol* 2011;37:361–5.
- Exacoustos C, Rosati P. Ultrasound diagnosis of uterine myomas and complications in pregnancy. *Obstet Gynecol* 1993;82:97–101.
- Sheiner E, Bashiri A, Levy A, Hershkovitz R, Katz M, Mazor M. Obstetric characteristics and perinatal outcome of pregnancies with uterine leiomyomas. *J Reprod Med* 2004;49:182–6.
- Qidwai GI, Caughey AB, Jacoby AF. Obstetric outcomes in women with sonographically identified uterine leiomyomata. *Obstet Gynecol* 2006;107(2 Pt 1):376–82.
- Vergani P, Locatelli A, Ghidini A, Andreani M, Sala F, Pezzullo JC. Large uterine leiomyomata and risk of cesarean delivery. *Obstet Gynecol* 2007;109(2 Pt 1):410–4.
- Chen YH, Lin HC, Chen SF, Lin HC. Increased risk of preterm births among women with uterine leiomyoma: a nationwide population-based study. *Hum Reprod* 2009;24:3049–56.
- Klatsky PC, Tran ND, Caughey AB, Fujimoto VY. Fibroids and reproductive outcomes: a systematic literature review from conception to delivery. *Am J Obstet Gynecol* 2008;198:357–66.
- Stout MJ, Odibo AO, Graseck AS, Macones GA, Crane JP, Cahill AG. Leiomyomas at routine second-trimester ultrasound examination and adverse obstetric outcomes. *Obstet Gynecol* 2010;116:1056–63.
- Lolis DE, Kalantaridou SN, Makrydimas G, Sotiriadis A, Navrozoglou I, Zikopoulos K, et al. Successful myomectomy during pregnancy. *Hum Reprod* 2003;18:1699–702.
- Mu YL, Wang S, Hao J, Shi M, Yelian FD, Wang XT. Successful pregnancies with uterine leiomyomas and myomectomy at the time of caesarean section. *Postgrad Med J* 2011;87:601–4.
- Gbadebo AA, Charles AA, Austin O. Myomectomy at caesarean section: descriptive study of clinical outcome in a tropical setting. *J Ayub Med Coll Abbottabad* 2009;21:7–9.
- Park BJ, Kim YW. Safety of cesarean myomectomy. *J Obstet Gynaecol Res* 2009;35:906–11.
- Parker WH, Fu YS, Berek JS. Uterine sarcoma in patients operated on for presumed leiomyoma and rapidly growing leiomyoma. *Obstet Gynecol* 1994;83:414–8.
- Leibsohn S, d’Ablaing G, Mishell DR Jr., Schlaerth JB. Leiomyosarcoma in a series of hysterectomies performed for presumed uterine leiomyomas. *Am J Obstet Gynecol* 1990;162:968–74; discussion 974–6.
- Knight J, Falcone T. Tissue extraction by morcellation: a clinical dilemma. *J Min Invas Gynecol* 2014;21:319–20.
- Vilos GA, Harding PG, Sugimoto AK, Ettler HC, Bernier MJ. Hysteroscopic endomyometrial resection of three uterine sarcomas. *J Am Assoc Gynecol Laparosc* 2001;8:545–51.

41. Vilos GA, Edris F, Abu-Rafea B, Hollett-Caines J, Ettlter HC, Al-Mubarak A. Miscellaneous uterine malignant neoplasms detected during hysteroscopic surgery. *J Min Invas Gynecol* 2009;16:318–25.
42. Ip PP, Tse KY, Tam KF. Uterine smooth muscle tumors other than the ordinary leiomyomas and leiomyosarcomas: a review of selected variants with emphasis on recent advances and unusual morphology that may cause concern for malignancy. *Adv Anat Pathol* 2010;17:91–112.
43. Vilos GA, Marks J, Ettlter HC, Vilos AG, Prefontaine M, Abu-Rafea B. Uterine smooth muscle tumors of uncertain malignant potential; diagnostic challenges and therapeutic dilemmas. Report of 2 cases and review of literature. *J Min Invas Gynecol* 2012;19:288–95.
44. Cantuaria GH, Anglioli R, Frost L, Duncan R, Penalver MA. Comparison of bimanual examination with ultrasound before hysterectomy for uterine leiomyoma. *Obstet Gynecol* 1998;92:109–12.
45. Farquhar C, Ekeroma A, Furness S, Arroll B. A systematic review of transvaginal ultrasonography, sonohysterography and hysteroscopy for the investigation of abnormal uterine bleeding in premenopausal women. *Acta Obstet Gynecol Scand* 2003;82:493–504.
46. Makris N, Kalmantis K, Startados N, Papadimitriou A, Mantzaris G, Antsaklis A. Three dimensional hysterosonography versus hysteroscopy for the detection of intracavitary uterine abnormalities. *Int J Gynecol Obstet* 2007;95:6–9.
47. Vercellini P, Crosignani PG, Mangioni C, Imperato E, Ferrari A, De Giorgi O. Treatment with a gonadotrophin releasing hormone agonist before hysterectomy for leiomyomas: results of a multicentre, randomized controlled trial. *Br J Obstet Gynaecol* 1998;105:1148–54.
48. Bradley LD, Falcone T, Magen AB. Radiographic imaging techniques for the diagnosis of abnormal uterine bleeding. *Obstet Gynecol Clin North Am* 2000;27:245–76.
49. Adusumilli S, Hussain HK, Caoili EM, Weadock WJ, Murray JP, Johnson TD, et al. MRI of sonographically indeterminate adnexal masses. *AJR Am J Roentgenol* 2006;187:732–40.
50. Dueholm M, Lundorf E, Hansen ES, Ledertoug S, Olesen F. Accuracy of magnetic resonance imaging and transvaginal ultrasonography in the diagnosis, mapping, and measurement of uterine myomas. *Am J Obstet Gynecol* 2002;186:409–15.
51. Omary RA, Vasireddy S, Chrisman HB, Ryu RK, Pereles FS, Carr JC, et al. The effect of pelvic MR imaging on the diagnosis and treatment of women with presumed symptomatic uterine fibroids. *J Vasc Interv Radiol* 2002;13:1149–53.
52. Stamatopoulos CP, Mikos T, Grimbizis GF, Dimitriadis AS, Efstratiou I, Stamatopoulos P, et al. Value of magnetic resonance imaging in diagnosis of adenomyosis and myomas of the uterus. *J Min Invas Gynecol* 2012;19:620–6.
53. Myers ER, Barber MD, Gustilo-Ashby T, Couchman G, Matchar DB, McCrory DC. Management of uterine leiomyomata: what do we really know? *Obstet Gynecol* 2002;100:8–17.
54. Peddada SD, Laughlin SK, Miner K, Guyon JP, Haneke K, Vahdat HL, et al. Growth of uterine leiomyomata among premenopausal black and white women. *Proc Natl Acad Sci USA*. 2008;105:19887–92.
55. DeWaay DJ, Syrop CH, Nygaard IE, Davis WA, Van Voorhis BJ. Natural history of uterine polyps and leiomyomata. *Obstet Gynecol* 2002;100:3–7.
56. Ang WC, Farrell E, Vollenhoven B. Effect of hormone replacement therapies and selective estrogen receptor modulators in postmenopausal women with uterine leiomyomas: a systematic review. *Climacteric* 2001;4:284–92.
57. Yang CH, Lee JN, Hsu SC, Kuo CH, Tsai EM. Effect of hormone replacement therapy on uterine fibroids in postmenopausal women—a 3-year study. *Maturitas* 2002;43:35–9.
58. Al-Hendy A, Salama S. Gene therapy and uterine leiomyoma: a review. *Hum Reprod Update* 2006;12:385–400.
59. Sayed GH, Zakherah MS, El-Nashar SA, Shaaban MM. A randomized clinical trial of a levonorgestrel-releasing intrauterine system and a low-dose combined oral contraceptive for fibroid-related menorrhagia. *Int J Gynaecol Obstet* 2011;112:126–30.
60. Maruo T, Ohara N, Yoshida S, Nakabayashi K, Sasaki H, Xu Q, et al. Translational research with progesterone receptor modulator motivated by the use of levonorgestrel-releasing intrauterine system. *Contraception* 2010;82:435–41.
61. Englund K, Blanck A, Gustavsson I, Lundkvist U, Sjöblom P, Norgren A, et al. Sex steroid receptors in human myometrium and fibroids: changes during the menstrual cycle and gonadotropin-releasing hormone treatment. *J Clin Endocrinol Metab* 1998 11;83:4092–6.
62. Magalhães J, Aldrighi JM, de Lima GR. Uterine volume and menstrual patterns in users of the levonorgestrel-releasing intrauterine system with idiopathic menorrhagia or menorrhagia due to leiomyomas. *Contraception* 2007;75:193–8.
63. Verspyck E, Marpeau L, Lucas C. Leuprorelin depot 3.75 mg versus lynestrenol in the preoperative treatment of symptomatic uterine myomas: a multicentre randomised trial. *Eur J Obstet Gynecol Reprod Biol* 2000;89:7–13.
64. Sangkomkham US, Lumbiganon P, Laopaiboon M, Mol BW. Progestogens or progestogen-releasing intrauterine systems for uterine fibroids. *Cochrane Database Syst Rev* 2013;2:CD008994.
65. Carr BR, Marshburn PB, Weatherall PT, Bradshaw KD, Breslau NA, Byrd W, et al. An evaluation of the effect of gonadotropin-releasing hormone analogs and medroxyprogesterone acetate on uterine leiomyomata volume by magnetic resonance imaging: a prospective, randomized, double blind, placebo-controlled, crossover trial. *J Clin Endocrinol Metab* 1993;76:1217–23.
66. Friedman AJ, Daly M, Juneau-Norcross M, Rein MS, Fine C, Gleason R, et al. A prospective, randomized trial of gonadotropin-releasing hormone agonist plus estrogen-progestin or progestin “add-back” regimens for women with leiomyomata uteri. *J Clin Endocrinol Metab* 1993;76:1439–45.
67. Friedman AJ, Hoffman DI, Comite F, Browneller RW, Miller JD. Treatment of leiomyomata uteri with leuprolide acetate depot: a double-blind, placebo-controlled, multicenter study. The Leuprolide Study Group. *Obstet Gynecol* 1991;77:720–5.
68. Reissmann T, Diedrich K, Comaru-Schally AM, Schally AV. Introduction of LHRH-antagonists into the treatment of gynaecological disorders. *Human Reprod* 1994;9:767–9.
69. Britten JL, Malik M, Levy G, Mendoza M, Catherino WH. Gonadotropin-releasing hormone (GnRH) agonist leuprolide acetate and GnRH antagonist cetrorelix acetate directly inhibit leiomyoma extracellular matrix production. *Fertil Steril* 2012;98:1299–307.
70. Panidis D, Vavilis D, Rousso D, Stergiopoulos K, Kalogeropoulos A. Danazol influences gonadotropin secretion acting at the hypothalamic level. *Int J Gynaecol Obstet* 1994;45:241–6.
71. ACOG Committee on Practice Bulletins-Gynecology. ACOG practice bulletin: surgical alternatives to hysterectomy in the management of leiomyomas. *Int J Gynaecol Obstet* 2001;73:285–94.
72. Ke LQ, Yang K, Li J, Li CM. Danazol for uterine fibroids. *Cochrane Database Syst Rev* 2009;3:CD007692.
73. Sumitani H, Shozu M, Segawa T, Murakami K, Yang HJ, Shimada K, et al. In situ estrogen synthesized by aromatase P450 in uterine leiomyoma cells promotes cell growth probably via an autocrine/intracrine mechanism. *Endocrinology* 2000;141:3852–61.
74. Song H, Lu D, Navaratnam K, Shi G. Aromatase inhibitors for uterine fibroids. *Cochrane Database Syst Rev* 2013;10:CD009505.
75. Wakeling AE, Dukes M, Bowler J. A potent specific pure antiestrogen with clinical potential. *Cancer Res* 1991;51:3867–73.

76. Donnez J, Hervais Vivancos B, Kudela M, Audebert A, Jadoul P. A randomized, placebo-controlled, dose-ranging trial comparing fulvestrant with goserelin in premenopausal patients with uterine fibroids awaiting hysterectomy. *Fertil Steril* 2003;79:1380–9.
77. Dutertre M, Smith CL. Molecular mechanisms of selective estrogen receptor modulator (SERM) action. *J Pharmacol Exp Ther* 2000;295:431–7.
78. Deng L, Wu T, Chen XY, Xie L, Yang J. Selective estrogen receptor modulators (SERMs) for uterine leiomyomas. *Cochrane Database Syst Rev* 2012;10:CD005287.
79. Chegini N, Ma C, Tang XM, Williams RS. Effects of GnRH analogues, 'add-back' steroid therapy, antiestrogen and antiprogesterins on leiomyoma and myometrial smooth muscle cell growth and transforming growth factor-beta expression. *Mol Hum Reprod* 2002;8:1071–8.
80. Maruo T, Ohara N, Wang J, Matsuo H. Sex steroidal regulation of uterine leiomyoma growth and apoptosis. *Hum Reprod Update* 2004;10:207–20.
81. Kawaguchi K, Fujii S, Konishi I, Nanbu Y, Nonogaki H, Mori T. Mitotic activity in uterine leiomyomas during the menstrual cycle. *Am J Obstet Gynecol* 1989;160:637–41.
82. Kawaguchi K, Fujii S, Konishi I, Iwai T, Nanbu Y, Nonogaki H, et al. Immunohistochemical analysis of oestrogen receptors, progesterone receptors and Ki-67 in leiomyoma and myometrium during the menstrual cycle and pregnancy. *Virchows Arch A Pathol Anat Histopathol* 1991;419:309–15.
83. Seegaloff A, Weed JC, Sternberg WH, Parson W. The progesterone therapy of human uterine leiomyomas. *J Clin Endocrinol Metab* 1949;9:1273–91.
84. Friedman AJ, Daly M, Juneau-Norcross M, Gleason R, Rein MS, LeBoff M. Long-term medical therapy for leiomyomata uteri: a prospective, randomized study of leuprolide acetate depot plus either oestrogen-progestin or progestin 'add-back' for 2 years. *Hum Reprod* 1994;9:1618–25.
85. Chwalisz K, Perez MC, Demanno D, Winkel C, Schubert G, Elger W. Selective progesterone receptor modulator development and use in the treatment of leiomyomata and endometriosis. *Endocr Rev* 2005;26:423–38.
86. Shen Q, Hua Y, Jiang W, Zhang W, Chen M, Zhu X. Effects of mifepristone on uterine leiomyoma in premenopausal women: a meta-analysis. *Fertil Steril* 2013;100:1722–6.
87. Chabbert-Buffet N, Pintiaux-Kairis A, Bouchard P; VA2914 Study Group. Effects of the progesterone receptor modulator VA2914 in a continuous low dose on the hypothalamic-pituitary-ovarian axis and endometrium in normal women: a prospective, randomized, placebo-controlled trial. *J Clin Endocrinol Metab* 2007;92:3582–9.
88. Donnez J, Tatarchuk TF, Bouchard P, Puscasiu L, Zakharenko NF, Ivanova T, et al. Ulipristal acetate versus placebo for fibroid treatment before surgery. *N Engl J Med* 2012;366:409–20.
89. Donnez J, Tomaszewski J, Vazquez F, Bouchard P, Lemieszczuk B, Baro F, et al. Ulipristal acetate versus leuprolide acetate for uterine fibroids. *N Engl J Med* 2012;366:421–32.
90. Donnez J, Vazquez F, Tomaszewski J, Nouri K, Bouchard P, Fauser B, et al. PEARL III and PEARL III Extension Study Group. Long-term treatment of uterine fibroids with ulipristal acetate\*. *Fertil Steril* 2014;101(6):1565–73.
91. Weber AM, Mitchinson AR, Gidwani GP, Mascha E, Walters MD. Uterine myomas and factors associated with hysterectomy in premenopausal women. *Am J Obstet Gynecol* 1997;176:1213–7.
92. Friedman AJ, Haas ST. Should uterine size be an indication for surgical intervention in women with myomas? *Am J Obstet Gynecol* 1993;168 (3 Pt 10):751–5.
93. Lefebvre G, Allaire A, Jeffrey J, Vilos G. Hysterectomy; Society of Obstetricians Clinical Practice Committee. SOGC Clinical Practice Guidelines, No. 109, January 2002. *J Obstet Gynaecol Can* 2002;24:37–48.
94. Thakar R, Ayers S, Clarkson P, Stanton S, Manyonda I. Outcomes after total versus subtotal abdominal hysterectomy. *N Engl J Med* 2002;347:1318–25.
95. Learman LA, Summitt RL Jr, Varner RE, McNeely SG, Goodman-Gruen D, Richter HE, et al; Total or Supracervical Hysterectomy (TOSH) Research Group. A randomized comparison of total or supracervical hysterectomy: surgical complications and clinical outcomes. *Obstet Gynecol* 2003;102:453–62.
96. American Association of Gynecologic Laparoscopists (AAGL). Practice report: practice guidelines for laparoscopic/subtotal supracervical hysterectomy. *J Min Invas Gynecol* 2014;21:9–16.
97. Garcia CR. Management of the symptomatic fibroid in women older than 40 years of age: hysterectomy or myomectomy? *Obstet Gynecol Clin North Am* 1993;20:337–48.
98. Yoo EH, Lee PI, Huh CY, Kim DH, Lee BS, Lee JK, et al. Predictors of leiomyoma recurrence after laparoscopic myomectomy. *J Minim Invasive Gynecol* 2007;14:690–7.
99. Al-Mahrizi S, Tulandi T. Treatment of uterine fibroids for abnormal uterine bleeding: myomectomy and uterine artery embolization. *Best Pract Res Clin Obstet Gynaecol* 2007;21:995–1005.
100. Cagnacci A, Pirillo D, Malmusi S, Arangino S, Alessandrini C, Volpe A. Early outcome of myomectomy by laparotomy, minilaparotomy and laparoscopically assisted minilaparotomy. A randomized prospective study. *Hum Reprod* 2003;18:2590–4.
101. American Association of Gynecologic Laparoscopists (AAGL): Advancing Minimally Invasive Gynecology Worldwide. AAGL practice report: practice guidelines for the diagnosis and management of submucous leiomyomas. *J Minim Invasive Gynecol* 2012;19:152–71.
102. Munro MG. Abnormal uterine bleeding: surgical management – part 3. *J Am Assoc Gynecol Laparosc* 2001;8:18–47.
103. College National des Gynécologues et Obstétriciens Français (CNGOF). Actualisation de la prise en charge des myomes [Myoma management recommandations]. *J Gynecol Obstet Biol Reprod* 2011;40:693–708.
104. Wamsteker K, Emanuel MH, de Kruif JH. Transcervical hysteroscopic resection of submucous fibroids for abnormal uterine bleeding: results regarding the degree of intramural extension. *Obstet Gynecol* 1993;82:736–40.
105. Loffer FD. Improving results of hysteroscopic submucosal myomectomy for menorrhagia by concomitant endometrial ablation. *J Min Invas Gynecol* 2005;12:254–60.
106. Emanuel MH, Wamsteker K, Hart AA, Metz G, Lammes FB. Long-term results of hysteroscopic myomectomy for abnormal uterine bleeding. *Obstet Gynecol* 1999;93(5 Pt 1):743–8.
107. Hart R, Molnar BG, Magos A. Long-term follow-up of hysteroscopic myomectomy assessed by survival analysis. *Br J Obstet Gynaecol* 1999;106:700–5.
108. Margiani R, Mossa B, Ebano V, Perniola G, Melluso J, Napolitano C. Transcervical myomectomy: long-term effects on abnormal uterine bleeding. *Clin Exp Obstet Gynecol* 2005;32:23–6.
109. Bradley LD. Complications in hysteroscopy: prevention, treatment and legal risk. *Curr Opin Obstet Gynecol* 2002;14:409–15.
110. Vilos GA. Chapter on hysteroscopic surgery: indications, contraindications and complications. In: Pasic R, Levine RA. *Practical manual of hysteroscopy and endometrial ablation: a clinical cookbook*. Boca Raton, FL: CRC Press 2004:237–58.

111. AAGL Advancing Minimally Invasive Gynecology Worldwide, Munro MG, Storz K, Abbott JA, Falcone T, Jacobs VR, et al. AAGL practice report. practice guidelines for the management of hysteroscopic distending media. *J Minim Invasive Gynecol* 2013;20:137–48.
112. Vilos GA, Brown S, Graham G, McCulloch S, Borg P. Genital tract electrical burns during hysteroscopic endometrial ablation: report of 13 cases in the United States and Canada. *J Am Assoc Gynecol Laparosc* 2000;7:141–7.
113. Vilos GA, McCulloch S, Borg P, Zheng W, Denstedt J. Intended and stray radiofrequency electrical currents during resectoscopic surgery. *J Am Assoc Gynecol Laparosc* 2000;7:55–63.
114. Vilos GA, Newton DW, Odell RC, Abu-Rafea B, Vilos AG. Characterization and mitigation of stray radiofrequency currents during monopolar resectoscopic electrosurgery. *J Minim Invasive Gynecol* 2006;13:134–40.
115. Jin C, Hu Y, Chen XC, Zheng FY, Lin F, Zhou K, et al. Laparoscopic versus open myomectomy – a meta-analysis of randomized controlled trials. *Eur J Obstet Gynecol Reprod Biol* 2009;145:14–21.
116. Holzer A, Jirecek ST, Illievich UM, Huber J, Wenzl RJ. Laparoscopic versus open myomectomy: a double-blind study to evaluate postoperative pain. *Anesth Analg* 2006;102:1480–4.
117. Alessandri F, Lijoi D, Mistrangelo E, Ferrero S, Ragni N. Randomized study of laparoscopic versus minilaparotomic myomectomy for uterine myomas. *J Minim Invasive Gynecol* 2006;13:92–7.
118. Malzoni M, Tinelli R, Cosentino F, Iuzzolino D, Surico D, Reich H. Laparoscopy versus minilaparotomy in women with symptomatic uterine myomas: short-term and fertility results. *Fertil Steril* 2010;93:2368–73.
119. Sinha R, Hegde A, Warty N, Patil N. Laparoscopic excision of very large myomas. *J Am Assoc Gynecol Laparosc* 2003;10:461–8.
120. Vilos GA, Ternamian A, Dempster J, Laberge PY; Society of Obstetricians and Gynaecologists of Canada Clinical Practice Gynaecology Committee. Laparoscopic entry: a review of techniques, technologies, and complications. SOGC Clinical Practice Guidelines, No. 193, May 2007. *J Obstet Gynaecol Can* 2007;29:433–65.
121. Lemyre M, Bujold E, Lathi R, Bhagan L, Huang JQ, Nezhat C. Comparison of morbidity associated with laparoscopic myomectomy and hysterectomy for the treatment of uterine leiomyomas. *J Obstet Gynaecol Can* 2012;34:57–62.
122. Gyamfi-Bannerman C, Gilbert S, Landon MB, Spong CY, Rouse DJ, Varner MW, et al.; Eunice Kennedy Shriver National Institute of Child Health and Human Development (NICHD) Maternal-Fetal Medicine Units (MFMU) Network. Risk of uterine rupture and placenta accreta with prior uterine surgery outside of the lower segment. *Obstet Gynecol* 2012;120:1332–7.
123. Kumakiri J, Takeuchi H, Itoh S, Kitade M, Kikuchi I, Shimanuki H, et al. Prospective evaluation for the feasibility and safety of vaginal birth after laparoscopic myomectomy. *J Minim Invasive Gynecol* 2008;15:420–4.
124. Seracchioli R, Manuzzi L, Vianello F, Gualerzi B, Savelli L, Paradisi R, et al. Obstetric and delivery outcome of pregnancies achieved after laparoscopic myomectomy. *Fertil Steril* 2006;86:159–65.
125. Seiner P, Arisio R, Decko A, Farina C, Crana F. Laparoscopic myomectomy: indications, surgical technique and complications. *Hum Reprod* 1997;12:1927–30.
126. Parker WH, Einarsson J, Istre O, Dubuisson JB. Risk factors for uterine rupture after laparoscopic myomectomy. *J Minim Invasive Gynecol* 2010;17:551–4.
127. Dicle O, Küçükler C, Pirnar T, Erata Y, Posaci C. Magnetic resonance imaging evaluation of incision healing after cesarean sections. *Eur Radiol* 1997;7:31–4.
128. Seracchioli R, Rossi S, Govoni F, Rossi E, Venturoli S, Bulletti C, et al. Fertility and obstetric outcome after laparoscopic myomectomy of large myomata: a randomized comparison with abdominal myomectomy. *Hum Reprod* 2000;15:2663–8.
129. Hurst BS, Matthew ML, Marshburn PB. Laparoscopic myomectomy for symptomatic uterine myomas. *Fertil Steril* 2005;83:1–23.
130. Prapas Y, Kalogiannidis I, Prapas N. Laparoscopy vs laparoscopically assisted myomectomy in the management of uterine myomas: a prospective study. *Am J Obstet Gynecol* 2009;200:144–6.
131. Wright JD, Ananth CV, Lewin SN, Burke WM, Lu YS, Neugut AI, et al. Robotically assisted vs laparoscopic hysterectomy among women with benign gynecologic disease. *JAMA* 2013;309:689–98.
132. Gargiulo AR, Srouji SS, Missmer SA, Correia KF, Vellinga T, Einarsson JI. Robot-assisted laparoscopic myomectomy compared with standard laparoscopic myomectomy. *Obstet Gynecol* 2012;120(2 Pt 1):284–91.
133. Liu H, Lu D, Wang L, Shi G, Song H, Clarke J. Robotic surgery for benign gynaecological disease. *Cochrane Database Syst Rev* 2012;2:CD008978.
134. AAGL Advancing Minimally Invasive Gynecology Worldwide. AAGL position statement: robotic-assisted laparoscopic surgery in benign gynecology. *J Min Invasiv Gynecol* 2013;20:2–9.
135. Milad M, Milad E. Laparoscopic morcellator-related complications. *J Min Invas Gynecol* 2014;21:486–91.
136. Sizzi O, Rossetti A, Malzoni M, Minelli L, La Grotta F, Soranna L, et al. Italian multicenter study on complications of laparoscopic myomectomy. *J Minim Invasive Gynecol* 2007;14:453–62.
137. Cucinella G, Granese R, Calagna G, Somigliana E, Perino A. Parasitic myomas after laparoscopic surgery: an emerging complication in the use of morcellator? Description of four cases. *Fertil Steril* 2011;96:e90–e96.
138. Hilger WS, Magrina JF. Removal of pelvic leiomyomata and endometriosis five years after supracervical hysterectomy. *Obstet Gynecol* 2006;108(3 Pt 2):772–4.
139. Hutchins FL Jr, Reinoehl EM. Retained myoma after laparoscopic supracervical hysterectomy with morcellation. *J Am Assoc Gynecol Laparosc* 1998;5:293–5.
140. Ordlu Z, Dal Cin P, Chong WWS, Choy KW, Lee C, Muto MG, et al. Disseminated peritoneal leiomyomatosis after laparoscopic supracervical hysterectomy with characteristic molecular cytogenetic findings of uterine leiomyoma. *Genes Chromosomes Cancer* 2010;49:1152–60.
141. Sinha R, Sundaram M, Mahajan C, Sambhus A. Multiple leiomyomas after laparoscopic hysterectomy: report of two cases. *J Minim Invasive Gynecol* 2007;14:123–7.
142. Worthington-Kirsch R, Hutchins FJ Jr. Retained myoma fragment after LASH procedure. *Clin Radiol* 2001;56:777–8.
143. Sinha R, Sundaram M, Lakhota S. Recurrent leiomyomatosis. *J Min Invas Gynecol* 2009;16:668–8.
144. Ribič-Pucelj M, Cvjetičanin B, Šalamun V. Leiomyomatosis peritonealis disseminata as a possible result of laparoscopic myomectomy—report of four cases. *Gynecol Surg* 2013;10:253–6.
145. American Cancer Society. Survival rates for uterine sarcoma, by stage. Atlanta, GA: American Cancer Society; 2014. Available at: <http://www.cancer.org/cancer/uterinesarcoma/detailedguide/uterine-sarcoma-survival-rates>. Accessed on November 11, 2014.
146. Health Canada. Laparoscopic electric morcellators - risk of spread of unsuspected uterine sarcoma - notice to hospitals. Ottawa: Health Canada; 2014. Available at <http://healthycanadians.gc.ca/recall-alert-rappel-avis/hc-sc/2014/39409a-eng.php>. Accessed on November 11, 2014.
147. Society of Gynecologic Oncology. SGO position statement: morcellation. Chicago: SGO; 2013. Available at <https://www.sgo.org/newsroom/position-statements-2/morcellation>. Accessed on November 11, 2014.

148. AAGL Advancing Minimally Invasive Gynecology Worldwide. Morcellation during uterine tissue extraction. *J Minim Invasive Gynecol* 2014;21:517–30.
149. American College of Obstetricians and Gynecologists. Power morcellation and occult malignancy in gynecologic surgery. Washington, DC: ACOG; 2014. Available at <http://www.acog.org/Resources-And-Publications/Task-Force-and-Work-Group-Reports/Power-Morcellation-and-Occult-Malignancy-in-Gynecologic-Surgery>. Accessed on November 22, 2014.
150. Food and Drug Administration. Quantitative assessment of the prevalence of unsuspected uterine sarcoma in women undergoing treatment of uterine fibroids: summary and key findings. Silver Spring, MD: FDA; 2014. Available at <http://www.fda.gov/downloads/MedicalDevices/Safety/AlertsandNotices/UCM393589.pdf>. Accessed on November 11, 2014.
151. Mussalam KM, Tamim HM, Richards T, Spahn DR, Rosendaal FR, Habbal A, et al. Preoperative anaemia and postoperative outcomes in non-cardiac surgery: a retrospective cohort study. *Lancet* 2011;378(9800):1396–407.
152. Lethaby A, Vollenhoven B, Sowter M. Pre-operative GnRH analogue therapy before hysterectomy or myomectomy for uterine fibroids. *Cochrane Database Syst Rev* 2001;(2):CD000547.
153. Chen I, Motan T, Kiddoo D. Gonadotropin-releasing hormone agonist in laparoscopic myomectomy: systematic review and meta-analysis of randomized controlled trials. *J Minim Invasive Gynecol* 2011;18:303–9.
154. De Falco M, Staibano S, Mascolo M, Mignogna C, Improda L, Ciociola F, et al. Leiomyoma pseudocapsule after pre-surgical treatment with gonadotropin-releasing hormone agonists: relationship between clinical features and immunohistochemical changes. *Eur J Obstet Gynecol Reprod Biol* 2009;144:44–7.
155. Mavrelou D, Ben-Nagi J, Davies A, Lee C, Salim R, Jurkovic D. The value of pre-operative treatment with GnRH analogues in women with submucous fibroids: a double-blind, placebo-controlled randomized trial. *Hum Reprod* 2010;25:2264–9.
156. Chang FW, Yu MH, Ku CH, Chen CH, Wu GJ, Liu JY. Effect of uterotonics on intra-operative blood loss during laparoscopy-assisted vaginal hysterectomy: a randomised controlled trial. *BJOG* 2006;113:47–52.
157. Celik H, Sapmaz E. Use of a single preoperative dose of misoprostol is efficacious for patients who undergo abdominal myomectomy. *Fertil Steril* 2003;79:1207–10.
158. Frederick S, Frederick J, Fletcher H, Reid M, Hardie M, Gardner W. A trial comparing the use of rectal misoprostol plus perivascular vasopressin with perivascular vasopressin alone to decrease myometrial bleeding at the time of abdominal myomectomy. *Fertil Steril* 2013;100:1044–9.
159. Preuthippan S, Herabutya Y. Vaginal misoprostol for cervical priming before operative hysteroscopy: a randomized controlled trial. *Obstet Gynecol* 2000;96:890–4.
160. Cesen-Cummings K, Houston KD, Copland JA, Moorman VJ, Walker CL, Davis BJ. Uterine leiomyomas express myometrial contractile-associated proteins involved in pregnancy-related hormone signaling. *J Soc Gynecol Investig* 2003;10:11–20.
161. Wang CJ, Yuen LT, Yen CF, Lee CL, Soong YK. A simplified method to decrease operative blood loss in laparoscopy-assisted vaginal hysterectomy for the large uterus. *J Am Assoc Gynecol Laparosc* 2004;11:370–3.
162. Kongnyuy EJ, Wiysonge CS. Interventions to reduce haemorrhage during myomectomy for fibroids. *Cochrane Database Syst Rev* 2011;(11):CD005355.
163. Riess ML, Ulrichs JG, Pagel PS, Woehleck HJ. Case report: severe vasospasm mimics hypotension after high-dose intrauterine vasopressin. *Anesth Analg* 2011;113:1103–5.
164. Okin CR, Guido RS, Meyn LA, Ramanathan S. Vasopressin during abdominal hysterectomy: a randomized controlled trial. *Obstet Gynecol* 2001;97:867–72.
165. Ginsburg ES, Benson CB, Garfield JM, Gleason RE, Friedman AJ. The effect of operative technique and uterine size on blood loss during myomectomy: a prospective randomized study. *Fertil Steril* 1993;60:956–62.
166. Fletcher H, Frederick J, Hardie M, Simeon D. A randomized comparison of vasopressin and tourniquet as hemostatic agents during myomectomy. *Obstet Gynecol* 1996;87:1014–8.
167. Zhao F, Jiao Y, Guo Z, Hou R, Wang M. Evaluation of loop ligation of larger myoma pseudocapsule combined with vasopressin on laparoscopic myomectomy. *Fertil Steril* 2011;95:762–6.
168. Zullo F, Palomba S, Corea D, Pellicano M, Russo T, Falbo A, et al. Bupivacaine plus epinephrine for laparoscopic myomectomy: a randomized placebo-controlled trial. *Obstet Gynecol* 2004;104:243–9.
169. Wellington K, Wagstaff AJ. Tranexamic acid: a review of its use in the management of menorrhagia. *Drugs* 2003;63:1417–33.
170. Caglar GS, Tasci Y, Kayikcioglu F, Haberal A. Intravenous tranexamic acid use in myomectomy: a prospective randomized double-blind placebo controlled study. *Eur J Obstet Gynecol Reprod Biol* 2008;137:227–31.
171. Bae JH, Chong GO, Seong WJ, Hong DG, Lee YS. Benefit of uterine artery ligation in laparoscopic myomectomy. *Fertil Steril* 2011;95:775–8.
172. Chang WC, Huang PS, Wang PH, Chang DY, Huang SC, Chen SY, et al. Comparison of laparoscopic myomectomy using in situ morcellation with and without uterine artery ligation for treatment of symptomatic myomas. *J Minim Invasive Gynecol* 2012;19:715–21.
173. Ikechebelu JI, Ezeama CO, Obiechina NJ. The use of tourniquet to reduce blood loss at myomectomy. *Niger J Clin Pract* 2010;13:154–8.
174. Taylor A, Sharma M, Tsirkas P, Di Spiezo Sardo A, Setchell M, Magos A. Reducing blood loss at open myomectomy using triple tourniquets: a randomised controlled trial. *BJOG* 2005;112:340–5.
175. Tinelli A, Malvasi A, Guido M, Tsin DA, Hudelist G, Hurst B, et al. Adhesion formation after intracapsular myomectomy with or without adhesion barrier. *Fertil Steril* 2011;95:1780–5.
176. Mettler L, Huicke J, Bojahr B, Tinneberg HR, Leyland N, Avelar R. A safety and efficacy study of a resorbable hydrogel for reduction of post-operative adhesions following myomectomy. *Hum Reprod* 2008;23:1093–100.
177. Takeuchi H, Kitade M, Kikuchi I, Shimanuki H, Kumakiri J, Kinoshita K. Adhesion-prevention effects of fibrin sealants after laparoscopic myomectomy as determined by second-look laparoscopy: a prospective, randomized, controlled study. *J Reprod Med* 2005;50:571–7.
178. Lefebvre GG, Vilos G, Asch M; Society of Obstetricians and Gynaecologists of Canada; Canadian Association of Radiologists; Canadian Interventional Radiology Association. Uterine fibroid embolization (UFE). SOGC Clinical Practice Guidelines, No. 150, October 2004. *J Obstet Gynaecol Can* 2004;26:913–28.
179. Pron G, Mocarski E, Bennett J, Vilos G, Common A, Vanderburgh L; Ontario UFE Collaborative Group. Pregnancy after uterine artery embolization for leiomyomata: the Ontario multicenter trial. *Obstet Gynecol* 2005;105:67–76.
180. Mara M, Kubinova K. Embolization of uterine fibroids from the point of view of the gynecologist: pros and cons. *Int J Womens Health* 2014;6:623–9.
181. Martin J, Bhanot K, Athreya S. Complications and reinterventions in uterine artery embolization for symptomatic uterine fibroids: a literature review and meta-analysis. *Cardiovasc Intervent Radiol* 2013;36:395–402.

182. Zupi E, Sbracia M, Marconi D, Munro MG. Myolysis of uterine fibroids: is there a role? *Clin Obstet Gynecol* 2006;49:821–33.
183. National Institute for Health and Clinical Excellence (NICE). IPG 413: magnetic resonance image-guided transcatheter focused ultrasound for uterine fibroids. London: NICE; 2014. Available at <https://www.nice.org.uk/guidance/ipg413/resources/guidance-magnetic-resonance-image-guided-transcatheter-focused-ultrasound-for-uterine-fibroids-pdf>. Accessed on November 11, 2014.
184. Ghezzi F, Cromi A, Bergamini V, Scarperi S, Bolis P, Franchi M. Midterm outcome of radiofrequency thermal ablation for symptomatic uterine myomas. *Surg Endosc* 2007;21:2081–5.
185. Pansky M, Cowan BD, Frank M, Hampton HL, Zimberg S. Laparoscopically assisted uterine fibroid cryoablation. *Am J Obstet Gynecol* 2009;201:571–7.
186. Bourlev V, Pavlovitch S, Stygar D, Volkov N, Lindblom B, Olovsson M. Different proliferative and apoptotic activity in peripheral versus central parts of human uterine leiomyomas. *Gynecol Obstet Invest* 2003;55:199–204.
187. Bouwsma EV, Hesley GK, Woodrum DA, Weaver AL, Leppert PC, Peterson LG, et al. Comparing focused ultrasound and uterine artery embolization for uterine fibroids—rationale and design of the Fibroid Interventions: Reducing Symptoms Today and Tomorrow (FIRSTT) trial. *Fertil Steril* 2011;96:704–10.
188. Bouwsma EV, Gorny KR, Hesley GK, Jensen JR, Peterson LG, Stewart EA. Magnetic resonance-guided focused ultrasound surgery for leiomyoma-associated infertility. *Fertil Steril* 2011;96:e9–e12.
189. Chudnoff SG, Berman JM, Levine DJ, Harris M, Guido RS, Banks E. Outpatient procedure for the treatment and relief of symptomatic uterine myomas. *Obstet Gynecol* 2013;121:1075–82.
190. Munro MG; Southern California Permanente Medical Group's Abnormal Uterine Bleeding Working Group. Acute uterine bleeding unrelated to pregnancy: a Southern California Permanente Medical Group practice guideline. *Perm J* 2013;17:43–56.
191. Friedman AJ. Combined oestrogen-progestin treatment of vaginal hemorrhage following gonadotropin-releasing hormone agonist therapy of uterine myomas. *Hum Reprod* 1993;8:540–2.
192. Thomas MA, Gass ML, Scott MC, Liu JH. Multiple therapies for vaginal bleeding secondary to large uterine myomas. *Int J Gynaecol Obstet* 1991;36:239–41.
193. Lakhani KP, Marsh MS, Purcell W, Hardiman P. Uterine artery blood flow parameters in women with dysfunctional uterine bleeding and uterine fibroids: the effects of tranexamic acid. *Ultrasound Obstet Gynecol* 1998;11:23–8.
194. Lukes AS, Moore KA, Muse KN, Gersten JK, Hecht BR, Edlund M, et al. Tranexamic acid treatment for heavy menstrual bleeding: a randomized controlled trial. *Obstet Gynecol* 2010;116:865–75.
195. Naoulou B, Tsai MC. Efficacy of tranexamic acid in the treatment of idiopathic and non-functional heavy menstrual bleeding: a systematic review. *Acta Obstet Gynecol Scand* 2012;91:529–37.
196. Lindoff C, Rybo G, Astedt B. Treatment with tranexamic acid during pregnancy, and the risk of thrombo-embolic complications. *Thromb Haemost* 1993;70:238–40.
197. Sundstrom A, Seaman H, Kieler H, Alfredsson L. The risk of venous thromboembolism associated with the use of tranexamic acid and other drugs used to treat menorrhagia: a case-control study using the General Practice Research Database. *BJOG* 2009;116:91–7.
198. Donnez J, Tomaszewski J, Vazquez F, Bouchard P, Lemieszczuk B, Baro F, et al. Ulipristal acetate versus leuprolide acetate for uterine fibroids. *N Engl J Med* 2012;366:421–32.
199. Hamani Y, Ben-Shachar I, Kalish Y, Porat S. Intrauterine balloon tamponade as a treatment for immune thrombocytopenic purpura-induced severe uterine bleeding. *Fertil Steril* 2010;94:2769.e13–e5.
200. Goldrath MH. Uterine tamponade for the control of acute uterine bleeding. *Am J Obstet Gynecol* 1983;147:869–72.
201. Thorp JM, Katz VL. Submucous myomas treated with gonadotropin releasing hormone agonist and resulting in vaginal hemorrhage. A case report. *J Reprod Med* 1991;36:625–6.
202. Richards SR. Endometrial ablation for life-threatening abnormal uterine bleeding. A report of two cases. *J Reprod Med* 1994 Sep;39:741–2.
203. Osuga Y, Okagaki R, Ozaki S, Matsumi H, Fujii T, Iwase H, et al. Successful emergency endometrial ablation for intractable uterine bleeding in a postmenopausal woman complicated with liver cirrhosis and morbid obesity. *Surg Endosc* 2001;15:898.
204. Woolf SH, Battista RN, Angerson GM, Logan AG, Eel W. Canadian Task Force on Preventive Health Care. New grades for recommendations from the Canadian Task Force on Preventive Health Care. *CMAJ* 2003;169:207–8.