

1-1-2021

Adrenal Cushing Syndrome Diagnosed during Pregnancy: Successful Medical Management with Metyrapone

Alescia Azzola
Schulich School of Medicine & Dentistry

Genevieve Eastabrook
Schulich School of Medicine & Dentistry

Doreen Matsui
Schulich School of Medicine & Dentistry

Amanda Berberich
Schulich School of Medicine & Dentistry

Rommel G. Tirona
Schulich School of Medicine & Dentistry, rommel.tirona@schulich.uwo.ca

See next page for additional authors

Follow this and additional works at: <https://ir.lib.uwo.ca/paedpub>

Citation of this paper:

Azzola, Alescia; Eastabrook, Genevieve; Matsui, Doreen; Berberich, Amanda; Tirona, Rommel G.; Gray, Daryl; Gallego, Patricia; and Van Uum, Stan, "Adrenal Cushing Syndrome Diagnosed during Pregnancy: Successful Medical Management with Metyrapone" (2021). *Paediatrics Publications*. 1530.
<https://ir.lib.uwo.ca/paedpub/1530>

Authors

Alescia Azzola, Genevieve Eastabrook, Doreen Matsui, Amanda Berberich, Rommel G. Tirona, Daryl Gray, Patricia Gallego, and Stan Van Uum

Case Report

Adrenal Cushing Syndrome Diagnosed During Pregnancy: Successful Medical Management With Metyrapone

Alescia Azzola,¹ Genevieve Eastabrook,² Doreen Matsui,³ Amanda Berberich,¹ Rommel G. Tirona,⁴ Daryl Gray,⁵ Patricia Gallego,³ and Stan Van Uum¹

¹Department of Medicine, Schulich School of Medicine, Western University, London, Ontario N6A 4V2, Canada; ²Obstetrics and Gynaecology, Schulich School of Medicine, Western University, London, Ontario N6A 3K7, Canada; ³Paediatrics, Schulich School of Medicine, Western University, London, Ontario N6A 3K7, Canada; ⁴Physiology and Pharmacology, Schulich School of Medicine, Western University, London, Ontario N6A 3K7, Canada; and ⁵Surgery, Schulich School of Medicine, Western University, London, Ontario N6A 3K7, Canada

ORCID numbers: 0000-0003-2657-1402 (A. Azzola); 0000-0001-9184-2796 (G. Eastabrook); 0000-0002-9461-9036 (A. Berberich); 0000-0001-5455-3960 (R. G. Tirona); 0000-0001-9773-4075 (D. Gray); 0000-0002-6114-7407 (P. Gallego); 0000-0002-0150-8223 (S. Van Uum).

Abbreviations: ACTH, adrenocorticotropin; CS, Cushing syndrome; LOD, limit of detection; LOQ, limit of quantitation; UA, umbilical artery.

Received: 8 July 2020; Editorial Decision: 26 October 2020; First Published Online: 5 November 2020; Corrected and Typeset: 3 December 2020.

Abstract

Adrenal Cushing syndrome during pregnancy is rare, and there is limited information on the effect and safety of metyrapone treatment both for mother and fetus. We present a 24-year-old woman diagnosed with adrenal Cushing syndrome at the end of the second trimester. We elected treatment with metyrapone titrated to 250 mg 3 times daily, resulting in good clinical response and maternal serum and saliva cortisol levels in the upper half of the normal pregnancy range. A healthy male infant was born at 35 weeks' gestation, with no clinical signs of adrenal insufficiency, this despite a low cortisol of 5 nmol/L on the first day of life. We measured metyrapone in maternal and umbilical cord blood samples, demonstrating fetal venous metyrapone levels similar to maternal venous concentration, and a fetal arterial cord concentration at about 60% of the fetal venous cord concentration. This case demonstrates that salivary cortisol levels may be used to monitor the effect of metyrapone on adrenal Cushing syndrome during pregnancy. We show, for the first time in humans, that metyrapone does cross the placenta and may suppress fetal cortisol production without necessarily causing clinical signs of adrenal insufficiency.

Key Words: Cushing, pregnancy, metyrapone, saliva cortisol, neonate

Cushing syndrome (CS) during pregnancy is rare, with only about 200 cases reported in the literature [1]. Its rarity in pregnancy is multifactorial because of low rates of fertility consequent to CS, and because of the challenging diagnosis [2] caused by the overlapping clinical presentation of CS vs the normal physiological state of hypercortisolism seen in pregnancy. In pregnant women, CS is most commonly adrenal in origin (50%-60% of cases), whereas in nonpregnant women pituitary Cushing disease is found in 70% of cases [2]. Left undiagnosed and untreated, CS can be detrimental both to maternal and fetal health [2].

Literature available to guide therapy is sparse, and no consensus has been established for optimal management of CS during pregnancy. Medical and surgical treatments were both found to be protective in avoiding fetal loss. Surgery tends to be preferred because of reduced complications at time of delivery. However, timing limits its safety to the second and early third trimester [2, 3].

Metyrapone, a steroidogenesis inhibitor, has been safely used in pregnancy for the medical treatment of CS [4, 5]. Metyrapone passes through the placental barrier and may potentially affect adrenal steroid production by the fetus [6]. There are no documented fetal complications with its use; however, transplacental studies have not been reported in humans. Animal studies have demonstrated cross-placental transfer of metyrapone without detrimental effect [7]. Risk of worsening preexisting hypertension leading to preeclampsia has been reported because of increase in the 11-deoxycortisol precursor. This case report explores the challenges of medical management of adrenal CS in pregnancy when surgical intervention is not possible. Metyrapone was used to reduce serum and saliva cortisol levels to the upper limits of expected pregnancy ranges. Unique to this case, additional analyses were performed to measure increase in 11-deoxycortisol as well as analysis of cord blood samples to assess cross-placental transfer of metyrapone.

1. Clinical Case

A 24-year-old pregnant woman was referred at 25 weeks' gestation for concerns about excess cortisol secretion. Her symptoms included rapid weight gain, hirsutism, chronic hypertension, generalized weakness, fatigue, and widespread violaceous striae. Her medications included prenatal vitamins with folic acid, daily low-dose aspirin, and nifedipine XL 60 mg daily. Six years prior to presentation, her first pregnancy was complicated by gestational diabetes, 32-kg weight gain, hypertension, and an eclamptic seizure necessitating an emergency cesarean delivery at 33 weeks' gestation in a community hospital. A baby boy weighing 3 pounds and 9 ounces was delivered. Post partum, her

hypertension persisted and widespread violaceous striae did not substantially improve. Over the next years her obesity remained and she continued antihypertensive treatment with long-acting nifedipine. A glucose tolerance test was normal, and she was followed by her family health team.

At presentation during the second pregnancy, she appeared cushingoid, with a round and flushed face, hirsutism, supraclavicular and dorsal fat pads, widespread violaceous striae, and mild proximal myopathy. Her weight was 123.1 kg with a body mass index of 44 kg/m², blood pressure of 145/108 mm Hg, and heart rate of 122 per minute. Laboratory investigations showed an increased 24-hour urine cortisol excretion of 1141 nmol/day (nonpregnancy reference range <275), increased salivary cortisol of 44.5 nmol/L at 8 AM and 61.1 nmol/L at 8 PM (<24.1 nmol/L for 6-8 AM and <9.7 for 4-8 PM) showing loss of diurnal variation, suppressed morning adrenocorticotropic hormone (ACTH) (<0.3 pmol/L) and low DHEAS (dehydroepiandrosterone sulfate) of 1.2 μmol/L (range, 2.7-9.2 μmol/L). A 2-hour 75-g glucose tolerance test confirmed diabetes mellitus. Testing of 24-hour urinary excretion of catecholamines and metanephrines was normal. Magnetic resonance imaging of the abdomen showed a 3.7-cm left adrenal adenoma.

A diagnosis of adrenal ACTH-independent CS during pregnancy was made. A multidisciplinary case conference, with representation of departments of adult endocrinology, general surgery, maternal fetal medicine, neonatology, anesthesia, and clinical pharmacology, was organized. Although the literature would favor early surgical adrenalectomy during pregnancy, this patient was considered a high-risk surgical candidate because of her high body mass index (possibly necessitating conversion from laparoscopic to open surgery) and the concern for inferior vena cava compression by the gravid uterus when placed in the right lateral decubitus position.

Therefore, we elected to treat this patient medically but decided against ketoconazole because of its reported embryotoxicity [8]. We started the patient on metyrapone, an inhibitor of 11β-hydroxylase in the steroidogenesis pathway of the adrenal cortex, resulting in a reduction in serum cortisol. Because the patient lived in a remote area, this was administered during hospital admission in our center. We performed serial measurements of plasma metyrapone, cortisol and 11-deoxycortisol, and salivary cortisol. We also measured metyrapone, cortisol, and 11-deoxycortisol in fetal (umbilical artery [UA] and vein) and maternal plasma during delivery.

We measured plasma concentrations of metyrapone, cortisol, and 11-deoxycortisol by liquid chromatography-tandem mass spectrometry. Briefly, plasma samples

(50 μ L) were combined with 150 μ L of acetonitrile containing internal standards (10 ng/mL alprazolam and 350 ng/mL D4-cortisol). Alprazolam served as the internal standard for metyrapone, while D4-cortisol was the internal standard used for the analysis of cortisol and 11-deoxycortisol. After centrifugation, the resulting supernatants were dried in a SpeedVac and reconstituted with 150 μ L of acetonitrile/water (5%/95%) containing 0.1% formic acid for injection into the liquid chromatograph (Agilent 1100). Analytes were separated with gradient elution using mobile phases A (water with 1% formic acid) and B (acetonitrile with 1% formic acid) on a Hypersil Gold C18 column (50 \times 5 mm, 5 μ m, Thermo Scientific). Retention times for metyrapone, alprazolam, cortisol, and 11-deoxycortisol were 2.9 minutes, 4.3 minutes, 4.3 minutes, and 4.3 minutes, respectively. Solutes were analyzed by tandem mass spectrometry (TSQ Vantage, Thermo Scientific) by electrospray ionization and detection in positive mode. For metyrapone, alprazolam, cortisol, D4-cortisol and 11-deoxycortisol, the mass transitions used were 227.2 \rightarrow 121.1 m/z, 309.0 \rightarrow 280.9 m/z, 363.2 \rightarrow 121.1 m/z, 367.2 \rightarrow 121.1 m/z and 347.0 \rightarrow 97.0 m/z, respectively. Standard curve samples

were prepared in charcoal-stripped plasma (BioIVT) and processed in a similar fashion as patient samples. For metyrapone, the limit of detection (LOD) was 0.05 ng/mL, the limit of quantitation (LOQ) was 0.2 ng/mL, precision (coefficient of variation %) was 9.3%, and bias was 11.4%. For cortisol, LOD was 2 ng/mL, LOQ was 5 ng/mL, precision was 2.0%, and bias was 2.3%. Last, for 11-deoxycortisol, LOD was 0.2 ng/mL, LOQ was 0.5 ng/mL, precision was 7.4%, and bias was 9.4%.

As shown in Table 1, a single dose of metyrapone 250 mg resulted in rapid metyrapone absorption within 1 hour, with levels returning to barely detectable 24 hours after ingestion. Maternal and fetal vital signs remained stable during this period. Similar analysis after a cumulative dose of 750 mg demonstrated mean peak plasma concentrations of 4.9 ng/mL.

The metyrapone dose was gradually increased to 250 mg TID. This dose resulted in a steady decline both of plasma and salivary cortisol concentrations (Fig. 1), approaching serum cortisol levels around 800 nmol/L and saliva cortisol levels around 30 pmol/L, both in the upper half of the normal pregnancy range [9]. Hypertension remained controlled on nifedipine.

Table 1. Metyrapone—effect of an initial single 250-mg dose and cumulative 1000-mg dose

	Time	Metyrapone, ng/mL	Cortisol, nmol/L	Cortisol saliva, nmol/L	11-Deoxycortisol, ng/mL
Day 1					
Baseline	12:30	0	1036	48.4	1.7
1 h post	13:30	35.9	820	28.6	12.4
8 h post	20:30	2.4	1015	40.4	2.8
24 h post	12:30	0.1	950	43.1	0.9
Day 3					
Pre-fifth dose	00:30	1.7	1096		3.1
1 h post	01:35	4.9	1141		2.8

The patient received 250 mg metyrapone at 12:30 on day 1, at 8:30 and 16:30 on day 2, and at 00:30 on day 3. All measurements were taken in plasma.

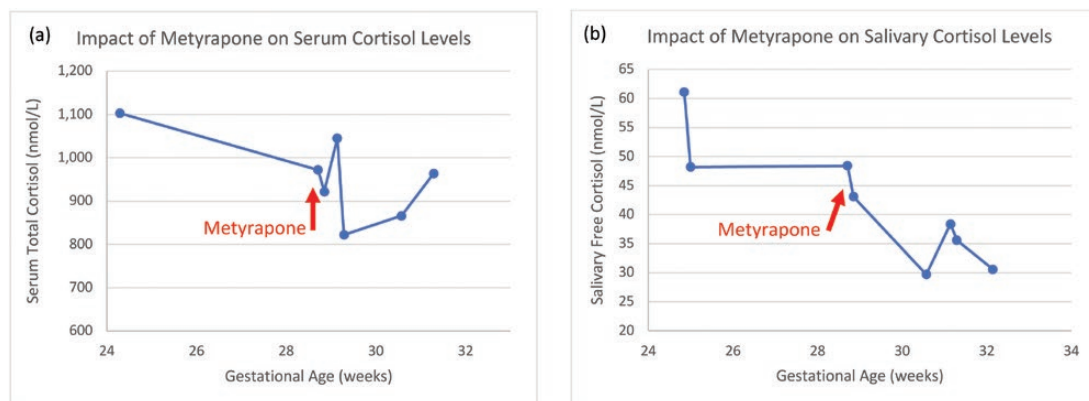


Figure 1. Steady decline both in A, plasma, and B, morning salivary cortisol readings were observed during successful control of hypercortisolism with metyrapone therapy. Note that serum cortisol levels reflect total cortisol (including protein-bound cortisol), whereas salivary cortisol levels reflect free cortisol concentrations.

A. Maternal Outcomes

The overall condition of the patient, including control of gestational diabetes and hypertension, improved during metyrapone therapy. An elective repeat cesarean delivery was performed at 35 weeks' gestation, after balancing the risks of further maternal medical decompensation with those of late preterm delivery. A healthy male infant was delivered without complication. Serum cortisol level at time of delivery was 2398 nmol/L, remaining around the upper limit of normal pregnancy levels. Postpartum transition to more affordable ketoconazole therapy was well tolerated. Laparoscopic left adrenalectomy was performed without complications at 10 weeks post delivery. Since then, there has been notable improvement of the patient's initial Cushing features. She was treated with a tapering dose of hydrocortisone for 6 months, at which time she had a normal functioning pituitary–right adrenal axis. Her cushingoid symptoms gradually improved and her weight decreased to 103 kg, her blood pressure normalized to 115/83 mm Hg off medications, and further biochemical evaluation showed normal cortisol secretion.

B. Fetal Outcomes

Fetal growth, well-being, and placental function were monitored during metyrapone treatment using serial ultrasounds. Estimated fetal weights were measured every 3 weeks, with growth parameters remaining within the normal range (70th percentile at 26 weeks, 50th percentile at 35 weeks). Biophysical profile scores and UA Dopplers were performed weekly and consistently within normal limits (UA pulsatility index < 95th percentile).

A male infant was born at 35 weeks' gestation with a weight of 2.41 kg (33rd percentile) and an Apgar score 9 both at 1 and 5 minutes. There were no signs suggestive of CS or hyperandrogenism, and no neonatal complications. On the first day of life, a random evening venous cortisol concentration was low at 5 nmol/L (normal range, 68–327 nmol/L). On the third day of life, the baseline ACTH was 9.12 pmol/L (range, 1.98–2.47 pmol/L), and the cortisol level improved to 41 nmol/L.

A peak cortisol value of 214 nmol/L was observed after ACTH stimulation. The child maintained a normal electrolytes profile and was clinically stable. Therefore, these results were interpreted as appropriate for the child's gestational age. Defining normal cortisol values is difficult in the neonatal period as studies have shown a large range of reference values [10]. There was no evidence of hypoglycemia, hyponatremia, hyperkalemia, lethargy, or vomiting. He was discharged home on the fourth day of life. He was seen by a pediatric endocrinologist at age 4 weeks and was noted to have had appropriate weight gain, regular feeding patterns, and a normal morning cortisol level (154 nmol/L). There was no clinical evidence of hyperandrogenism. He was discharged from endocrinology follow-up to primary care.

The results of umbilical cord sampling are shown in Table 2 and demonstrate that metyrapone does cross the placenta, with the fetal venous cord concentration being only slightly lower than the maternal venous concentration, and the fetal arterial cord concentration being about 60% of the fetal venous cord concentration.

2. Discussion

We describe a patient with adrenal CS diagnosed at the end of the second trimester who elected treatment with metyrapone. Unique features of this case include the monitoring of salivary cortisol in addition to serum cortisol, as well as monitoring of maternal and fetal levels of cortisol and metyrapone at the time of delivery.

Systematic review of published cases until April 2015 have found only 220 patients (263 pregnancies) with active CS in pregnancy [2, 6]. The diagnosis of CS is also confounded by the physiological state of hypercortisolism normally seen in pregnancy. Serum cortisol levels have been noted to increase 2 to 3 times the upper limit of normal, and urine cortisol can rise 180% in pregnancy. Lack of suppression with dexamethasone is often seen because of persistent unsuppressed placental ACTH secretion. The salivary diurnal variation, however, seems to be preserved during pregnancy [9]. Early recognition of CS in pregnancy

Table 2. Maternal and fetal effects of metyrapone therapy at delivery

	Time	Metyrapone, ng/mL	Cortisol, nmol/L	11-Deoxycortisol, ng/mL
Sample				
Mother	15:00	19.8	2398	7.1
Venous cord	15:00	16.1	843	4.8
Arterial cord	15:00	9.4	924	3.8

All measurements were taken in plasma.

is imperative. Caimari et al [2] demonstrated a higher risk of gestational diabetes (36.9 vs 2.3% $P = .003$), gestational hypertension (40.5 vs 2.3% $P < .001$), and preeclampsia (26.3 vs 2.3% $P = .001$) in active compared to cured pregnant patients. Fetal outcomes were also negatively affected, with higher rates of fetal loss (23.6 vs 8.5% $P = .021$) and global fetal morbidities (33.3 vs 4.9% $P < .001$). The most common fetal morbidities include premature birth, intrauterine growth restriction, stillbirths and, rarely, adrenal insufficiency. No fetal hypercortisolism was reported [2]. Other maternal complications noted in the literature included poor wound healing, osteoporosis, pathological fractures, cardiac failure and, rarely, maternal mortality.

Although the primary treatment of adrenal CS in pregnancy is adrenalectomy, we elected to treat the patient with metyrapone because of the gestational age at diagnosis and the concerns about surgical complications due to maternal body habitus. Serum cortisol levels were monitored but, because serum cortisol measures total cortisol including protein-bound cortisol, interpretation remains challenging. Ambroziak and colleagues [9] described salivary cortisol levels specified by trimester, and reported a morning saliva cortisol of 21.9 nmol/L (range, 8.9-39.7 nmol/L [mean and 2.5 and 97.5th percentile]). During the patient's metyrapone treatment, we were able to achieve morning saliva cortisol levels in the upper half of this third trimester-specific range. Worsening hypertension and risk of preeclampsia are known risks of metyrapone use. It has been suggested that the increased levels of precursor 11-deoxycortisol during the inhibition of 11 β -hydroxylase by metyrapone cause sodium retention, leading to hypertension. In this patient, with the use of liquid chromatography-tandem mass spectrometry, 11-deoxycortisol levels were measured and a slight increase was observed. However, her blood pressure improved once she was on the metyrapone and remained stable throughout the pregnancy. 11-Deoxycortisol may have some glucocorticoid activity (about 15% of that of cortisol) [11] but does not have mineralocorticoid activity. However, the hypertension and hypokalemia may primarily be caused by 11-deoxycorticosterone, which has mineralocorticoid but no glucocorticoid activity [12], and which would be increased due to inhibition of 11 β -hydroxylase activity [13]. In the present study we did not measure 11-deoxycorticosterone levels.

In addition, immunoassays for cortisol may have cross-reactivity for 11-deoxycortisol. This cross-reactivity is reported to be low at 4.6%, but indicated to be clinically relevant in patients with 11 β -hydroxylase deficiency or following metyrapone challenge [14]. Therefore, the use of liquid chromatography-mass spectrometry to measure 11-deoxycortisol was also important to reduce the risk of overtreatment and potential adrenal insufficiency both for mother and fetus.

We are not aware of any previous human transplacental data on metyrapone. Animal models demonstrate a 50% placental transfer of metyrapone with no pronounced effects on adrenal function [7]. Our data demonstrate that metyrapone does cross the placenta in humans. The metyrapone concentration in venous cord blood was 16.1 ng/mL and 9.4 ng/mL in arterial cord blood. This implies that the theoretical risk of fetal steroid synthesis inhibition is real, with a potential risk of fetal adrenal insufficiency. Indeed, on day 3 of life, neonatal cortisol levels were suboptimal both at baseline and after stimulation, demonstrating a likely transient effect of metyrapone on fetal cortisol production. However, there were no clinical or other biochemical signs of adrenal insufficiency, and this child has never required glucocorticoid administration. Although in this particular case there were no signs of neonatal adrenal insufficiency, we were able to confirm that fetal exposure to metyrapone does occur and careful monitoring of the neonatal hypothalamic-pituitary-adrenal axis post delivery remains important.

The metyrapone plasma concentrations described in the product monograph were based on data published in abstract format in 1967 [15]. Concentrations were measured after a single dose of 750 mg, but the analytic methods were not described, making any direct comparison with our results difficult. The plasma concentrations in our patient are similar to what has been reported for metyrapone in breast milk [16].

During her first pregnancy, our patient developed symptoms and complications that could potentially be explained by CS. Hána and colleagues [17] described a patient with ACTH-independent CS that developed during pregnancy and went into remission within 3 weeks of delivery, with the same pattern developing during her next 2 pregnancies. Searching for an underlying mechanism, Andreescu and colleagues [18] described the presence of abnormal cortisol responses in 3 pregnant patients with CS due to an adrenal adenoma. These patients had an abnormal cortisol response to luteinizing hormone-releasing hormone and human chorionic gonadotropin, and suppressed ACTH levels, and developed CS during pregnancy. Other rare causes of pregnancy-induced CS included placental corticotropin-releasing hormone synthesis or estrogen-dependent nodular adrenal hyperplasia [19]. It is possible that similar mechanisms may explain, at least in part, the presentation in our patient. However, because her symptoms did not completely resolve between pregnancies, this is unlikely to completely explain our patient's pathophysiology.

In conclusion, this case report illustrates the additional complexity of CS management when detected in late pregnancy. Our case report clearly illustrates that a multidisciplinary approach is critical because it provides the

information and expertise required to carefully balance maternal and fetal risks. In a high-risk surgical patient, the literature on medical therapy is sparse. Therefore, multiple key endocrine points required exploration, including the safety of medical treatment in pregnancy, the availability and effectiveness of metyrapone in pregnancy, as well as unknown fetal risk. We have demonstrated the use of saliva cortisol for monitoring the effect of metyrapone, and demonstrated, for the first time, that metyrapone crosses the placenta in humans.

Additional Information

Correspondence: Stan Van Uum, MD, PhD, FRCPC, Schulich School of Medicine and Dentistry, Western University, Division of Endocrinology and Metabolism, Department of Medicine, University of Western Ontario, St. Joseph's Health Care, Room B5-130, 268 Grosvenor St, London, Ontario N6A 4V2, Canada. E-mail: stan.vanuuum@sjhc.london.on.ca.

Disclosure Summary: The authors have nothing to disclose.

Data Availability: Data sharing is not applicable to this article because no data sets were generated or analyzed during the present study.

References

- Lindsay JR, Jonklaas J, Oldfield EH, Nieman LK. Cushing's syndrome during pregnancy: personal experience and review of the literature. *J Clin Endocrinol Metab.* 2005;90(5):3077-3083.
- Caimari F, Valassi E, Garbayo P, et al. Cushing's syndrome and pregnancy outcomes: a systematic review of published cases. *Endocrine.* 2017;55(2):555-563.
- Bevan JS, Gough MH, Gillmer MD, Burke CW. Cushing's syndrome in pregnancy: the timing of definitive treatment. *Clin Endocrinol (Oxf).* 1987;27(2):225-233.
- Blanco C, Maqueda E, Rubio JA, Rodriguez A. Cushing's syndrome during pregnancy secondary to adrenal adenoma: metyrapone treatment and laparoscopic adrenalectomy. *J Endocrinol Invest.* 2006;29(2):164-167.
- Zieleniewski W, Michalak R. A successful case of pregnancy in a woman with ACTH-independent Cushing's syndrome treated with ketoconazole and metyrapone. *Gynecol Endocrinol.* 2017;33(5):349-352.
- Brue T, Amodru V, Castinetti F. Management of endocrine disease: management of Cushing's syndrome during pregnancy: solved and unsolved questions. *Eur J Endocrinol.* 2018;178(6):R259-R266.
- Leret ML, Rua C, Garcia-Montojo M, Lecumberri M, González JC. Influence of metyrapone treatment during pregnancy on the development and maturation of brain monoaminergic systems in the rat. *Acta Physiol (Oxf).* 2009;197(4):333-340.
- Lim WH, Torpy DJ, Jeffries WS. The medical management of Cushing's syndrome during pregnancy. *Eur J Obstet Gynecol Reprod Biol.* 2013;168(1):1-6.
- Ambroziak U, Kondracka A, Bartoszewicz Z, Krasnodębska-Kiljańska M, Bednarczyk T. The morning and late-night salivary cortisol ranges for healthy women may be used in pregnancy. *Clin Endocrinol (Oxf).* 2015;83(6):774-778.
- Choi R, Park HD, Oh HJ, Lee K, Song J, Lee SY. Dried blood spot multiplexed steroid profiling using liquid chromatography tandem mass spectrometry in Korean neonates. *Ann Lab Med.* 2019;39(3):263-270.
- Engels M, Pijnenburg-Kleizen KJ, Utari A, et al. Glucocorticoid activity of adrenal steroid precursors in untreated patients with congenital adrenal hyperplasia. *J Clin Endocrinol Metab.* 2019;104(11):5065-5072.
- Greenlee MM, Lynch IJ, Gumz ML, Cain BD, Wingo CS. Mineralocorticoids stimulate the activity and expression of renal H⁺,K⁺-ATPases. *J Am Soc Nephrol.* 2011;22(1):49-58.
- Boughton C, Taylor D, Ghataore L, Taylor N, Whitelaw BC. Mineralocorticoid hypertension and hypokalaemia induced by posaconazole. *Endocrinol Diabetes Metab Case Rep.* 2018;2018:1-5.
- Krasowski MD, Drees D, Morris CS, Maakestad J, Blau JL, Ekins S. Cross-reactivity of steroid hormone immunoassays: clinical significance and two-dimensional molecular similarity prediction. *BMC Clin Pathol.* 2014;14:33.
- Sprunt JG, Browning MC, Hannah DM. Some aspects of the pharmacology of metyrapone. *Proc R Soc Med.* 1967;60(9):908-909.
- Hotham NJ, Ilett KF, Hackett LP, Morton MR, Muller P, Hague WM. Transfer of metyrapone and its metabolite, rac-metyrapol, into breast milk. *J Hum Lact.* 2009;25(4):451-454.
- Hána V, Dokoupilová M, Marek J, Plavka R. Recurrent ACTH-independent Cushing's syndrome in multiple pregnancies and its treatment with metyrapone. *Clin Endocrinol (Oxf).* 2001;54(2):277-281.
- Andreescu CE, Alwani RA, Hofland J, et al. Adrenal Cushing's syndrome during pregnancy. *Eur J Endocrinol.* 2017;177(5):K13-K20.
- Caticha O, Odell WD, Wilson DE, et al. Estradiol stimulates cortisol production by adrenal cells in estrogen-dependent primary adrenocortical nodular dysplasia. *J Clin Endocrinol Metab.* 1993;77(2):494-497.