

2022

## Pulmonary Hypertension with “Normal” Pulmonary Vascular Resistance

Marwan F. Jumean

*The University of Texas Health Science Center at Houston, marwan.f.jumean@uth.tmc.edu*

Sriram Nathan

*The University of Texas Health Science Center at Houston, sriram.nathan@uth.tmc.edu*

Maria Patarroyo Aponte

*The University of Texas Health Science Center at Houston, maria.m.patarroyoaponte@uth.tmc.edu*

Follow this and additional works at: <https://digitalcommons.library.tmc.edu/josh>



Part of the [Cardiology Commons](#), and the [Critical Care Commons](#)

---

### Recommended Citation

Jumean, Marwan F.; Nathan, Sriram; and Patarroyo Aponte, Maria (2022) "Pulmonary Hypertension with “Normal” Pulmonary Vascular Resistance," *Journal of Shock and Hemodynamics*: Vol. 1(1) :E20221114 Available at: <https://digitalcommons.library.tmc.edu/josh/vol1/iss1/14>

This Perspective is brought to you for free and open access by the University of Texas Health Sciences Center at Houston (UTHealth) at DigitalCommons@TMC. It has been accepted for inclusion in Journal of Shock and Hemodynamics by an authorized editor of DigitalCommons@TMC. For more information, please contact [digitalcommons@library.tmc.edu](mailto:digitalcommons@library.tmc.edu).

**Perspectives**

# Pulmonary Hypertension with “Normal” Pulmonary Vascular Resistance

**Marwan Jumean, MD, Sriram Nathan, MD, and Maria Patarroyo-Aponte, MD**

Department of Advanced Cardiopulmonary Therapies and Transplantation, The University of Texas Health Science Center at Houston, Houston, USA

**Email:** Marwan.f.jumean@uth.tmc.edu*Received September 8, 2022**Published September 16, 2022*

It is widely known and accepted that as heart failure progresses, the hemodynamic changes of increasing mean pulmonary arterial pressure (mPAP) and pulmonary vascular resistance (PVR) are compensated by concentric remodeling of the right ventricle (RV), thus maintaining a normal cardiac index (CI) and a normal right atrial pressure (RAP). As the disease progresses and the RV fails, a different hemodynamic profile is noted: an elevated RAP, a relative reduction in mPAP, a narrower pulmonary artery (PA) pulse pressure, and a drop in CI (Figure). Clinically, this manifests with early satiety, persistent volume overload, worsening liver congestion, and renal failure. If this is not corrected rapidly, further reduction in CI, protein-losing enteropathy, hypoalbuminemia, and anasarca ensue.

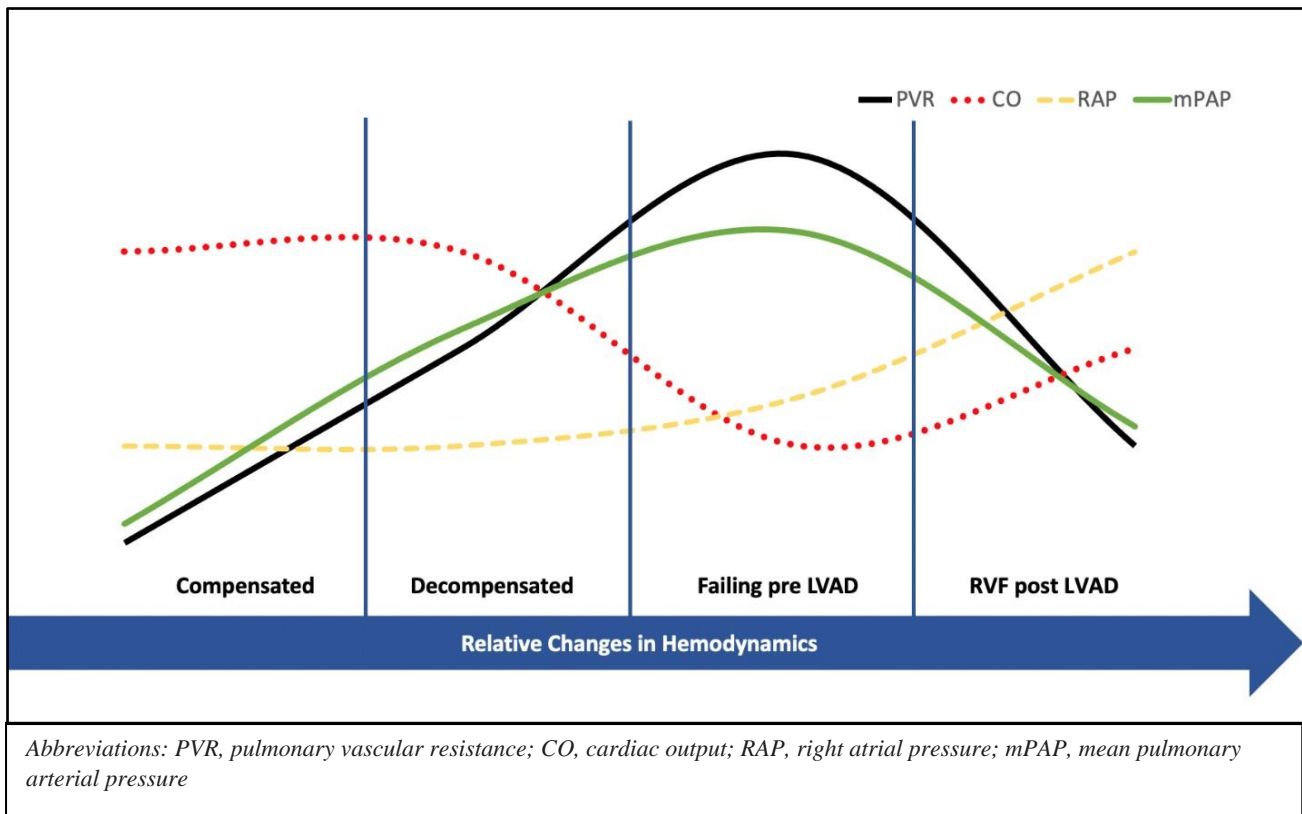
Orthotopic heart transplantation (OHT) is contraindicated in patients with high PVR (greater than 3 woods Unit) as it is associated with early graft dysfunction and increased mortality.<sup>1</sup> In longstanding stage D heart failure patients with elevated PVR, chronic unloading of the failed left ventricle with left ventricular assist device (LVAD) therapy allows for reverse remodeling of the pulmonary circulation and a reduction in PVR in most patients within six to twelve months.<sup>2</sup> This allows a previously high or prohibitive risk patient to become an acceptable risk with lower PVR and undergo successful OHT. However, some studies have also demonstrated that patients with a history of severe pulmonary hypertension pre-LVAD have a higher risk for in-hospital mortality after OHT, suggesting that reversal of pulmonary vascular remodeling may be incomplete and that PVR calculation is affected mainly by improvement in cardiac output (CO) rather than real changes in trans-pulmonary gradient (TPG). This underrecognized pulmonary vascular

remodeling could be the substrate for pulmonary hypertensive crisis immediately after a heart transplant that would be associated with primary graft dysfunction due to severe RV failure.<sup>3</sup>

In addition, a different clinical and hemodynamic profile is noted in a subset of patients with LVADs with severe refractory RV failure (Figure). Those patients suffer chronic sequelae of persistently elevated right-sided filling pressures with liver congestion, renal failure often necessitating renal replacement therapy, and a persistently vasodilated state. While they may appear stable with LVAD therapy, the hemodynamics of this state consist of a persistently elevated RAP > 15mmHg, equalization of chamber pressures in diastole, and normal to high CI. As such, PVR, calculated as TPG divided by CO, will not be elevated. CO calculations by thermodilution and Fick methods in this setting are often inaccurate due to severe tricuspid regurgitation and presumed fixed oxygen consumption, respectively. The reduction in mPAP is driven by RV failure, not by chronic LV unloading. Additionally, the obliteration of the diastolic gradient between pulmonary capillary wedge pressure and PA diastolic pressure is driven by RV failure.

As such, the commonly used parameters and calculations by which we assess RV afterload are often inaccurate in patients with LVADs with severe RV failure. PVR is often underestimated. We believe that this state of pulmonary hypertension with seemingly “normal” PVR (PHnPVR) is associated with a very high mortality rate, and exercising caution before listing these patients for heart transplantation is paramount. Perhaps using parameters of resistive and pulsatile afterload of the RV, such as pulmonary artery compliance and

Figure 1. Relative changes in hemodynamics as heart failure progresses and following left ventricular assist device implantation complicated by right ventricular failure.



elastance, may better risk stratify this subset of patients. In light of the increasing utilization of LVAD therapy in heart failure patients, further research in understanding the incidence, implications, and prognosis of PHnPVr is critical.

## References

- [1] Mehra M, Canter C, Hannan M, et al. The 2016 International Society for Heart Lung Transplantation listing criteria for heart transplantation: a 10 year update. *J Heart Lung Transplant*. 2016;35(1):1-23. doi: 10.1016/j.healun.2015.10.023.
- [2] Mikus E, Stepanenko A, Krabatsch T, et al. Reversibility of fixed pulmonary hypertension in left ventricular assist device support recipients. *Eur J Cardiothorac Surg*. 2011;40(4):971-7. doi: 10.1016/j.ejcts.2011.01.019.
- [3] Tsukashita M, Takayama H, Takeda K, et al. Effect of pulmonary vascular resistance before left ventricular assist device implantation on short and long term post-transplant survival. *J Thorac Cardiovasc Surg*. 2015;150(5):1352-60. doi: 10.1016/j.jtcvs.2015.07.012.