



Basic nutritional investigation

The antiinflammatory and antifibrotic effect of olive phenols and *Lactiplantibacillus plantarum* IMC513 in dextran sodium sulfate–induced chronic colitis



Antonella Vetuschi Ph.D.^a, Natalia Battista Ph.D.^b, Simona Pompili Ph.D.^{a,*}, Alfredo Cappariello Ph.D.^a, Roberta Prete Ph.D.^b, Agnese Taticchi Ph.D.^c, Roberto Selvaggini MS^c, Giovanni Latella G M.D.^d, Aldo Corsetti Ph.D.^b, Roberta Sferra Ph.D.^a

^a Department of Biotechnological and Applied Clinical Sciences, University of L'Aquila, L'Aquila, Italy

^b Faculty of Bioscience and Technology for Food, Agriculture and Environment, University of Teramo, Teramo, Italy

^c Department of Agricultural, Food and Environmental Sciences, University of Perugia, Perugia, Italy

^d Department of Life, Health and Environmental Sciences—Gastroenterology, Hepatology and Nutrition Division, University of L'Aquila, L'Aquila, Italy

ARTICLE INFO

Article History:

Received 23 March 2021

Received in revised form 17 September 2021

Accepted 3 October 2021

Keywords:

Inflammatory bowel disease

Diet

Olive

Probiotics

Lactiplantibacillus plantarum

Microbiome

ABSTRACT

Objectives: After a chronic intestinal injury, several intestinal cells switch their phenotype to activated myofibroblasts, which in turn release an abnormal amount of extracellular matrix proteins, leading to the onset of the fibrotic process. To date, no resolutive pharmacological treatments are available, and the identification of new therapeutic approaches represents a crucial goal to achieve. The onset, maintenance, and progression of inflammatory bowel disease are related to abnormal intestinal immune responses to environmental factors, including diet and intestinal microflora components. This study aimed to evaluate the potential antiinflammatory and antifibrotic effect of a biologically debittered olive cream and its probiotic oral administration in an experimental model of dextran sodium sulfate (DSS)–induced chronic colitis.

Methods: Chronic colitis was induced in mice by three cycles of oral administration of 2.5% DSS (5 d of DSS followed by 7 d of tap water). Mice were randomly divided into five groups: 10 control mice fed with standard diet (SD), 20 mice receiving SD and DSS (SD+DSS), 20 mice receiving an enriched diet (ED) with olive cream and DSS (ED+DSS), 20 mice receiving SD plus probiotics (PB; *Lactiplantibacillus plantarum* IMC513) and DSS (SD+PB+DSS), and 20 mice receiving ED plus PB and DSS (ED+ PB+DSS). Clinical features and large bowel macroscopic, histologic, and immunohistochemical findings were evaluated.

Results: The simultaneous administration of ED and PB induced a significant reduction in macroscopic and microscopic colitis scores compared with the other DSS-treated groups. In addition, ED and PB led to a significant decrease in the expression of inflammatory cytokines and profibrotic molecules.

Conclusions: The concomitant oral administration of a diet enriched with biologically debittered olive cream and a specific probiotic strain (*Lactiplantibacillus plantarum* IMC513) can exert synergistic antiinflammatory and antifibrotic action in DSS-induced chronic colitis. Further studies are needed to define the cellular and molecular mechanisms modulated by olive cream compounds and by *Lactiplantibacillus plantarum* IMC513.

© 2021 The Authors. Published by Elsevier Inc. This is an open access article under the CC BY-NC-ND license (<http://creativecommons.org/licenses/by-nc-nd/4.0/>)

Author Contributions: All authors have contributed to this article as follows: Antonella Vetuschi and Natalia Battista developed the study design, coordination, and manuscript drafting; Agnese Taticchi substantially contributed to the conception and design of the work; Roberto Selvaggini performed instrumental analyses of destoned pomaces for the production of olive cream; Simona Pompili performed the in vivo experiments, immunohistochemistry, and quantitative analyses; Alfredo Cappariello and Giovanni Latella provided study supervision and manuscript revision; Roberta Prete performed the fermentation and microbiological experiments; and Roberta Sferra and Aldo Corsetti conceived the experiments, supported the writing of the manuscript, and supervised the overall study. All authors have read and approved the final manuscript.

This research was funded by the Italian Ministry of University and Research (PRIN Project 20152LFKAT).

Antonella Vetuschi and Natalia Battista made equal contributions to this work.

Aldo Corsetti and Roberta Sferra also made equal contributions to this work.

*Corresponding author. Tel.: +390862-433504/74.

E-mail address: simona.pompili@guest.univaq (S. Pompili).

Introduction

Crohn's disease and ulcerative colitis are the two major inflammatory bowel diseases (IBDs). These chronic relapsing disorders cause critical alterations to intestinal functions owing to the development of fibrosis. Intestinal fibrosis can cause severe complications such as stenosis and obstructions [1–3]. Intestinal fibrosis is the result of an abnormal and uncontrolled deposition of extracellular matrix (ECM) proteins. The excessive accumulation of ECM proteins is owed to their increased production by locally activated myofibroblasts or to their reduced degradation by metalloproteinases. In intestinal fibrogenesis related to chronic inflammation, different cell types, including fibroblasts, subepithelial myofibroblasts, smooth muscle cells, epithelial cells, and endothelial cells, as well as pericytes and staminal cells, undergo differentiation processes and become activated ECM-producing myofibroblasts [4–6].

In most organs, including the intestine, one of the key players of inflammation and fibrosis is transforming growth factor $\beta 1$ (TGF- $\beta 1$). This cytokine can act not only through its canonical interaction with small mothers against decapentaplegic proteins (SMADs) but also with several other transduction pathways such as mammalian target of rapamycin and mitogen-activated protein kinase. Transforming growth factor $\beta 1$ interacts with numerous proinflammatory and antiinflammatory signaling pathways as well as profibrotic and antifibrotic molecules [7–13].

Current IBD therapies include the administration of 5-aminosalicylic acid, steroids, antibiotics, probiotics, and immunosuppressive or biological drugs (anti-tumor necrosis factor [TNF], anti-interleukin [IL]-6, anti-IL-17, anti-IL-12, anti-IL-23, anti- $\alpha 4\beta 7$, and anti-integrin monoclonal antibodies) [14–17]. All these drugs are effective in improving both acute and chronic inflammation, but they fail to prevent or reverse intestinal fibrosis. Bowel surgery remains the only available treatment for intestinal fibrostenosis. Therefore, the identification of new preventive strategies appears to be a necessary approach to avoid IBD-related intestinal fibrosis.

It is well known that several plants and algae extracts (i.e., artemisinin and spirulin) act as nutraceuticals, exerting beneficial effects on different diseases [18–23]. Natural drugs and dietary components may strongly modulate the gut immune response and microbiome [24–28]. In turn, the gut microbiome is known to interact with and affect distant systems and their functions, such as the central nervous system [29].

Furthermore, the microbiome can also be directly modulated by a dietary regimen. The Mediterranean diet appears to be a promising nutritional regimen in the prevention and management of several inflammatory disorders, including IBD. It is composed of a mix of fruit and vegetables (rich in fiber, vitamins, and antioxidants), grains and nuts, and virgin olive oil (containing monounsaturated and polyunsaturated fatty acids and phenolic compounds) [24,27,30–32]. In particular, *in vitro* and *in vivo* studies have highlighted the ability of polyphenols from olive oil to mitigate clinical and histological features of experimentally induced colitis [33–36].

Phenolic molecules suppress the expression of proinflammatory molecules, inhibit the activity of oxidant enzymes, and regulate several inflammatory signaling pathways [33–36]. Furthermore, some reports have shown that the oral administration of probiotics (i.e., lactic acid bacteria [LAB] and *Bifidobacterium* species) may contribute to the recovery of microbiome compositions and the maintenance of intestinal mucosa integrity [27,31,37,38]. Among the LAB, many strains of *Lactiplantibacillus* (*Lpb.*) *plantarum*, such as Sanriku-SU7, LP01, 03 06, and CBT LP3,

have been shown to exert beneficial effects on animal models of colitis, including in patients with IBD [39–44], leading to an increasing scientific interest in selecting specific probiotic strains that are effective in the treatment of IBD [45,46]. The mechanisms behind the beneficial effects of probiotics remain to be elucidated.

During the mechanical extraction of virgin olive oil, more than 47% of the total phenols present remain in the pomace [47]. The destoned pomace may represent an important food source of phenolic compounds, mainly derivatives of secoiridoids, but its gustatory acceptability may be achieved (as in the case of table olives) after a debittering process that is able to chemically or biologically hydrolyze the bitter secoiridoids into their aglycon phenolic derivatives. This processed product is a new kind of “olive cream.”

We hypothesize that the administration of a natural phenolic source in association with probiotics could mitigate colitis. In particular, the antigenotoxic and immunomodulatory effects of these compounds could be related to the activation of TGF- β –SMADs and TGF- β –non-SMADs signaling. Therefore, this study aimed to evaluate the potential antiinflammatory and antifibrotic role of administering biologically debittered olive cream produced from destoned pomace and a specific probiotic (*Lpb. plantarum* strain) in dextran sodium sulfate (DSS)–induced chronic colitis.

Materials and methods

This study was conducted according to the guidelines of the Declaration of Helsinki and the National Institutes of Health Guide for the Care and Use of Laboratory Animals (publication number 85-23, 1985) and was approved by the Institutional Review Board of the Ministero della Salute (authorization number 869/2018-PR Prot. CE5C5.20).

Olive cream

Destoned pomaces for olive cream production were obtained from olives (cv. Moraiolo) and processed by means of an industrial three-phase Alfa Laval decanter (0.3 ton/h) equipped with an olive destoner machine (AlfaOliver 500). Pomaces were subjected to the debittering process and analyzed for their phenolic composition by high-performance liquid chromatography with diode-array detection after phenol extraction. The analysis method has been described by Tuffariello et al. [48].

Bacterial strains and debittering process

All strains used in this study belong to the collection of the Faculty of Bioscience and Technology for Food, Agriculture, and Environment of the University of Teramo. In particular, two *Lpb. pentosus* strains, previously characterized for their oleuropeinolytic activity, were used as starter culture mixtures to produce olive cream through the biological debittering of the olive destoned pomace. Briefly, before olive pomace inoculation, *Lpb. pentosus* strains (used as debittering starter mixtures) were subcultured overnight in de Man, Rogosa, and Sharpe broth (Oxoid Ltd., Basingstoke, United Kingdom) at 30°C. Subsequently, bacterial cells were centrifuged, washed, and resuspended in sterile saline solution (0.85% weight/volume).

Destoned olive pomace was unfrozen overnight at room temperature and aliquoted (800 g) into sterilized glass vessels. Subsequently, after the addition of glucose (20g/L) and yeast extract powder (10 g/L), the olive pomace was thermally stabilized in an autoclave at 121°C for 5 min. The olive pomace was inoculated with a mixture (1:1 ratio) of the two *Lpb. pentosus* strains at a final concentration of 10⁷ colony forming units (CFU)/mL and incubated at 30°C for 72 h to allow fermentation to occur. The fermentative activity of the starter mixture was confirmed by monitoring microbial communities, pH, and titratable acidity as well as the evolution of the phenolic composition (data not shown).

In addition, the human-derived probiotic *Lpb. plantarum* IMC513 (Synbiotec S. r.l., Camerino, Italy), which previously has been characterized to possess several beneficial properties including antiinflammatory effects in *in vitro* intestinal cell models [49–53], was used as a dietary adjunct in tap water at a final concentration of 10⁹ CFU/mL/mice/die. The dosage was selected based on similar experiments reported in the current literature [54,55].

Animals

The induction of experimental colitis was carried out at the Department of Biotechnological and Applied Clinical Sciences, University of L'Aquila (L'Aquila, Italy). All experiments complied with government guidelines (European Economic

Community Council Directive 86/609, OJ 358, December 1, 1987; Italian Legislative Decree 116/92, Gazzetta Ufficiale della Repubblica Italiana no. 40, February 18, 1992; National Institutes of Health Guide for the Care and Use of Laboratory Animals, publication no. 85-23, 1985) and approved by the Minister of Health (authorization number 869/2018-PR Prot. CE5C5.20).

Ninety C57BL/6 wild-type male mice were included in the study (Charles River Laboratories, Lyon, France). All animals were housed in a plastic cage and kept in a pathogen-free environment at constant room temperature, with a 12 h/12 h light/dark cycle and food and water ad libitum.

We provided animals with 20 g dry weight of food at 100 g/animal/d, according to Animal Research Review Panel guidelines. The animals were housed two or three per cage to guarantee social behavior and equal access to food. At 20 d of life, the mice were randomly divided into five groups: 10 mice received a standard diet (SD) and were used as controls; 20 received SD and DSS (SD+DSS); 20 received an enriched diet (ED) with 10% biologically debittered olive cream and DSS (ED+DSS); 20 received SD plus probiotic (PB; *Lpb. plantarum* IMC513) and DSS (SD+PB+DSS); and 20 received ED plus PB and DSS (ED+PB+DSS).

Experimental procedures

Chronic colitis was induced in mice by oral administration of 2.5% w/v DSS (molecular weight: 36 000–44 000 kDa, purchased from TdB Labs, Uppsala, Sweden). The DSS was solubilized in autoclaved tap water and administered ad libitum for three cycles (5 d of DSS followed by 7 d of tap water). The control group received only tap water.

Two groups of animals (ED+DSS and ED+PB+DSS) received DSS in tap water and were fed with chow enriched with 10% biologically debittered, core-free olive cream. The phenolic composition of the fermented cream used in the enriched diet is reported in Table 1. Both SD and ED chow were produced by Mucedola S.r.l. (Milan, Italy).

Two groups of animals (SD+PB+DSS and ED+PB+DSS) received DSS and the *Lpb. plantarum* IMC513 probiotic strain in tap water as follows: 10^9 CFU/mL/mouse/d, equivalent to 10 mg in 10 mL of tap water/mouse/die.

Sample recovery, preparation, and assessment of colonic injury

Animals were monitored daily for fluid intake and weight changes and examined for signs of colitis, including weight loss and diarrhea (scored on a 0–2 scale as follows: 0 = absence, 1 = mild, and 2 = severe) [56].

Body weight was measured every week. Four days after the last DSS cycle, all animals were euthanized by carbon dioxide. Following laparotomy, the colon was identified, rapidly excised, and photographed. On a scale from 0 to 2, the presence of adhesions between the colon and adjacent organs was assessed. The length and the weight of the colon were measured and the colon was then scored for macroscopic lesions. Then, colonic tissue samples were fixed in 4% buffered formaldehyde and embedded in paraffin for histological and immunohistochemical analysis.

Macroscopic and microscopic evaluation of colonic injury

Colon length and weight were measured to score the macroscopic lesions by two independent observers on a 0–2 scale as follows: colonic adhesions (0 = absence, 1 = mild or focal zonal, 2 = severe or diffuse); colonic dilation (0 = absence, 1 = mild, 2 = severe); and colonic thickness (0 = normal, 1 = mild

increase, 2 = marked increase [>3 mm]) [56]. The total macroscopic score was expressed as the sum of the individual scores of colonic alterations.

To evaluate microscopic features, colonic samples were subjected to conventional histological procedures: they were fixed in 4% buffered formalin in phosphate buffer saline (PBS) at pH 7.4 for 3 h at room temperature and then paraffin embedded. Serial 3- μ m sections were stained with hematoxylin and eosin to assess organ morphology and highlight the degree of inflammation and with Masson's trichrome stain to detect connective tissue deposition and evaluate the stage of fibrosis. The stained sections were observed under an Olympus BX51 Light Microscope (Olympus Optical Co. Ltd, Tokyo, Japan) and scored in a double-blind manner according to the presence of ulcerations (0 = absent, 1 = small ulcers, 2 = big ulcers), degree of inflammation (0 = absent, 1 = mild, 2 = moderate, and 3 = severe), depth of the lesions (0 = absent, 1 = lesions extending into the submucosa, 2 = lesions in the muscularis propria, and 3 = lesions in the serosa), and degree of fibrosis (0 = absent, 1 = mild, 2 = moderate, 3 = severe) [49]. The total microscopic score was expressed as the sum of the individual scores.

Signs of intestinal inflammation were scored as absent, mild, moderate, or severe according to the density and the extent of the inflammatory infiltrate, the loss of goblet cells, and the thickening of the bowel wall.

Fibrosis staging was assessed by Masson's trichrome staining as mild, moderate, or severe based on the density and the extent of the connective tissue as well as the disruption of tissue architecture.

Immunohistochemistry analyses

Colonic specimens were fixed in 4% buffered formalin in PBS (pH 7.4) for 3 h, dehydrated in graded ethanol, and embedded in low-melting paraffin. Sections (3 μ m thick) were incubated in methanol for 40 min and then in 3% hydrogen peroxide for 5 min. Samples were incubated overnight at 4°C with specific antibodies (Table 2). To control for the specificity of the immune reactions, control sections were incubated omitting the primary antibody.

The specimens were washed in PBS (three times for 5 min each) and incubated with streptavidin-biotin-peroxidase-conjugated secondary antibody (K0675; DakoCytomation, Milano, Italy). After being rinsed in PBS for 10 min, the sections were incubated with 3,3'-diaminobenzidine-tetrahydrochloride for 1–3 min. Finally, the sections were counterstained with Mayer's hematoxylin, mounted, and observed under an Olympus BX51 Light Microscope.

Semiquantitative digital image analysis of immunohistochemical staining

Semiquantitative comparison of immunohistochemical staining was measured using ImageJ, public domain software for digital image analysis [57]. The immunohistochemistry profiler software plugin was required. Immunopositivity was expressed as a percentage of the total software-classified areas, and the data obtained were plotted as histograms. Results were expressed as means \pm standard deviation; a *P* value <0.05 was considered statistically significant.

Statistical analysis

Histological scores were reported as means \pm standard error of the means. Analysis of variance with the post hoc Mann–Whitney *U* test was used to determine differences between groups for normally and not normally distributed data, respectively, at *P* <0.05 . Analyses were conducted using GraphPad Prism, version 7.00 (GraphPad Software, Inc., La Jolla, California, United States).

Results

Biologically debittered olive cream and probiotic oral administration improved DSS-induced chronic colitis and fibrosis.

Effect of the administration of biologically debittered olive cream and probiotics on clinical features and macroscopic and microscopic findings

First, the effects of treatments on the health and zoometric parameters were assessed. Male C57BL/6J mice were monitored for body weight at 1, 2, 3, and 4 wk, and no significant loss of body weight was observed in any group (Fig. 1A). Dextran sodium sulfate acts as chemical irritant in the large intestine, inducing inflammation and alteration in the organ structure. Macroscopic evaluation revealed a significant increase in colon weight (referred to as the last 8 cm of the distal large bowel) and a reduction in colon length in SD+DSS mice compared with the control group (Fig. 1B, C; Table 3).

Table 1

Phenolic composition of the fermented olive cream included in the enriched diet chow (formula weight)

Compound	Quantity
3,4-DHPEA	1159.33 \pm 5.7 mg/kg
p-HPEA	404.84 \pm 0.7 mg/kg
Vannilic acid	622.48 \pm 2.4 mg/kg
Hydroxytyrosol acetate	153.32 \pm 1.3 mg/kg
Caffeic acid	114.87 \pm 0.7 mg/kg
Verbascoside	1118.64 \pm 6.4 mg/kg
Isoverbascoside	441.94 \pm 6.7 mg/kg
3,4-DHPEA-EDA	335.35 \pm 4.2 mg/kg
p-HPEA-EDA	56.70 \pm 1.9 mg/kg
Rutin	159.51 \pm 6.1 mg/kg
(+) - 1-Acetoxy-pinoreosinol	37.194 \pm 0.4 mg/kg
(+) - Pinoreosinol	17.492 \pm 0.9 mg/kg
Luteolin	79.30 \pm 3.3 mg/kg
Total amount of phenols	4701.0 \pm 13.2 mg/kg

3,4-DHPEA, 3,4-dihydroxyphenylethanol-elenolic acid; p-HPEA, para-hydroxyphenyl ethyl alcohol; 3,4-DHPEA-EDA, 3,4-dihydroxyphenylethanol-elenolic acid dialdehyde

Table 2
Antibodies used with their sources and dilutions

Antibody	Source	Dilution
Interleukin (IL)-1 β	Santa Cruz Biotechnology Inc., Santa Cruz, California, USA; code sc-32294	1:100
IL-6	Santa Cruz Biotechnology Inc., Santa Cruz, California, USA; code sc-28343	1:100
Tumor necrosis factor (TNF)- α	Biorbyt Ltd, Cowley Road, Cambridge, Cambridgeshire, UK; code orb323199	1:100
Transforming growth factor (TGF)- β 1	Santa Cruz Biotechnology Inc., Santa Cruz, California, USA; code sc-146	1:100
Phosphorylated small mothers against decapentaplegic (p-SMAD)3	Santa Cruz Biotechnology Inc., Santa Cruz, California, USA; code sc-130218	1:200
Phosphatidylinositol 3-kinase (PI3K)	Thermo Fisher Scientific, Waltham, Massachusetts, USA; code PA5-28070	1:100
Phosphorylated protein kinase B (p-Akt)	Biorbyt Ltd, Orwell Furlong, Cowley Rd, Cambridge, UK; code orb397210	1:100
Alpha smooth muscle actin (α -SMA)	Santa Cruz Biotechnology Inc., Santa Cruz, California, USA; code sc-32251	1:200
Collagen I–III	Santa Cruz Biotechnology Inc., Santa Cruz, California, USA; codes sc-8784; sc-8781	1:200

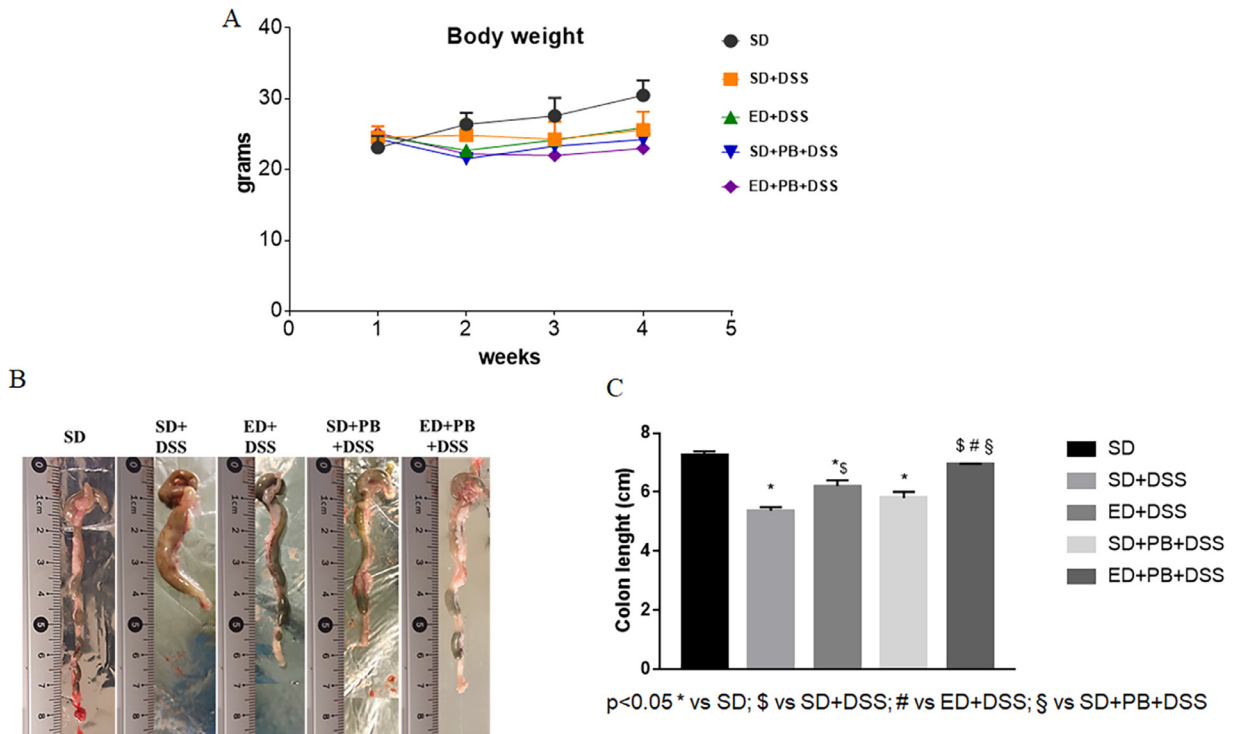


Fig. 1. (A) Body weights. Mice were weighed at 1, 2, 3, and 4 wk. No significant differences were found among the groups. (B) Macroscopic evaluation of explanted colons at 36 d posttreatment. Representative images of the macroscopic appearance of the colon from mice in the five different groups (SD, SD+DSS, ED+DSS, SD+PB+DSS, and ED+PB+DSS). (C) Assessment of colon length. Values are means \pm standard errors of means. Statistical significance was calculated via analysis of variance ($P < 0.05$). DSS, dextran sodium sulfate; ED, enriched diet; PB, probiotic; SD, standard diet.

The main macroscopic signs associated with chronic DSS administration (dilatation, thickness, stenosis, and adhesions) were improved in mice that were simultaneously fed with olive cream-enriched chow and probiotics. The total macroscopic score was lower in mice treated with ED+PB+DSS versus those treated with SD+DSS (Table 3; Fig. 2).

The other DSS-treated groups did not show significant improvement in colonic parameters associated with DSS administration or a reduction in total macroscopic score compared with SD+DSS mice (Table 3; Fig. 2). After the second cycle of oral administration of DSS, evident signs of disease, including reduced mobility, a decrease of social interactions, raised fur, and diarrhea, were detected in all DSS-treated mice.

Chronic administration of DSS can induce both colorectal inflammation and fibrosis. Histomorphology evaluation, as assessed by hematoxylin and eosin staining, showed marked signs of inflammation in SD+DSS mice compared with SD mice

and ED+PB+DSS mice (Fig. 3A). Inflammation involved the mucosal and submucosal layers and was characterized by increased infiltration of inflammatory cells and a decrease in goblet cells as well as reduction and alteration of crypt architecture. Features of inflammation were also found in ED+DSS and ED+PB+DSS mice, although to lesser degree compared with SD+DSS mice (Fig. 3A). Masson's trichrome staining highlighted signs of fibrosis in SD+DSS mice compared with the other groups (Fig. 3B). In particular, an increase in collagen deposition was observed in the mucosa, submucosa, and serosa layer of SD+DSS mice, which decreased in the other DSS-treated groups (mainly in ED+PB+DSS mice) (Fig. 3B). The total microscopic score showed a significant reduction in inflammation and signs of fibrosis in the ED+PB+DSS group compared with SD+DSS-treated mice (Fig. 3C, D). No noticeable improvement in these parameters was observed in mice receiving ED+DSS or SD+PB+DSS (Fig. 3C, D).

Table 3
Effect of a diet enriched with fermented olive cream and probiotics on the macroscopic features of DSS-induced colitis

Parameter	SD	SD+DSS	ED+DSS	SD+PB+DSS	ED+PB+DSS
Duration of DSS administration, d	-	36	36	36	36
Duration of diet administration, d	36	36	36	36	36
Duration of probiotic administration, d	-	-	-	36	36
Number of mice	10	20	20	20	20
Body weight, g	30.5 ± 0.67	25.6 ± 0.58 ^{ns}	25.93 ± 0.45 ^{ns}	24.25 ± 0.57 ^{ns}	23.0 ± 0.54 ^{ns}
Colon weight, g	0.11 ± 0.003	0.25 ± 0.006 [*]	0.20 ± 0.019 ^{*,†}	0.19 ± 0.02 ^{*,†}	0.18 ± 0.013 [*]
Colon length, cm	7.25 ± 0.13	5.37 ± 0.12 [*]	6.2 ± 0.2 ^{*,†}	5.8 ± 0.21 [*]	6.95 ± 0.011 ^{†,‡,§}
Colon weight/body weight, %	0.3 ± 0.005	0.9 ± 0.01 ^{ns}	0.7 ± 0.42 ^{ns}	0.8 ± 0.035 ^{ns}	0.8 ± 0.024 ^{ns}
Dilatation	np	1.28 ± 0.11 [*]	1.16 ± 0.23 [*]	1.10 ± 0.21 [*]	0.75 ± 0.10 [*]
Thickness	np	1.12 ± 0.12 [*]	1.09 ± 0.25 [*]	1.12 ± 0.23 [*]	0.88 ± 0.13 [*]
Stenosis	np	0.72 ± 0.11 [*]	0.65 ± 0.28 [*]	0.85 ± 0.25 [*]	0.30 ± 0.12 [*]
Adhesions	np	0.42 ± 0.15 [*]	0.36 ± 0.27 [*]	0.33 ± 0.24 [*]	0.10 ± 0.16 [*]
Total macroscopic score	-	3.54 ± 0.28 [*]	3.26 ± 0.59 [*]	3.4 ± 0.54 [*]	2.03 ± 0.28 ^{*,†}

DSS, dextran sodium sulfates; ED, enriched diet; ns, not significant; np, not present; PB, probiotic; SD, standard diet

Data are expressed as mean ± standard error of the mean

*P < 0.05 versus SD

†P < 0.05 versus SD+DSS

‡P < 0.05 versus ED+DSS

§P < 0.05 versus SD+PB+DSS

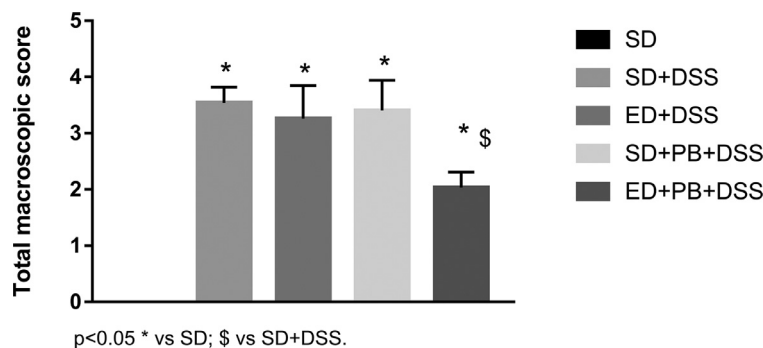


Fig. 2. Total macroscopic score evaluation. The total macroscopic score was calculated as the sum of the score of individual macroscopic lesions (dilatation, thickness, stenosis, and adhesions). Mice receiving ED+PB+DSS showed a significant reduction in macroscopic score compared with the group receiving SD+DSS. DSS, dextran sodium sulfate; ED, enriched diet; PB, probiotic; SD, standard diet.

Effect of fermented olive cream and probiotic oral administration on the expression of inflammatory and fibrotic cytokines

Generally, macroscopic and structural changes of the intestine owing to inflammation and fibrogenesis are associated with an abnormal cytokine profile. To assess the degree of inflammation, we performed immunohistochemical analysis, examining the inflammatory cytokines IL-1 β , IL-6, and TNF- α (Fig. 4A–C). As expected, all three markers were increased in SD+DSS mice compared with the controls. Furthermore, a noticeable reduction was detected in ED+PB+DSS mice compared with the other groups, as confirmed by semiquantitative analysis of each of the examined cytokines (Fig. 4D–F).

Chronic inflammation leads to extracellular matrix deposition and contributes to the onset and progression of fibrosis. To evaluate the fibrogenesis status in our experimental groups, we assessed the expression of TGF- β 1, the pivotal driver of intestinal fibrosis. Although TGF- β 1 was expressed in all DSS-treated mice (Fig. 5A), a significant increase in this protein was detectable in SD+DSS mice compared with the ED+PB+DSS group, confirming the ability of olive phenols and probiotics to reduce the progression of fibrosis (Fig. 5A, C).

The TGF- β 1 profibrotic signal acts through the activation of the downstream SMADs cascade. Accordingly, we found a significant overexpression of p-SMAD3 in SD+DSS mice as well in the other DSS-treated mice compared with the ED+PB+DSS group (Fig. 5B,

D). These data for both TGF- β 1 and p-SMAD3 were supported by the semiquantitative analyses results (Fig. 5C, D).

To analyze the ability of TGF- β 1 to regulate fibrosis through its noncanonical pathway, we assessed the expression of phosphatidylinositol 3-kinase (PI3K) and phosphorylated protein kinase (p-Akt) (Fig. 6). These molecules are strongly associated with the release of inflammatory cytokines and the fibrotic process.

Expression of PI3K was significantly increased in SD+DSS mice compared not only with the SD group but also with ED+DSS+PB mice, confirming an improvement in fibrosis attributable to the simultaneous administration of olive cream and probiotics (Fig. 6A).

Similarly, immunohistochemistry staining for p-Akt showed a noticeable reduction in ED+PB+DSS mice, comparable with SD mice, with respect to the other experimental groups (Fig. 6B). These results were validated by semiquantitative analyses (Fig. 6C, D).

To investigate the beneficial effects of the administration of fermented olive cream and *Lpb. plantarum* on DSS-induced colitis, we assessed the fibrotic markers alpha smooth muscle actin (α -SMA) and collagens I–III (Fig. 7).

Immunohistochemistry analysis highlighted the increased expression of α -SMA in SD+DSS mice compared with the other groups (Fig. 7A). In particular, in SD+DSS-treated animals, α -SMA immunopositivity was present not only in the muscle cells of the muscularis mucosa and muscularis propria but in the lamina

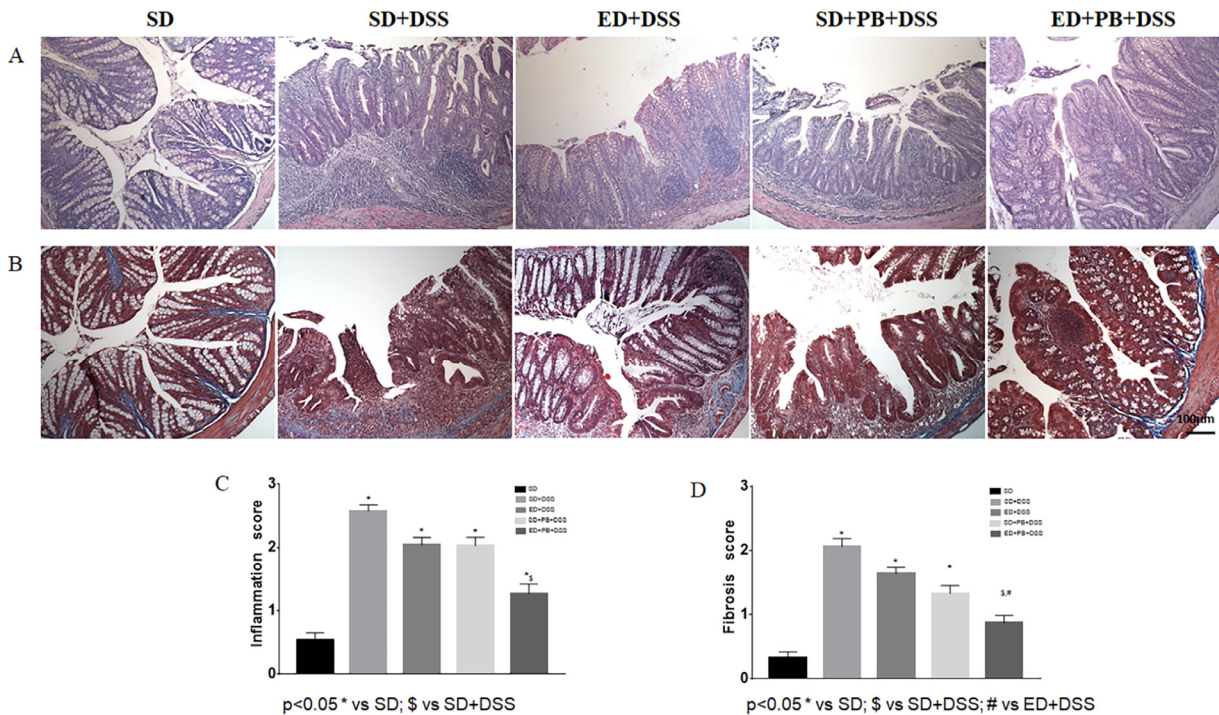


Fig. 3. (A) Hematoxylin and eosin staining. (B) Masson's trichrome staining. Original magnification: 10 ×; scale bar: 100 μm. Mice receiving ED+PB+DSS showed a significant reduction in signs of chronic inflammation and fibrosis compared with the other DSS-treated groups. (C) Inflammation score. (D) Fibrosis score. Graphs of inflammation (calculated as 0 = absent, 1 = mild, 2 = moderate, and 3 = severe) and fibrosis (calculated as 0 = absent, 1 = mild, 2 = moderate, and 3 = severe) scores showed a significant reduction in colitis features in ED+PB+DSS mice compared with mice in other groups. DSS, dextran sodium sulfate; ED, enriched diet; PB, probiotic; SD, standard diet.

propria, submucosa, and serosa layers. In ED+PB+DSS mice, expression was mostly restricted to the typical layers, which was also observed for SD-fed mice (Fig. 7A). Evaluation of collagens I–III revealed poor immunopositivity in ED+PB+DSS the group, which was similar to the control. Conversely, the expression of collagens I–III was significantly increased in the other DSS-treated mice (Fig. 7B). These results, for both α -SMA and collagens I–III, were confirmed by semiquantitative evaluation (Fig. 7C, D).

Discussion

Chronic intestinal inflammation commonly leads to fibrosis, owing to the uncontrolled production and deposition of ECM components. This process is modulated by both profibrotic and antifibrotic factors [9]. Intestinal fibrosis plays a central role in the changes that occur to the intestinal wall architecture, which can lead to strictures, obstruction, and loss of function. The pathophysiology of intestinal fibrosis is still unclear, although several risk factors including diet, environmental factors, immune response, pathogens, genetic alterations, and the intestinal microbiome contribute to its onset and progression [58–62]. The gut microbiome ecosystem is essential for the maintenance of intestinal barrier functions, and its disruption seems to play a pivotal role in the development of chronic intestinal inflammation and fibrosis, which occurs in IBD.

Various animal models have provided significant and relevant insights toward understanding the histopathological and morphological changes that occur in the intestinal wall. Colitis induced by DSS, one of the most frequently used models of experimental colitis, causes intestinal epithelial barrier disruption with a consequent massive passage of intraluminal microbes and antigens into the mucosa and submucosa,

triggering the local inflammatory response [63]. Dextran sodium sulfate induces mucin depletion, altering the mucus layers adhering to the mucosal surface, making it more permeable to luminal microbes. Colitis induced by DSS is associated with significant intestinal dysbiosis [63,64].

Dietary habits have been strongly linked to the maintenance of intestinal epithelium homeostasis. Alterations of this homeostasis contribute to the pathogenesis of chronic intestinal inflammation and the related risk of colorectal cancer. In recent years, great attention has been focused on the correlation between the Western diet, characterized by a high amount of fat and low amounts of fruits and vegetables, and the alarming increase in the incidence of several disorders, including IBD and colorectal cancer [58–61,65,66]. On the contrary, the Mediterranean diet, which is rich in fruits, vegetables, grains, nuts, and olive oil, represents one of the most promising dietary regimens for the prevention and management of intestinal disorders [67].

In particular, the beneficial effects on health of extra virgin olive oil, attributed to the monounsaturated fat content and to the presence of phenolic compounds, include antioxidant, anti-inflammatory, and immunomodulatory properties. Among dietary components, monounsaturated fatty acids and phenolic compounds appear to be beneficial for gut health [68,69].

Consumption of extra virgin olive oil causes a strong anti-inflammatory effect on the gut mucosa, because it interacts with antioxidant molecules (i.e., hydroxytyrosol, squalene, and oleuropein derivatives) to modulate intestinal permeability and modify the intestinal microbiota [70,71].

Moreover, increasing attention has been paid to the development of nondairy fermented foods such as vegetable food matrices to overcome the limitations of lactose intolerance and vegetarian or cholesterol-restricted diets. Among the products of vegetable

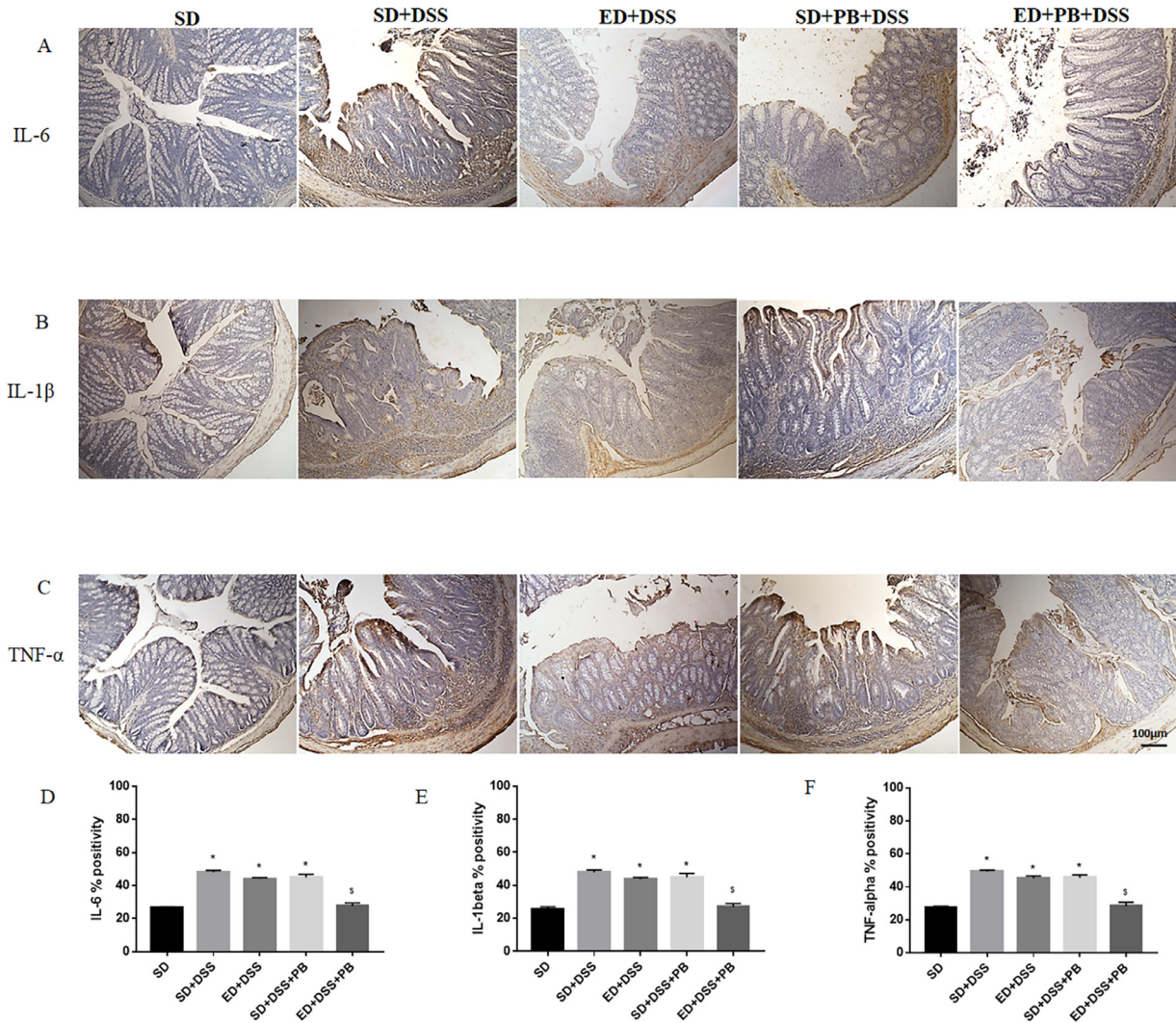


Fig. 4. (A–C) Immunohistochemistry of the inflammatory cytokines IL-6, IL-1 β , and TNF- α . Original magnification: 10 \times ; scale bar: 100 μ m. The expression of the indicated inflammatory molecules was decreased in ED+PB+DSS mice compared with the other DSS-treated groups. (D–F) Semiquantitative evaluation of IL-6, IL-1 β , and TNF- α . This analysis confirmed a significant reduction in the examined inflammatory cytokines in the ED+PB+DSS group. $P < 0.05$ versus SD (*) and SD+DSS (s). DSS, dextran sodium sulfates; ED, enriched diet; IL, interleukin; PB, probiotic; SD, standard diet; TNF, tumor necrosis factor.

origin, table olives and their derivatives (i.e., olive cream) represent an important source of fiber and bioactive molecules such as phenolic compounds and triterpene acids. The palatability of olive cream (as for table olives) is achieved after a fermentation process that is able to hydrolyze bitter secoiridoids and enhance the sensory and aromatic profile of the final product. Biotransformation using selected LAB is a suitable alternative to chemical hydrolysis [72]. Several studies have shown that olive hydrophilic phenols (mainly secoiridoids, exclusive to the *Oleaceae* family) exert antioxidant, antimicrobial, and antiinflammatory activities, leading to numerous health benefits such as a reduction in cardiovascular risk factors and the prevention of various chronic diseases, chronic inflammation, stroke, and other degenerative diseases [48,73–76].

Accordingly, several studies have shown the ability of some probiotics to reduce intestinal inflammation in experimental models of colitis [76–78]. Among probiotics, *Lpb. plantarum* represents one of the most versatile and promising species for its various health-promoting effects; thus, the administration of *Lpb. plantarum* strains has shown a promising role in ameliorating colon

inflammation in different models of experimental colitis [43,79–83]. The promising use of *Lpb. plantarum* probiotic strains as a dietary intervention to prevent and/or attenuate gut inflammatory diseases such as IBD was also recently confirmed in human intervention studies [84–86].

In general, probiotics attenuate colon inflammation by downregulating inflammatory signaling as well as modulating mucosal immunity and gut microbiota [43]. The mechanisms behind these beneficial effects are still unclear; however, *Lpb. plantarum* has been found to be able to prevent and/or ameliorate IBD conditions, mainly by modulating specific proinflammatory and antiinflammatory pathways [87].

In particular, the production of proinflammatory cytokines such as TNF- α , IL-1 β , and IL-6 in Bagg Albino/c in DSS-induced colitis in mice was reduced by the oral administration of *Lpb. plantarum* K68 [88]. A similar antiinflammatory effect was found following the administration of *Lactobacillus brevis* K65 [89]. The beneficial effect of *Lpb. plantarum* 06CC2 in DSS-induced colitis in mice was found to be mainly owed to the increased production of the antiinflammatory cytokine IL-10 [82].

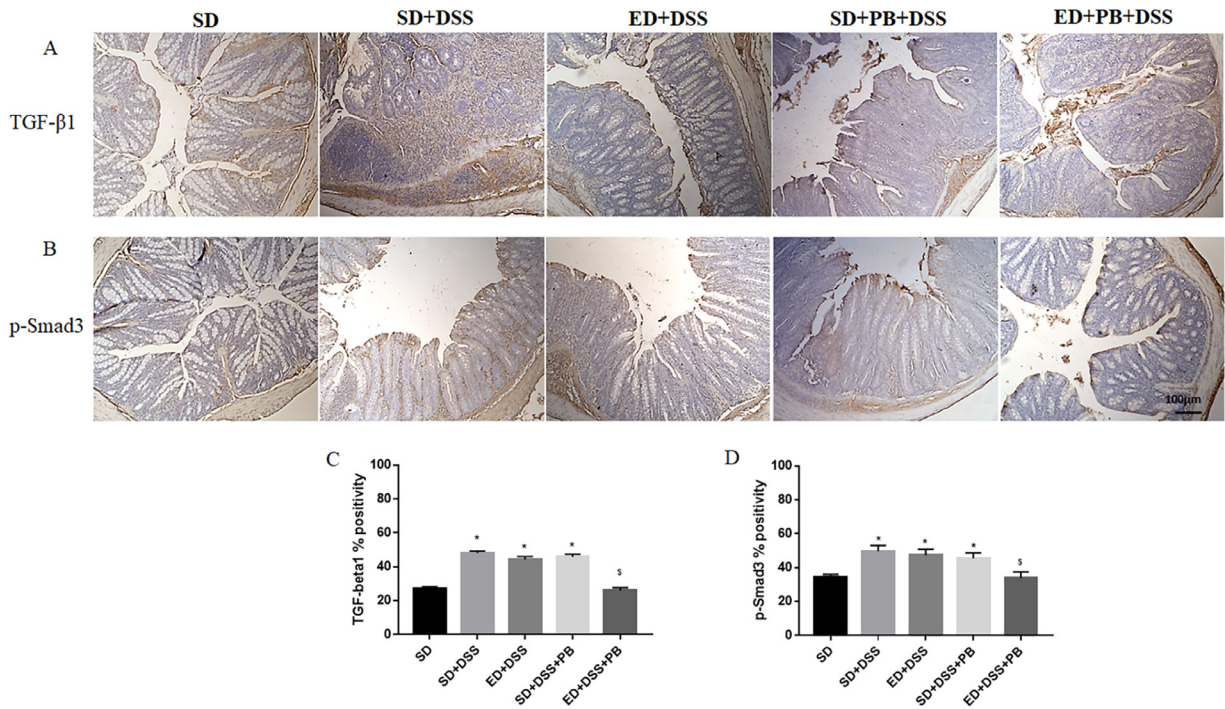


Fig. 5. (A, B) Immunohistochemistry of TGF- β 1 and p-SMAD3 molecules. Original magnification: 10 \times ; scale bar: 100 μ m. An increased expression of both TGF- β 1 and p-SMAD3 was seen in DSS-treated mice compared with the ED+PB+DSS group. (C, D) Semi-quantitative evaluation of TGF- β 1 and p-SMAD3. This analysis validated the significant increase in the expression of these molecules in SD+DSS mice compared with the ED+PB+DSS group. $P < 0.05$ versus SD (*) and SD+DSS (\dagger). DSS, dextran sodium sulfates; ED, enriched diet; PB, probiotic; SD, standard diet; SMAD, small mothers against decapentaplegic protein; TGF, transforming growth factor.

This study showed that the simultaneous oral administration of a diet enriched with fermented olive cream and a probiotic significantly improved both intestinal inflammation and

fibrosis in the experimental model of DSS-induced colitis. The mice receiving ED+PB+DSS showed a reduction in the clinical features and the macroscopic and microscopic parameters of

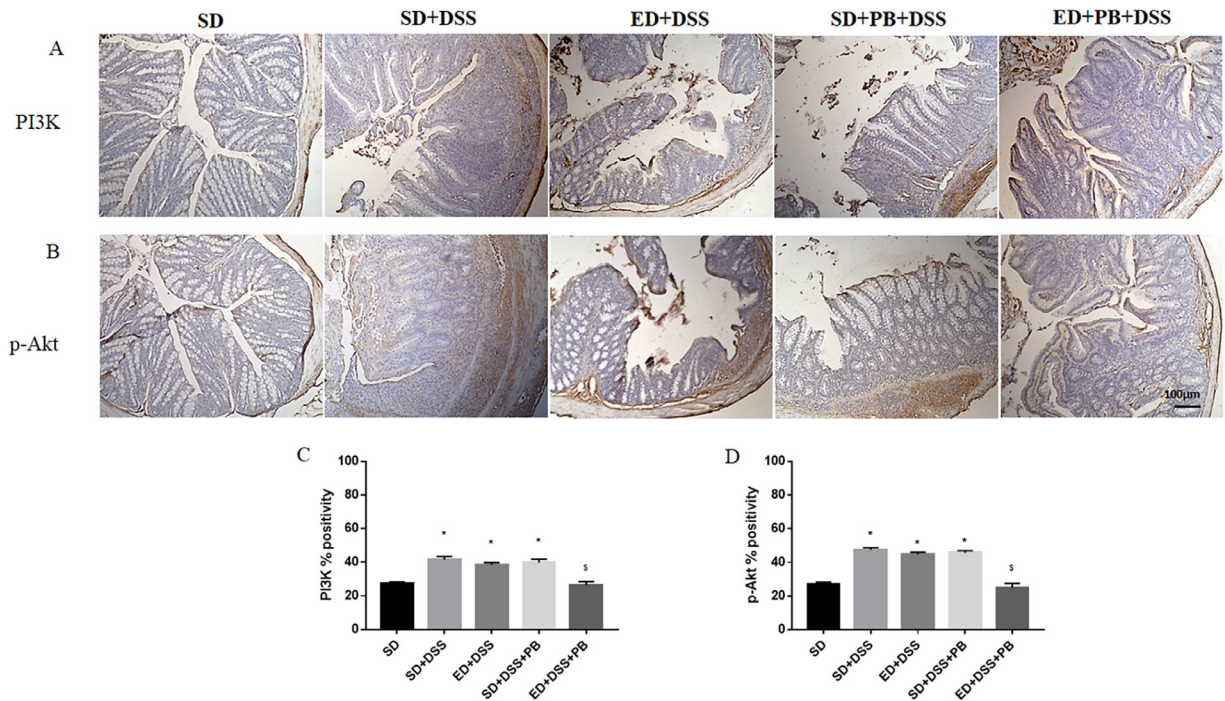


Fig. 6. (A, B) Immunohistochemistry of PI3K and p-Akt. Original magnification: 10 \times ; scale bar: 100 μ m. A significant increase in PI3K and Akt expression was seen in DSS-treated groups compared with ED+PB+DSS mice, in which the positivity was similar to control mice. (C, D) Semi-quantitative analysis of PI3K and p-Akt. This analysis confirmed the significant increase of these molecules in the SD+DSS group compared with ED+PB+DSS-treated mice. $P < 0.05$ * versus SD (*) and SD+DSS (\dagger). DSS, dextran sodium sulfates; ED, enriched diet; p-Akt, phosphorylated protein kinase; PB, probiotic; PI3K, phosphatidylinositol 3-kinase; SD, standard diet.

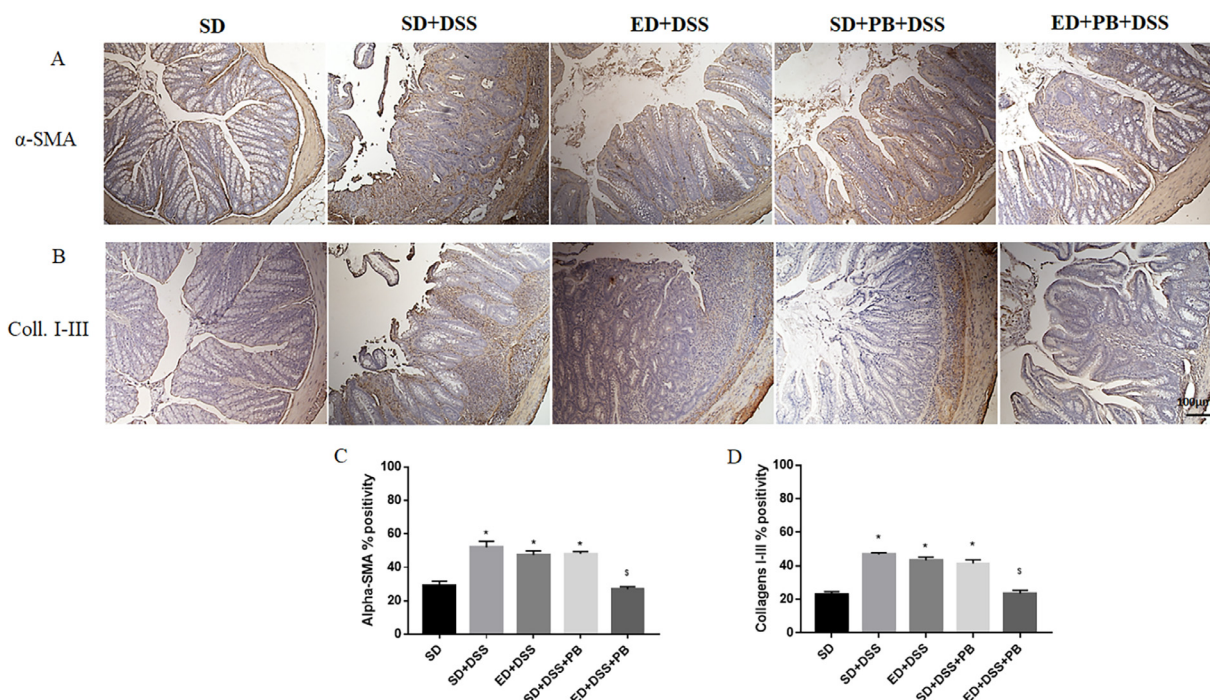


Fig. 7. (A) (B) Immunohistochemistry of α -SMA and collagens I–III. Original magnification: $10\times$; scale bar: $100\ \mu\text{m}$. The immunopositivity of α -SMA and collagens I–III was significantly reduced in ED+PB+DSS mice compared with the other DSS-tested groups. (C) (D) Semiquantitative analysis of α -SMA and collagen I–III. This analysis highlighted the significant decrease in the expression of these molecules in ED+PB+DSS-treated mice compared with the other fibrotic groups. $P < 0.05$ * versus SD; \$ versus SD+DSS. α -SMA, alpha smooth muscle actin; DSS, dextran sodium sulfates; ED, enriched diet; PB, probiotic; SD, standard diet.

large bowel inflammation and fibrosis compared with the mice in other groups.

Histological analyses revealed that inflammatory infiltrates and the signs of fibrosis were significantly ameliorated in mice receiving ED+PB+DSS. In this group, we detected a decreased expression of the inflammatory molecules IL-1 β , IL-6, and TNF- α compared with the SD+DSS, ED+DSS, and SD+PB+DSS groups, as supported by semiquantitative evaluation.

Immunohistochemical and semiquantitative analyses for TGF- β 1, p-SMAD3, PI3K, p-Akt, α -SMA, and collagens I–III showed a decreased expression of these inflammatory and fibrotic markers in the ED+PB+DSS group. These data show the efficacy of the olive compounds and the probiotic to modulate the profibrotic signaling induced by both the TGF- β canonical and noncanonical pathways.

These results show that the oral administration of a diet enriched in fermented olive cream and *Lpb. plantarum* IMC513 exerted a beneficial role toward the prevention and development of chronic inflammation, but only when they had been concomitantly administered (Fig. 8). These results can be explained in part by the fact that the olive cream used in this study preserved most of the compounds present in the olive and a retained high concentration of their hydrolyzed hydrophilic derivatives, which are partially lost during the separation of extra virgin olive oil.

Some olive cream components may be the preferred fermentation substrates for *Lpb. Plantarum* strains, leading to the production of beneficial metabolites for the gut mucosa, such as short chain fatty acids [90]. Of the short chain fatty acids, butyrate represents the main energy substrate of colonocytes and is an important factor in the regulation of the local intestinal immune response [91]. Furthermore, the reduced production of butyrate is also involved in colorectal carcinogenesis [92]. *Lpb. plantarum* strains interacting with specific components of olive cream may acquire protective properties for the intestinal mucosa. This study's data represent a good starting point to improve understanding of the relationship

between diet habits and intestinal flora composition in order to identify new approaches for the prevention and/or treatment of chronic intestinal inflammation such as IBD and its related intestinal fibrosis and cancer. Although the exact etiology of IBD is still unknown, diet is one of the major environmental factors involved in its pathogenesis [93–95] as well in the pathogenesis of other intestinal disorders such as microscopic colitis and irritable bowel syndrome [96,97]. Some components of the diet act, on one hand, by modifying the diversity of the microbiota gut, and on the other, by acting directly on the metabolism of the intestinal mucosa, with both processes being responsible for maintaining the intestinal barrier function. The synergistic action of the phenols of olive cream with *Lpb. plantarum* could act in the maintenance or even in the strengthening of the mucosal barrier functions and therefore could have benefits not only for IBD and irritable bowel syndrome but also for microscopic colitis. Furthermore, the antifibrotic action on the intestine shown by the association of the olive phenols with *Lpb. plantarum* could play a favorable role in preventing or slowing down the fibrogenesis process that occurs in IBD. Potentially, the phenols of the olive cream could be used in IBD, microscopic colitis, and irritable bowel syndrome directly as a dietary supplement or as a food fortification with these compounds.

Conclusions

This study's preliminary results prompted us to hypothesize that olive cream with its potential prebiotic effects and the *Lpb. plantarum* IMC513 strain could restore the gut-microbiome ecosystem. It is widely accepted that in general, both prebiotics and probiotics may improve the gut dysbiosis in chronic colitis [94–96]. Further studies are needed to define the cellular and molecular mechanisms that are modulated by olive cream compounds and by *Lpb. plantarum* IMC513.

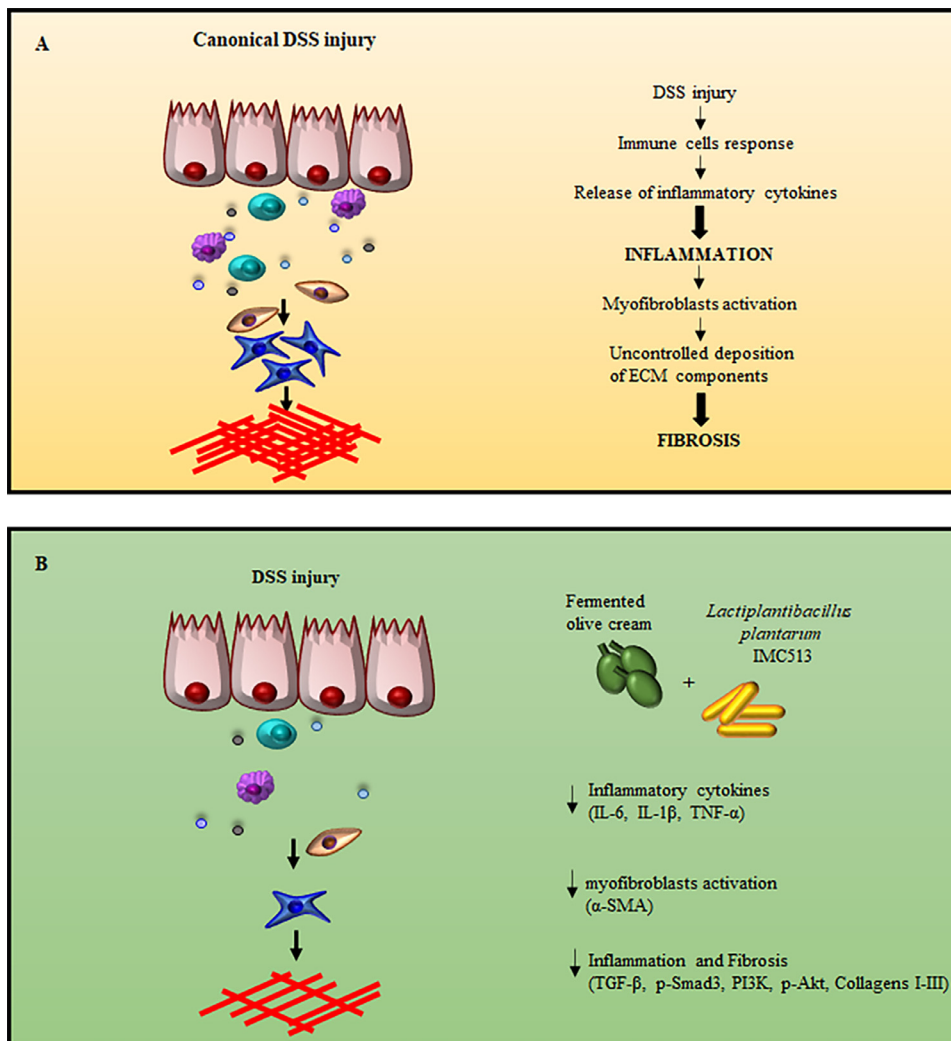


Fig. 8. The effect of a diet enriched with fermented olive cream enriched and probiotic administration on DSS-induced colitis. (A) After a DSS injury, inflammatory cytokines are released. A persistent inflammation status leads to myofibroblast activation and consequently to an abnormal deposition of extracellular matrix proteins. These events result in the onset of a fibrotic process. (B) The simultaneous consumption of a diet enriched with fermented olive cream enriched and *Lactiplantibacillus plantarum* IMC513 was able to reduce intestinal inflammation (by reducing IL-6, IL-1 β , TNF- α , and PI3K signaling) and the development of fibrosis (by decreasing the expression of TGF- β , p-SMAD3, PI3K, p-Akt, α -SMA, and collagens I–III). α -SMA, alpha smooth muscle actin; DSS, dextran sodium sulfates; IL, interleukin; p-Akt, phosphorylated protein kinase; PI3K, phosphatidylinositol 3-kinase; SMAD, small mothers against decapentaplegic protein; TGF, transforming growth factor; TNF, tumor necrosis factor.

Acknowledgments

The authors gratefully acknowledge Synbiotec S.r.l. (Camerino, Italy), which kindly provided us with *Lpb. plantarum* IMC513.

References

- [1] Rieder F, Brenmoehl J, Leeb S, Schölmerich J, Rogler G. Wound healing and fibrosis in intestinal disease. *Gut* 2007;56:130–9.
- [2] Fiocchi C, Lund PK. Themes in fibrosis and gastrointestinal inflammation. *Am J Physiol Gastrointest Liver Physiol* 2011;300:677–83.
- [3] Wynn TA, Ramalingam TR. Mechanisms of fibrosis: therapeutic translation for fibrotic disease. *Nat Med* 2012;18:1028–40.
- [4] Specia S, Giusti I, Rieder F, Latella G. Cellular and molecular mechanisms of intestinal fibrosis. *World J Gastroenterol* 2012;18:3635–61.
- [5] Vetuschy A, Latella G, Pompili S, Gaudio E, Sferra R. Features of intestinal lesions in the clinical course of inflammatory bowel diseases. *Ital J Anat Embryol* 2014;119:286–303.
- [6] Latella G, Di Gregorio J, Flati V, Rieder F, Lawrance IC. Mechanisms of initiation and progression of intestinal fibrosis in IBD. *Scand J Gastroenterol* 2015;50:53–65.
- [7] Samarakoon R, Overstreet JM, Higgins PJ. TGF- β signaling in tissue fibrosis: redox controls, target genes and therapeutic opportunities. *Cell Signal* 2013;25:264–8.
- [8] Liu RM, Desai LP. Reciprocal regulation of TGF- β and reactive oxygen species: a perverse cycle for fibrosis. *Redox Biol* 2015;6:565–77.
- [9] Di Gregorio J, Sferra R, Specia S, Vetuschy A, Dubuquoy C, Desreumaux P, et al. Role of glycogen synthase kinase-3 β and PPAR- γ on epithelial-to-mesenchymal transition in DSS-induced colorectal fibrosis. *PLoS One* 2017;12:e0171093.
- [10] Sferra R, Pompili S, Ventura L, Dubuquoy C, Specia S, Gaudio E, et al. Interaction between sphingosine kinase/sphingosine 1 phosphate and transforming growth factor- β /Smads pathways in experimental intestinal fibrosis: an in vivo immunohistochemical study. *Eur J Histochem* 2018;62:2956.
- [11] Vetuschy A, Pompili S, Gallone A, D'Alfonso A, Carbone MG, Carta G, et al. Immunolocalization of advanced glycation end products, mitogen activated protein kinases, and transforming growth factor- β /Smads in pelvic organ prolapse. *J Histochem Cytochem* 2018;66:673–86.
- [12] Pompili S, Sferra R, Gaudio E, Viscido A, Frieri G, Vetuschy A, Latella G. Can Nrf2 modulate the development of intestinal fibrosis and cancer in inflammatory bowel disease? *Int J Mol Sci* 2019;20:4061.
- [13] Vetuschy A, Pompili S, Di Marco GP, Calvaruso F, Iacomino E, Angelosante L, et al. Can the AGE/RAGE/ERK signalling pathway and the epithelial-to-mesenchymal transition interact in the pathogenesis of chronic rhinosinusitis with nasal polyps? *Eur J Histochem* 2020;64:3079.

- [14] Latella G, Vetuschy A, Sferra R, Specia S, Gaudio E. Localization of $\alpha\text{v}\beta 6$ integrin-TGF- $\beta 1$ /Smad3, mTOR and PPAR γ in experimental colorectal fibrosis. *Eur J Histochem* 2013;57:e40.
- [15] Specia S, Rousseaux C, Dubuquoy C, Rieder F, Vetuschy A, Sferra R, et al. Novel PPAR- γ modulator GED050734levo ameliorates inflammation-driven intestinal fibrosis. *Inflamm Bowel Dis* 2016;22:279–92.
- [16] Dubois-Camacho K, Ottum PA, Franco-Muñoz D, De la Fuente M, Torres-Riquelme A, Díaz-Jiménez D, et al. Glucocorticosteroid therapy in inflammatory bowel diseases: from clinical practice to molecular biology. *World J Gastroenterol* 2017;23(36):6628–38.
- [17] Detrez I, Thomas D, Van Steen K, Ballet V, Peeters M, Hoylaerts MF, et al. Successful infliximab treatment is associated with reversal of clotting abnormalities in inflammatory bowel disease patients. *J Clin Gastroenterol* 2020;54:819–25.
- [18] Khan MF, Kader FB, Arman M, Ahmed S, Lyzu C, Sakib SA, et al. Pharmacological insights and prediction of lead bioactive isolates of Dita bark through experimental and computer-aided mechanism. *Biomed Pharmacother* 2020;131:110774.
- [19] Vieira G, Cavalli J, Gonçalves ECD, Braga SFP, Ferreira RS, Santos ARS, et al. Antidepressant-like effect of terpineol in an inflammatory model of depression: involvement of the cannabinoid system and D2 dopamine receptor. *Biomolecules* 2020;10:792.
- [20] Martínez V, Iriondo De-Hond A, Borrelli F, Capasso R, Del Castillo MD, Abalo R. Cannabidiol and other non-psychoactive cannabinoids for prevention and treatment of gastrointestinal disorders: useful nutraceuticals? *Int J Mol Sci* 2020;21:3067.
- [21] Ağaçıntüz D, Çelik MN, Çıtar Dazıroğlu ME, Capasso R. Emergent drug and nutrition interactions in COVID-19: a comprehensive narrative review. *Nutrients* 2021;13:1550.
- [22] Freitas MA, Vasconcelos A, Gonçalves ECD, Ferrarini EG, Vieira GB, Cicia D, et al. Involvement of opioid system and TRPM8/TRPA1 channels in the antinociceptive effect of *Spirulina platensis*. *Biomolecules* 2021;11:592.
- [23] Islam N, Khan MF, Khatun MR, Nur S, Hanif NB, Kulsom U, et al. Neuropharmacological insights of African oil palm leaf through experimental assessment in rodent behavioral model and computer-aided mechanism. *Food Bioscience* 2021;40:100881.
- [24] Kaulmann A, Bohn T. Bioactivity of polyphenols: preventive and adjuvant strategies toward reducing inflammatory bowel diseases-promises, perspectives, and pitfalls. *Oxidative Medicine and Cellular Longevity* 2016. Article ID:9346470.
- [25] Mazieiro R, Frizon RR, Barbalho SM, de Alvares, Goulart R. Is curcumin a possibility to treat inflammatory bowel diseases? *J Med Food* 2018;21:1077–85.
- [26] Reddavid R, Rotolo O, Caruso MG, Stasi E, Notarnicola M, Miraglia C, et al. The role of diet in the prevention and treatment of inflammatory bowel diseases. *Acta Biomed* 2018;89:60–75.
- [27] da Silva-Maia JK, Batista AG, Cazarin CBB, Soares ES, Bogusz Junior S, Leal RF, et al. Aqueous extract of Brazilian berry (*Myrciaria jaboticaba*) peel improves inflammatory parameters and modulates *Lactobacillus* and *Bifidobacterium* in rats with induced-colitis. *Nutrients* 2019;11:2776.
- [28] Sugihara K, Morhardt TL, Kamada N. The role of dietary nutrients in inflammatory bowel disease. *Front Immunol* 2019;9:3183.
- [29] Karakan T, Ozkul C, Kùpeli Akkol E, Bilici S, Sobarzo-Sánchez E, Capasso R. Gut-brain-microbiota axis: antibiotics and functional gastrointestinal disorders. *Nutrients* 2021;13:389.
- [30] Serra G, Incani A, Serrelli G, Porru L, Melis MP, Tuberoso CIG, et al. Olive oil polyphenols reduce oxysterols-induced redox imbalance and proinflammatory response in intestinal cells. *Eur J Nutr* 2012;51:497–506.
- [31] Larussa T, Imeneo M, Luzzo F. Olive tree biophenols in inflammatory bowel disease: when bitter is better. *Int J Mol Sci* 2019;20:1390.
- [32] Taticchi A, Urbani S, Albi E, Servili M, Codini M, Traina G, et al. In vitro anti-inflammatory effects of phenolic compounds from Moraiolo virgin olive oil (MVOO) in brain cells via regulating the TLR4/NLRP3 axis. *Molecules* 2019;24:4523.
- [33] Sanchez-Fidalgo S, de Iburguen LS, Cárdeno A, de la Lastra CA. Influence of extra virgin olive oil diet enriched with hydroxytyrosol in a chronic DSS colitis model. *Eur J Nutr* 2012;51:497–506.
- [34] Sanchez-Fidalgo S, Cárdeno A, Sánchez-Hidalgo M, Aparicio-Soto M, de la Lastra CA. Dietary extra virgin olive oil polyphenols supplementation modulates DSS-induced chronic colitis in mice. *J Nutr Biochem* 2013;24:1401–13.
- [35] Takashima T, Sakata Y, Iwakiri R, Shiraishi R, Oda Y, Inoue N, et al. Feeding with olive oil attenuates inflammation in dextran sulfate sodium-induced colitis in rat. *J Nutr Biochem* 2014;25:186–92.
- [36] Sanchez-Fidalgo S, Villegas I, Aparicio-Soto M, Cárdeno A, Rosillo MA, González-Benjumea A, et al. Effects of dietary virgin olive oil polyphenols: hydroxytyrosyl acetate and 3, 4-dihydroxyphenylglycol on DSS-induced acute colitis in mice. *J Nutr Biochem* 2015;26:513–20.
- [37] Li Z, Summanen PH, Komoriya T, Henning SM, Lee RP, Carlson E, et al. Pomegranate ellagitannins stimulate growth of gut bacteria in vitro: implications for prebiotic and metabolic effects. *Anaerobe* 2015;34:164–8.
- [38] Ritchie LE, Sturino JM, Carroll RJ, Rooney LW, Azcarate-Peril MA, Turner ND. Polyphenol-rich sorghum brans alter colon microbiota and impact species diversity and species richness after multiple bouts of dextran sodium sulfate-induced colitis. *FEMS Microbiology Ecology* 2015;91:3.
- [39] Bernardo D, Sánchez B, HO Al-Hassi, Mann ER, Urdaci MC, Knight SC, et al. Microbiota/host crosstalk biomarkers: regulatory response of human intestinal dendritic cells exposed to *Lactobacillus* extracellular encrypted peptide. *PLoS One* 2012;7:e36262.
- [40] Nemoto M, Kuda T, Eda M, Yamakawa H, Takahashi H, Kimura B. Protective effects of Mekabu aqueous solution fermented by *Lactobacillus plantarum* Sanriku-SU7 on human enterocyte-like HT-29-luc cells and DSS-induced murine IBD model. *Probiotics Antimicrob Proteins* 2017;9:48–55.
- [41] Bonavina L, Arini A, Ficano L, Iannuzziello D, Pasquale L, Aragosa SE, et al. On digestive disorders ISG. Abincol® (*Lactobacillus plantarum* LP01, *Lactobacillus lactis* subspecies cremoris LLC02, *Lactobacillus delbrueckii* LDD01), an oral nutraceutical, pragmatic use in patients with chronic intestinal disorders. *Acta Biomed* 2019;90(7-S):8–12.
- [42] Hasannejad-Bibalan M, Mojtahedi A, Eshaghi M, Rohani M, Pourshafie MR, Talebi M. The effect of selected *Lactobacillus* strains on dextran sulfate sodium-induced mouse colitis model. *Acta Microbiol Immunol Hung* 2020;67:138–42.
- [43] Kim DH, Kim S, Ahn JB, Kim JH, Ma HW, Seo DH, et al. *Lactobacillus plantarum* CBT LP3 ameliorates colitis via modulating T cells in mice. *Int J Med Microbiol* 2020;310:151391.
- [44] Kim H, Venanci VP, Fang C, Dupont AW, Talcott ST, SU Mertens-Talcott. Mango (*Mangifera indica* L.) polyphenols reduce IL-8, GRO, and GM-SCF plasma levels and increase *Lactobacillus* species in a pilot study in patients with inflammatory bowel disease. *Nutr Res* 2020;75:85–94.
- [45] Clarke G, Cryan FG, Dinan TG, Quigley EM. Probiotics for the treatment of irritable bowel syndrome—focus on lactic acid bacteria. *Aliment Pharmacol Ther* 2012;35:403–13.
- [46] Zaylaa M, Al Kassar I, Alard J, Peucelle V, Boutillier D, Desramaut J, et al. Probiotics in IBD: combining in vitro and in vivo models for selecting strains with both anti-inflammatory potential as well as a capacity to restore the gut epithelial barrier. *J Funct Foods* 2018;47:304–15.
- [47] Veneziani G, Novelli E, Esposito S, Taticchi A, Servili M. Applications of recovered bioactive compounds in food products. In: Galanakis CM, editor. *Olive mill waste: recent advances for sustainable management*, London: Academic Press; 2017. p. 231–53.
- [48] Tufariello M, Durante M, Veneziani G, Taticchi A, Servili M, Blevé G, et al. Pate olive cake: possible exploitation of a by-product for food applications. *Front Nutr* 2019;6:3.
- [49] Prete R, Tofalo R, Federici E, Ciarrocchi A, Cenci G, Corsetti A. Food-associated *Lactobacillus plantarum* and yeasts inhibit the genotoxic effect of 4-nitroquinoline-1-oxide. *Front Microbiol* 2017;8:2349.
- [50] Garcia-Gonzalez N, Prete R, Battista N, Corsetti A. Adhesion properties of food-associated *Lactobacillus plantarum* strains on human intestinal epithelial cells and modulation of IL-8 release. *Front Microbiol* 2018;9:2392.
- [51] Prete R, Long SL, Joyce SA, Corsetti A. Genotypic and phenotypic characterization of food-associated *Lactobacillus plantarum* isolates for potential probiotic activities. *FEMS Microbiology Letters* 2020;367:fnaa076.
- [52] Prete R, Long SL, Lopez Gallardo A, Gahan CG, Corsetti A, Joyce SA. Beneficial bile acid metabolism from *Lactobacillus plantarum* of food origin. *Scientific Reports* 2020;10:1165.
- [53] Prete R, Garcia-Gonzalez N, CD Di Mattia, Corsetti A, Food-borne Battista N. *Lactiplantibacillus plantarum* protect normal intestinal cells against inflammation by modulating reactive oxygen species and IL-23/IL-17 axis. *Scientific Reports* 2020;10:16340.
- [54] Xia Y, Chen HQ, Zhang M, Jiang YQ, Hang XM, Qin HL. Effect of *Lactobacillus plantarum* LP-Only on gut flora and colitis in interleukin-10 knockout mice. *J Gastroenterol Hepatol* 2011;26:405–11.
- [55] Chen H, Xia Y, Zhu S, Yang J, Yao J, Di J, et al. *Lactobacillus plantarum* LP-Only alters the gut flora and attenuates colitis by inducing microbiome alteration in interleukin-10 knockout mice. *Mol Med Rep* 2017;16(5):5979–85.
- [56] Latella G, Vetuschy A, Sferra R, Zanninelli G, D'Angelo A, Catitti V, et al. Smad3 loss confers resistance to the development of trinitrobenzene sulfonic acid-induced colorectal fibrosis. *Eur J Clin Invest* 2009;39:145–56.
- [57] Abramoff MD, Magalhaes PJ, Ram SJ. Image processing with. *ImageJ*. *Biophotonics International* 2004;11:36–42.
- [58] Appleyard CB, Hernández G, Rios-Bedoya CF. Basic epidemiology of inflammatory bowel disease in Puerto Rico. *Inflamm Bowel Dis* 2004;10:106–11.
- [59] Amre DK, D'Souza S, Morgan K, Seidman G, Lambrette P, Grimard G, et al. Imbalances in dietary consumption of fatty acids, vegetables, and fruits are associated with risk for Crohn's disease in children. *Am J Gastroenterol* 2007;102:2016–25.
- [60] Yang SK, Yun S, Kim JH, Park JY, Kim HY, Kim YH, et al. Epidemiology of inflammatory bowel disease in the Songpa-Kangdong district, Seoul, Korea, 1986–2005: a KASID study. *Inflamm Bowel Dis* 2008;14:542–9.
- [61] Hou JK, Abraham B, El-Serag H. Dietary intake and risk of developing inflammatory bowel disease: a systematic review of the literature. *Am J Gastroenterol* 2011;106:563–73.
- [62] Rockey DC, Bell PD, Hill JA. Fibrosis—a common pathway to organ injury and failure. *N Engl J Med* 2015;373:96.
- [63] Shin W, Kim HJ. Intestinal barrier dysfunction orchestrates the onset of inflammatory host—microbiome cross-talk in a human gut inflammation-on-a-chip. *PNAS* 2018;115:E10539–47.

- [64] Munyaka PM, Rabbi MF, Khafipour E, Ghia JE. Acute dextran sulphate sodium (DSS)-induced colitis promotes gut microbial dysbiosis in mice. *J Basic Microbiol* 2016;56:986–98.
- [65] Tessitore A, Mastroiaco V, Vetuschi A, Sferra R, Pompili S, Ciciarelli G, et al. Development of hepatocellular cancer induced by long term low fat-high carbohydrate diet in a NAFLD/NASH mouse model. *Oncotarget* 2017;8:53482–94.
- [66] Pompili S, Vetuschi A, Gaudio E, Tessitore A, Capelli R, Alesse E, et al. Long-term abuse of a high-carbohydrate diet is as harmful as a high-fat diet for development and progression of liver injury in a mouse model of NAFLD/NASH. *Nutrition* 2020;110782.
- [67] Brown K, DeCoffe D, Molcan E, Gibson DL. Diet-induced dysbiosis of the intestinal microbiota and the effects on immunity and disease. *Nutrients* 2012;4:1095–119.
- [68] Kelder T, Stroeve JH, Bijlsma S, Radonjic M, Roeselers G. Correlation network analysis reveals relationships between diet-induced changes in human gut microbiota and metabolic health. *Nutr Diabetes* 2014;4:122.
- [69] Deiana M, Serra G, Corona G. Modulation of intestinal epithelium homeostasis by extra virgin olive oil phenolic compounds. *Food Funct* 2018;9:4085.
- [70] Huang Z, Rose AH, Hoffmann PR. The role of selenium in inflammation and immunity: from molecular mechanisms to therapeutic opportunities. *Antioxid. Redox Signal* 2012;16:705–43.
- [71] Eeckhaut V, Ducatelle R, Sas B, Vermeire S, Van Immerseel F. Progress towards butyrate-producing probiotics: *Butyricoccus pullicaecorum* capsule and efficacy in TNBS models in comparison with therapeutics. *Gut* 2014;63:367.
- [72] Perpetuini G, Prete R, Garcia-Gonzalez N, Khairul AM, Corsetti A. Table olives more than a fermented food. *Foods* 2020;9:178.
- [73] Ciriminna R, Meneguzzo F, Fidalgo A, Ilharco LM, Pagliaro M. Extraction, benefits and valorization of olive polyphenols. *Eur J Lipid Sci Tech* 2016;117:503–11.
- [74] Ahmad Farooqi A, Fayyaz S, Silva AS, Sureda A, Nabavi SF, Mocan A, et al. Oleuropein and cancer chemoprevention: the link is hot. *Molecules* 2017;22:705.
- [75] Di Nunzio M, Picone G, Pasini F, Chiarello E, Caboni MF, Capozzi F, et al. Olive oil by-product as functional ingredient in bakery products: influence of processing and evaluation of biological effects. *Food Res Int* 2020;131:108940.
- [76] Madsen KL, Doyle JS, Jewell LD, Taverini MM, Fedorak RN. *Lactobacillus* species prevents colitis in interleukin-10 gene-deficient mice. *Gastroenterol* 1999;116:1107–14.
- [77] O'Mahony L, Feeney M, O'Halloran S, Murphy L, Kiely B, Fitzgibbon J, et al. Probiotic impact on microbial flora, inflammation and tumour development in IL10 knockout mice. *Aliment Pharmacol Ther* 2001;15:1219–25.
- [78] Schultz M, Veltkamp C, Dieleman LA, Grenther WB, Wyrick PB, Tonkonogy SL, et al. *Lactobacillus plantarum* 299v in the treatment and prevention of spontaneous colitis in interleukin-10 deficient mice. *Inflamm Bowel Dis* 2002;8:71–80.
- [79] Jonkers D, Stockbrügger R. Probiotics and inflammatory bowel disease. *J R Soc Med* 2003;96:167–71.
- [80] Ahn YS, Park MY, Shin JH, Kim JY, Kwon O. Lysate of probiotic *Lactobacillus plantarum* K8 modulate the mucosal inflammatory system in dextran sulfate sodium-induced colitic rats. *Korean J Food Sci Anim Resour* 2014;34:829–35.
- [81] Zhao J, Tian F, Yan S, Zhai Q, Zhang H, Chen W. *Lactobacillus plantarum* CCFM10 alleviating oxidative stress and restoring the gut microbiota in d-galactose induced aging mice. *Food Funct* 2018;9:917–24.
- [82] Tanaka A, Kanmura S, Morinaga Y, Kawabata K, Arima S, Sasaki F, et al. Oral administration of *Lactobacillus plantarum* 06CC2 prevents experimental colitis in mice via an anti-inflammatory response. *Mol Med Rep* 2020;21:1181–91.
- [83] Zhang F, Li Y, Wang X, Wang S, Bi D. The impact of *Lactobacillus plantarum* on the gut microbiota of mice with DSS-induced colitis. *Biomed Res Int* 2019;3921315.
- [84] Niedzielin K, Kordecki H, Birkenfeld B. A controlled, double-blind, randomized study on the efficacy of *Lactobacillus plantarum* 299V in patients with irritable bowel syndrome. *Eur J Gastroenterol Hepatol* 2001;13:1143–7.
- [85] Fedorak RN, Feagan BG, Hotte N, Leddin D, Dieleman LA, Petrunia DM, et al. The probiotic VSL#3 has anti-inflammatory effects and could reduce endoscopic recurrence after surgery for Crohn's disease. *Clin Gastroenterol Hepatol* 2015;13:928–35. e922.
- [86] Barraza-Ortiz DA, Pérez-López N, Medina-López VM, Minero-Alfaro JI, Zamarripa-Dorsey F, Fernández-Martínez NDC, et al. Combination of a probiotic and an antispasmodic increases quality of life and reduces symptoms in patients with irritable bowel syndrome: a pilot study. *Dig Dis* 2020. <https://doi.org/10.1159/000510950>.
- [87] Le B, Yang SH. Efficacy of *Lactobacillus plantarum* in prevention of inflammatory bowel disease. *Toxicol Rep* 2018;5:314–7.
- [88] Liu YW, Su YW, Ong WK, Cheng TH, Tsai YC. Oral administration of *Lactobacillus plantarum* K68 ameliorates DSS-induced ulcerative colitis in BALB/c mice via the anti-inflammatory and immunomodulatory activities. *Int Immunopharmacol* 2011;11:2159–66.
- [89] Liu YW, Ong WK, Su YW, Hsu CC, Cheng TH, Tsai YC. Anti-inflammatory effects of *Lactobacillus brevis* K65 on RAW 264.7 cells and in mice with dextran sulphate sodium-induced ulcerative colitis. *Benef Microbes* 2016;7:387–96.
- [90] Markowiak-Kopeć P, Śliżewska K. The effect of probiotics on the production of short-chain fatty acids by human intestinal microbiome. *Nutrients* 2020;12:1107.
- [91] Latella G, Caprilli R. Metabolism of large bowel mucosa in health and disease. *Int J Colorectal Dis* 1991;6:127–32.
- [92] Vernia F, Longo S, Stefanelli G, Viscidi A, Latella G. Dietary factors modulating colorectal carcinogenesis. *Nutrients* 2021;13:143.
- [93] Glassner KL, Abraham BP, Quigley EMM. The microbiome and inflammatory bowel disease. *J Allergy Clin Immunol* 2020;145:16–27.
- [94] Oka A, Sartor RB. Microbial-based and microbial-targeted therapies for inflammatory bowel diseases. *Dig Dis Sci* 2020;65:757–88.
- [95] Mishima Y, Sartor RB. Manipulating resident microbiota to enhance regulatory immune function to treat inflammatory bowel diseases. *J Gastroenterol* 2020;55:4–14.
- [96] Zabana Y, Tontini G, Hultgren-Hörnquist E, Skonieczna-Żydecka K, Latella G, Østvik AE, et al. Pathogenesis of microscopic colitis: a systematic review. *J Crohns Colitis* 2021;Jul 17:jjab123.
- [97] El-Salhy M, Hatlebakk JG, Hausken T. Diet in irritable bowel syndrome (IBS): interaction with gut microbiota and gut hormones. *Nutrients* 2019;11:1824.