

RESEARCH

Open Access



Efficacy of Bravecto[®] Plus spot-on solution for cats (280 mg/ml fluralaner and 14 mg/ml moxidectin) for the prevention of aelurostrongylosis in experimentally infected cats

Katharina Raue¹, Nadja Rohdich², Daniela Hauck¹, Eva Zschiesche², Simone Morelli³, Donato Traversa³, Angela Di Cesare³, Rainer K. A. Roepke² and Christina Strube^{1*}

Abstract

Background: The feline lungworm *Aelurostrongylus abstrusus* affects the lower respiratory tract in cats worldwide. As infections may lead to chronic respiratory changes or even death, preventive treatment in cats with outdoor access is warranted.

Methods: The preventive efficacy of a spot-on solution (Bravecto[®] Plus spot-on solution for cats, MSD) against cat aelurostrongylosis was evaluated using three different preventive treatment regimes in a negative controlled, randomized and partially blinded laboratory efficacy study with 31 purpose-bred cats. The minimum recommended dose of 2.0 mg moxidectin + 40 mg fluralaner/kg bodyweight was applied once 12 (Group [G]1), 8 (G2) or 4 (G3) weeks before experimental infection with 300 third-stage larvae (L3) of *A. abstrusus*. Another group served as untreated control (G4). Individual faecal samples were analysed as of day 30 post infection (pi) to monitor larvae excretion. Necropsy was performed at days 47–50 pi. The lungs were examined macroscopically for pathological findings and (pre-)adult worms were counted to assess preventive efficacy.

Results: Beginning at day 32–40 pi, all cats of the control group were constantly shedding larvae of *A. abstrusus*, whereas only one animal of G1 excreted larvae at several consecutive days. In addition, two cats of G1 and G3 and three of G2 were positive on a single occasion. The geometric mean (GM) of the maximum number of excreted larvae was 7574.29 in the control group compared to 1.10 (G1), 1.19 (G2) and 0.53 (G3), resulting in a GM reduction of > 99.9% in all treatment groups. All lungs of the control animals showed severe or very severe alterations at necropsy, while in 94.44% of the treated cats lung pathology was rated as absent or mild. The GM number of (pre-)adult *A. abstrusus* retrieved from the lungs was 26.57 in the control group, 0.09 in G1 and 0.00 in G2 and G3. Thus, GM worm count reduction was 99.66% in G1 and 100% in G2 and G3.

Conclusions: A single application of Bravecto[®] Plus spot-on solution at a dose of 2.0 mg moxidectin + 40 mg fluralaner/kg bodyweight reliably prevents cat aelurostrongylosis for at least 12 weeks.

Keywords: *Aelurostrongylus abstrusus*, Feline lungworms, Macrocytic lactones, Moxidectin, Treatment, Prevention, Control

*Correspondence: christina.strube@tiho-hannover.de

¹ Institute for Parasitology, Centre for Infection Medicine, University of Veterinary Medicine Hannover, Hanover, Germany
Full list of author information is available at the end of the article



© The Author(s) 2021. This article is licensed under a Creative Commons Attribution 4.0 International License, which permits use, sharing, adaptation, distribution and reproduction in any medium or format, as long as you give appropriate credit to the original author(s) and the source, provide a link to the Creative Commons licence, and indicate if changes were made. The images or other third party material in this article are included in the article's Creative Commons licence, unless indicated otherwise in a credit line to the material. If material is not included in the article's Creative Commons licence and your intended use is not permitted by statutory regulation or exceeds the permitted use, you will need to obtain permission directly from the copyright holder. To view a copy of this licence, visit <http://creativecommons.org/licenses/by/4.0/>. The Creative Commons Public Domain Dedication waiver (<http://creativecommons.org/publicdomain/zero/1.0/>) applies to the data made available in this article, unless otherwise stated in a credit line to the data.

Background

The cat lungworm *Aelurostrongylus abstrusus* Railliet, 1898 (Nematoda, Metastrongyloidea) causes mild to severe respiratory disease in cats with clinical signs such as coughing, sneezing, nasal discharge, panting, respiratory sounds and dyspnoea [1–3] and occasionally leads to death [4]. However, patent infections may be also detected during routine faecal examination in sub-clinically infected cats [2, 5, 6]. The heteroxenous life-cycle relies on gastropods as intermediate hosts, and different prey species play a role in transmission as paratenic hosts [7, 8]. Most reports on *A. abstrusus* prevalence in cats originate from Europe, ranging between 0.1 and 10.7% in northern and central Europe [9–16] and between 8.0 and 27.3% in eastern and southern Europe [5, 17–20], but studies were also conducted in Asia (e.g. Qatar 7.5% [21]), the Americas (e.g. Argentina 2.6% [22], Midwest USA 1.2%, Northeast USA 2.7% [23]) and Australia (e.g. Christmas Island 25.0% [24]). A supposed risk factor for *A. abstrusus* infection is young age [5, 13, 19, 23, 25], potentially due to an immature immune system [23, 26]. Other factors that have been linked to a higher prevalence are neutering status [5, 13], FIV infection [25] and outdoor access [5, 10, 13].

Due to non-specific signs in combination with methodological limitations, the clinical diagnosis of aelurostrongylosis is challenging. Detection of first-stage larvae (L1) by copromicroscopy, e.g. via the Baermann migration method, may be hampered by irregular larval shedding [1] and presumably low survival rates of excreted larvae in faeces mixed with cat litter [27]. In addition, the collection of faecal samples may be difficult, especially in cats with outdoor access, which are particularly at risk of acquiring *A. abstrusus* [5, 10, 13]. An ELISA for the detection of serum antibodies against *A. abstrusus* using recombinantly expressed bovine lungworm major sperm protein (MSP) as diagnostic antigen [28] has been recently developed [26]. However, this serological test is being used only in experimental and epizootiological studies so far [13, 18, 20, 25].

Currently, products licensed in Europe for the treatment of cat aelurostrongylosis contain fenbendazole (only in the UK), emodepside, moxidectin or eprinomectin. In addition, some data suggest the potential efficacy, in terms of resolution of clinical signs and termination of larval excretion, of selamectin and milbemycine oxime in single clinical cases reviewed in Refs. [29] and [30]. Effective parasite control should aim to preventing a patent infection and manifest disease. This is particularly true for *A. abstrusus* as lung damage occurs already during prepatency [31]. In this regard, an experimental study provided encouraging results, as eprinomectin was able

to prevent clinical aelurostrongylosis and larval shedding when applied as early as 4 days post infection [32] and led to the license of a spot-on formulation containing eprinomectin against fourth- (L4) and fifth- (L5) stage larvae of *A. abstrusus*. Likewise, a product containing moxidectin is licensed against third-stage larvae (L3) and L4 if applied at monthly intervals, since it has been demonstrated that two moxidectin treatments 4 weeks apart at different time points before and after experimental infection reliably eliminate larval stages of *A. abstrusus* and hence can prevent lung damage and a patent infection [33]. Indeed, the long-lasting property of moxidectin makes this molecule a promising candidate for the prevention of aelurostrongylosis even after a single treatment several weeks prior to infection. Thus, the aim of the present study was to evaluate the efficacy and safety of a combination of moxidectin and fluralaner in preventing clinical aelurostrongylosis and patent infections in cats experimentally challenged with *A. abstrusus* at different time points (i.e. 4, 8 or 12 weeks) after a single treatment.

Methods

Study design

To evaluate the preventive efficacy of a single dose of 2.0 mg moxidectin + 40 mg fluralaner/kg bodyweight (BW) as a spot-on solution against cat aelurostrongylosis, the substance (Bravecto® Plus spot-on solution for cats) was applied topically 4, 8 or 12 weeks prior to experimental inoculation with infective *A. abstrusus* L3 in a negative (placebo-)controlled, randomized and partially blinded laboratory study. The study was conducted in accordance with VICH guideline 9 “Good Clinical Practice” [34] and VICH guideline 7 “Efficacy of anthelmintics: General requirements” [35].

Study animals and group allocation

Thirty-one purpose-bred European Shorthair cats (16 females and 15 males) aged between 21–29 weeks with a mean bodyweight of 2.9 kg (2.2–4.2 kg) were purchased from a commercial breeder and acclimatized to the study site (Institute for Parasitology, University of Veterinary Medicine Hannover, Germany) for 7 days (study days [SD] -7 to -1) before inclusion in the study. For study inclusion, animals had to meet the following criteria: clinically healthy status, bodyweight ≥ 1.2 kg on SD 0, at least two faecal samples collected during the acclimatization period negative for the presence of nematode eggs or larvae (tested by a combined sedimentation-flotation technique with zinc sulphate as flotation solution [specific gravity 1.3] and the Baermann method) as well as no treatment with drugs that could interfere with the establishment of the experimental infection (e.g. long-acting

anthelmintics). To achieve a homogeneous distribution of sex and body weight in all study groups, all 31 cats were ranked, prior to SD -7, by descending bodyweight, stratified by sex and allocated to the study groups according to a pre-defined list (order of the 16 female cats: 4-3-2-1-4-2-1-4-3-2-2-4-2-1-4-3, order of the 15 male cats: 1-2-3-4-3-1-4-1-2-3-1-3-4-1-2). Detailed information on the individual study cats and composition of the study groups at SD 0 is given in Additional file 1: Table S1.

Animals were housed indoors in environmentally controlled rooms in pairs or groups of three cats in their respective study groups. At the day of treatment and the 2 following days, and the day of experimental infection and for collection of individual faecal samples, cats were separated by dividing the pen with acrylic glass but still allowing audio-visual and olfactory contact with their group mates. Pens were equipped with litter boxes and bowls for food and water and were environmentally enriched with shelves, scratch poles, toys and cardboard boxes. The animals received a standard commercial dry diet at recommended rates, and water was provided *ad libitum*.

Health monitoring

General health observations were performed at least once a day by qualified and trained animal caretakers. The animals were weighed and physically examined by a veterinarian on the day before the treatment, before experimental infection and additionally if any abnormality was reported by the animal caretakers. An in-depth clinical respiratory assessment was performed on all cats the day before the first treatment and before experimental infection, respectively, and following that twice weekly until necropsy. The respiratory frequency, intensity of inspiratory and expiratory sounds on a scale from 0 to 3 (0 = no sound; 1 = slight sound; 2 = moderate sound; 3 = severe sound), quality of the respiratory sound (physiological sound, deepened but physiological sound, stertor, stridor, rhonchus, wheeze, crackle) and abdominal involvement, panting and coughing or retching (yes or no) were recorded.

Treatment

Animals of groups (G) 1, 2 and 3 were dosed once with Bravecto® Plus spot-on solution at the minimum recommended dose on SD 0, SD 28 and SD 56, respectively. Animals of the control group (G4) were dosed with a placebo (0.9% saline solution) at the same study days (SD 0, SD 28 and SD 56). To maintain blinding, cats in G1 were treated with the placebo on SD 28 and SD 56, cats in G2 on SD 0 and 56 and cats in G3 on SD 0 and 28. An overview of the study design is given in Table 1.

Ten minutes and 24 h \pm 4 h after treatment (i.e. SD 1 \pm 4 h, SD 29 \pm 4 h and SD 57 \pm 4 h) and at the day of necropsy (SD 131 to 134), the administration site was checked for abnormalities. Additionally, 2 h \pm 15 min after treatment all cats were observed by a veterinarian for general health. On all other days post-treatment, the cats were observed at least once a day for general health by a qualified animal caretaker (cf. section on health monitoring above).

Experimental *Aelurostrongylus abstrusus* infection

Snail (*Cornu aspersum*) breeding, their infection with *A. abstrusus* L1 and snail maintenance until L3 development were conducted at the University of Teramo, Italy, as previously described [36]. All *C. aspersum* specimens originated from an established farm for heliciculture in Central Italy. The absence of natural infections of the snails with other metastrongylid nematodes was assessed morphologically and molecularly as previously described by examining 10% of the snails before starting their breeding [30, 36, 37]. Each snail was infected with 500 L1 of *A. abstrusus* obtained from faecal samples of a naturally infected cat. After infection, snails were kept at 26 °C and fed *ad libitum* with vegetables for at least 2 months to allow development of *A. abstrusus* L3 [36].

Digestion of the snails to obtain cat-infective L3 was performed at the day of infection (SD 84) based on an established protocol [38]. Briefly, the muscular foot of the snails was minced and transferred in freshly prepared digesting solution (6 g pepsin [\geq 2000 FIP-U/g, Carl Roth GmbH]) and 7 ml HCl 37% in 1 l water. The tissue of 10–15 snails each was added to 100–250 ml digesting solution and stirred in a water bath at 41 °C for 30 min. Then, the preparation was sieved and centrifuged at room temperature (600 g for 5 min). The supernatant was discarded, the sediment re-suspended in tap water and the centrifugation step repeated. The sediment was pooled, thoroughly shaken and placed on a magnetic stirrer. While stirring constantly, the L3 present in five aliquots of 0.1 ml suspension each were counted to determine the mean number of larvae in the respective volume. Afterwards, the volume of the inoculum containing approximately 300 L3 was calculated. Until inoculation of the cats, the larvae suspension was kept at 20–25 °C.

Each cat was inoculated orally with approximately 300 L3 of *A. abstrusus* on SD 84. For inoculation, the animals were anaesthetised by intramuscular injection of 80 μ g/kg medetomidine (Domitor®, Vetoquinol) and 7.5 mg/kg ketamine (Ketamin® 10%, bela-pharm) combined in one syringe. Additionally, 0.3 mg/kg metoclopramide (Metomotyl® 5 mg/ml, CP-Pharma) was injected intramuscularly to avoid regurgitation. After applying the inoculum via a syringe connected to a stomach tube

Table 1 Overview of the study design to evaluate the preventive efficacy of Bravecto® Plus spot-on solution at the minimum recommended dose (2.0 mg moxidectin/kg BW + 40 mg fluralaner/kg) compared to placebo treatment (0.9% saline solution)

Group	No. of cats	Treatment (study day)	Infection with 300 <i>Aelurostrongylus abstrusus</i> L3 (study day)	Necropsy (study day)
1	8	0 Bravecto® Plus spot-on solution	84	131–134
		28 Placebo		
		56 Placebo		
2	8	0 Placebo		
		28 Bravecto® Plus spot-on solution		
		56 Placebo		
3	7	0 Placebo		
		28 Placebo		
		56 Bravecto® Plus spot-on solution		
4	8	0 Placebo		
		28 Placebo		
		56 Placebo		

directly into the stomach, the tube was flushed with tap water and then pulled out. The animals were observed at 10 (\pm 2) min and 1 h (\pm 10 min) post inoculation if vomiting occurred. One cat in G2 (ID 7273) vomited approximately 1 ml fluid within this time frame and was re-inoculated with the complete dose (300 L3). Another 22 animals (7 in G1, 4 in G2, 4 in G3 and 7 in G4) vomited between 1 h after inoculation and the next morning but were not re-inoculated.

Faecal larvae counts after experimental *A. abstrusus* infection

Individual faecal samples were collected from each cat daily between SD 114 and SD 130, i.e. between 30 and 46 days post infection (dpi). Samples of 5 g faeces each were processed with the Baermann method the same day or, if collected at the weekend, stored at 3–9.5 °C and processed the following Monday. L1 were allowed to migrate overnight and larvae counts were performed the next morning.

Parasitological necropsy

On SD 131 to 134, i.e. 47 to 50 dpi, the animals were euthanized by intravenous application of pentobarbital (Euthadorm® 500 mg/ml, CP-Pharma) and necropsy was performed. Similar ratios of the study groups were euthanized and necropsied each day. After verification of death, the thorax was opened in the sternal region and the lungs were removed and examined macroscopically for any pathological findings. If present, these were rated from 0 = absent, 1 = mild, 2 = moderate, 3 = severe to 4 = very severe.

Afterwards, the trachea and bronchi were opened lengthwise with scissors and examined under a binocular loupe with 25 \times magnification for visible nematodes.

Subsequently, the lungs were cut into small pieces (maximum 0.5 \times 0.5 cm) and parasites were collected using dressing forceps and transferred into vessels containing 0.9% saline solution. Recovered nematodes were examined under a stereomicroscope with 40–100 \times magnification to determine viability, developmental stage and, if possible, sex. Dead worms were also classified as viable if they did not show signs of degradation. Worm fragments were counted only if the head or tail was present. The total *A. abstrusus* worm count per animal was calculated by summing the numbers of intact (pre-)adult worms and worm fragments (either heads or tails, whichever number was higher).

Statistical analysis and calculation of preventive efficacy

Statistical analysis was performed using the SAS® software package (version 9.4; SAS Institute Inc., Cary, NC, USA).

Primary preventive efficacy criterion was the geometric mean (GM) worm count in each treatment group compared to the control group. Necropsy worm counts were used to evaluate the percentage preventive efficacy in each treatment group using the following formula according to the recommendations for controlled tests described in VICH GL7 [35]:

$$\text{Efficacy reduction [\%]} = \frac{\bar{x}_C - \bar{x}_T}{\bar{x}_C} \times 100$$

where \bar{x}_C is the GM number of *A. abstrusus* worms in the control group (G4); \bar{x}_T is the GM number of *A. abstrusus* worms in each treatment group (G1–G3).

To allow the calculation in case of zero counts, the GM was calculated as follows:

$$x_g = \left(\prod_{i=1}^n (x_i + 1) \right)^{\frac{1}{n}} - 1$$

To confirm the anthelmintic efficacy results, necropsy worm counts were formally analysed using two-sided two sample *t*-tests for the pairwise comparison of each treatment group to the control group. The level of significance was set to $\alpha = 0.05$.

As secondary preventive efficacy criteria the following parameters were evaluated statistically: (i) The individual maximum larvae counts between SD 114 and SD 130 in the treatment groups (G1–G3) were compared to the control group (G4) using a two-sided two-sample *t*-test with the level of significance set to $\alpha = 0.05$. To evaluate the percentage preventive efficacy against faecal larvae excretion, GM and efficacy reduction of the maximum larvae counts in the study groups were calculated using the formula given above. (ii) The respiratory frequencies examined on the day prior to the first treatment (SD -1), the day prior to experimental infection (SD 83) and twice weekly between SD 85–128 were summarized and graphically displayed. Respiratory frequencies were also retrospectively compared pairwise between each treatment group (G1, G2 and G3) and the control group (G4) using *t*-tests with the level of significance set to $\alpha = 0.05$ (two-sided). (iii) The lung pathology scores at necropsy (scores 0 to 4) of the treated groups (G1–G3) were compared to the control group (G4) using Wilcoxon's rank sum test (two-sided) with the level of significance set to $\alpha = 0.05$.

Other noted respiratory parameters (intensity and quality of respiratory sound, panting, abdominal involvement and coughing or retching) were evaluated but not analysed statistically.

Results

Inclusion criteria and safety assessment

All 31 cats met the criteria to be included in the study. After application of Bravecto® Plus spot-on solution for cats, one animal in G1 (ID 9657) exhibited slight scaling/flaking at the administration site for 1 day, and another two animals in G2 (ID 3599 and 6242) showed signs of itching (increased scratching and licking) at the administration site 2 h post treatment, which however disappeared the next day. No adverse effects on general health were observed in any of the cats.

Faecal larvae counts

Beginning at 32–40 dpi, all cats of the control group (G4) excreted *A. abstrusus* L1 and remained constantly positive throughout the study. By contrast, only one animal of G1 excreted larvae at consecutive days, starting at 39 dpi

until 46 dpi, when the last faecal examination was performed. Additionally, two further cats of G1, three of G2 and two of G3 were copromicroscopically positive on a single occasion between 36–44 dpi. In positive cats, the maximum number of excreted larvae in 5 g faeces on a single day varied between 54 and 45,900 L1 in the control group (G4), 1 and 31 (G1), 1 and 25 (G2), and 1 and 9 (G3) L1 in the treatment groups. Detailed data on individual cats are provided in Table 2.

The GM of the maximum number of excreted larvae in 5 g faeces per day was 7574.29 (ranging from 54 to 45,900 L1) in the control group (G4) compared to 1.10 (G1), 1.19 (G2) and 0.53 (G3) in the treatment groups. The respective arithmetic mean (AM) was 22,019.25 in the control group (G4) and 4.63 (G1), 4.38 (G2) and 1.43 (G3) in the treatment groups. Based on GMs, the preventive efficacy of the treatment against *A. abstrusus* L1 excretion was 99.99% when applied 12 (G1) or 4 (G3) weeks and 99.98% when applied 8 (G2) weeks before experimental infection.

Respiratory assessment and lung pathology

The mean respiratory frequency in the control group (G4) was higher than in the treatment groups (G1–G3, Fig. 1) starting at SD 110 (26 dpi). However, there was no statistically significant difference between the groups. The intensity and quality of inspiratory and expiratory sounds showed no obvious difference between the study groups throughout the course of the study. Panting was observed in three cats at day 13 pi, thereof each one in G1 (ID 9657), G2 (ID 6242) and G4 (ID 1465). In one animal of the control group (G4, ID 1465) coughing during the respiratory examination at day 26 pi was noticed. None of the study cats showed abdominal involvement.

The lungs of all eight control cats (G4) showed severe or very severe macroscopic signs of a verminous pneumonia, e.g. atelectasis, subpleural nodules and/or emphysema at necropsy (Fig. 2). By contrast, in 94.44% of the treated cats lung pathology was considered absent or mild. In G1, four lungs were rated as mildly altered, while no alterations were observed in the other four lungs. In G2, two lungs showed mild and one moderate pathological changes, whereas in the five remaining lungs pathological alterations were absent. In G3, two lungs were rated as mildly altered; the other five lungs appeared inconspicuous (Fig. 3, individual cat data are listed in Table 2). The mean lung pathology score in the control group was significantly higher than those of the treatment groups ($P \leq 0.0002$).

Nematode counts

According to the applied guidelines [34, 35], the experimental *A. abstrusus* infection was considered adequate,

Table 2 Parasitological parameters, lung pathology and preventive drug efficacy against larvae excretion and (pre-)adult of *Aelurostrongylus abstrusus*

Group	Animal ID	First day of L1 excretion (dpi)	Max. L1 count/day in 5 g faeces	GM of max. L1 count/day	Efficacy (%)	Lung pathology score	(Pre-)adult worm count	GM of adult worms	Preventive efficacy (%)
1 (treated 12 weeks prior to infection)	0801	n.a.	0	1.10	99.99	1	0	0.09	99.66
	1054	39	5			0	0		
	2936	n.a.	0			1	0		
	3881	37	1			0	0		
	5300	n.a.	0			1	1		
	6615	n.a.	0			0	0		
	8860	39	31			1	0		
	9657	n.a.	0			0	0		
2 (treated 8 weeks prior to infection)	0370	n.a.	0	1.19	99.99	0	0	0.00	100
	3599	36	1			0	0		
	5820	n.a.	0			2	0		
	6242	37	25			1	0		
	6554	n.a.	0			0	0		
	7273	42	9			0	0		
	7707	n.a.	0			1	0		
	8219	n.a.	0			0	0		
3 (treated 4 weeks prior to infection)	0862	n.a.	0	0.53	99.98	0	0	0.00	100
	1160	n.a.	0			0	0		
	1291	n.a.	0			0	0		
	3550	41	1			1	0		
	6179	44	9			0	0		
	6676	n.a.	0			0	0		
	9914	n.a.	0			1	0		
4 (untreated control)	1151	33	45,900	7574.29	99.99	3	23	26.57	n.a.
	1465	36	7400			3	36		
	1509	40	54			4	10		
	1588	38	1200			3	15		
	6407	33	43,100			4	64		
	6646	33	45,300			3	56		
	9013	36	11,300			3	23		
	9335	32	21,900			3	23		

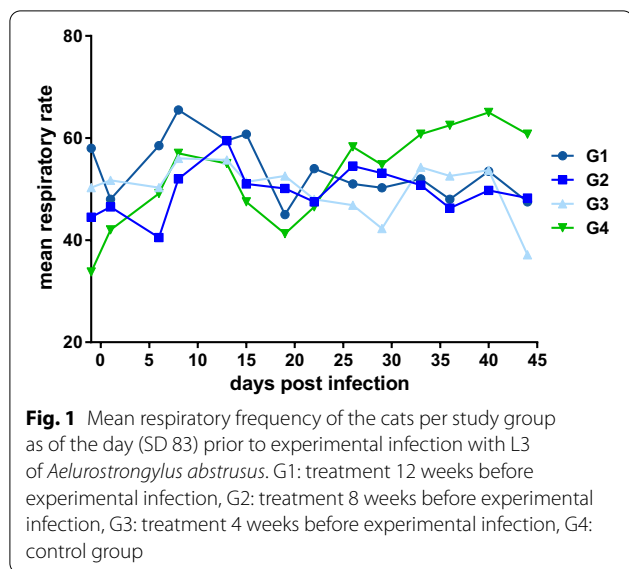
dpi = day post infection, max. = maximum, GM = geometric mean, n.a. = not applicable

as all animals of the control group (G4) were infected and numbers of (pre-)adult worms retrieved from the lungs ranged from 10 to 64. In the treatment groups, one animal of G1 harboured one female worm, whereas no worms were detected in the cats belonging to G2 and G3. Individual cat data are provided in Table 2. The GM count was 26.57 worms in the control group (G4) compared to 0.09 (G1) and 0.00 (G2 and G3) worms in the treatment groups. The respective AM was 31.25 worms in the control group (G4) as well as 0.13 (G1) and 0.00 (G2 and G3) worms in the treatment groups. Based on

GMs, the preventive efficacy of the treatment against *A. abstrusus* worms was 99.66% in G1 and 100% in G2 and G3, respectively. Statistical comparison showed significant differences ($P < 0.0001$) in necropsy worm counts between the control group and all treatment groups.

Discussion

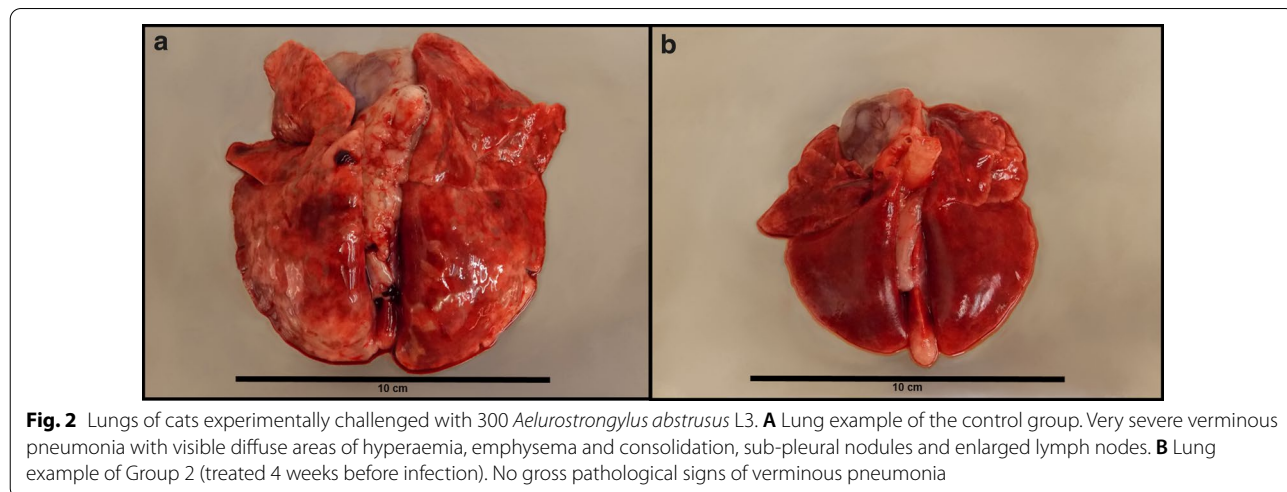
This is the first study demonstrating a long-term preventive efficacy of a drug against cat aelurostrongylosis when applied as a single treatment prior to infection. Based on necropsy worm counts, the preventive efficacy

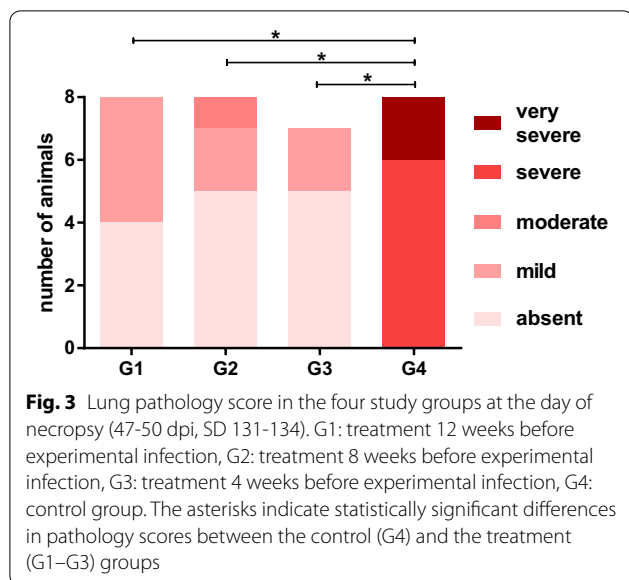


of Bravecto® Plus spot-on solution for cats (280 mg/ml fluralaner and 14 mg/ml moxidectin) at the minimum recommended dose of 2.0 mg moxidectin + 40 mg fluralaner/kg BW against aelurostrongylosis was 100% after application 8 or 4 weeks prior to experimental challenge infection and 99.66% when applied 12 weeks prior to infection. In the latter group, only one cat harboured a single adult *A. abstrusus* female with no faecal larvae excretion observed in this animal during the course of the study. However, another animal in this study group was positive for L1 excretion on several consecutive days. Thus, it appears certain that this cat had a patent infection, even though no adult lungworms could be retrieved from the lungs during necropsy. This is not surprising given that the small size (i.e. 5–10 mm) of adult worms

[16, 39] and their location in the terminal bronchioles, alveoli and alveolar ducts (i.e. the lung parenchyma) [31, 39] render difficult to find *A. abstrusus* during manual dissection of the lungs [1, 16]. Therefore, it is not unlikely that single specimens were missed in the present study despite utmost care. This might also be true for the seven treated cats showing larvae excretion at singular days. Nonetheless, the maximum number of larvae in 5 g faeces ranged from 1 to 31 in the treated cats, while the control cats reached up to 45,900 L1. Overall, data evaluation resulted in > 99.9% preventive efficacy of Bravecto® Plus spot-on solution against larval excretion upon challenge infection 4–12 weeks after treatment.

A known issue of the experimental *A. abstrusus* infection model (inoculation of digested snail solution) is vomiting after inoculation [1, 33, 40]. Here, 23 cats vomited despite the administration of metoclopramide. One cat vomited within 1 h (46 min) after the infection and thus was re-inoculated. The other 22 cats vomited between 81 min pi and the next morning and were not re-inoculated, which might raise the question whether these animals kept the whole infection dose. Even though no precise data are available on how fast *A. abstrusus* L3 penetrate the intestinal mucosa, it can be assumed that the whole infection dose is assured as the mean half-time of gastric emptying after liquid meals is supposed to be < 80 min [41]. In addition, gastric emptying is accelerated by metoclopramide [42]. In another study, one cat vomited 23 min after inoculation of 800 L3, but still harboured 36 worms in the dissected half of the lung without re-inoculation [1]. This is in line with the findings in the present study, where seven out of eight cats of the control group vomited at some point after inoculation, but were all adequately infected with ten or more worms during necropsy without re-inoculation.





Notably, recurring outbreaks of a mild, apyretic upper respiratory tract disease (commonly known as “cat flu”) occurred in 13 cats (2 in G1, 4 in G2, 3 in G3, 4 in G4) during the whole course of the study. Upon request, the breeder reported similar events in the breeding facility. Possible underlying agents are feline herpesvirus, feline calicivirus, *Chlamydomphila felis* or *Bordetella bronchiseptica* [43]. Affected cats, some of which were affected more than once, showed nasal and ocular discharge, sneezing, sniffing, stertor due to mucosal secretions and coughing. These signs could have interfered with the clinical signs because of experimental lungworm infection. Thus, the results of the respiratory assessment performed twice weekly after infection were probably overlain by the cat flu symptoms and could explain why there was no clear difference in respiratory parameters between the control and the treated groups. Furthermore, the respiratory assessments were not always carried out by the same veterinarian. In this respect, it should be taken into account that the evaluation of the intensity of respiratory sounds in cases of minor deviations from the physiological status cannot be fully objectified and thus not completely standardized between different examiners. In addition, subclinical or mild *A. abstrusus* infections are not unusual and may remain unnoticed by the owners or even veterinarians [2, 5, 6]. Hence, respiratory sounds and alterations should be considered with caution to assess the preventive efficacy of anthelmintics against *A. abstrusus*. Here, no statistically significant differences regarding the respiratory frequency were observed between the control and treatment groups, although the control animals showed an increased mean respiratory frequency, which may be interpreted as a first sign of increased oxygen demand or decreased gas

exchange as in the case of aelurostrongylosis [44]. Further evaluations are warranted to assess whether the (mean) respiratory frequency or other clinical signs may be considered as auxiliary parameters in efficacy studies.

In contrast to the clinical parameters, statistically significant differences between the groups in gross lung pathology were observed, despite the presence of the mild upper respiratory tract infection in some cats. Since none of these cats showed fever or general depression, a pneumonia due to the “cat flu” was unlikely. Nevertheless, a minor impact on the lung pathology score cannot be excluded. However, the study groups were evenly affected by the “cat flu,” while lung appearance during necropsy showed clear differences: In the control group, the lungs showed severe to very severe pathological findings typical of aelurostrongylosis such as emphysema, subpleural opaque or yellowish nodules and areas of hyperaemia [1, 33, 40]. In all treated groups such findings were either absent or only mild to moderate. Thus, lung pathology appeared to be a suitable additional parameter to assess the preventive efficacy, and the observed data fit with a previous study, which reported marked differences in the gross lung appearance between control cats and those preventively treated against aelurostrongylosis [33]. This latter study showed the efficacy of two treatments of an imidacloprid 10%/moxidectin 1% spot-on formulation (Advocate[®]; Bayer Animal Health [part of ELANCO Animal Health]) at the minimum recommended dose of 10 mg/kg BW imidacloprid and 1 mg/kg BW moxidectin applied at a 4-week interval in preventing cat aelurostrongylosis [33]. The first treatment was performed either 4, 10 or 20 days before and the second 24, 14 or 4 days after experimental infection, respectively. As a single administration of moxidectin is reported to be effective at least in terms of suppressing larval excretion and resolving clinical signs in a patent infection [2, 6, 45], the protective effect of the first treatment in the mentioned study [33] applied prior to the challenge infection cannot be properly assessed. Therefore, it remains unclear whether and to what extent the treatment prior to infection had a preventive effect against subsequent challenge infection. Nevertheless, this study showed that monthly administration of the product reliably eliminated early larval stages and thereby precludes lung damages and patent infections by *A. abstrusus* [33].

The preventive efficacy of a single application of Bravecto[®] Plus spot-on solution for cats against aelurostrongylosis for a period of 12 weeks is in line with the treatment interval recommended by the manufacturer to control flea and tick infestations and to prevent heartworm disease. Similarly, at least four anthelmintic treatments or faecal examinations (and treatment in case of positive results) per year are recommended by the

European Scientific Counsel Companion Animal Parasites (ESCCAP) to reduce the risk of excretion of *Toxocara* eggs in free-roaming cats [46]. However, for cats sharing homes with young children or immunocompromised persons, monthly treatment against roundworms or faecal examination is advised. A monthly interval is also generally recommended by the current country-specific German adaptation of the ESCCAP guidelines for cats with non-supervised outdoor access [47].

Conclusion

The administration of Bravecto® Plus spot-on solution for cats (280 mg/ml fluralaner and 14 mg/ml moxidectin) 4, 8 or 12 weeks prior to *A. abstrusus* infection was safe and reliable in inhibiting the establishment of adult *A. abstrusus* in the lung and in preventing visible lung damages and larval excretion. Thus, it can be concluded that a single treatment prevents cat aelurostrongylosis for at least 12 weeks.

Supplementary Information

The online version contains supplementary material available at <https://doi.org/10.1186/s13071-021-04610-y>.

Additional file 1. Detailed information on the study population and composition of the study groups.

Abbreviations

AM: Arithmetic mean; BW: Body weight; dpi: Days post infection; ESCCAP: European Scientific Counsel for Companion Animal Parasites; GM: Geometric mean; G: Study group; L1: First-stage larvae; L3: Third-stage larvae; L4: Fourth-stage larvae; L5: Fifth-stage larvae; pi: Post infection; SD: Study day; VICH: International Cooperation on Harmonization of Technical Requirements for Registration of Veterinary Medicinal Products; WAAVP: World Association for the Advancement of Veterinary Parasitology.

Acknowledgements

The authors would like to thank Katrin Blazejak for assisting in conducting the study. Furthermore, the assistance of the veterinary and laboratory personnel of the Institute for Parasitology, University of Veterinary Medicine Hannover, is gratefully acknowledged.

Authors' contributions

KR and DH performed practical work and NR monitored the study. EZ conducted the statistical calculations. SM and ADC produced infected snails. DT supervised the snail infection and breeding. KR, NR, RKAR and CS designed the study, and KR, NR and CS coordinated the study. KR, NR and CS drafted the manuscript. All authors participated in data analysis and interpretation and reviewed the manuscript draft. All authors read and approved the final manuscript.

Funding

Open Access funding enabled and organized by Projekt DEAL. The study was funded by MSD Animal Health.

Availability of data and materials

Most data analysed during this study are included in the article. The remaining data from this clinical study are proprietary and maintained by MSD Animal Health.

Ethics approval and consent to participate

Animal experiments to evaluate the drug combination in cats were approved by the ethics commission of the Institutional Animal Care and Use Committee (IACUC) of the German Lower Saxony State Office for Consumer Protection and Food Safety (Niedersaechsisches Landesamt fuer Verbraucherschutz und Lebensmittelsicherheit) under reference number 33.19-42502-04-18/3002. Animal husbandry and handling complied with the European Commission guidelines for the accommodation of animals used for experimental and other scientific purposes. The activities on experimental infected snails and the larvae collection from naturally infected cats were approved by the Italian Ethical committee CEISA (Committee on Animal Research and Ethics of the Universities of Chieti-Pescara, Teramo L'Aquila and of the Experimental Zoonophylactic Institute of Abruzzo-Molise) under reference number UNCHD12 n. 311B-11/07/2018 as well as the Italian Ministry of Health (Ministero della Salute, Direzione Generale Sanità Animale e dei Farmaci Veterinari) under reference number DGSFAF 0018252-P-24/07/2018.

Consent for publication

Not applicable.

Competing interests

NR, EZ and RKAR are employees of MSD Animal Health. KR, DH, DT, SM, ADC and CS declare that there is no conflict with commercial interests. DT, SM and ADC declare that the snail infection and breeding did not coincide with other similar laboratory procedures for the cat lungworm *Aelurostrongylus abstrusus*.

Author details

¹ Institute for Parasitology, Centre for Infection Medicine, University of Veterinary Medicine Hannover, Hanover, Germany. ² MSD Animal Health Innovation GmbH, Schwabenheim, Germany. ³ Faculty of Veterinary Medicine, University of Teramo, Teramo, Italy.

Received: 20 November 2020 Accepted: 23 January 2021

Published online: 16 February 2021

References

- Schnyder M, Di Cesare A, Basso W, Guscetti F, Riond B, Glaus T, et al. Clinical, laboratory and pathological findings in cats experimentally infected with *Aelurostrongylus abstrusus*. *Parasitol Res*. 2014;113:1425–33.
- Crisi PE, Aste G, Traversa D, Di Cesare A, Febo E, Vignoli M, et al. Single and mixed feline lungworm infections: clinical, radiographic and therapeutic features of 26 cases (2013–2015). *J Feline Med Surg*. 2017;19:1017–29.
- Soares C, Cardoso M, Mestre A, Crisi PE. Case report: Severe and progressive bronchopneumonia by *Aelurostrongylus abstrusus* in an adopted stray cat from Portugal. *J Parasit Dis*. 2017;41:976–80.
- Philbey AW, Krause S, Jefferies R. Verminous pneumonia and enteritis due to hyperinfection with *Aelurostrongylus abstrusus* in a kitten. *J Comp Pathol*. 2014;150:357–60.
- Kiszely S, Gyurkovszky M, Solymosi N, Farkas R. Survey of lungworm infection of domestic cats in Hungary. *Acta Vet Hung*. 2019;67:407–17.
- Traversa D, Di Cesare A, Milillo P, Lohr B, Iorio R, Pampurini F, et al. Efficacy and safety of imidacloprid 10%/moxidectin 1% spot-on formulation in the treatment of feline aelurostrongylosis. *Parasitol Res*. 2009;105(Suppl 1):55–62.
- Hobmaier M, Hobmaier A. Mammalian phase of the lung-worm *Aelurostrongylus abstrusus* in the cat. *J Am Vet Med Assoc*. 1935;87:191–8.
- Jezewski W, Bunkowska-Gawlik K, Hildebrand J, Perec-Matysiak A, Laskowski Z. Intermediate and paratenic hosts in the life cycle of *Aelurostrongylus abstrusus* in natural environment. *Vet Parasitology*. 2013;198:401–5.
- Grandi G, Comin A, Ibrahim O, Schaper R, Forshell U, Lind EO. Prevalence of helminth and coccidian parasites in Swedish outdoor cats and the first report of *Aelurostrongylus abstrusus* in Sweden: a coprological investigation. *Acta Vet Scand*. 2017;59:19.
- Elsheikha HM, Wright I, Wang B, Schaper R. Prevalence of feline lungworm *Aelurostrongylus abstrusus* in England. *Vet Parasitology Reg Stud Rep*. 2019;16:100271.

11. Garcia-Campos A, Power C, O'Shaughnessy J, Browne C, Lawlor A, McCarthy G, et al. One-year parasitological screening of stray dogs and cats in County Dublin. *Ireland Parasitology*. 2018;9:1–7.
12. Zottler EM, Bieri M, Basso W, Schnyder M. Intestinal parasites and lungworms in stray, shelter and privately owned cats of Switzerland. *Parasitol Int*. 2019;69:75–81.
13. Gueldner EK, Gilli U, Strube C, Schnyder M. Seroprevalence, biogeographic distribution and risk factors for *Aelurostrongylus abstrusus* infections in Swiss cats. *Vet Parasitol*. 2019;266:27–33.
14. Raue K, Heuer L, Böhm C, Wolken S, Epe C, Strube C. 10-year parasitological examination results (2003 to 2012) of faecal samples from horses, ruminants, pigs, dogs, cats, rabbits and hedgehogs. *Parasitol Res*. 2017;116:3315–30.
15. Hansen AP, Skarbye LK, Vinther LM, Willesen JL, Pipper CB, Olsen CS, et al. Occurrence and clinical significance of *Aelurostrongylus abstrusus* and other endoparasites in Danish cats. *Vet Parasitol*. 2017;234:31–9.
16. Olsen CS, Willesen JL, Pipper CB, Mejer H. Occurrence of *Aelurostrongylus abstrusus* (Railliet, 1898) in Danish cats: A modified lung digestion method for isolating adult worms. *Vet Parasitol*. 2015;210:32–9.
17. Diakou A, Di Cesare A, Barros LA, Morelli S, Halos L, Beugnet F, et al. Occurrence of *Aelurostrongylus abstrusus* and *Troglostrongylus brevior* in domestic cats in Greece. *Parasit Vectors*. 2015;8:590.
18. Morelli S, Diakou A, Di Cesare A, Schnyder M, Colombo M, Strube C, et al. Feline lungworms in Greece: copromicroscopic, molecular and serological study. *Parasitol Research*. 2020;119:2877–83.
19. Giannelli A, Capelli G, Joachim A, Hinney B, Losson B, Kirkova Z, et al. Lungworms and gastrointestinal parasites of domestic cats: a European perspective. *Int J Parasitol*. 2017;47:517–28.
20. Di Cesare A, Gueldner EK, Traversa D, Veronesi F, Morelli S, Crisi PE, et al. Seroprevalence of antibodies against the cat lungworm *Aelurostrongylus abstrusus* in cats from endemic areas of Italy. *Vet Parasitol*. 2019;272:13–6.
21. Abu-Madi MA, Al-Ahbab DA, Al-Mashhadani MM, Al-Ibrahim R, Pal P, Lewis JW. Patterns of parasitic infections in faecal samples from stray cat populations in Qatar. *J Helminthol*. 2007;81:281–6.
22. Sommerfelt IE, Cardillo N, Lopez C, Ribicich M, Gallo C, Franco A. Prevalence of *Toxocara cati* and other parasites in cats' faeces collected from the open spaces of public institutions: Buenos Aires. *Argentina Vet Parasitol*. 2006;140:296–301.
23. Carruth AJ, Buch JS, Braff JC, Chandrashekar R, Bowman DD. Distribution of the feline lungworm *Aelurostrongylus abstrusus* in the USA based on fecal testing. *JFMS Open Rep*. 2019;5:2055116919869053.
24. Adams PJ, Elliot AD, Algar D, Brazell RI. Gastrointestinal parasites of feral cats from Christmas Island. *Aust Vet J*. 2008;86:60–3.
25. Cavalera MA, Schnyder M, Gueldner EK, Furlanello T, Iatta R, Brianti E, et al. Serological survey and risk factors of *Aelurostrongylus abstrusus* infection among owned cats in Italy. *Parasitol Res*. 2019;118:2377–82.
26. Zottler EM, Strube C, Schnyder M. Detection of specific antibodies in cats infected with the lung nematode *Aelurostrongylus abstrusus*. *Vet Parasitol*. 2017;235:75–82.
27. Abbate JM, Arfuso F, Gaglio G, Napoli E, Cavalera MA, Giannetto S, et al. Larval survival of *Aelurostrongylus abstrusus* lungworm in cat litters. *J F Med Surg*. 2019;21:992–7.
28. von Holtum C, Strube C, Schnieder T, von Samson-Himmelstjerna G. Development and evaluation of a recombinant antigen-based ELISA for serodiagnosis of cattle lungworm. *Vet Parasitol*. 2008;151:218–26.
29. Pennisi MG, Hartmann K, Addie DD, Boucraut-Baralon C, Egberink H, Frymus T, et al. Lungworm disease in cats: ABCD guidelines on prevention and management. *J F Med Surg*. 2015;17:626–36.
30. Traversa D, Di Cesare A. Diagnosis and management of lungworm infections in cats: Cornerstones, dilemmas and new avenues. *J F Med Surg*. 2016;18:7–20.
31. Hamilton JM. The influence of infestation by *Aelurostrongylus abstrusus* on the pulmonary vasculature of the cat. *Br Vet J*. 1970;126:202–9.
32. Knaus M, Chester ST, Rosenthal J, Kühnert A, Rehbein S. Efficacy of a novel topical combination of fipronil, (S)-methoprene, eprinomectin and praziquantel against larval and adult stages of the cat lungworm *Aelurostrongylus abstrusus*. *Vet Parasitol*. 2014;202:64–8.
33. Heuer L, Petry G, Pollmeier M, Schaper R, Deuster K, Schmidt H, et al. Efficacy of imidacloprid 10%/moxidectin 1% spot-on formulation (Advocate®) in the prevention and treatment of feline aelurostrongylosis. *Parasit Vectors*. 2020;13:65.
34. VICH Guideline 9: Good Clinical Practice. Veterinary International Cooperation on Harmonization, European Agency for the Evaluation of Medical Products, London, CVMP/VICH/595/98-Final, 2000.
35. VICH Guideline 7: Efficacy of Anthelmintics: General Requirements., Veterinary International Cooperation on Harmonization, European Agency for the Evaluation of Medical Products, London, CVMP/VICH/832/99-corr. 2000.
36. Di Cesare A, Crisi PE, Di Giulio E, Veronesi F, FrangipaniRegalbono A, Talone T, et al. Larval development of the feline lungworm *Aelurostrongylus abstrusus* in *Helix aspersa*. *Parasitol Res*. 2013;112:3101–8.
37. Di Cesare A, Veronesi F, FrangipaniRegalbono A, Iorio R, Traversa D. Novel Molecular Assay for Simultaneous Identification of Neglected Lungworms and Heartworms Affecting Cats. *J Clin Microbiol*. 2015;53:3009–13.
38. Morelli S, Traversa D, Colombo M, Raue K, Strube C, Pollmeier M, et al. The effect of the hibernation on the larval development of *Troglostrongylus brevior* in the land snail *Cornu aspersum*. *Vet Parasitol*. 2020;282:109123.
39. Gerichter CB. Studies on the nematodes parasitic in the lungs of Felidae in Palestine. *Parasitology*. 1949;39:251–62.
40. Böhm C, Wolken S, Schnyder M, Basso W, Deplazes P, Di Cesare A, et al. Efficacy of Emodepside/Praziquantel Spot-on (Profender®) against adult *Aelurostrongylus abstrusus* Nematodes in Experimentally Infected Cats. *Parasitol Res*. 2015;114(Suppl 1):S155–64.
41. Gould RJ, Fioravanti C, Cook PG, Solomon HF. A model of gastric emptying in cats shows solid emptying is promoted by MK-329: a CCK antagonist. *J Nucl Med*. 1990;31:1494–9.
42. Husnik R, Gaschen FP, Fletcher JM, Gaschen L. Ultrasonographic assessment of the effect of metoclopramide, erythromycin, and xenatide on solid-phase gastric emptying in healthy cats. *J Vet Intern Med*. 2020;34:99.
43. Helps CR, Lait P, Damhuis A, Björnehmar U, Bolta D, Brovida C, et al. Factors associated with upper respiratory tract disease caused by feline herpesvirus, feline calicivirus, *Chlamydophila felis* and *Bordetella bronchiseptica* in cats: experience from 218 European catteries. *Vet Rec*. 2005;156:669–73.
44. Gerdin JA, Slater MR, Makolinski KV, Looney AL, Appel LD, Martin NM, et al. Post-mortem findings in 54 cases of anesthetic associated death in cats from two spay-neuter programs in New York State. *J F Med Surg*. 2011;13:959–66.
45. Cavalera MA, Colella V, Napoli E, Arfuso F, Panarese R, Brianti E, et al. Shedding of feline lungworm larvae and their infectivity to snail intermediate hosts after anthelmintic treatment. *Int J Parasitol*. 2019;49:449–53.
46. ESCCAP. Worm control in dogs and cats. ESCCAP guideline 01, sixth edition. 2020. <https://www.esccap.org/link-document/27/>. Accessed 10 Nov 2020.
47. ESCCAP Deutschland. Bekämpfung von Würmern (Helminthen) bei Hunden und Katzen. Deutsche Adaption der ESCCAP-Empfehlung Nr. 1. 2014. https://www.esccap.de/v2/wp-content/uploads/2020/06/2018-ESCCA-P-Helminthen_01.pdf. Accessed 10 Nov 2020.

Publisher's Note

Springer Nature remains neutral with regard to jurisdictional claims in published maps and institutional affiliations.

Ready to submit your research? Choose BMC and benefit from:

- fast, convenient online submission
- thorough peer review by experienced researchers in your field
- rapid publication on acceptance
- support for research data, including large and complex data types
- gold Open Access which fosters wider collaboration and increased citations
- maximum visibility for your research: over 100M website views per year

At BMC, research is always in progress.

Learn more biomedcentral.com/submissions

