

<https://helda.helsinki.fi>

Respiratory muscle function in patients with nemaline myopathy

van Kleef, Esmee S.B.

2022-08

van Kleef , E S B , van Doorn , J L M , Gaytant , M A , de Weerd , W , Vosse , B A H , Wallgren-Pettersson , C , van Engelen , B G M , Ottenheijm , C A C , Voermans , N C & Doorduyn , J 2022 , ' Respiratory muscle function in patients with nemaline myopathy ' , Neuromuscular Disorders , vol. 32 , no. 8 , pp. 654-663 . <https://doi.org/10.1016/j.nmd.2022.06.009>

<http://hdl.handle.net/10138/348049>

<https://doi.org/10.1016/j.nmd.2022.06.009>

cc_by

publishedVersion

Downloaded from Helda, University of Helsinki institutional repository.

This is an electronic reprint of the original article.

This reprint may differ from the original in pagination and typographic detail.


Please cite the original version.



ELSEVIER

Contents lists available at ScienceDirect

Neuromuscular Disorders

journal homepage: www.elsevier.com/locate/nmd

Respiratory muscle function in patients with nemaline myopathy

Esmee S.B. van Kleef^a, Jeroen L.M. van Doorn^a, Michael A. Gaytant^b, Willemien de Weerd^c, Bettine A.H. Vosse^d, Carina Wallgren-Pettersson^{e,f}, Baziel G.M. van Engelen^a, Coen A.C. Ottenheijm^g, Nicol C. Voermans^a, Jonne Doorduyn^{a,*}

^a Department of Neurology, Donders Institute for Brain, Cognition and Behaviour, Radboud University Medical Centre, Nijmegen, the Netherlands

^b Department of Pulmonary Diseases/Home Mechanical Ventilation, University Medical Center Utrecht, the Netherlands

^c Department of Pediatrics, Beatrix Children's Hospital, University Medical Center Groningen, the Netherlands

^d Department of Pulmonary Diseases, Maastricht University Medical Center, the Netherlands

^e Folkhälsan Institute of Genetics, Folkhälsan Research Center, Helsinki, Finland

^f Department of Medical and Clinical Genetics, Medicum, University of Helsinki, Helsinki, Finland

^g Department of Physiology, Amsterdam UMC (location Vumc), the Netherlands

ARTICLE INFO

Article history:

Received 20 January 2022

Revised 16 June 2022

Accepted 20 June 2022

Keywords:

Respiratory muscles
Nemaline myopathy
Diaphragm
Ultrasound
Spirometry

ABSTRACT

In this cross-sectional study, we comprehensively assessed respiratory muscle function in various clinical forms of nemaline myopathy (NM) including non-volitional tests for diaphragm function. Forty-two patients with NM were included (10 males (25–74 y/o); 32 females (11–76 y/o)). The NM forms were typical (n=11), mild (n=7), or childhood-onset with slowness of movements (n=24). Forced vital capacity (FVC) and maximal inspiratory pressure were decreased in typical NM in comparison with childhood-onset NM with slowness (32.0 [29.0–58.5] vs 81.0 [75.0–87.0]%, $p < 0.01$, and 35.0 [24.0–55.0] vs 81.0 [65.0–102.5] cmH₂O, $p < 0.01$). Eight patients with childhood-onset NM with slowness had respiratory muscle weakness. There was a low correlation between FVC and Motor Function Measure scores ($r = 0.48$, $p < 0.01$). End-inspiratory diaphragm thickness and twitch mouth pressure were decreased in patients requiring home mechanical ventilation compared to non-ventilated patients with normal lung function (1.8 [1.5–2.4] vs 3.1 [2.0–4.6] mm, $p = 0.049$, and -7.9 [-10.9– -4.0] vs -14.9 [-17.3– -12.6], $p = 0.04$). Our results show that respiratory muscle weakness is present in all NM forms, including childhood-onset NM with slowness, and may be present irrespective of the degree of general motor function impairment. These findings highlight the importance for screening of respiratory function in patients with NM to guide respiratory management.

© 2022 The Authors. Published by Elsevier B.V.

This is an open access article under the CC BY license (<http://creativecommons.org/licenses/by/4.0/>)

1. Introduction

Nemaline myopathy (NM) is a congenital myopathy with characteristic nemaline rods in the muscle biopsy [1,2] with clinical manifestation ranging from severe NM to childhood-onset NM with slowness of movements. Causative mutations in at least 12 genes have been identified [3–17], with *NEB* and *ACTA1* mutations being the most prevalent worldwide [1,2]. The most prevalent NM form in the Netherlands is childhood-onset NM with slowness of movements caused by mutations in the *KBTBD13* gene [18–21].

Respiratory muscle weakness is a common feature in patients with NM and can lead to respiratory failure [22,23]. In previous

clinical studies, the physiological impact of respiratory muscle weakness was mostly assessed by spirometry or based on the presence of clinically evident respiratory insufficiency [9,24–28]. A recent NM cohort study also assessed respiratory muscle strength [29]. These studies did not assess respiratory involvement in relation to the clinical NM forms, the relationship between respiratory muscle function and motor function, or specific measures of diaphragm function and structure. Furthermore, respiratory muscle weakness in childhood-onset NM with slowness has not been reported in the cohort studies [20,30,31], although it was tested in only one study [31]. Detailed knowledge of respiratory muscle involvement in the different forms of NM is important for respiratory management and for the development of outcome measures for clinical trials.

This cross-sectional study comprehensively assessed the degree of respiratory muscle involvement in different NM forms and genotypes using global measures of respiratory muscle function

* Corresponding author: P.O. Box 9101, 6500 HB

E-mail address: Jonne.Doorduyn@radboudumc.nl (J. Doorduyn).

(spirometry, respiratory muscle strength testing). Moreover, compared to previous work we used non-volitional measures of respiratory muscle function, i.e. ultrasound imaging of diaphragm and intercostal muscles and twitch mouth pressure ($P_{mo,tw}$) elicited by magnetic stimulation of the phrenic nerves. Furthermore, we explored the relationship between respiratory muscle function and motor function, and included patients with childhood-onset NM with slowness of movements.

2. Patients and methods

2.1. Study design

This cross-sectional study was performed between October 2018 and September 2020 at the Radboud University Medical Centre, Nijmegen, the Netherlands. Ethical approval (NL65214.091.18) was obtained from the local ethical committee and written informed consent was obtained from all patients or legal representatives.

2.2. Study population

Recruitment was performed by contacting patients with NM who had previously visited the outpatient clinic. Moreover, we reached out to clinicians in neuromuscular centres in the Netherlands and to patients via the Dutch patient organisation. The inclusion criteria were genetically confirmed NM or the combination of an NM clinical phenotype, a biopsy confirming NM, and a first degree family member with genetically confirmed NM. The age range included was six to 80 years to increase the likelihood for patients to be cognitively and physically able to carry out the tests. Patients with other conditions affecting pulmonary or respiratory muscle function were excluded. Patient demographics (age, sex, BMI) and genotype were systematically collected.

2.3. Form of NM and motor function

The form of NM, ambulation, requirement for home mechanical ventilation (HMV), and spinal deformity were systematically collected. We used the recently proposed revised classification, which distinguishes five forms of NM based on the age of onset and severity [1,2]:

- 1) **severe NM** (contractures, fractures, no respiratory effort or no movements at birth);
- 2) **typical NM** (perinatal onset and motor milestones delayed but reached);
- 3) **mild NM** (childhood or juvenile onset);
- 4) **distal NM** (distal weakness);
- 5) **childhood-onset NM with slowness** (slowness of movements and core-rod histology, caused by the *KBTBD13* mutation [18–20]);
- 6) **recessive *TNNT1*** (former Amish) **NM**. Ambulation was classified as unaided, using walking aids including intermittent wheelchair use, or wheelchair-dependent. HMV was categorised as none, nocturnal non-invasive, nocturnal and daytime non-invasive, and invasive ventilation. The presence of scoliosis was assessed by physical examination and by the Adam's forward bend test [32], and dichotomized as present or absent. The 32-item Motor Function Measure (MFM) was used to examine motor function. The total score is expressed as percentage of the maximum score.

In case the patients were not able or willing to visit the Radboud University Medical Centre, a limited protocol consisting of MFM assessment and respiratory muscle strength testing was performed during home visits.

2.4. Spirometry and respiratory muscle strength testing

Spirometry was carried out with a handheld electronic spirometer (SpiroUSB, Vyaire Medical, Mettawa, IL, USA) connected

to PC Spirometry software, Spida CareFusion 2.3.0.10 for Windows 7). Forced vital capacity (FVC) and vital capacity (VC) upright and supine, and forced expiratory volume in the first second (FEV1) were measured and compared with reference values [33]. Peak cough flow (PCF) was also measured. Respiratory muscle strength testing, including maximal inspiratory pressure (MIP), maximal expiratory pressure (MEP), and sniff nasal inspiratory pressure (SNIP), was performed with a handheld electronic manometer (Micro RPM, Micro Medical, Rhymney, UK connected to Puma software version 1.4.2) and compared with reference values [34,35]. Both spirometry and respiratory muscle strength tests were performed in accordance with the standards of the American Thoracic Society and the European Respiratory Society [36–38].

2.5. Respiratory muscle ultrasound

Right hemidiaphragm and intercostal muscle thickness and echogenicity was measured in supine position using an Esaote MyLab Twice ultrasound machine (Esaote SpA, Genoa, Italy) equipped with a 3–13 MHz LA533 linear transducer (Esaote SpA, Genoa, Italy) according to previously described standards [39,40]. The ultrasound probe was placed near the zone of apposition of the diaphragm, typically in the 8th or 9th intercostal space, on the antero-axillary line. Thickness was measured at resting end-expiration (DT_{EE}), i.e. at functional residual capacity, and at maximal end-inspiration (DT_{EI}), i.e. at total lung capacity, from the inner part of the peritoneal layer to the inner part of the pleural layer. An average value was calculated from three separate measurements. Thickening ratio (DTR) was calculated as DT_{EI} / DT_{EE} [39] and absolute change in thickness was calculated as $DT_{EI} - DT_{EE}$. Thickness of the intercostal muscles was measured at resting end-expiration (IT_{EE}). Muscle echogenicity was measured by manually selecting a region of interest, using the trace method [41], in the diaphragm or intercostal muscular tissue in the images at end-expiration using custom developed software in Matlab (R2018a, Mathworks, Natick, MA, USA). Echogenicity cannot be reliably measured in a diaphragm thickness of less than 1 mm, leading to exclusion of echogenicity analysis. Three measurements were averaged to calculate the mean echogenicity in grey values. Echogenicity evaluates the muscle structure and increased echogenicity may result from fibrosis, inflammation or fatty degeneration of the muscle [42]. As the reference values of echogenicity are dependent of the ultrasound machine and its settings, standardised scores (z-scores) were calculated as the number of standard deviations from the predicted value. These predicted values were calculated using a linear regression equation including age. This linear regression was obtained from diaphragm ultrasound images from 83 healthy subjects (2–80 y/o) measured in our lab with an even distribution of males and females.

2.6. Twitch mouth pressure

$P_{mo,tw}$ was measured to obtain a nonvolitional measurement of diaphragm function. To measure $P_{mo,tw}$ we used an automated inspiratory-pressure trigger device, as described previously [43]. The patient wore a nose clip in a seated position and breathed through a flanged mouthpiece connected to a two-way non-rebreathing valve with an inflatable balloon connected to the inspiratory port (Series 9300, Hans Rudolph Inc, Kansas City, MO, USA). Mouth pressure was recorded from a small port near the mouthpiece that was connected to a pressure transducer (MP160 equipped with DA100C and TSD160E, connected to AcqKnowledge software version 5.0.2, Biopac systems Inc. Goleta, CA, USA). Two small figure-of-eight coils (D40 Alpha Branding Iron Coil 4179-00, Magstim, Whitland, UK) were placed bilaterally on the phrenic nerves at the posterior border of

the sternomastoid muscle at the level of the cricoid cartilage. The pulses were simultaneously generated by two magnetic stimulators (Magstim 200², Magstim, Whitland, UK). Optimal coil position and intensity were determined by varying the position of the coils and increasing the intensity. The stimulations were automatically delivered at a predetermined inspiratory pressure trigger of -5 cmH₂O to ensure an open glottis. We performed five measurements with 30 seconds in between to avoid twitch potentiation [44]. The highest value was chosen. The compound muscle action potential of the diaphragm was recorded using electrodes (MP160 equipped with BIO100C and MEC110C, connected to AcqKnowledge software version 5.0.2, Biopac systems Inc. Goleta, CA, USA) positioned at the costal margin to check for correct stimulation of the diaphragm. $P_{mo,tw}$ values below -11 cmH₂O were considered abnormal, indicating diaphragm dysfunction [45].

2.7. Respiratory symptoms

We explicitly asked for the presence of respiratory symptoms and symptoms of sleep-related hypoventilation as part of the medical history. We systematically asked about exertional dyspnoea (dyspnoea when washing, dressing and/or walking), orthopnoea, and dyspnoea when bending forward. Symptoms of sleep-related hypoventilation were waking up more often in comparison with five years ago, restlessness during sleep, nightmares, morning headache, and daytime sleepiness (all at multiple days a week).

2.8. Data analysis

The data was stored in Castor EDC (Castor clinical data management platform, Amsterdam, The Netherlands) and the statistical analysis was performed using GraphPad Prism software

version 5.03 (GraphPad Software, San Diego, CA, USA). Results are presented in two different categorisations: form of NM and degree of respiratory involvement. The latter is based on the presence of a restrictive lung pattern, i.e. FVC < 80% of predicted, and use of HMV.

Results are expressed as median [interquartile range (IQR)]. Kruskal-Wallis tests with Dunns post-test analysis were used to compare the groups. Chi-squared tests were used to compare categorical data. Spearman tests assessed correlation analyses. A *p*-value < 0.05 was considered to be statistically significant.

3. Results

3.1. Patient characteristics

Forty-three female patients and 21 male patients with NM were identified, of whom five patients did not fulfil the inclusion criteria because their diagnosis had not been genetically verified. Seventeen patients declined to participate because of various reasons, including the visit considered to be too strenuous or time-consuming. Forty-two patients with NM participated in this study, including ten male patients (24%; aged 25 to 74 years) and 32 female patients (76%; aged 11 to 76 years).

3.2. Form of NM and motor function

The forms of NM were either typical (n=11), mild (n=7), or childhood-onset with slowness (n=24). Walking aids were used by 12 patients and six patients were wheelchair-dependent. A total of 11 patients required HMV. Within this group, seven patients required only nocturnal non-invasive HMV, two NEB patients required daytime and nocturnal non-invasive HMV, and two ACTA1 patients required continuous invasive HMV via tracheostomy. The initial indication for HMV in these 11 patients was sleep-related

Table 1
Demographics and characteristics of included patients with nemaline myopathy.

| | Typical NM (n=11) | Mild NM (n=7) | Childhood-onset NM with slowness (n=24) | Total (n=42) | <i>p</i> -value |
|--|-------------------|------------------|---|------------------|-----------------|
| Genotype (n) | | | | | |
| NEB | 3 | 2 | - | 5 | |
| ACTA1 | 4 | 1 | - | 5 | |
| TPM2 | 1 | 1 | - | 2 | |
| TPM3 | 1 | - | - | 1 | |
| RYR1 | - | 2 | - | 2 | |
| CFL2 | 1 | - | - | 1 | |
| LMOD3 | 1 | - | - | 1 | |
| MYPN | - | 1 | - | 1 | |
| KBTD13 | - | - | 24 | 24 | |
| Female (n (%)) | 8 (73%) | 5 (71%) | 19 (79%) | 32 (76%) | ns |
| Age (years) | 21 [18.0-47.0] | 63 [28.0-67.0] | 49 [31.0-56.8] | 40 [26.5-58.3] | ns |
| BMI (kg/m²) | 20.6 [16.6-24.0]* | 22.8 [19.4-37.6] | 24.7 [23.5-27.2] | 24.0 [20.6-26.7] | 0.01 |
| MFM (%) | 55.0 [49.0-94.0]* | 88.0 [72.0-93.0] | 90.5 [83.5-95.3] | 88.5[66.0-93.3] | 0.02 |
| Ambulation (n) | | | | | |
| Unaided | 2 | 3 | 19 | 24 | |
| Walking aids (including intermittent wheelchair use) | 3 | 4 | 5 | 12 | |
| Wheelchair-dependent | 6 | - | - | 6 | |
| Mechanical ventilation(n) | | | | | |
| None | 2 | 5 | 24 | 31 | |
| Nocturnal non-invasive | 6 | 1 | - | 7 | |
| Nocturnal and daytime non-invasive | 1 | 1 | - | 2 | |
| Invasive | 2 | - | - | 2 | |
| Scoliosis (n) | | | | | |
| No | 5 | 5 | 21 | 31 | |
| Yes | 6 | 2 | 3 | 11 | |

The data are categorised on the form of NM of the patients. NM form is classified according to Laitila et al. [1]. Data are presented as median [IQR]. * Significant difference in comparison with childhood-onset NM with slowness. NM, nemaline myopathy. BMI, body mass index. MFM, Motor Function Measure. IQR, interquartile range.

* Significant difference in comparison with childhood-onset NM with slowness. NM, nemaline myopathy. BMI, body mass index. MFM, Motor Function Measure. IQR, interquartile range.

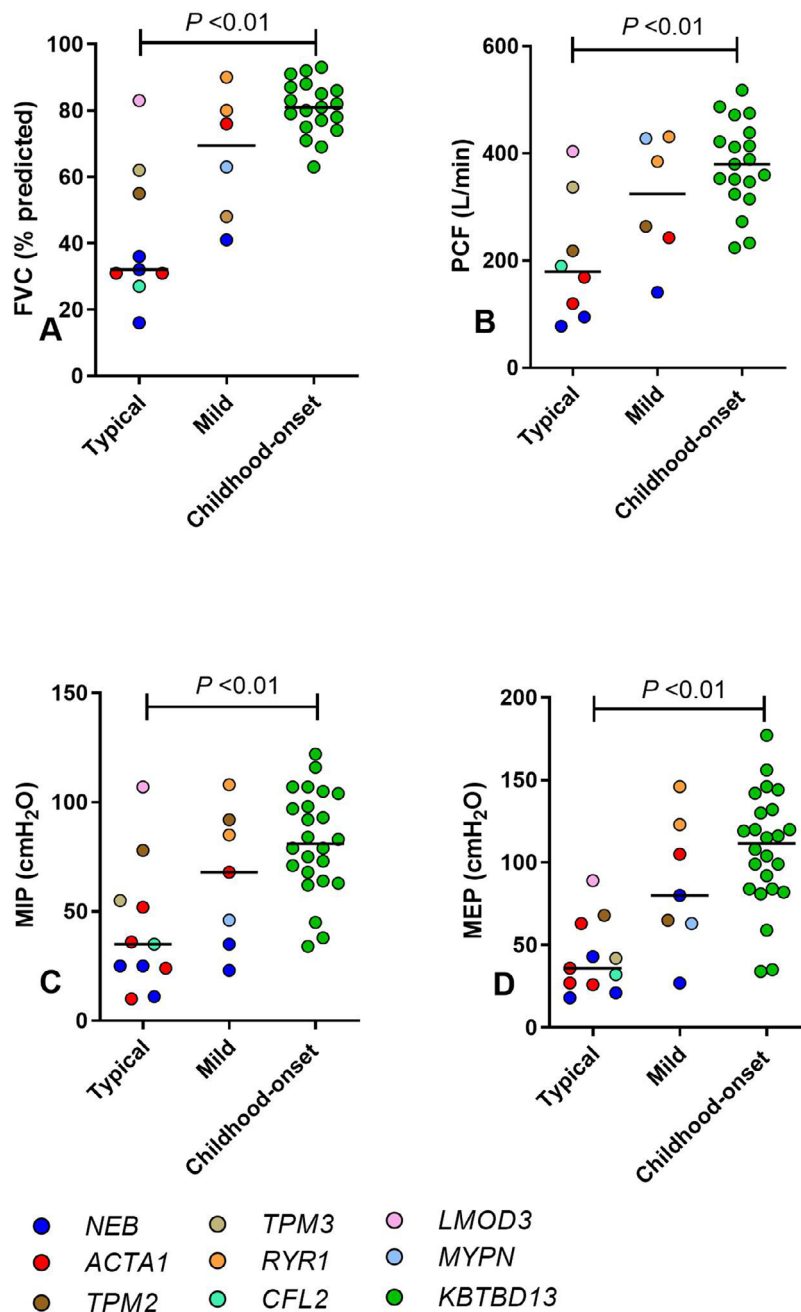


Fig. 1. FVC (A), PCF (B), MIP (C) and MEP (D) in patients with a typical, mild or childhood-onset NM with slowness form. The genotypes are represented by different colours and the horizontal bars represent the median. Significant differences are indicated by p -values of the Dunns post-test. FVC, forced vital capacity. PCF, peak cough flow. MIP, maximal inspiratory pressure. MEP, maximal expiratory pressure. NM, nemaline myopathy

hypoventilation in seven patients and daytime hypercapnia in three patients. In one patient it was not specified other than respiratory insufficiency. Scoliosis was present in 11 patients. Seven patients were visited at home. The patient demographics and characteristics subdivided based on NM form are displayed in Table 1.

3.3. Spirometry and respiratory muscle strength testing

Results of spirometry and respiratory muscle strength testing are presented in Table 2 and Fig. 1, subdivided based on NM forms. At group level, patients with a typical form showed a lower FVC, VC, PCF, MIP, MEP and SNIP in comparison with patients with childhood-onset NM with slowness. However, a large variation in the degree of respiratory muscle involvement was observed within

the three groups. All *NEB* ($n=4$) and *ACTA1* ($n=3$) patients and eight of the 19 *KBTBD13* patients had an FVC < 80% of predicted. FEV₁/FVC was above 70% in all patients, thus no obstructive lung pattern was present. MIP was correlated with FVC (Fig. 2A). There was a low correlation between MFM scores and FVC (Fig. 2B).

To further characterise the patients, they were subdivided based on the presence of a restrictive lung pattern, i.e. an FVC of less than 80% predicted, and requirement for HMV. One *ACTA1* patient was excluded from this subdivision as spirometry could not be performed due to severe respiratory muscle weakness. MIP and MEP were decreased in patients requiring HMV compared to non-ventilated patients with FVC \geq 80% of predicted (Table 3, Fig. 3A and 3B). MEP was decreased in comparison with patients with FVC < 80% of predicted without HMV too.

Table 2

Spirometry, respiratory muscle strength tests, diaphragm and intercostal muscle ultrasound, and twitch mouth pressure results in patients with a typical, mild, or a childhood-onset NM with slowness form.

| | Typical NM (n=11) | Mild NM (n=7) | Childhood-onset NM with slowness (n=24) | Total (n=42) | p-value |
|---|----------------------------|----------------------------|---|----------------------------|---------|
| Spirometry | | | | | |
| FVC (L) | 1.1 [1.0-2.3]* | 2.3 [1.8-2.9] | 3.0 [2.8-3.5] | 2.7 [2.2-3.2] | <0.01 |
| FVC(% predicted) | 32.0 [29.0-58.5]* | 69.5 [46.3-82.5] | 81.0 [75.0-87.0] | 76.5 [53.3-83.5] | <0.01 |
| VC (L) | 1.1 [0.9-2.2]* | 2.2 [1.7-2.9] | 3.0 [2.8-3.6] | 2.8 [2.0-3.3] | <0.01 |
| Change VC upright and supine (%) | -9.0 [-18.8- -1.3] | -2.0 [-10.8- -0.5] | -6.0 [-9.0- -2.0] | -5.0 [-10.0- -1.5] | ns |
| FEV1/FVC | 90.0 [82.0-95.0] | 80.5 [72.5-88.8] | 80.0 [78.0-88.0] | 82.5 [77.8-90.0] | ns |
| PCF (L/min) | 179.5 [101.3-307.3]* | 324.5 [217.5-428.8] | 380.0 [324.0-439.0] | 352.0 [228.5-418.0] | 0.01 |
| Respiratory muscle testing | | | | | |
| MIP (cmH ₂ O) | 35.0 [24.0-55.0]* | 68.0 [35.0-92.0] | 81.0 [65.0-102.5] | 72.0 [37.5-94.0] | <0.01 |
| MIP(% predicted) | 50.0 [32.0-77.0]* | 103.0 [42.0-122.0] | 102.0 [84.3-127.0] | 90.5 [49.8-116.5] | <0.01 |
| MEP (cmH ₂ O) | 36.0 [26.0-63.0]* | 80.0 [63.0-123.0] | 111.5 [84.0-131.5] | 86.5 [42.8-120.0] | <0.01 |
| MEP(% predicted) | 35.0 [28.0-46.0]* | 79.0 [42.0-135.0] | 105.0 [87.8-122.0] | 88.5 [42.0-115.0] | <0.01 |
| SNIP(cmH ₂ O) | 34.5 [18.8-60.3]* | 55.0 [50.0-83.0] | 76.0 [61.8-82.0] | 68.0 [48.5-79.5] | <0.01 |
| SNIP(% predicted) | 36.0 [19.5-63.5]* | 59.0 [48.0-102.0] | 81.0 [72.3-94.5] | 73.0 [50.5-90.0] | <0.01 |
| Diaphragm ultrasound | | | | | |
| DT _{EE} (mm) | 1.4 [1.1-1.7] | 1.4 [1.0-2.7] | 1.4 [1.1-1.7] | 1.4 [1.1-1.7] | ns |
| DT _{EI} (mm) | 2.4 [1.5-2.8] | 3.5 [1.8-5.8] | 2.2 [1.9-3.6] | 2.3 [1.8-3.7] | ns |
| DT _{EI} - DT _{EE} (mm)DTR | 0.7 [0.2-1.3]1.5 [1.2-1.9] | 1.8 [0.8-3.2]2.1 [1.6-2.6] | 0.9 [0.7-1.7] | 1.0 [0.6-1.8]1.7 [1.5-2.1] | nsns |
| Echogenicity(z-scores) | 2.4 [1.5-3.0] | 0.6 [-0.2-1.9] | 1.2 [0.0-1.9] | 1.4 [0.0-2.3] | ns |
| Intercostal muscle ultrasound | | | | | |
| IT _{EE} (mm) | 2.0 [1.8-2.2] | 2.5 [1.7-3.4] | 2.0 [1.7-2.6] | 2.0 [1.8-2.6] | ns |
| Echogenicity(z-scores) | 1.4 [0.8-2.6] | 0.8 [-0.7-2.1] | 1.6 [0.9-2.2] | 1.4 [0.6-2.1] | ns |
| P _{mo,tw} (cmH ₂ O) | -8.7 [-12.2- -4.7]* | -10.0 [-10.1- -9.3] | -15.2 [-19.3- -10.9] | -13.6 [-17.8- -8.8] | 0.02 |

The spirometry and diaphragm and intercostal muscle ultrasound results are obtained from patients who visited the hospital, i.e. 10 patients with a typical, 5 patient with a mild, and 19 patients with a childhood-onset NM with slowness form. The PCF result of one patient with a typical form is missing. Three patients were excluded from diaphragm echogenicity measurement due to a diaphragm thickness of less than 1 mm. Pmo,tw was measured in 5, 3 and 17 adult patients, respectively. Data are presented as median [IQR]. * Significant difference in comparison to patients with childhood-onset NM with slowness. NM, nemaline myopathy. HMV, home mechanical ventilation. FVC, forced vital capacity. VC, vital capacity. FEV1, forced expiratory volume in first second. PCF, peak cough flow. MIP, maximal inspiratory pressure. MEP, maximal expiratory pressure. SNIP, sniff nasal inspiratory pressure. DTEE, end-expiratory diaphragm thickness. DTEI, maximal end-inspiratory diaphragm thickness. DTEI-DTEE, absolute change in diaphragm thickness. DTR, thickening ratio diaphragm. ITEE, end-expiratory intercostal muscle thickness. Pmo,tw, twitch mouth pressure. IQR, interquartile range.

* Significant difference in comparison to patients with childhood-onset NM with slowness. NM, nemaline myopathy. HMV, home mechanical ventilation. FVC, forced vital capacity. VC, vital capacity. FEV1, forced expiratory volume in first second. PCF, peak cough flow. MIP, maximal inspiratory pressure. MEP, maximal expiratory pressure. SNIP, sniff nasal inspiratory pressure. DT_{EE}, end-expiratory diaphragm thickness. DT_{EI}, maximal end-inspiratory diaphragm thickness. DT_{EI}-DT_{EE}, absolute change in diaphragm thickness. DTR, thickening ratio diaphragm. ITEE, end-expiratory intercostal muscle thickness. P_{mo,tw}, twitch mouth pressure. IQR, interquartile range.

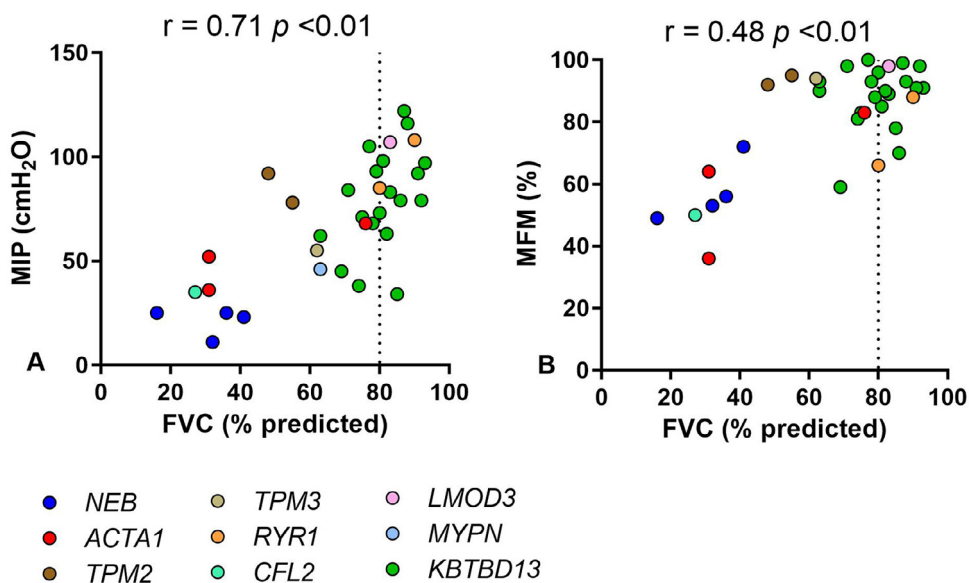


Fig. 2. Correlation between MIP and FVC (A), and MFM and FVC (B). The genotypes are represented by different colours. The dotted vertical line represents the definition of restrictive lung pattern (less than 80% of predicted FVC). FVC, forced vital capacity. MIP, maximal inspiratory pressure. MFM, Motor Function Measure

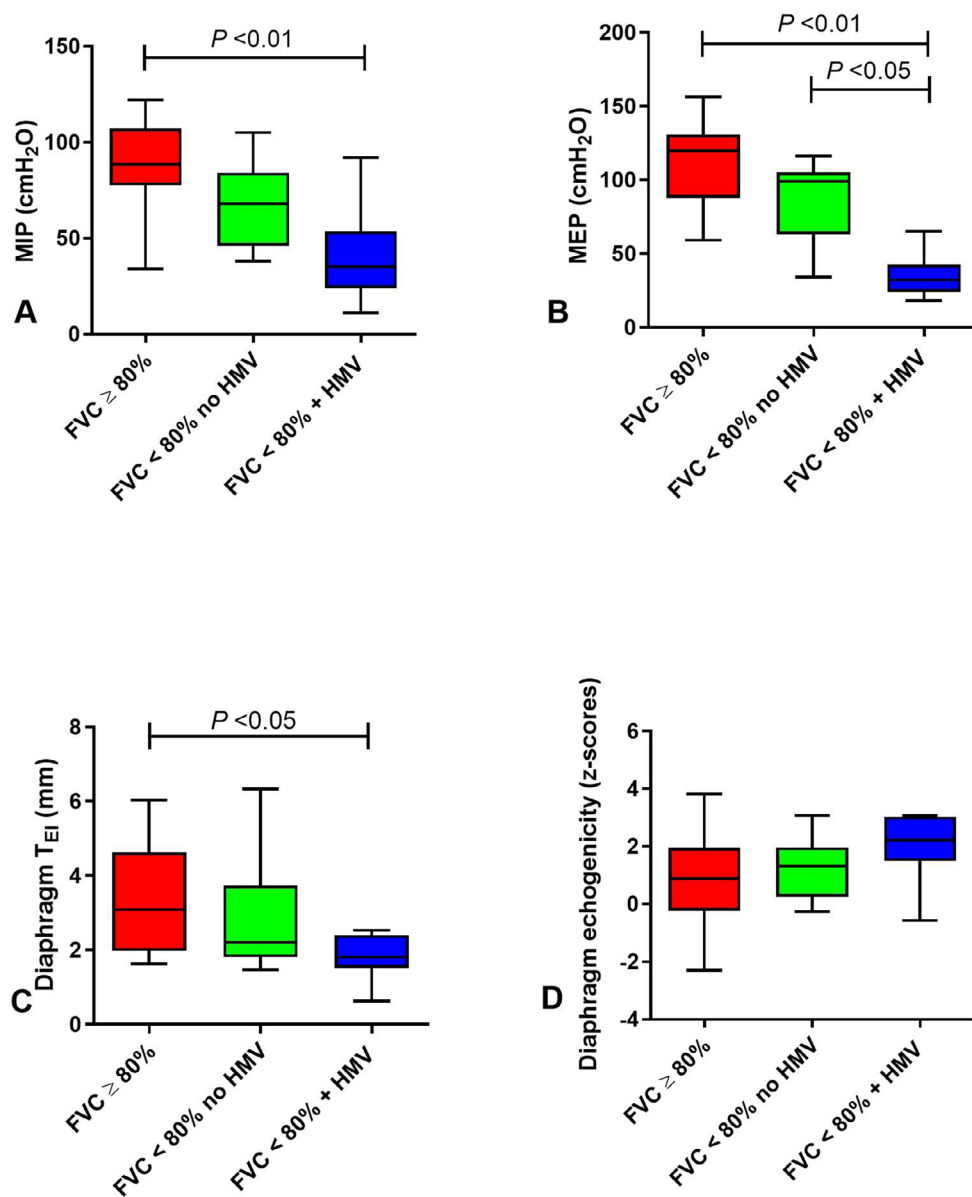


Fig. 3. MIP (A), MEP (B), Diaphragm T_{EI} (C), and echogenicity of the diaphragm (D) in patients with $FVC \geq 80\%$ predicted, $FVC < 80\%$ predicted without HMV, and $FVC < 80\%$ predicted with HMV. The horizontal bars indicate the median. Significant differences are indicated by p -values of the Dunns post-test. HMV, home mechanical ventilation. FVC, forced vital capacity. MIP, maximal inspiratory pressure. MEP, maximal expiratory pressure. T_{EI} , maximal end-inspiratory thickness.

3.4. Diaphragm and intercostal muscle function

At group level, there was no difference in diaphragm and intercostal muscle thickness, and echogenicity between the different forms of NM (Table 2). Due to declination and contraindications for magnetic stimulation, $P_{mo,tw}$ was measured in a selected number of adult patients ($n=25$). $P_{mo,tw}$ was decreased in typical NM in comparison with childhood-onset NM with slowness. In Table 3, results of diaphragm and intercostal muscle measurements are shown in patients with and without restrictive lung pattern and HMV. There was no difference in DT_{EE} between groups, but DT_{EI} , absolute change in thickness, and DTR in patients requiring HMV were lower in comparison with patients with $FVC \geq 80\%$ predicted (Fig. 3C). IT_{EE} showed no difference between the groups. Three patients were excluded from diaphragm echogenicity measurement due to a diaphragm thickness of less than 1 mm. There were no differences in echogenicity of the diaphragm and intercostal muscles between patients, but the majority had a

higher echogenicity than predicted, indicated by a z -score > 0 (Fig. 3D). $P_{mo,tw}$ was decreased in patients requiring HMV in comparison with patients with $FVC \geq 80\%$ predicted.

3.5. Respiratory symptoms

Table 3 shows the respiratory symptoms in groups with different degrees of respiratory muscle weakness. Complaints indicative of respiratory muscle weakness were present in all patients.

4. Discussion

This study showed that respiratory muscle weakness is present in a large proportion (59%) of patients with NM of all clinical forms. In contrast to previous findings, we found that respiratory muscle weakness is also present in patients with childhood-onset NM with slowness of movements. There

Table 3

Results from respiratory muscle strength testing, diaphragm and intercostal muscle ultrasound, twitch mouth pressure, and respiratory symptoms in patients with FVC \geq 80% predicted, FVC < 80% predicted without HMV, and FVC < 80% predicted with HMV.

| | FVC \geq 80% (n=14) | FVC <80% no HMV (n=11) | FVC <80% + HMV (n=9) | p-value |
|---|----------------------------|----------------------------|-------------------------------|----------|
| Genotype (n) | | | | |
| <i>NEB</i> | - | - | 4 | |
| <i>ACTA1</i> | - | 1 | 2 | |
| <i>TPM2</i> | - | 1 | 1 | |
| <i>TPM3</i> | - | - | 1 | |
| <i>RYR1</i> | 2 | - | - | |
| <i>CFL2</i> | - | - | 1 | |
| <i>LMOD3</i> | 1 | - | - | |
| <i>MYPN</i> | - | 1 | - | |
| <i>KBTBD13</i> | 11 | 8 | - | |
| NM form (n) | | | | |
| Typical | 1 | 2 | 7 | |
| Mild | 2 | 1 | 2 | |
| Childhood-onset with slowness | 11 | 8 | - | |
| Female (n (%)) | 11 (79%) | 9 (82%) | 8 (89%) | ns |
| Age (years) | 55 [39.5-59.8] | 34 [28.0-58.0] | 28 [18.0-60.5] | ns |
| BMI (kg/m²) | 26.3 [24.4-32.6] | 23.7 [22.2-24.5] | 19.4 [16.6-21.9]* | <0.01 |
| MFM (%) | 90.5 [83.3-96.5] | 90.0 [83.0-95.0] | 56.0 [49.5-82.0]* † | 0.01 |
| Respiratory muscle testing | | | | |
| MIP (cmH ₂ O) | 88.5 [77.5-107.3] | 68.0 [46.0-84.0] | 35.0 [24.0-53.5]* | <0.01 |
| MIP(% predicted) | 114.0 [102.3-130.8] | 96.0 [55.0-103.] | 50.0 [32.0-76.5]* | <0.01 |
| MEP (cmH ₂ O) | 119.5 [87.8-130.5] | 99.0 [63.0-105.0] | 32.0 [24.0-42.5]* † | <0.01 |
| MEP(% predicted) | 117.0 [84.3-132.0] | 93.0 [42.0-111.0] | 35.0 [23.5-43.5]* † | <0.01 |
| SNIP (cmH ₂ O) | 77.5 [71.3-81.5] | 68.0 [55.0-83.0] | 20.0 [17.0-57.0]* † | <0.01 |
| SNIP(% predicted) | 85.5 [71.5-99.0] | 77.0 [52.0-95.0] | 24.0 [19.0-56.5]* † | <0.01 |
| Diaphragm ultrasound | | | | |
| DT _{EE} (mm) | 1.4 [1.3-2.0] | 1.3 [1.0-1.7] | 1.3 [1.0-1.6] | ns |
| DT _{EI} (mm) | 3.1 [2.0-4.6] | 2.2 [1.8-3.7] | 1.8 [1.5-2.4]* | 0.049 |
| DT _{EI} - DT _{EE} (mm)DTR | 1.6 [0.7-2.8]1.9 [1.6-2.6] | 1.1 [0.7-1.9]1.7 [1.6-2.1] | 0.5 [0.2-1.0]* 1.4 [1.2-1.7]* | 0.020.03 |
| Echogenicity(z-scores) | 0.9 [-0.2-2.0] | 1.3 [0.3-2.0] | 2.2 [1.5-3.0] | ns |
| Intercostal muscle ultrasound | | | | |
| IT _{EE} (mm) | 2.0 [1.7-3.1] | 2.1 [1.3-2.6] | 1.9 [1.8-2.2] | ns |
| Echogenicity(z-scores) | 1.1 [0.5-1.7] | 1.9 [0.9-2.4] | 1.4 [1.0-2.6] | ns |
| P_{mo,tw} (cmH₂O) | -14.9 [-17.3- -12.6] | -9.0 [-19.4- -8.4] | -7.9 [-10.9- -4.0]* | 0.04 |
| Respiratory symptoms(n (%)) | | | | |
| Exertional dyspnoea | 5 (36%) | 3 (27%) | 6 (67%) | |
| Orthopnoea | 0 (0%) | 1 (9%) | 3 (33%) | |
| Dyspnoea when bending forward | 2 (14%) | 3 (27%) | 3 (33%) | |
| Waking up more often | 6 (43%) | 3 (27%) | 2 (22%) | |
| Restlessness | 4 (29%) | 1 (9%) | 1 (11%) | |
| Nightmares | 0 (0%) | 1 (9%) | 3 (33%) | |
| Morning headache | 3 (21%) | 4 (36%) | 1 (11%) | |
| Daytime sleepiness | 6 (43%) | 0 (0%) | 2 (22%) | |

Three patients were excluded from diaphragm echogenicity measurement due to a diaphragm thickness of less than 1 mm. P_{mo,tw} was measured in 11 patients with FVC \geq 80% predicted, 10 with FVC < 80% predicted without HMV, and 4 with FVC < 80% predicted with HMV. Data are presented as median [IQR].

* Significant in comparison to patients with FVC \geq 80%.

† Significant in comparison to patients with FVC < 80% without HMV. HMV, home mechanical ventilation. FVC, forced vital capacity. NM, nemaline myopathy. BMI, body mass index. MFM, Motor Function Measure. MIP, maximal inspiratory pressure. MEP, maximal expiratory pressure. SNIP, sniff nasal inspiratory pressure. DT_{EE}, end-expiratory diaphragm thickness. DT_{EI}, maximal end-inspiratory diaphragm thickness. DT_{EI}-DT_{EE}, absolute change in diaphragm thickness. DTR, thickening ratio diaphragm. IT_{EE}, end-expiratory intercostal muscle thickness. P_{mo,tw}, twitch mouth pressure. IQR, interquartile range.

was a low correlation between motor function and the degree of respiratory muscle weakness in our cohort, indicating that respiratory muscle function can be compromised independently of motor performance. Furthermore, we showed, using diaphragm ultrasound and twitch mouth pressure, that impaired diaphragm function is a key component of respiratory muscle weakness in NM.

Respiratory muscle function was most severely compromised in the typical form of NM. However, within the different forms a large variability was observed. This variability is partly explained by distinct differences in respiratory muscle function in relation to genotypes, but also by variation within genotypes. All patients with *NEB* and *ACTA1* mutations included had respiratory muscle weakness and most of these patients required non-invasive or invasive HMV, which is in accordance with previous studies [46,47]. In contrast, respiratory muscle function varied widely in the patients with *TPM2*, *TPM3*, *RYR1*, *CFL2*, *LMOD3*, and *MYPN* mutations. The adult *RYR1* patients and the adult *LMOD3* patient

had no respiratory muscle weakness. These findings stand out from previously described patients with severe or typical NM forms with respiratory insufficiency [3,5,6], which adds to the variability of the clinical spectrum of these genotypes. Another contrasting finding is that the included *TPM2* patients showed respiratory muscle weakness with a high MFM score, while mildly affected patients with mutations in this gene usually do not have respiratory muscle weakness [14]. Interestingly, we found mild respiratory muscle weakness in eight of the 24 patients with the childhood-onset with slowness form caused by a mutation in the *KBTBD13* gene, which has not been observed in previous cohort studies [20,30,31]. However, respiratory function tests were not systematically performed in these studies. A case report assessing FVC in a patient with a mutation in the *KBTBD13* gene did find respiratory muscle weakness [48]. Overall, the variability in respiratory muscle weakness between different NM forms and genotypes in our cohort emphasises the need for regular screening of respiratory muscle function in all patients with NM.

Importantly, we found a low correlation between motor function and spirometry. This may partly be explained by a known ceiling effect of the MFM in mildly affected patients [49]. However, 20 patients with high MFM scores (90% or more) showed a broad range of FVC values (48–93% predicted). Moreover, two *NEB* patients and one *ACTA1* patient with respiratory involvement in our study had a mild form of NM. This confirms the clinical observation that the degree of motor function impairment is not representative for respiratory muscle function in all patients with NM, as shown previously in case reports [50–52]. The low correlation could also be caused by the heterogeneity in genotypes. For example, the *TPM2* patients stand out with a high MFM score and a decreased FVC. Moreover, the correlation is influenced by a large group of mildly affected *KBTD13* patients. We cannot exclude that there is a stronger correlation between motor function and spirometry in specific genotypes or clinical forms of NM. The monocentric nature of our study and consequently the relatively low number of patients per genotype or clinical form of NM limits these subgroup analyses.

Diaphragm and intercostal muscle thickness and echogenicity did not differ between the different forms of NM. However, echogenicity of these respiratory muscles was higher than their predicted normal value in most patients. This finding is in line with a previous study which found high muscle echogenicity in peripheral muscles in NM caused by fatty degeneration [53]. A possible explanation for the lack of difference between the forms of NM might be that structural changes in the respiratory muscles precede changes in pulmonary function. In patients receiving HMV impaired diaphragm function is a key component of impaired respiratory function, shown by a decreased diaphragm thickness (end-inspiration) and a decreased $P_{m0,tw}$. In line with these results, previous post-mortem studies in cases with severe respiratory insufficiency have found a high concentration of nemaline rods in the diaphragm, indicating an important role of diaphragm involvement [54,55]. Whether respiratory muscle ultrasound is suitable as an outcome measure for respiratory function in NM patients should be evaluated in future studies.

All patients reported respiratory symptoms regardless of the degree of respiratory muscle weakness. Thus, in our study respiratory symptoms were not indicative of the severity of respiratory muscle weakness.

This study has several limitations. First, the number of patients for each form of NM, except childhood-onset NM with slowness, was limited. Second, genetically unresolved cases were not included. Third, no patients with severe NM were included. This led to a bias towards less severely affected patients. Fourth, there was a female predominance, which cannot be explained by a selection bias. This predominance of female patients was not reported in other studies [24,29]. Hence, because of this coincidence, these data are more representative for female patients. Last, were unable to perform a quantitative analysis on the reported respiratory symptoms, as we did not use a validated questionnaire.

Given that respiratory muscle weakness is an important feature in all forms of NM, future longitudinal studies and clinical trials should evaluate respiratory muscle function as well as general motor function. Longitudinal studies will be able to determine the intervals needed for respiratory monitoring by assessing the progression of respiratory muscle weakness. Relevant outcome measures for a longitudinal study of nemaline myopathy, including respiratory outcomes, have also been discussed [56]. Furthermore, these studies should also focus on which measurements and corresponding cut-off values can predict the need for HMV. Interestingly, diaphragm ultrasound has recently been shown as a novel predictor of nocturnal hypercapnia in slowly progressive myopathies [57].

In conclusion, respiratory muscle weakness in NM is present in all clinical forms and genotypes, and may be present irrespective of the degree of motor function impairment. Diaphragm dysfunction was identified as an important contributor to respiratory muscle weakness. In contrast to previous findings, we also found respiratory muscles weakness in patients with childhood-onset NM with slowness of movements. Therefore, screening of respiratory function is important to guide respiratory management in all patients with NM.

Funding sources

This work was supported by the Princess Beatrix Fund [Grant number W.OR17-08] and A Foundation Building Strength.

Stated declarations of interest

Esmee van Kleef:

Grants: Prinses Beatrix Spierfonds, A foundation Building Strength.

Jeroen van Doorn:

EURO-NMD bursary: Support for attending the 2021 WMS conference.

Michael Gaytant:

Member of the board of the association of caregivers and institutions who are involved in the treatment of patients with home mechanical ventilation (unpaid).

Willemien de Weerd:

None.

Bettine Vosse:

None.

Carina Wallgren-Pettersson:

Grants: The Finska Läkaresällskapet, The Medicinska Understödsföreningen Liv och Hälsa, The Perklén Foundation, A Foundation Building Strength.

Scientific board of private foundation funding research: the Minerva Institute.

Baziel van Engelen:

Grants: Prinses Beatrix Spierfonds, Dutch FSHD Foundation, Stichting Spieren voor Spieren.

Royalties/licences: Myositis. Patent number: EP2012740236, date of filing 5-7-2012.

Consulting fees paid to institution: Fulcum, Arrowhead, Facio.

Coen Ottenheijm:

Grants: Prinses Beatrix Spierfonds.

Nicol Voermans:

Grant: Prinses Beatrix Spierfonds.

Contract with Dynacure for performing phase 1-2 trial (paid to institution).

DSMB: Rycall trial, performed by NIH (paid to institution).

Chair of FSHD European trial network.

Jonne Doorduyn:

Grant: A foundation Building Strength.

Declarations of interest

None.

Acknowledgements

The patients with nemaline myopathy included in this study are acknowledged for their participation. Several authors are members of the European Reference Network for rare neuromuscular diseases (EURO-NMD).

References

- [1] Laitila J, Wallgren-Pettersson C. Recent advances in nemaline myopathy. *Neuromuscul Disord* 2021;31:955–67. doi:10.1016/j.nmd.2021.07.012.
- [2] Sewry CA, Laitila JM, Wallgren-Pettersson C. Nemaline myopathies: a current view. *J Muscle Res Cell Motil* 2019;40:111–26. doi:10.1007/s10974-019-09519-9.
- [3] Yuen M, Sandaradura SA, Dowling JJ, Kostyukova AS, Moroz N, Quinlan KG, et al. Leiomodlin-3 dysfunction results in thin filament disorganization and nemaline myopathy. *J Clin Invest* 2014;124:4693–708. doi:10.1172/jci75199.
- [4] Sambuughin N, Yau KS, Olivé M, Duff RM, Bayarsaikhan M, Lu S, et al. Dominant mutations in KBTBD13, a member of the BTB/Kelch family, cause nemaline myopathy with cores. *Am J Hum Genet* 2010;87:842–7. doi:10.1016/j.ajhg.2010.10.020.
- [5] Hernandez-Lain A, Husson I, Monnier N, Farnoux C, Brochier G, Lacène E, et al. De novo RYR1 heterozygous mutation (I4898T) causing lethal core-rod myopathy in twins. *Eur J Med Genet* 2011;54:29–33. doi:10.1016/j.ejmg.2010.09.009.
- [6] Kondo E, Nishimura T, Kosho T, Inaba Y, Mitsuhashi S, Ishida T, et al. Recessive RYR1 mutations in a patient with severe congenital nemaline myopathy with ophthalmoplegia identified through massively parallel sequencing. *Am J Med Genet A* 2012;158a:772–8. doi:10.1002/ajmg.a.35243.
- [7] Gupta VA, Ravenscroft G, Shaheen R, Todd EJ, Swanson LC, Shiina M, et al. Identification of KLHL41 Mutations Implicates BTB-Kelch-Mediated Ubiquitination as an Alternate Pathway to Myofibrillar Disruption in Nemaline Myopathy. *Am J Hum Genet* 2013;93:1108–17. doi:10.1016/j.ajhg.2013.10.020.
- [8] Ravenscroft G, Miyatake S, Lehtokari VL, Todd EJ, Vornanen P, Yau KS, et al. Mutations in KLHL40 are a frequent cause of severe autosomal-recessive nemaline myopathy. *Am J Hum Genet* 2013;93:6–18. doi:10.1016/j.ajhg.2013.05.004.
- [9] Miyatake S, Mitsuhashi S, Hayashi YK, Purojvav E, Nishikawa A, Koshimizu E, et al. Biallelic Mutations in MYPN, Encoding Myopalladin, Are Associated with Childhood-Onset, Slowly Progressive Nemaline Myopathy. *Am J Hum Genet* 2017;100:169–78. doi:10.1016/j.ajhg.2016.11.017.
- [10] Nilipour Y, Nafissi S, Tjust AE, Ravenscroft G, Hossein Nejad Nedai H, Taylor RL, et al. Ryanodine receptor type 3 (RYR3) as a novel gene associated with a myopathy with nemaline bodies. *Eur J Neurol* 2018;25:841–7. doi:10.1111/ene.13607.
- [11] Sandaradura SA, Bournazos A, Mallawaarachchi A, Cummings BB, Waddell LB, Jones KJ, et al. Nemaline myopathy and distal arthrogyrosis associated with an autosomal recessive TNNT3 splice variant. *Hum Mutat* 2018;39:383–8. doi:10.1002/humu.23385.
- [12] Agrawal PB, Greenleaf RS, Tomczak KK, Lehtokari VL, Wallgren-Pettersson C, Wallefeld W, et al. Nemaline myopathy with minicores caused by mutation of the CFL2 gene encoding the skeletal muscle actin-binding protein, cofilin-2. *Am J Hum Genet* 2007;80:162–7. doi:10.1086/510402.
- [13] Kiphuth IC, Krause S, Huttner HB, Dekomien G, Struffert T, Schröder R. Autosomal dominant nemaline myopathy caused by a novel alpha-tropomyosin 3 mutation. *J Neurol* 2010;257:658–60. doi:10.1007/s00415-009-5413-y.
- [14] Davidson AE, Siddiqui FM, Lopez MA, Lunt P, Carlson HA, Moore BE, et al. Novel deletion of lysine 7 expands the clinical, histopathological and genetic spectrum of TPM2-related myopathies. *Brain* 2013;136:508–21. doi:10.1093/brain/aws344.
- [15] Pelin K, Ridanpää M, Donner K, Wilton S, Krishnarajah J, Laing N, et al. Refined localisation of the genes for nebulin and titin on chromosome 2q allows the assignment of nebulin as a candidate gene for autosomal recessive nemaline myopathy. *Eur J Hum Genet* 1997;5:229–34.
- [16] Johnston JJ, Kelley RI, Crawford TO, Morton DH, Agarwala R, Koch T, et al. A novel nemaline myopathy in the Amish caused by a mutation in troponin T1. *Am J Hum Genet* 2000;67:814–21. doi:10.1086/303089.
- [17] Nowak KJ, Wattanasirichaigoon D, Goebel HH, Wilce M, Pelin K, Donner K, et al. Mutations in the skeletal muscle alpha-actin gene in patients with actin myopathy and nemaline myopathy. *Nat Genet* 1999;23:208–12. doi:10.1038/13837.
- [18] Pauw-Gommans IM, Gerrits KH, de Haan A, van Engelen BG. Muscle slowness in a family with nemaline myopathy. *Neuromuscul Disord* 2006;16:477–80. doi:10.1016/j.nmd.2006.05.003.
- [19] Gommans IM, Davis M, Saar K, Lammens M, Mastaglia F, Lamont P, et al. A locus on chromosome 15q for a dominantly inherited nemaline myopathy with core-like lesions. *Brain* 2003;126:1545–51. doi:10.1093/brain/awg162.
- [20] Gommans IM, van Engelen BG, ter Laak HJ, Brunner HG, Kremer H, Lammens M, et al. A new phenotype of autosomal dominant nemaline myopathy. *Neuromuscul Disord* 2002;12:13–18. doi:10.1016/s0960-8966(01)00231-0.
- [21] de Winter JM, Molenaar JP, Yuen M, van der Pijl R, Shen S, Conijn S, et al. KBTBD13 is an actin-binding protein that modulates muscle kinetics. *J Clin Invest* 2020;130:754–67. doi:10.1172/jci124000.
- [22] Wallgren-Pettersson C, Sewry CA, Nowak KJ, Laing NG. Nemaline myopathies. *Semin Pediatr Neurol* 2011;18:230–8. doi:10.1016/j.spen.2011.10.004.
- [23] Smith BK, Bleiweis MS, Zauhar J, Martin AD. Inspiratory muscle training in a child with nemaline myopathy and organ transplantation. *Pediatr Crit Care Med* 2011;12:e94–8. doi:10.1097/PCC.0b013e3181d8e680.
- [24] Ryan MM, Schnell C, Strickland CD, Shield LK, Morgan G, Iannaccone ST, et al. Nemaline myopathy: a clinical study of 143 cases. *Ann Neurol* 2001;50:312–20. doi:10.1002/ana.1080.
- [25] Yin X, Pu CQ, Wang Q, Liu JX, Mao YL. Clinical and pathological features of patients with nemaline myopathy. *Mol Med Rep* 2014;10:175–82. doi:10.3892/mmr.2014.2184.
- [26] Yin X, Pu C, Wang Z, Li K, Wang H. Clinico-pathological features and mutational spectrum of 16 nemaline myopathy patients from a Chinese neuromuscular center. *Acta Neurol Belg* 2021. doi:10.1007/s13760-020-01542-9.
- [27] Wang Q, Hu Z, Chang X, Yu M, Xie Z, Lv H, et al. Mutational and clinical spectrum in a cohort of Chinese patients with hereditary nemaline myopathy. *Clin Genet* 2020;97:878–89. doi:10.1111/cge.13745.
- [28] Nagata R, Kamimura D, Suzuki Y, Saito T, Toyama H, Dejima T, et al. A case of nemaline myopathy with associated dilated cardiomyopathy and respiratory failure. *Int Heart J* 2011;52:401–5. doi:10.1536/ihj.52.401.
- [29] Amburgey K, Acker M, Saeed S, Amin R, Beggs AH, Bonnemann CG, et al. A Cross-Sectional Study of Nemaline Myopathy. *Neurology* 2021;96:e1425–36. doi:10.1212/WNL.00000000000011458.
- [30] Kang ZX, Wei XJ, Miao J, Gao YL, Wang ZY, Yu XF. A family with nemaline myopathy type 6 caused by heterozygous mutation (c.1222C>T) in the KBTBD13 gene in China: A case report. *Neuropathology* 2020;40:104–8. doi:10.1111/neup.12610.
- [31] Olivé M, Goldfarb LG, Lee HS, Odgerel Z, Blokhin A, Gonzalez-Mera L, et al. Nemaline myopathy type 6: clinical and myopathological features. *Muscle Nerve* 2010;42:901–7. doi:10.1002/mus.21788.
- [32] Côté P, Kreitz BG, Cassidy JD, Dzus AK, Martel J. A study of the diagnostic accuracy and reliability of the Scoliometer and Adam's forward bend test. *Spine (Phila Pa 1976)* 1998;23:796–802 discussion 803. doi:10.1097/00007632-199804010-00011.
- [33] Quanjer PH, Stanojevic S, Cole TJ, Baur X, Hall GL, Culver BH, et al. Multi-ethnic reference values for spirometry for the 3–95-yr age range: the global lung function 2012 equations. *Eur Respir J* 2012;40:1324–43. doi:10.1183/09031936.00080312.
- [34] Wilson SH, Cooke NT, Edwards RH, Spiro SG. Predicted normal values for maximal respiratory pressures in caucasian adults and children. *Thorax* 1984;39:535–8. doi:10.1136/thx.39.7.535.
- [35] Uldry C, Fitting JW. Maximal values of sniff nasal inspiratory pressure in healthy subjects. *Thorax* 1995;50:371–5. doi:10.1136/thx.50.4.371.
- [36] Laveneziana P, Albuquerque A, Aliverti A, Babb T, Barreiro E, Dres M, et al. ERS statement on respiratory muscle testing at rest and during exercise. *Eur Respir J* 2019;53. doi:10.1183/13993003.01214-2018.
- [37] Graham BL, Steenbruggen I, Miller MR, Barjaktarevic IZ, Cooper BG, Hall GL, et al. Standardization of Spirometry 2019 Update. An Official American Thoracic Society and European Respiratory Society Technical Statement. *Am J Respir Crit Care Med* 2019;200:e70–88. doi:10.1164/rccm.201908-1590ST.
- [38] American Thoracic Society/European Respiratory Society. SATS/ERS Statement on respiratory muscle testing. *Am J Respir Crit Care Med* 2002;166:518–624. doi:10.1164/rccm.166.4.518.
- [39] Boon AJ, Harper CJ, Ghahfarokhi LS, Strommen JA, Watson JC, Sorenson EJ. Two-dimensional ultrasound imaging of the diaphragm: quantitative values in normal subjects. *Muscle Nerve* 2013;47:884–9. doi:10.1002/mus.23702.
- [40] van Doorn JLM, Pennati F, Hansen HHG, van Engelen BGM, Aliverti A, Doorduyn J. Respiratory muscle imaging by ultrasound and MRI in neuromuscular disorders. *Eur Respir J* 2021. doi:10.1183/13993003.00137-2021.
- [41] Sarwal A, Parry SM, Berry MJ, Hsu FC, Lewis MT, Justus NW, et al. Interobserver Reliability of Quantitative Muscle Sonographic Analysis in the Critically Ill Population. *J Ultrasound Med* 2015;34:1191–200. doi:10.7863/ultra.34.7.1191.
- [42] Pillen S, Arts IM, Zwarts MJ. Muscle ultrasound in neuromuscular disorders. *Muscle Nerve* 2008;37:679–93. doi:10.1002/mus.21015.
- [43] Santos DB, Desmarais G, Falaize L, Ogna A, Cognet S, Louis B, et al. Twitch mouth pressure for detecting respiratory muscle weakness in suspicion of neuromuscular disorder. *Neuromuscul Disord* 2017;27:518–25. doi:10.1016/j.nmd.2017.01.022.
- [44] Wragg S, Hamnegard C, Road J, Kyroussis D, Moran J, Green M, et al. Potentiation of diaphragmatic twitch after voluntary contraction in normal subjects. *Thorax* 1994;49:1234–7. doi:10.1136/thx.49.12.1234.
- [45] Laghi F, Tobin MJ. Relationship between transdiaphragmatic and mouth twitch pressures at functional residual capacity. *Eur Respir J* 1997;10:530–6.
- [46] Moreno CAM, Abath Neto O, Donkervoort S, Hu Y, Reed UC, Oliveira ASB, et al. Clinical and Histologic Findings in ACTA1-Related Nemaline Myopathy: Case Series and Review of the Literature. *Pediatr Neurol* 2017;75:11–16. doi:10.1016/j.pediatrneurol.2017.04.002.
- [47] Piga D, Magri F, Ronchi D, Corti S, Cassandrini D, Mercuri E, et al. New Mutations in NEB Gene Discovered by Targeted Next-Generation Sequencing in Nemaline Myopathy Italian Patients. *J Mol Neurosci* 2016;59:351–9. doi:10.1007/s12031-016-0739-2.
- [48] Garibaldi M, Fattori F, Bortolotti CA, Brochier G, Labasse C, Verardo M, et al. Core-rod myopathy due to a novel mutation in BTB/POZ domain of KBTBD13 manifesting as late onset LGMD. *Acta Neuropathol Commun* 2018;6:94. doi:10.1186/s40478-018-0595-0.
- [49] Mul K, Horlings CGC, Faber CG, van Engelen BGM, Merkies ISJ. Rasch analysis to evaluate the motor function measure for patients with facioscapulohumeral muscular dystrophy. *Int J Rehabil Res* 2021;44:38–44. doi:10.1097/mrr.0000000000000444.
- [50] Belfort P, Landreau L, Pagès AM, Jonquet O, Pagès M. [Adult onset nemaline myopathy revealed by respiratory insufficiency]. *Rev Neurol (Paris)* 2006;162:1260–2. doi:10.1016/s0035-3787(06)75141-4.

- [51] Kelly E, Farrell MA, McElvaney NG. Adult-onset nemaline myopathy presenting as respiratory failure. *Respir Care* 2008;53:1490–4.
- [52] Whitaker J, Love S, Williams AP, Plummeridge M. Idiopathic adult-onset nemaline myopathy presenting with isolated respiratory failure. *Muscle Nerve* 2009;39:406–8. doi:10.1002/mus.21234.
- [53] Wallgren-Pettersson C, Kivisaari L, Jääskeläinen J, Lamminen A, Holmberg C. Ultrasonography, CT, and MRI of muscles in congenital nemaline myopathy. *Pediatr Neurol* 1990;6:20–8. doi:10.1016/0887-8994(90)90074-b.
- [54] Shafiq SA, Dubowitz V, Peterson Hde C, Milhorat AT. Nemaline myopathy: report of a fatal case, with histochemical and electron microscopic studies. *Brain* 1967;90:817–28. doi:10.1093/brain/90.4.817.
- [55] Tsujihata M, Shimomura C, Yoshimura T, Sato A, Ogawa T, Tsuji Y, et al. Fatal neonatal nemaline myopathy: a case report. *J Neurol Neurosurg Psychiatry* 1983;46:856–9. doi:10.1136/jnnp.46.9.856.
- [56] Neuhaus SB, Wallgren-Pettersson C, Bönnemann CG, Schara U, Servais L. 250th ENMC International Workshop: Clinical trial readiness in nemaline myopathy 6–8 September 2019, Hoofddorp, the Netherlands. *Neuromuscul Disord* 2020;30:866–75. doi:10.1016/j.nmd.2020.08.356.
- [57] Spiesshoefer J, Lutter R, Kabitz HJ, Henke C, Herkenrath S, Randerath W, et al. Respiratory Muscle Function Tests and Diaphragm Ultrasound Predict Nocturnal Hypoventilation in Slowly Progressive Myopathies. *Front Neurol* 2021;12:731865. doi:10.3389/fneur.2021.731865.